

## Previously published content

Content in the following section, and as listed below, was previously published in regular issues of *The Journal of Laryngology & Otology*.

As such, all content and associated bibliographic data (Volume and Issue numbers, page ranges, DOIs, and publication dates) remain unchanged in both print and electronic formats.

All citations should be to the original Volume and Issue of publication (see below list and individual paper details), and not to this Supplement.

### Review

Wood JM, Hussey DJ, Woods CM, Watson DI, Carney AS. Biomarkers and laryngopharyngeal reflux. *J Laryngol Otol* 2011;**125**:1218–24.  
<http://dx.doi.org/10.1017/S0022215111002234>

### Main Articles

Prasad BK. ENT morbidity at high altitude. *J Laryngol Otol* 2011;**125**:188–92.  
<http://dx.doi.org/10.1017/S00222151110002331>

Choroomi S, Curotta J. Foreign body aspiration and language spoken at home: 10-year review. *J Laryngol Otol* 2011;**125**:719–23.  
<http://dx.doi.org/10.1017/S0022215111000727>

Albirmawy OA. Ring versus ‘Mercedes-Benz’ cartilage-perichondrium graft tympanoplasty in management of pars tensa cholesteatoma. *J Laryngol Otol* 2011;**125**:1232–38.  
<http://dx.doi.org/10.1017/S0022215111002593>

Sivasubramaniam R, Sacks R, Thornton M. Silent sinus syndrome: dynamic changes in the position of the orbital floor after restoration of normal sinus pressure. *J Laryngol Otol* 2011;**125**:1239–43.  
<http://dx.doi.org/10.1017/S0022215111001952>

Hesham A, Ghali A. Rapid Rhino versus Merocel nasal packs in septal surgery. *J Laryngol Otol* 2011;**125**:1244–46.  
<http://dx.doi.org/10.1017/S0022215111002179>

Lester SE, Rigby MH, MacLean M, Taylor SM. ‘How does that sound?’: objective and subjective voice outcomes following CO<sub>2</sub> laser resection for early glottic cancer. *J Laryngol Otol* 2011;**125**:1251–55.  
<http://dx.doi.org/10.1017/S0022215111002490>

Penney SE, Homer JJ. Thyroid lymphoma: acute presentation and long-term outcome. *J Laryngol Otol* 2011;**125**:1256–62.  
<http://dx.doi.org/10.1017/S0022215111001812>

Fleming JC, Gibbins N, Ingram PJ, Harries M. An anatomical study of the myelination of human laryngeal nerves. *J Laryngol Otol* 2011;**125**:1263–67.  
<http://dx.doi.org/10.1017/S0022215111001939>

### Clinical Records

Teh BM, Hall C, Kleid S. Infected tracheocele (acquired tracheal diverticulum): case report and literature review. *J Laryngol Otol* 2011;**125**:540–45.  
<http://dx.doi.org/10.1017/S00222151110003026>

Joshi H, Woodworth BA, Carney AS. Coblation for epistaxis management in patients with hereditary haemorrhagic telangiectasia: a multicentre case series. *J Laryngol Otol* 2011;**125**:1176–80.  
<http://dx.doi.org/10.1017/S0022215111001733>

## Biomarkers and laryngopharyngeal reflux

J M WOOD, D J HUSSEY, C M WOODS, D I WATSON, A S CARNEY

*ENT Unit, Department of Surgery, Flinders University and Flinders Medical Centre, Bedford Park, South Australia, Australia*

### Abstract

Laryngopharyngeal reflux is a controversial but increasingly made diagnosis used in patients with a collection of often non-specific laryngeal symptoms. It is a clinical diagnosis, and its pathophysiology is currently poorly understood.

Previous reflux research has focused on injurious agents, acid, pepsin and biomarker expression. Failure of intrinsic defences in the larynx may cause changes in laryngeal epithelia, particularly alterations in carbonic anhydrases and E-cadherin. Carbonic anhydrase III levels vary in the larynx in response to laryngopharyngeal reflux, depending on location. Expression of E-cadherin, a known tumour suppressor, is reduced in the presence of reflux. Mucin expression also varies according to the severity of reflux.

Further research is required to define the clinical entity of laryngopharyngeal reflux, and to identify a definitive mechanism for mucosal injury. Understanding this mechanism should allow the development of a comprehensive model, which would enable future diagnostic and therapeutic interventions to be developed.

**Key words:** Larynx; Mucins; Pepsin A; Gastroesophageal Reflux; Carbonic Anhydrases; Cadherins

### Introduction

Throat symptoms and gastroesophageal reflux are common clinical complaints which may be linked, with at least a proportion of some throat symptoms occurring secondary to laryngopharyngeal reflux. However, laryngopharyngeal reflux is a highly controversial issue for otolaryngologists, gastroenterologists and upper gastrointestinal surgeons, with widely varying views held about its prevalence, aetiology, diagnosis and treatment. A better understanding of this condition, and of the role of various investigations and treatments, is essential for progress in this area.

In this paper, we review the evidence supporting the diagnosis of laryngopharyngeal reflux, focusing on the role of molecular biology and on the possible ways this may assist the clinician.

Gastroesophageal reflux disease is one of the commonest diseases in the Western world,<sup>1,2</sup> affecting up to 50 per cent of Western adult populations. Extra-oesophageal manifestations of gastroesophageal reflux disease have progressively attracted attention over the last 15 years, and have been linked to asthma, non-cardiac chest pain and chronic cough. Otolaryngological manifestations attributed to laryngopharyngeal reflux may include dysphagia, dysphonia, hoarseness, globus pharyngeus and altered salivation.<sup>3</sup>

Laryngopharyngeal reflux is increasingly 'diagnosed' in ENT practice, and often suspected in patients

who present with chronic or intermittent laryngopharyngeal symptoms. These patients are typically identified by their medical history, clinical examination and fibre-optic laryngoscopy results. Changes attributed to laryngopharyngeal reflux include erythema and oedema of the posterior commissure, laryngeal granulomata, subglottic stenosis, vocal fold nodules, and laryngeal pseudosulcus. Both pre-malignant and malignant transformations have also been attributed to laryngopharyngeal reflux.<sup>4</sup> However, a history of non-specific laryngeal symptoms, and examination findings with poor inter-observer reliability,<sup>5</sup> make definitive diagnosis difficult.

From clinical and molecular biology research, it is becoming apparent that the pathophysiology of laryngopharyngeal reflux may actually be different to that of gastroesophageal reflux disease.<sup>4</sup> Patients with laryngopharyngeal reflux are thought to suffer more upright (daytime) reflux, whereas patients with gastroesophageal reflux disease tend to reflux more in the supine (nocturnal) position.<sup>4</sup> Additionally, it is likely that mucosal acid exposure is prolonged in gastroesophageal reflux disease when compared with laryngopharyngeal reflux.<sup>4</sup> This is because distal oesophageal acid exposure is always greater than proximal exposure, and the mechanism underpinning laryngopharyngeal reflux probably depends on shorter periods of exposure to refluxate.

Despite this, definitive diagnosis has proved elusive, and there is no consistently reliable diagnostic tool currently available.<sup>6</sup> Hypopharyngeal pH monitoring has a reported diagnostic sensitivity of only 40 per cent,<sup>7</sup> and there is no pathognomonic laryngopharyngeal reflux finding on laryngoscopy.

Currently, commencement of empirical antireflux medication (typically proton-pump inhibitors (PPIs)) has been used as an alternative diagnostic modality, with a favourable response taken as 'confirming' the diagnosis. The literature on PPIs and other antireflux medication is variable in quality, and different outcomes have been reported.<sup>8</sup>

Laparoscopic fundoplication is a well established surgical treatment for gastroesophageal reflux disease, with reliable and reproducible results;<sup>9</sup> however, its role in the management of laryngopharyngeal reflux is uncertain. Recent research reviewing a large series of patients following fundoplication found that patients with throat symptoms in addition to typical (gastroesophageal) reflux symptoms had a similar improvement to those with only typical reflux symptoms.<sup>9</sup> In contrast, patients with only throat symptoms, but with objective evidence of reflux on 24-hour pH monitoring, had a much poorer outcome,<sup>9</sup> indicating a possible non-reflux-related cause of symptoms in many of these patients.

However, an incomplete understanding of the pathophysiology and accurate diagnosis of laryngopharyngeal reflux makes high quality evaluation of any medical or surgical management difficult. Consequently, an understanding of the molecular basis of laryngopharyngeal reflux is an important first step.

### Damaging events

The luminal environment of the pharynx is pH-neutral, at 7.0,<sup>10</sup> whilst the stomach secretes acid at a pH of 1.5 to 2.0. Consequently, reflux can lead to a significant decrease in laryngeal pH. Damage may occur due to this drop in pH and also due to exposure to noxious elements in the refluxate, including pepsin, bile salts and pancreatic enzymes.<sup>11</sup> In order for refluxate to reach the oesophagus and larynx, there needs to be failure of the anatomical and physiological barriers to reflux. Whilst it is normal for individuals to experience some 'physiological' oesophageal reflux, the amount of laryngopharyngeal reflux required to cause injury is uncertain.

#### Acid

Whilst up to 50 oesophageal reflux episodes per day can be considered normal,<sup>12</sup> as few as three episodes of laryngeal reflux may cause mucosal injury.<sup>3</sup> Consequently, techniques for diagnosing laryngeal reflux episodes based on oesophageal reflux may lack the sensitivity to identify such infrequent events. Acid reflux is recognised as leading to oesophagitis, which increases in severity with increasing acid exposure. However, the effect of acid on the larynx is

uncertain, with some research suggesting that a combination of acid and pepsin is required to cause laryngeal damage.<sup>11</sup>

#### Pepsin

Non-acidic reflux has increasingly been implicated in leading to inflammation in both laryngopharyngeal reflux and gastroesophageal reflux disease. Multi-channel intra-luminal pH monitoring impedance studies have identified episodes of gastric reflux that are either non-acidic or weakly acidic, in symptomatic patients,<sup>13</sup> suggesting that mucosal injury may be caused by non-acid refluxate components such as bile salts and pepsin. The damaging effects of pepsin in an acidic environment have been well described previously,<sup>3</sup> with an optimum activity at a pH of 2.0.<sup>14</sup> Recent research has proposed that pepsin is a causative agent of laryngeal damage in non-acidic reflux.<sup>11–13,15</sup>

Whilst pepsin is inactive at a pH of 6.5,<sup>14</sup> it is irreversibly inactivated at a pH of 8.0.<sup>16</sup> Recently, it has been shown that at 37°C pepsin remains stable at a pH of 7.0 for more than 24 hours, retaining nearly 80 per cent of its original activity on re-acidification. With a mean pH of 6.8,<sup>15</sup> the larynx may contain stable pepsin, which may potentially cause more damage with subsequent reflux episodes. Additionally, there is evidence that such pepsin is actively transported into, and remains within, laryngeal epithelial cells.<sup>16</sup> Intracellular structures such as Golgi bodies and lysosomes have a lower pH (of 5.0 and 4.0, respectively); therefore, pepsin could be acting by causing intracellular damage<sup>16</sup> even if the larynx itself is only exposed to inactive pepsin.

Furthermore, research on patients with reflux-attributed laryngeal disease has found a significant association between the presence of pepsin in laryngeal epithelia and the depletion of two laryngeal protective proteins, carbonic anhydrase isoenzyme III (CA III) and Sep70 (a squamous epithelial stress protein).<sup>16</sup> It is of note that both these proteins are depleted after exposure to pepsin, and not in response to low pH alone, suggesting a specific role for pepsin in laryngeal damage.

#### Bile acids

While acid and pepsin are important in the development of oesophageal mucosal injury, there is evidence to suggest that duodeno-gastro-oesophageal reflux contributes bile acids and pancreatic secretions to the refluxate. Duodenal secretions have been shown in clinical studies to be capable of refluxing into the stomach and oesophagus,<sup>17,18</sup> and of causing damage to the larynx.<sup>19</sup> Conjugated bile causes mucosal injury at a low pH (1.2–1.5).<sup>20</sup>

Interestingly, the unconjugated component of bile, chenodeoxycholic acid, is activated at pH 7.0 but not at pH 2.0. Consequently, in the experimental setting, conjugated bile acids are more injurious to mucosa at an acidic pH, whereas chenodeoxycholic acid is more active at pH 5.0–8.0.<sup>19</sup> Recent research exposed rat

laryngeal mucosa to taurocholic acid and chenodeoxycholic acid at a pH range of 1.5–7.4, with normal saline as a negative control, and found that taurocholic acid is injurious to laryngeal mucosa at a pH of 1.5, whereas chenodeoxycholic acid causes maximum inflammation at a pH of 7.4.<sup>19</sup> This suggests that bile has a mechanism for generating laryngeal injury in both acid and non-acid environments, although it remains to be determined whether the same mechanism occurs in the human larynx.

## Reflux biomarkers

### *Inflammatory cytokines*

Multiple inflammatory cytokines have been implicated in oesophageal mucosal inflammation caused by reflux. It has been well documented that gastroesophageal reflux disease leads to changes in interleukin-6 (IL-6) messenger RNA expression, and this correlates with reflux-induced mucosal inflammation.<sup>21</sup> Interleukin-6 is a cytokine with roles in multiple processes, including acute-phase responses and inflammation and immune responses.<sup>22</sup> It is recognised that oesophageal levels of IL-6 increase as the grade of reflux pathology increases, and decrease following treatment of gastroesophageal reflux disease. Consequently, it would be reasonable to consider IL-6 to be an indicator of reflux-related inflammation in both the oesophageal and laryngeal mucosa. Despite this, few studies of laryngopharyngeal reflux have directly included IL-6 as a marker of inflammation.<sup>23</sup>

Interleukin-8 has also been implicated in the inflammatory process associated with gastroesophageal reflux disease, and its expression has been found to increase with such reflux. The greatest expression levels have been found in the oesophageal mucosa of patients with reflux-related complications, including Barrett's dysplasia and adenocarcinoma. Following anti-reflux surgery, IL-8 levels decrease significantly.<sup>24</sup> Activation of this cytokine is of importance, given its role in tumour progression. Tumour-derived IL-8 is recognised as having an autocrine mechanism, and can activate endothelial cells in tumour vasculature to promote angiogenesis; it can also enhance the proliferation and survival of cancer cells. Furthermore, it can induce tumour-associated macrophages to secrete additional growth factors that can increase the rate of cell proliferation.<sup>25</sup> The involvement of IL-8 in laryngopharyngeal reflux is still uncertain. However, *in vitro* experiments have demonstrated increased expression of this and other inflammatory markers, when exposed to pepsin.<sup>13</sup>

### *Carbonic anhydrase*

The actual mechanism of damage caused by reflux is elusive. However, recent research has focused on the failure of anti-reflux barriers. Such failure could allow increased exposure of epithelia to refluxate, and in laryngopharyngeal reflux this occurs in an area considered to be more sensitive than the oesophagus to

such injury.<sup>12</sup> Such exposure may have greater effects because the larynx lacks some of the extrinsic defences which are normally present in the oesophagus. Carbonic anhydrase (CA) is an integral component of this defence, and acts by catalysing the reversible hydration of carbon dioxide. This produces bicarbonate ions which are then actively pumped into the extracellular space, enabling neutralisation of acidic refluxate. In the oesophagus, this process plays a significant role, with CA capable of increasing the pH of gastroesophageal refluxed residual acid from 2.5 to close to neutral.<sup>26</sup>

There are 11 identified CA isoenzymes,<sup>27</sup> with demonstrated differences in activity, inhibitor susceptibility and tissue distribution. Carbonic anhydrase isoenzymes I to IV have been demonstrated to be expressed by oesophageal epithelium, and changes in distribution have been found in inflamed oesophageal biopsy specimens.<sup>27</sup>

Recent research has demonstrated that CA isoenzymes I, II and III are present in normal laryngeal epithelial cells to a variable extent.<sup>27,28</sup> Carbonic anhydrase isoenzyme III has been demonstrated in the squamous epithelial cells of the oesophagus and in the posterior commissure area of the larynx.<sup>29</sup> In inflamed oesophageal mucosa from patients with gastroesophageal reflux disease, increased levels of CA III expression have been noted both in the oesophageal squamous epithelia and in the laryngeal commissure, with a redistribution of expression from the basal to the suprabasal cell layers.<sup>27,30</sup> It is thought that these changes are due to refluxate, and represent attempts to counteract damage.<sup>29</sup> It has been proposed that an increase in CA III expression may be due to basal cell hyperplasia, a histopathological sign of oesophagitis.<sup>27</sup>

Carbonic anhydrase isoenzymes I and II have been demonstrated in both the vocal fold and inter-arytenoid areas, while CA III has been found throughout the laryngeal epithelium. In patients with laryngopharyngeal reflux, the expression of CA III has been found to differ between laryngeal biopsy locations.<sup>27</sup> In the presence of laryngopharyngeal reflux, and pepsin in particular, CA III expression in the vocal fold is potentially decreased, allowing further damage to occur from acidic refluxate. Conversely, CA III expression may increase in the posterior commissure in response to laryngopharyngeal reflux,<sup>12</sup> with a correlation between symptom severity and CA III levels.<sup>28</sup> Given that the larynx possesses areas of respiratory-type epithelium in addition to squamous epithelium, there remains the possibility that certain laryngeal areas may vary in response to laryngopharyngeal reflux; however, there is currently no epidemiological research assessing the epithelial type of various laryngeal areas in patients with laryngopharyngeal reflux.

### *E-Cadherin*

The cadherin family of molecules are calcium-dependent, cell–cell adhesion molecules which mediate

homophilic adhesion. E-cadherin is recognised as having a crucial role in the maintenance of epithelial integrity and barrier functions.<sup>29</sup> Damage to epithelial cell–cell adhesion from refluxate may lead to a breach of the mucosal barrier. Pepsin has been proposed to damage structures by digesting intracellular structures that maintain cohesion between cells.<sup>29</sup> Levels of E-cadherin have been found to decrease in response to laryngopharyngeal reflux,<sup>31</sup> but it is not clear whether this down-regulation is due to the refluxate components (e.g. acid and pepsin) or to an inflammatory response associated with the reflux.

Decreased expression of E-cadherin has been associated with poor prognostic factors in head and neck squamous cell carcinoma patients, including vascular invasion, and with decreased patient survival.<sup>32</sup> There is strong evidence that E-cadherin is a tumour suppressor, and that the loss of E-cadherin expression is a key initial step in tumour invasion.<sup>32</sup> Consequently, decreased E-cadherin expression in the presence of laryngopharyngeal reflux may play a role in the development of laryngeal symptoms, and may contribute to the development of laryngeal carcinoma in the setting of reflux.

### Mucins

Mucins are high molecular weight glycoproteins which traditionally have been considered to be gel-forming components of viscoelastic mucus gels. They are expressed by various epithelial cell types that exist in relatively harsh environments exposed to fluctuations in pH, ionic concentration, hydration and oxygenation. Accordingly, their primary functions are protection, lubrication and transport. Mucins have also been implicated in renewal and differentiation of epithelium, modulation of cell cycle progression, adhesion, and signal cell transduction.<sup>33</sup> They have a role in maintaining homeostasis, and consequently promote cell survival. They are classified into two primary classes: secreted gel-forming mucins and transmembrane mucins. Sixteen mucins (see Table I adjustment) have been identified in the aerodigestive tract (Table I). Altered expression of mucins has been reported in a number of inflammatory and neoplastic diseases.

Samuels *et al.*<sup>33</sup> studied laryngeal biopsies from three patients with laryngopharyngeal reflux and two controls. MUC1–5, 7, 9, 13, 15, 16 and 18–20 were detected in normal laryngeal epithelium, while mucins 6, 8 and 17 were absent. Of these, MUC1 and 4 were the predominant transmembrane mucins, and MUC2, 5A and 5B the major constituents of airway mucus in the laryngeal epithelium. In the patients with laryngopharyngeal reflux, there was decreased expression of MUC2, 5A and 5B. This would lead to an overall decrease in mucin secretion from the laryngeal epithelium, resulting in decreased protection against further reflux episodes. This is consistent with a gastroesophageal reflux disease model in

TABLE I  
MUCIN GENES IN THE AERODIGESTIVE TRACT

Gene	Localisation	Primary tissue expression
<i>MUC1</i>	Transmembrane	Breast, pancreas
<i>MUC2</i>	Secreted	Jejunum, ileum, colon
<i>MUC3</i>	Transmembrane	Colon, small intestine, gallbladder
<i>MUC4</i>	Transmembrane	Airways, colon
<i>MUC5AC</i>	Secreted	Airways, stomach
<i>MUC5B</i>	Secreted	Airways, submandibular glands
<i>MUC6</i>	Secreted	Stomach, ileum, gallbladder
<i>MUC7</i>	Secreted	Sublingual & submandibular glands
<i>MUC8</i>	Secreted	Airways
<i>MUC12</i>	Transmembrane	Colon, airways, reproductive tract
<i>MUC13</i>	Transmembrane	Colon, trachea, kidney, small intestine
<i>MUC15</i>	Transmembrane	Colon, airways, small intestine, prostate
<i>MUC17</i>	Transmembrane	Duodenum, colon, stomach
<i>MUC18</i>	Transmembrane	Airways, lung, breast
<i>MUC19</i>	Secreted	Salivary glands, trachea
<i>MUC20</i>	Transmembrane	Placenta, colon, lung, prostate, liver

Adapted with permission.<sup>33</sup>

which oesophageal mucin secretion was also reduced in patients with reflux oesophagitis.<sup>34</sup>

Alterations in mucin expression have been identified in a variety of inflammatory conditions, including gastritis, peptic ulcer disease, intestinal neoplasia and inflammatory bowel diseases.

A reduction in MUC3 expression has also been noted in samples from laryngopharyngeal reflux patients. MUC3 has been noted to play an active role in epithelial cell restitution.<sup>35</sup> Specifically MUC3A mucins are thought to play a role in the maintenance of intestinal epithelium during hypoxic conditions and in the modulation of cell migration and apoptosis to promote wound healing.<sup>35</sup>

Recently, it has been suggested that mucins are involved in the pathogenesis of cancer. Recent studies have indicated that MUC1 and 4 may modulate various pathways affecting cell growth.<sup>37</sup> MUC1 is known to be over-expressed in pancreatic and colon cancers, and in over 90 per cent of breast cancers.<sup>38</sup> MUC1 is recognised to have multiple effects on tumourigenesis. Firstly, it is known to act as a natural ligand of galectin-3 in human cancer cells, and the interaction between galectin-3 and cancer-associated mucin 1 enhances adhesion between cancer cells and endothelial cells, which may promote metastasis.<sup>39</sup> Secondly, as a transmembrane protein, its cytoplasmic tail binds with the ErbB family of growth factor receptor tyrosine kinases and potentiates ErbB-dependent signal transduction in the MUC1 transgenic breast cancer mouse model. MUC1 activation is thought to increase cell proliferation by activating extracellular signal-regulated kinases,<sup>37</sup> and it also plays a role in protection against oxidative stress induced cell death.<sup>37</sup>

One study found high levels of MUC1 expression in patients with laryngeal dysplasia and cancer.<sup>40</sup> High expression levels were also reported in 'control' patients' larynges; however, these were not healthy controls. The role of MUC1 in the context of laryngeal pathology remains unclear, and further research is required to characterise MUC1 expression in patients with pathology ranging from laryngopharyngeal reflux through to laryngeal cancer.

MUC4 is expressed on the epithelial surfaces of the oral cavity, eye, salivary glands and many other epithelial surfaces, where it acts to protect and lubricate. In a retrospective analysis of laryngeal cancer specimens, MUC4 was identified in nearly half the specimens.<sup>41</sup> In this study, the presence of MUC4 was associated with a trend towards better survival in patients with advanced stage, non-metastatic laryngeal cancer. In contrast, other research has shown that pancreatic, bile duct and lung cancers over-express MUC4, and that it is associated with a poorer prognosis in patients with these tumours.<sup>37</sup> Consequently, whilst there are proposed mechanisms for tumour progression in other cancers, the role of MUC4 in laryngeal cancer is still unclear.

## Discussion

Laryngopharyngeal reflux has made a significant impact on the otolaryngological literature over the last 20 years, although scepticism exists about the methods used for its diagnosis, and even whether the condition actually exists. The latter view is widely held by upper gastrointestinal surgeons, who have in general been disappointed with the clinical outcomes of antireflux surgery for patients with a diagnosis of laryngopharyngeal reflux.<sup>9</sup>

Undoubtedly, there exists a wide cluster of symptoms which are attributed to laryngopharyngeal reflux. However, many of these are not restricted to laryngopharyngeal reflux alone. There are a number of laryngological signs which are suggestive of rather than definitive for laryngopharyngeal reflux, and their detection is recognised as having high intra- and inter-observer variability.<sup>42</sup>

Furthermore, the reliability of double-probe 24-hour pH monitoring has also been questioned, and there is no consensus regarding probe placement or interpretation of results.<sup>43</sup>

Currently, a combination of history, examination and, typically, a successful trial of PPI treatment is considered proof of laryngopharyngeal reflux. However, failure of such a trial may suggest an inability to treat the noxious non-acid components of refluxate rather than the acid alone.<sup>42</sup>

When all of this uncertainty is combined with the lack of a definitive diagnostic test, clinicians are left with a conundrum about how best to manage these patients.

What is well accepted is that there is a link between gastroesophageal reflux disease and symptoms

suggestive of irritation and inflammation of the structures of the upper respiratory tract in some patients, and that some are 'cured' by antireflux surgery. The most logical explanation for these cases is that of damage caused by refluxate. Research has demonstrated that acid alone is not the only causative agent, with pepsin and bile acids also being contributors.<sup>12,16,44</sup> The actual mechanism for damage to the mucosal surface is not yet apparent. However, pepsin is being increasingly implicated, with research demonstrating its intracellular presence, and its ability to remain stable and to be reactivated at a pH which is not uncommon in the larynx.<sup>13,45</sup>

There have been many studies investigating the presence of, and resultant damage from, potential biomarkers of laryngopharyngeal reflux. The most notable of these affected by laryngopharyngeal reflux is CA III, a component of intrinsic mucosal protection in the larynx.<sup>12</sup> Mucins, which also provide mucosal protection, have altered expression in the larynx in the presence of laryngopharyngeal reflux. Such changes are significant, given the increasing amount of information emerging regarding these biomarkers' roles, not only in mucosal defence but also in tumour progression.

A definitive diagnostic technique for laryngopharyngeal reflux remains elusive. However, research implies that the occurrence of such reflux is indicated by biomarker changes and the presence of pepsin. Therefore, further research is required, in order to better define the clinical entity and spectrum of laryngopharyngeal reflux, and to identify specific patient subgroups (e.g. non-acid refluxers). In addition, as a definitive mechanism for mucosal damage is lacking (although probable causative agents have been identified), deeper understanding of this mechanism may enable the identification of better diagnostic biomarkers, as well facilitating therapeutic developments, particularly for patients unresponsive to PPIs.

## Conclusion

Laryngopharyngeal reflux disease is commonly diagnosed in ENT practice, in the presence of a cluster of non-specific laryngeal symptoms and signs.

The mechanism of laryngeal injury is uncertain, but is considered to be caused by a combination of acid and refluxate components, particularly pepsin. The latter is implicated particularly in 'non-acid' or 'weak-acid' reflux, and may remain in a stable, inactive form in the larynx, to be reactivated by further reflux episodes. Receptor-mediated uptake of pepsin may cause damage at an intracellular level.

Carbonic anhydrase isoenzyme III has also been implicated. Expression of this enzyme varies throughout the larynx in response to laryngopharyngeal reflux, with decreased expression in vocal fold epithelium but increased expression in the posterior commissure.

Laryngopharyngeal reflux is also associated with reduced expression of E-cadherin and mucin, either in response to reflux components (e.g. pepsin) or as a result of the inflammatory response to reflux.

Further studies are required to identify a definitive diagnostic tool for laryngopharyngeal reflux, and to determine the mechanism of mucosal injury, in order to enable therapeutic developments to help manage the full spectrum of laryngopharyngeal reflux pathology.

## Acknowledgements

This research was supported by the Garnett Passe and Rodney Williams Memorial Foundation, and by a Flinders University Faculty of Health Science Seeding Grant.

## References

- Dent J, El-Serag HB, Wallander M-A, Johansson S. Epidemiology of gastro-oesophageal reflux disease: a systematic review. *Gut* 2005;**54**:710–17
- Heading RC. Prevalence of upper gastrointestinal symptoms in the general population: a systematic review. *Scand J Gastroenterol Suppl* 1999;**231**:3–8
- Koufman JA. The otolaryngologic manifestations of gastroesophageal reflux disease (GERD): a clinical investigation of 225 patients using ambulatory 24-hour pH monitoring and an experimental investigation of the role of acid and pepsin in the development of laryngeal injury. *Laryngoscope* 1991;**101**(suppl 53): 1–78
- Koufman JA, Aviv JE, Casiano RR, Shaw GY. Laryngopharyngeal reflux: position statement of the Committee on Speech, Voice and Swallowing Disorders of the American Academy of Otolaryngology – Head and Neck Surgery. *Otolaryngol Head Neck Surg* 2002;**127**:32–5
- Kendall KA. Controversies in the diagnosis and management of laryngopharyngeal reflux disease. *Curr Opin Otolaryngol Head Neck Surg* 2006;**14**:113–15
- Joniau S, Bradshaw A, Esterman A, Carney AS. Reflux and laryngitis: a systematic review. *Otolaryngol Head Neck Surg* 2007;**136**:686–92
- Vaezi MF. We should learn from important negative results. *Laryngoscope* 2006;**116**:1718
- Karkos PD, Wilson JA. Empiric treatment of laryngopharyngeal reflux with proton pump inhibitors: a systematic review. *Laryngoscope* 2006;**116**:144–8
- Ratnasingham D, Irvine T, Thompson SK, Watson DI. Laparoscopic antireflux surgery in patients with throat symptoms: A word of caution. *World J Surg* 2011;**35**(2):342–8
- Feldman M, Friedman LS, Sleisenger MH, ed. *Sleisenger and Fordtran's Gastrointestinal and Liver Disease*, 7th edn. Philadelphia: Saunders, 2002
- Ylitalo R, Baugh A, Li W, Thibeault S. Effect of acid and pepsin on gene expression in laryngeal fibroblasts. *Ann Otol Rhinol Laryngol* 2004;**113**:866–71
- Johnston N, Knight J, Dettmar PW, Lively MO, Koufman J. Pepsin and carbonic anhydrase isoenzyme III as diagnostic markers for laryngopharyngeal reflux disease. *Laryngoscope* 2004;**114**:2129–34
- Samuels TL, Johnston N. Pepsin as a causal agent of inflammation during nonacidic reflux. *Otolaryngol Head Neck Surg* 2009;**141**:559–63
- Piper DW, Fenton BH. pH stability and activity curves of pepsin with special reference to their clinical importance. *Gut* 1965;**6**: 506–8
- Johnston N, Dettmar PW, Bishwokarma B, Lively MO, Koufman JA. Activity/stability of human pepsin: implications for reflux attributed laryngeal disease. *Laryngoscope* 2007;**117**:1036–9
- Johnston N, Wells CW, Blumin JH, Toohill RJ, Merati AL. Receptor-mediated uptake of pepsin by laryngeal epithelial cells. *Ann Otol Rhinol Laryngol* 2007;**116**:934–8
- Bollschweiler E, Wolfgarten E, Pütz B, Gutschow C, Holscher AH. Bile reflux into the stomach and esophagus for volunteers older than 40 years. *Digestion* 2005;**71**:63–4
- Tack J, Koek G, Demedts I, Sifrim D, Janssens J. Gastroesophageal reflux disease poorly responsive to single-dose proton pump inhibitors in patients without Barrett's esophagus: acid reflux, bile reflux or both? *Am J Gastroenterol* 2004;**99**:989–90
- Saskai CT, Marotta J, Hundal J, Chow J, Eisen RN. Bile-induced laryngitis: is there a basis of evidence. *Ann Otol Rhinol Laryngol* 2005;**114**:192–7
- Lillemoe KD, Johnson LF, Harmon JW. Role of the components of the gastroduodenal contents in experimental acid esophagitis. *Surgery* 1982;**92**:276–84
- Van Roon AH, Mayne GC, Wijnhoven BP, Watson DI, Leong MP, Neijman GE *et al.* Impact of gastro-esophageal reflux on mucin mRNA expression in the esophageal mucosa. *J Gastrointest Surg* 2008;**12**:1331–40
- Hirano T. Interleukin 6 in autoimmune and inflammatory diseases: a personal memoir. *Proc Jpn Acad Ser B Phys Biol Sci* 2010;**86**:717–30
- Thibeault SL, Smith ME, Peterson K, Ylitalo-Moller R. Gene expression changes of inflammatory mediators in posterior laryngitis due to laryngopharyngeal reflux and evolution with PPI treatment: A preliminary study. *Laryngoscope* 2007;**117**: 2050–6
- Oh DS, DeMeester SR, Vallbohmer D, Mori R, Kuramochi H, Hagen JA *et al.* Reduction of interleukin 8 gene expression in reflux esophagitis and Barretts' esophagus with antireflux surgery. *Arch Surg* 2007;**142**:554–60
- Waugh DJJ, Wilson C. The interleukin-8 pathway in cancer. *Clin Cancer Res* 2008;**14**:6735–41
- Tobey NA, Powell DW, Schreiner VJ, Orlando RC. Serosal bicarbonate protects against acid injury to rabbit esophagus. *Gastroenterology* 1989;**96**:1466–77
- Axford SE, Sharp N, Ross PE, Pearson JP, Dettmar PW, Panetti M *et al.* Cell biology of laryngeal epithelial defenses in health and disease: preliminary studies. *Ann Otol Rhinol Laryngol* 2001;**110**:1099–108
- Johnston N, Bulmer D, Gill GA, Panetti M, Ross PE, Pearson JP *et al.* Cell biology of laryngeal epithelial defenses in health and disease: further studies. *Ann Otol Rhinol Laryngol* 2003;**112**: 481–91
- Gill GA, Johnston N, Buda A, Pignatelli M, Pearson J, Dettmar PW *et al.* Laryngeal epithelial defenses against laryngopharyngeal reflux: investigations of E-cadherin, carbonic anhydrase isoenzyme III, and pepsin. *Ann Otol Rhinol Laryngol* 2005;**114**:913–21
- Christie KN, Thomson C, Xue L, Lucocq JM, Hopwood D. Carbonic anhydrase isoenzymes I, II, III, and IV are present in human esophageal epithelium. *J Histochem Cytochem* 1997;**45**:35–40
- Reichel O, Mayr D, Durst F, Berghaus A. E-cadherin but not  $\beta$ -catenin expression is decreased in laryngeal biopsies from patients with laryngopharyngeal reflux. *Eur Arch Otorhinolaryngol* 2008;**265**:937–42
- Kurtz KA, Hoffman HT, Zimmermann MB, Robinson RA. Decreased E-cadherin but not B-catenin expression is associated with vascular invasion and decreased survival in head and neck squamous carcinomas. *Otolaryngol Head Neck Surg* 2006;**134**: 142–6
- Samuels TL, Handler E, Syring ML, Pajewski NM, Blumin JH, Kerschner JE *et al.* Mucin gene expression in human laryngeal epithelia: effect of laryngopharyngeal reflux. *Ann Otol Rhinol Laryngol* 2008;**117**:688–95
- Namit Z, Sarosiek J, Marcinkiewicz M, Edmunds MC, McCallum RW. Declined human esophageal mucin secretion in patients with severe reflux esophagitis. *Dig Dis Sci* 1994;**39**:2523–9
- Ho SB, Dvorak LA, Moor RE, Jacobson AC, Frey MR, Corredor J *et al.* Cysteine-rich domains of muc3 intestinal mucin promote cell migration, inhibit apoptosis, and accelerate wound healing. *Gastroenterology* 2006;**131**:1501–17
- Louis NA, Hamilton KE, Canny G, Shekels LL, Ho SB, Colgan SP. Selective induction of mucin-3 by hypoxia in intestinal epithelia. *J Cell Biochem* 2006;**99**:1616–27
- Bafna S, Kaur S, Batra SK. Membrane-bound mucins: the mechanistic basis for alteration in the growth and survival of cancer cells. *Oncogene* 2010;**29**:2893–904

- 38 Gendler SJ. MUC1, the renaissance molecule. *J Mammary Gland Biol Neoplasia* 2001;**6**:330–53
- 39 Zhao Q, Guo X, Nash GB, Stone PC, Hilken J, Rhodes JM *et al.* Circulating galectin-3 promotes metastasis by modifying MUC1 localization on cancer cell surface. *Cancer Res* 2009;**69**:6799–806
- 40 Jeannon J-P, Stafford FW, Soames JV, Wilson J. Altered MUC1 and MUC2 glycoprotein expression in laryngeal cancer. *Otolaryngol Head Neck Surg* 2001;**124**:199–202
- 41 Paleri V, Pearson JP, Bulmer D, Jeannon J-P, Wight R, Wilson J. Expression of mucin gene products in laryngeal squamous cancer. *Otolaryngol Head Neck Surg* 2004;**131**: 84–8
- 42 Mahieu HF. Review article: the laryngological manifestations of reflux disease; why the scepticism? *Aliment Pharmacol Ther* 2007;**26**(suppl 2):17–24
- 43 Sato K, Umeno H, Chitose S, Nakashima T. Tetra-probe, 24-hour pH monitoring for laryngopharyngeal reflux: a technique for simultaneous study of hypopharynx, oesophagus and stomach. *J Laryngol Otol* 2009;**123**(suppl S31):117–22
- 44 Galli J, Calò L, Agostino S, Cadoni G, Sergi B, Cianci R *et al.* Bile reflux as possible risk factor in laryngopharyngeal inflammatory and neoplastic lesion. *Acta Otorhinolaryngol Ital* 2003;**23**:377–82
- 45 Samuels TL, Johnston N. Pepsin as a marker of extraesophageal reflux. *Ann Otol Rhinol Laryngol* 2010;**119**:203–8

Address for correspondence:  
Prof A.S. Carney,  
Flinders ENT, Department of Surgery,  
Room 3D204, Flinders Medical Centre,  
Bedford Park,  
South Australia 5042, Australia

Fax: +61 8 8204 3987  
E-mail: scarney@ent-surgery.com

---

Dr J Wood takes responsibility for the integrity of the content of the paper  
Competing interests: Professor A Simon Carney sits on the Arthrocare medical advisory board and receives honoraria for educational activities from Schering-Plough

---



## ENT morbidity at high altitude

B K PRASAD

*Department of ENT and Head and Neck Surgery, Command Hospital (Eastern Command (EC)), Kolkata, West Bengal, India*

### Abstract

**Background:** People suffer unique health problems in high altitude areas, due to such factors as elevation, aircraft ascent and descent, extreme cold, hypoxia, hypobaria, and low relative humidity. This study was conducted to evaluate ENT morbidity at high altitude.

**Methods:** Serving soldiers introduced to a high altitude environment who presented with various ENT symptoms were examined to identify ENT disease. In addition, patients undergoing hyperbaric chamber therapy, tracheostomy and treatment of cold injuries were also examined for ENT problems.

**Results:** The following were detected: 13 cases of otic barotrauma, 11 cases of sinus barotrauma, three cases of vertigo, six cases of pinna frostbite, three cases of barotrauma caused by hyperbaric chamber therapy, an unusually high incidence of epistaxis, and innumerable patients with high altitude pharyngitis.

**Conclusion:** Diseases of the ear, nose and throat contribute significantly to high altitude morbidity. In a military context, health education of troops is necessary to avoid such problems.

**Key words:** Altitude; Head and Neck; Barotrauma; Frostbite

### Introduction

By definition, any location which is 2700 m (9000 feet) or more above sea level is considered to be at high altitude. Many health problems hamper healthy human life at such elevations. However, the scientific literature lacks information on ENT morbidity associated with high altitudes.

This article presents a personal experience of ENT problems encountered at the highest multi-specialty hospital in the world, located at an altitude of 3600 m.

The atmospheric pressure at sea level is 1 Atmosphere. Above sea level, the atmospheric pressure decreases by 50 per cent for every increase of approximately 5400 m.<sup>1</sup> Thus, air has a lower density at high altitude because its component gases expand.

The response of gas to pressure changes also governs the behaviour of air in the middle ear and paranasal sinuses. During ascent, gas in the middle ear expands, whereas during descent the volume of gas decreases as the atmospheric pressure increases. During descent, the eustachian tube must be opened by swallowing movements to enable the middle-ear volume to be adjusted. If this mechanism fails or is delayed, increasing differential pressure acting on the soft nasopharyngeal end of the eustachian tube will close it. When this pressure becomes greater than that which can be generated by the tubal dilator muscles,

the eustachian tube becomes 'locked'. Thereafter, assuming descent continues, the pathological changes of otic barotrauma are inevitable. These changes affect the tympanic membrane and middle ear and are mainly vascular. They manifest clinically as tympanic membrane invagination, congestion along the handle of the malleus and in the attic, interstitial haemorrhage, middle-ear effusion, and tympanic membrane rupture.<sup>2</sup>

During descent, forceful coughing and sneezing, or production of an overpressure in the middle ear via performing the Valsalva manoeuvre, may cause sudden pressure transfer into the inner ear, causing inner-ear barotrauma.

Sinus barotrauma during descent is caused by obstruction of the ostium from the nasal side. If obstruction remains unrelieved and descent continues, the decreasing volume of air in the sinus exerts a suction effect on the lining mucosa, thus increasing ostium blockage. During ascent, the ostium may be blocked from within the sinus cavity. Symptoms are produced by unrelieved expansion of air contained in the closed bony sinus.<sup>3</sup>

The present study was conducted in the north Indian region of Ladakh, situated at high altitude in the state of Jammu and Kashmir. Ladakh shares its geographical boundary with Pakistan in the west and China in the east. The climate is extremely cold and dry, and the

terrain lacks vegetation. Such extreme weather causes severe crusting of the upper airway mucosa. This leads to an unusually high incidence of epistaxis and pharyngitis, tracheostomy problems, and chilblain and frostbite of the nose and pinna.

## Materials and methods

The present study was carried out from September 2005 to January 2008 in a garrison hospital located 3600 m above sea level. The ENT department evaluated deployed soldiers operating in various high altitude locations, from sparsely vegetated areas at 2700 m and cold deserts at 3000–4500 m to the icy heights of the Siachen glacier at 6900 m. All patients were male, of various ages. All soldiers had been medically examined prior to their induction into high altitude work and had been declared medically fit. Patients included soldiers new to high altitude service, those who had remained in the area for up to two years, and those returning to the area after lower altitude service.

Thirteen cases of otic barotrauma and 11 cases of sinus barotrauma were diagnosed. These cases were analysed for their presenting symptoms, clinical signs and predisposing factors. Treatment aimed to relieve pain and to maintain the ventilation of the middle ear and paranasal sinuses. Surgery was reserved for underlying nasal pathology and non-healing tympanic membrane perforations.

Three cases of sudden-onset vertigo during descent from altitude were evaluated. Otological monitoring comprised otoneurological testing and pure tone audiometry.

Twelve cases of high altitude cerebral oedema and nine cases of high altitude pulmonary oedema were treated in a hyperbaric chamber. As a precautionary measure, these patients were asked to evacuate their bladder and bowel and were taught the Valsalva manoeuvre. Nasal decongestant drops were instilled into the nose, drinking water was available inside the hyperbaric chamber to assist swallowing, and a nursing assistant stayed inside the chamber to monitor the patient's vital signs and oxygen saturation. The chamber was pressurised with air, and patients were given 100 per cent, pressurised oxygen via a face mask.

A total of 262 cases of epistaxis were evaluated with nasal endoscopic examination to determine their aetiology.

Forty-two cases of frostbite and 36 cases of chilblain were examined for head and neck involvement.

A large number of cases of chronic cough were seen in the hospital out-patient department. A careful clinical history excluded smoking, chronic infection, gastroesophageal reflux disease, angiotensin-converting enzyme medication, etc. Local causes in the throat were excluded by oropharyngeal examination and flexible fibre-optic laryngoscopy.

## Results and analysis

### *Otic barotrauma*

All 13 cases of otic barotrauma had no history of previous aural disease. Three patients were new to high altitude service, whereas 10 had returned to high altitude service after low altitude work. Nine cases were unilateral and four bilateral. All presented with acute earache, while six also complained of upper respiratory tract infection symptoms. Only three patients had tympanic membrane perforation on otoscopic examination at presentation (Table I).

The majority of patients recovered with conservative treatment (Table II). All 13 cases had identifiable predisposing factors. Surgery was undertaken to treat the underlying nasal causes in six cases, to drain middle-ear effusion in one case and to repair tympanic membrane perforation in another. One patient was lost to follow up (Table III).

### *Sinus barotrauma*

Of the 11 cases of sinus barotrauma, nine were unilateral and two bilateral. Two patients presented with frontal headache only. Nine patients had facial pain. All patients were assessed for predisposing factors, and most were treated surgically (Table IV).

### *Vertigo*

Three patients, all new to high altitude service, presented immediately upon arrival with acute-onset vertigo with no other aural symptoms. None of the three patients had nystagmus, and the fistula sign was negative. They were managed conservatively with bed rest, vasodilators, laxatives and otological monitoring. Clinical features resolved in three days.

### *Barotrauma related to hyperbaric chamber therapy*

Of the 21 patients treated in the hyperbaric chamber, three (14 per cent) suffered otic barotrauma.

### *Frostbite*

Of the 78 cases of cold injury, six were found to have frostbite of the pinna. Both ears were affected in two cases. Prolonged contact of the pinna with the flaps of a wet cap was found to be the cause in all cases. Patients were treated with rapid re-warming in water heated to 40–42°C, aloe vera cream application, oral

TABLE I  
OTIC BAROTRAUMA CASES: OTOSCOPIC FINDINGS  
ON PRESENTATION\*

Findings	Pts (n)
Unilat retracted, congested TM	8
Bilat retracted, congested TM	2
Perf R TM + retracted, congested L TM	2
Multiple TM perms	1

\*Within 24 hours of arrival. Pts = patients; unilat = unilateral; TM = tympanic membrane; bilat = bilateral; perf = perforation; R = right; L = left

TABLE II  
OTIC BAROTRAUMA PATIENTS: OTOSCOPIC FINDINGS  
AFTER MEDICAL TREATMENT

Findings	Pts (n)
Recovered*	7
Progression to OME	3
Persistent OME with conductive HL	1
Persistent bilat TM perf <sup>†</sup>	1
Multiple R TM perfs	1

\*Following active coryza treatment. <sup>†</sup>On 10th day; right tympanic membrane (TM) healed after four weeks. Pts = patients; OME = otitis media with effusion; HL = hearing loss; bilat = bilateral; perf = perforation; R = right

pentoxyphyllin 400 mg twice daily and oral aspirin 150 mg once daily.

#### High altitude pharyngitis

Sore throat and chronic cough were found to be nearly universal in any personnel who had spent some time at high altitude. These symptoms occurred without fever, chills, myalgia, lymphadenopathy, exudate, gastroesophageal reflux or any sign of infection.

#### Epistaxis

Of the 262 cases of epistaxis (comprising 8.7 per cent of total out-patient department attendance), 107 (41 per cent) were caused by nasal crusts and their dislodgement – a significant proportion (Table V). Commonly affected sites were Little's area, the septal spur and the anterior end of the inferior turbinate. All active bleeding was treated by chemical cautery.

## Discussion

#### Otic barotrauma

The development of otic barotrauma is dependent upon the rate of descent or the rate of ambient pressure increase, in contrast to the rate of middle-ear pressure increase. The latter is affected by the patency of the lumen and by the degree, frequency and duration of eustachian tube opening.<sup>4</sup> One episode of otic barotrauma can predispose an individual to further episodes, if the original predisposing factor persists, or if

TABLE III  
OTIC BAROTRAUMA PATIENTS: PREDISPOSING  
FACTORS AND TREATMENT

Predisposing factor	Pts (n)	Treatment
Coryza	7	Conservative
DNS	3	Septoplasty
Sinusitis	1	FESS
Allergic rhinitis	1	Later myringotomy & grommets
Allergic rhinitis	1	Topical nasal steroid spray
Allergic rhinitis	1	Myringoplasty*
Allergic rhinitis	1	Lost to follow up <sup>†</sup>

\*Successful. <sup>†</sup>Patient had multiple right tympanic membrane perforations. Pts = patients; DNS = deviated nasal septal; FESS = functional endoscopic sinus surgery

TABLE IV  
SINUS BAROTRAUMA PATIENTS: PREDISPOSING  
FACTORS AND TREATMENT

Predisposing factor	Pts (n)	Treatment
Coryza with DNS	4	Septoplasty
Sinusitis with DNS	4	Septoplasty & FESS
Allergic rhinitis	1	Topical steroid spray
Allergic rhinitis with polyps	2	FESS & topical steroid spray

Pts = patients; DNS = deviated nasal septum; FESS = functional endoscopic sinus surgery

sufficient time has not been allowed for the original lesion to recover before the individual is exposed to further pressure changes.<sup>5</sup>

#### Sinus barotrauma

Humans can voluntarily control the ostium of the eustachian tube by swallowing, yawning, gaping, or performing the Valsalva or Frenzel manoeuvre, but have no such control over the ostia of sinuses. Sinus ostia may be occluded by a plug of mucus, mucosal oedema, polyp or mass. This obstruction is often valvular in nature, so that air passes easily in one direction only. Coryza, vasomotor rhinitis, allergic rhinitis and rhinosinusitis can also cause oedema of the nasal mucosa, which predisposes to sinus barotrauma. Nasal trauma and nasal septum deviations can also act in the same way.

Described in aviators by King in 1965, sinus barotrauma most commonly involves the frontal sinus.<sup>6</sup> In Fagan and colleagues' series of affected patients, there was a prior history of previous paranasal sinus barotrauma in one-third, and a history of recent upper respiratory tract infection or chronic nasal and sinus inflammatory disease in one-half.<sup>7</sup> None of these cases required surgery.

#### Inner-ear barotrauma

Goodhill stated in 1971 that an increase in intracranial pressure from coughing, sneezing or straining may cause sudden, spontaneous rupture of the round

TABLE V  
EPISTAXIS PATIENTS: AETIOLOGY

Aetiology	Pts	
	n	%
Crusts	107	41
Infection	78	30
Trauma	21	8
Hypertension	13	5
Atrophic rhinitis	6	2
Tumour	2	0.8
Rhinosporidiosis	2	0.8
DIC	1	0.4
Idiopathic	32	12
Total	262	100

Pts = patients; DIC = disseminated intravascular coagulation

window.<sup>8</sup> This same author also believed that a sudden change in middle-ear pressure may have the same effect during flight. Jones termed this 'pressure vertigo', and Lundgren 'alternobaric vertigo'.<sup>9,10</sup> Afflicted patients present with sudden deafness, tinnitus, and intense, short-lasting vertigo or ataxia. Otorhinolaryngological examination will reveal nystagmus and sensorineural hearing loss. Findings of decompression sickness, such as joint pain or central nervous system symptoms, will be conspicuously lacking.

It is postulated that this overpressure in the middle ear is not transmitted equally to the fluid system of the inner ear by the round and oval windows at the same time, and there may also be a mismatch between the left and the right ear.

However, in the present study none of the three vertigo cases had tinnitus or deafness. In the absence of nystagmus and the fistula sign, it was presumed that vertigo could have resulted from temporary vaso-spasm due to extremely cold weather.

#### *Hyperbaric chamber therapy*

At sea level, the atmospheric pressure is 1 Atmosphere; at 3600 m it is 0.6 Atmospheres. During hyperbaric chamber therapy, the rate of increase or decrease of pressure inside the chamber should not exceed 0.01 Atmospheres per minute. Therefore, in the present study it took 35 minutes to attain a pressure of 1 Atmosphere; this was then maintained for 6 hours. As patients breathe in oxygen under pressure, middle-ear ventilation is essential, otherwise otic barotrauma is inevitable.

Karhatay *et al.* assessed the development of otic barotrauma following hyperbaric chamber therapy, and reported a 66.7 per cent incidence, compared with incidences of 8–82 per cent published elsewhere.<sup>11</sup> In the present study, 14 per cent of patients receiving hyperbaric chamber treatment developed otic barotrauma.

#### *Tracheostomy problems*

On the plains of India, the relative humidity varies between 60 and 99 per cent, whereas in Ladakh it ranges from 10 to 50 per cent, with an average of just 30 per cent. After tracheostomy, the tracheal mucosa has to be kept moist and humidified, otherwise there will be crusting, with the possibility of subsequent blockage and asphyxia. At high altitudes, saline nebulisation at frequent intervals keeps the respiratory tract moist, and early decannulation is advisable.

#### *Epistaxis*

Dry inspired air invariably causes crusting in the nose. As a result, epistaxis is a very common ENT problem at high altitude. Almost 100 per cent of the general population will experience minor nasal bleeding at some stage, but most will not seek ENT consultation. In Ladakh, as part of their health education, troops are advised to instil saline or glycerine nasal drops to keep the nasal mucosa moist and prevent crusting.

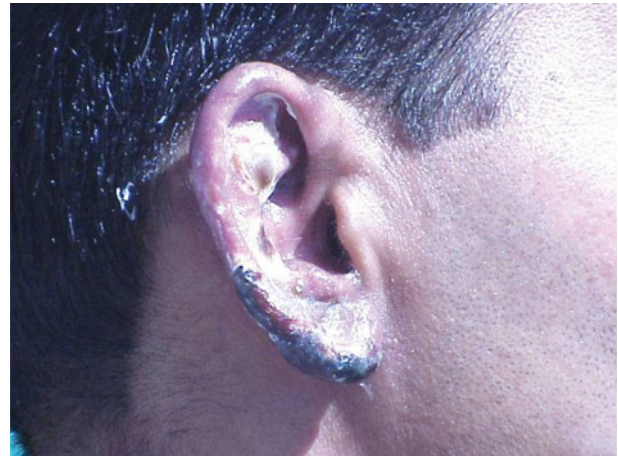

FIG. 1  
Frostbite of the pinna.

#### *Cold injuries*

The present study included patients exposed to temperatures varying from  $-5$  to  $-50^{\circ}\text{C}$ . Cold injuries result from the inability to properly protect oneself from exposure to cold. These injuries can be of two types: (1) generalised (i.e. hypothermia) and (2) localised (i.e. chilblain and frostbite).

Chilblain comprises local swelling and tenderness after exposure to cold and moisture for 3–6 hours, and has little or no residual consequence. In contrast, frostbite involves the formation of ice crystals in tissues, along with denaturation of lipid-protein complexes, which may be followed by thrombosis, ischaemia and gangrene. The severity of frostbite depends on the temperature, length of exposure, wind chill factor and moisture level.

Cold injuries commonly affect the fingers and toes but can also affect the nose and ears. A common site in the head and neck region is the pinna (Figure 1).

#### *High altitude pharyngitis*

The term 'high altitude pharyngitis' is suggested because of the present study's finding of a high incidence of chronic cough in individuals living in a high altitude location, which could not be attributed to any

TABLE VI  
ENT MORBIDITY AT HIGH ALTITUDE: DISTRIBUTION\*

Diagnosis	Pts (n)
High altitude pulmonary oedema	91
High altitude cerebral oedema	12
Acute mountain sickness	113
Frostbite	42
Chilblain	36
Deep vein thrombosis	23
Otic barotrauma	13
Sinus barotrauma	11
Vertigo	3
Epistaxis	262

\*Patients treated September 2005 to January 2008.

other cause. Hypoxia and hypobaria at high altitude demand extra breathing effort. The increase in ventilation forces obligate mouth-breathing, bypassing the warming and moisturising action of the nasal mucous membrane and sinuses. It is suggested that the movement of large amounts of cold, dry air across the pharyngeal mucosa causes marked dehydration, irritation and pain, similar to pharyngitis. Vasomotor rhinitis, which is quite common at cold temperatures, aggravates this condition by necessitating mouth-breathing during sleep.

- **This study documented ENT morbidity in military personnel serving at high altitude**
- **Factors producing morbidity at high altitude include hypoxia, hypobaria, extreme cold, low humidity and hypercoagulability**
- **Particular ENT problems include frostbite, epistaxis, and barotrauma of the ear and sinuses**
- **Many high altitude ENT problems are preventable**

Cases of high altitude pharyngitis were successfully treated by steam inhalation, forced hydration, throat lozenges and saline nasal drops.

### Conclusion

Analysis of ENT morbidity encountered at high altitude reveals three types of disease: (1) life-threatening diseases such as high altitude pulmonary oedema, high altitude cerebral oedema and deep vein thrombosis; (2) limb-threatening diseases such as chilblain and frostbite; and (3) other diseases, including the ENT ailments detailed above (Table VI). Epistaxis is so common that it is accepted as part of life, until one suffers a severe case. Pharyngitis is bothersome but does not prevent soldiers from carrying out their duties. Barotrauma has not gained a place amongst the notifiable diseases of high altitude, not only because of less awareness of this problem, but also because the majority of cases go unreported. In Ladakh, the medical treatment given by Regimental

Medical Officers to soldiers suffering barotrauma is simple yet effective, and recovery is good with few residual consequences; hence, referral to an ENT specialist is infrequent.

These ENT problems are preventable if those at risk are aware. Hence, individuals living and working in high altitude areas should be educated about the possible ENT problems they face, and how to avoid them.

### References

- 1 Farmer JC, Gillespie CA. Exposure to aerospace, diving and compressed gases. In: Alberti PW, Ruben RJ, eds. *Otologic Medicine and Surgery*. New York: Churchill Livingstone, 1988;2:1753–802
- 2 Edward C, Freeman P, Thomas R, Tonkin J, Blackwood FA. *Otological Aspects of Diving*. Sydney: Australian Medical Publishing, 1973
- 3 Benson AJ, King PF. Physiology of ear and nasal sinuses in the aerospace environment. In: Wright D, ed. *Scott-Brown's Otolaryngology Basic Sciences*, 5th edn. London: Butterworths, 1987;1:190–1
- 4 Dickson EDD, King PF. *The Incidence of Barotraumas in Present Day Service Flying*. Flying Personnel Research Committee Report No 881. London: Air Ministry, 1954
- 5 Miller GR Jr. ET function in normal and diseased ears. *Arch Otolaryngol Head Neck Surg* 1965;81:41–8
- 6 King PF. Sinus barotrauma. In: Gilles JA, ed. *A Textbook of Aviation Physiology*. London: Pergamon, 1965;112–21
- 7 Fagan P, Mckensie B, Edmonds C. Sinus barotraumas in divers. *Ann Otol Rhinol Laryngol* 1976;85:61–4
- 8 Goodhill V. Sudden deafness and round window rupture. *Laryngoscope* 1971;81:1462–74
- 9 Jones GM. *Inner Ear Barotrauma in Service Flying*. Flying Personnel Committee Report No 1021. London: Air Ministry, 1957
- 10 Lundgren CEG. Alternobaric vertigo – a diving hazard. *BMJ* 1965;2:511–13
- 11 Karhatay S, Yilmaz YF, Birkent H, Ay H, Satar B. Middle ear barotraumas with hyperbaric oxygen therapy: incidence and the predictive value of the nine step inflation/deflation test and otoscopy. *Ear Nose Throat J* 2008;87:684–8

Address for correspondence:

Lt Col (Dr) B K Prasad,  
Department of ENT and Head and Neck Surgery,  
Command Hospital (EC), Alipore Road,  
Kolkata 700027, West Bengal, India

Email: bipin\_rupa@rediffmail.com

---

Dr B K Prasad takes responsibility for the integrity of the content of the paper

Competing interests: None declared

---

# Foreign body aspiration and language spoken at home: 10-year review

S CHOROOMI, J CUROTTA

*Department of Ear, Nose and Throat Surgery, The Children's Hospital at Westmead, New South Wales, Australia*

## Abstract

**Objective:** To review foreign body aspiration cases encountered over a 10-year period in a tertiary paediatric hospital, and to assess correlation between foreign body type and language spoken at home.

**Study design and method:** Retrospective chart review of all children undergoing direct laryngobronchoscopy for foreign body aspiration over a 10-year period. Age, sex, foreign body type, complications, hospital stay and home language were analysed.

**Results:** At direct laryngobronchoscopy, 132 children had foreign body aspiration (male:female ratio 1.31:1; mean age 32 months (2.67 years)). Mean hospital stay was 2.0 days. Foreign bodies most commonly comprised food matter (53/132; 40.1 per cent), followed by non-food matter (44/132; 33.33 per cent), a negative endoscopy (11/132; 8.33 per cent) and unknown composition (24/132; 18.2 per cent). Most parents spoke English (92/132, 69.7 per cent; *vs* non-English-speaking 40/132, 30.3 per cent), but non-English-speaking patients had disproportionately more food foreign bodies, and significantly more nut aspirations ( $p = 0.0065$ ). Results constitute level 2b evidence.

**Conclusion:** Patients from non-English speaking backgrounds had a significantly higher incidence of food (particularly nut) aspiration. Awareness-raising and public education is needed in relevant communities to prevent certain foods, particularly nuts, being given to children too young to chew and swallow them adequately.

**Key words:** Foreign Bodies; Paediatrics; Trachea; Bronchi; Language; Culture

## Introduction

Children have a higher incidence of foreign body aspiration than adults. Such aspiration can cause significant morbidity and mortality.<sup>1</sup>

In any children at the age of exploring their surroundings with their mouths, foreign body aspiration should always be a differential diagnosis for paediatric stridor and respiratory distress.<sup>1</sup> Although the majority of patients with foreign body aspiration present within a day of the incident,<sup>2</sup> the diagnosis of foreign body aspiration can be delayed. Scoring systems have been developed to aid diagnosis and thus facilitate early removal.<sup>3</sup> Although foreign body aspiration is an uncommon cause of paediatric laryngotracheal obstruction, accounting for approximately 5 per cent of cases,<sup>4</sup> delayed diagnosis can lead acutely to death, and in the longer term to chronic pulmonary problems such as bronchiectasis and lung abscess.<sup>5</sup> In some cases, foreign body aspiration may be sub-clinical, as the foreign body may not cause complete obstruction but may instead give rise to inflammatory and granulation tissue, causing later symptoms.<sup>6</sup>

Given that a variety of foods may be aspirated, the cultural influences on individual families may have an effect on the type of foreign body aspiration encountered. This study aimed to assess the correlation between the type and frequency of foreign body aspiration, and the language spoken in the patient's home.

The potential exists for public education regarding withholding certain foods until children are mature enough to chew and swallow adequately. This is particularly important in certain ethnic groups, which may unknowingly encourage children to eat foods which are commonly aspirated.

## Materials and methods

A retrospective medical record review was performed for all children coded for admission with suspected foreign body aspiration over a 10-year period (2000–2009). All children were admitted to the Children's Hospital at Westmead, Sydney, New South Wales, Australia, a tertiary paediatric referral hospital servicing both local and state-wide patients. The local area is diversely multicultural, with a broad range of cultures and languages spoken.

The information obtained from the medical record included patient age and sex, type of foreign body found on direct laryngobronchoscopy, length of hospital stay, complications (if any) and, importantly for this study, the language spoken by the patient's parents at home.

Data on foreign body type were obtained from each patient's surgical record. The language spoken at home was obtained from the carer's response when asked at the hospital triage desk, 'What is the main language spoken at home?'

Statistical analysis comparing nut foreign body aspirations in English versus non-English speakers was performed using a two-way contingency table, and tested for significance using Fisher's exact test (the appropriate test for the sample size).

## Results and analysis

We reviewed 184 patient medical records coded for 'foreign body in airway/larynx/bronchus'. Of these, 52 were excluded as the patient had been miscoded and did not have a true foreign body aspiration, but, rather, other conditions (e.g. aspiration of vomitus or other causes of paediatric stridor). This left a series of 132 patients encountered over a 10-year period with suspected foreign body, who went on to direct laryngobronchoscopy.

The mean age of these foreign body aspiration patients was 32 months (2.67 years); the range is depicted in Figure 1. The incidence of foreign body aspiration was higher in boys (75/132) than girls (57/132), giving a male:female ratio of 1.31:1. The average number of bed days required per case was 2.0 days (range 1 to 28 days).

Two patients died, both of whom had arrested on arrival at the emergency department and were unable to be resuscitated. These children had a clear history of choking on a foreign body (one child had aspirated a metal screw, the other a piece of apple) and developing sudden-onset acute respiratory distress.

Two patients had foreign bodies which could not be removed by direct laryngobronchoscopy, requiring a thoracotomy.

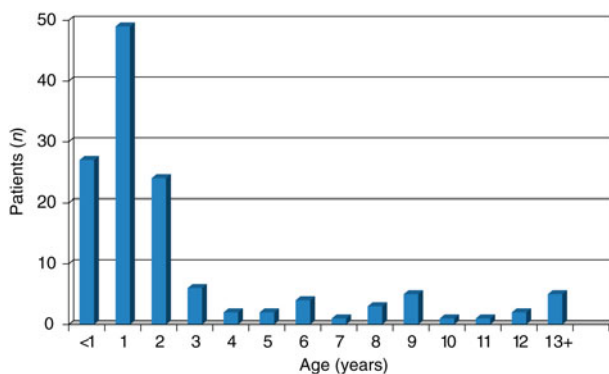


FIG. 1

Age distribution of patients with foreign body aspiration.

## Foreign body types

Types of foreign bodies are summarised in Tables I and II. Foreign bodies were broadly categorised as food, non-food, a negative endoscopy (i.e. no foreign body found on direct laryngobronchoscopy) or unknown. The latter category was attributed when a foreign body was removed at direct laryngobronchoscopy but no clear documentation of its composition could be identified from the medical or surgical records.

Food matter accounted for the largest proportion of aspirated foreign bodies (53/132, 40.1 per cent), followed by non-food matter (44/132, 33.33 per cent). Negative endoscopies made up 11 of the 132 cases (8.33 per cent). The nature of the foreign body was unknown in 24 of the 132 cases (18.2 per cent) (see Figure 2).

Nuts (including all types of nuts and seeds) made up the biggest proportion of food foreign bodies, accounting for 31 of the 53 such cases (58.5 per cent). Peanuts were the commonest nut involved (accounting for 54.8 per cent of nut aspiration cases). This is in keeping with other findings; one study reported that peanuts accounted for the greatest proportion (40.7 per cent) of aspirated foreign body cases.<sup>1</sup> The shape and texture of peanuts makes them easily aspirated by children. Furthermore, the arachis oil they contain may cause airway inflammation and granulation tissue formation.

Three patients had aspiration of Christmas decorations (all these cases occurred between 28 November and 22 December). Two of these patients came from an English-speaking home and one from a Gujarati-speaking home. Figure 3 depicts intra-operative findings.

Aspirated non-food foreign bodies comprised a broad range of common small household items, including pins, small toys, beads and coins. All these objects

TABLE I  
FOOD FOREIGN BODY TYPES

Type	Pts (n)
Peanut	17
Almonds	6
Carrot	5
Apple	3
Food matter	3
Chicken	3
Sunflower seeds	2
Walnut	2
Cashew nut	2
Bone	1
Chickpea	1
Grape	1
Meat	1
Milk*	1
Nut (unknown)	1
Olive	1
Pistachio nut	1
Popcorn	1

\*Fluid requiring suctioning. Pts = patients

TABLE II  
NON-FOOD FOREIGN BODY TYPES

Type	Pts (n)
Needle or pin	9
Plastic piece	5
Dirt or debris	4
Bead	4
Coin	4
Christmas decoration	3
Wood piece	2
Metal piece	2
Pen top	2
Lego	2
Crayon	1
Paper	1
Paperclip	1
Pearl	1
Screw	1
Stone	1
Straw	1

Pts = patients

are frequently within easy reach of children, and the risk of aspiration is to a large extent unavoidable.

#### Language spoken at home

The languages spoken in the homes of children with foreign body aspiration are summarised in Table III.

Patients from English-speaking homes constituted the majority (92/132; 69.7 per cent). Such patients

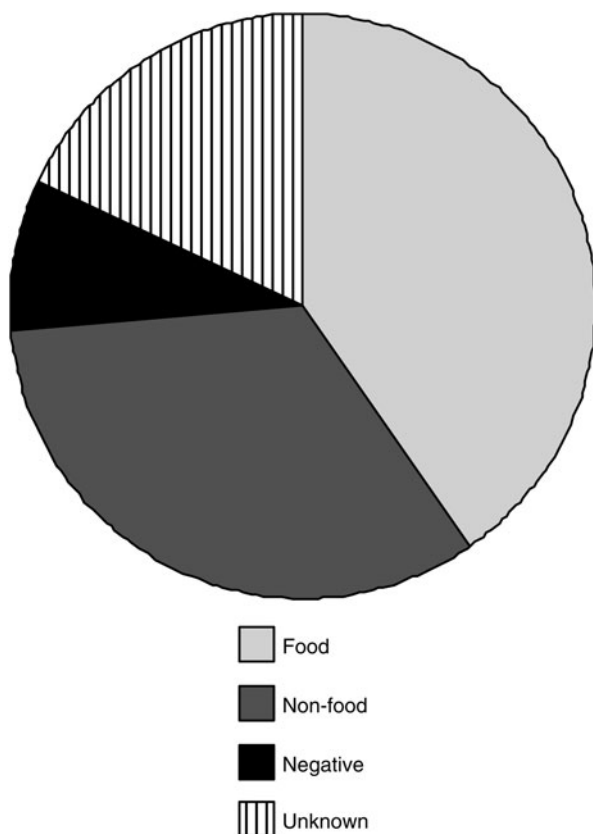


FIG. 2

Types of foreign bodies aspirated, and relative proportions.  
Negative = no foreign body on endoscopy

accounted for 58 per cent of food aspiration cases and 48.4 per cent of nut aspiration cases.

Patients from non-English-speaking homes accounted for 30.3 per cent of the patient series. These patients accounted for 42 per cent of food aspiration cases and 51.6 per cent of nut aspiration cases (see Table IV).

#### Discussion

Our findings are comparable with those of other studies assessing paediatric foreign body aspiration.

In our patients, the mean age for foreign body aspiration was 32 months (2.67 years); this is similar to other reported results, which range from 25.5<sup>7</sup> to 38.1 months.<sup>1</sup> In one study assessing all children presenting with signs of laryngotracheal obstruction (irrespective of cause), the mean patient age was 28 months (2.3 years).<sup>4</sup>

Our male:female ratio was 1.31:1, which is lower than figures reported by other studies, e.g. 2.3:1<sup>7</sup> and 1.8:1<sup>1</sup>.

Our patients required an average of 2.0 bed days, similar to the 1.97 days (range 1–26 days) reported by another study.<sup>1</sup>

In our study, the commonest foreign body type was food, accounting for 40.1 per cent of cases. Other studies also observed food to be the commonest foreign body type; one study found that up to 85 per cent of foreign bodies were organic in nature, upon direct laryngobronchoscopy.<sup>8</sup>

The negative endoscopy rate in our study (8.33 per cent) was lower than that reported in a recent study of 207 patients (28.2 per cent).<sup>7</sup>

- Foreign body aspiration should always be considered in the differential diagnosis of paediatric stridor and airway obstruction
- Aspirated foreign bodies are more commonly food than non-food items
- Direct laryngobronchoscopy is often required, if only to exclude foreign body aspiration
- Cultural influences play a large role in foods given to children, and therefore influence the risk of foreign body aspiration
- In this study, a non-English-speaking home background was a significant risk factor for food foreign body aspiration, particularly nut aspiration

We encountered two deaths over the 10-year study period, demonstrating that foreign body aspiration is potentially lethal and can occur with common small household objects or food items.

To a certain extent, food foreign body aspiration can be averted if inappropriate foods are avoided before children have a sufficiently mature swallow mechanism. Many of the food items in Table I should be



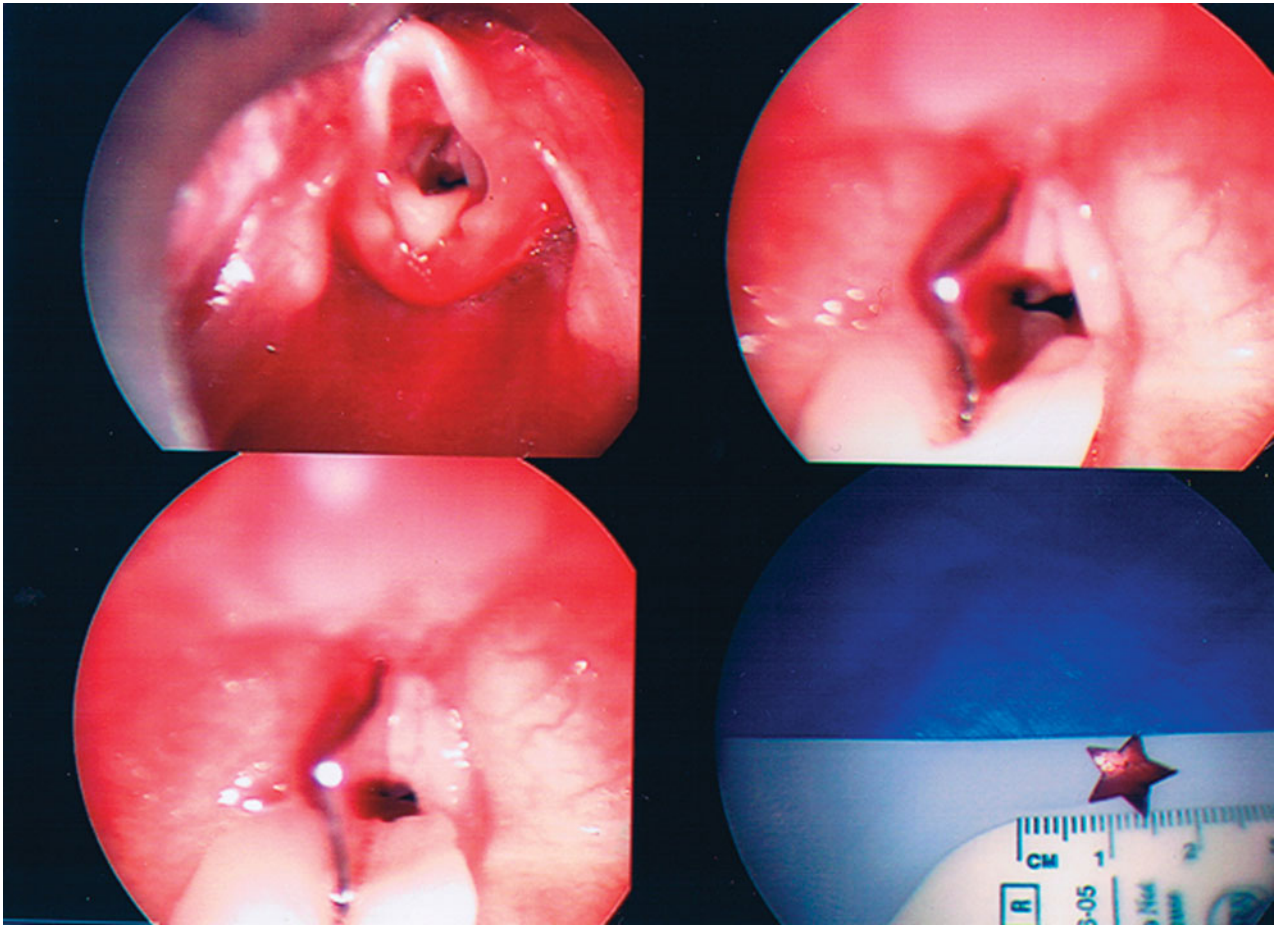


FIG. 3

Intra-operative laryngobronchoscopic views of aspirated Christmas decoration.

avoided until the child is five to six years of age, and should certainly not be given at the age of two to three years, the average age of our patients.

From our findings, we were able to establish a statistically significant link between certain types of foreign body aspiration and the language spoken in the patient's home ( $p = 0.0065$ ). Food foreign body aspiration has a higher incidence in patients from

non-English-speaking backgrounds. In particular, nut aspiration has a higher incidence in such patients, particularly those with Arabic-speaking parents.

Efforts to prevent food foreign body aspiration could involve raising parents' awareness that certain foods, particularly nuts, should be avoided until their child is mature enough to chew and swallow adequately. Parents should also avoid solid foods such as carrot and apple, which need to be adequately chewed and have a tendency to slip, until the child is mature enough to chew well. On this point, cultural influences

TABLE III  
LANGUAGE SPOKEN AT HOME

Language	Pts (n)
English	92
Arabic	17
Hindi	4
Turkish	4
Korean	2
Macadonian	2
Tamil	2
Urdu	2
Vietnamese	2
Assyrian	1
Cantonese	1
Gujarati	1
Mandarin	1
Spanish	1

Pts = patients

TABLE IV  
PATIENT DISTRIBUTION BY HOME LANGUAGE AND FOREIGN BODY TYPE

Language	Pts with nut aspiration		Total pts (%)
	n	%	
English	15	48.4	69.7
Not English	16	51.6	30.3
Arabic	7	22.6	12.8

There was a statistically significant association between non-English-speaking background and nut foreign body aspiration; two-tailed  $p = 0.0065$ .

are important. The incidence of foreign body aspiration could be significantly decreased if family doctors and paediatricians took on the role of informing and educating parents about the need to avoid feeding their child certain foods, especially nuts, until the age of five to six years. A local doctor who speaks the parents' language and who is aware of their culture and common foods may be more able to motivate parents to avoid feeding their child foods that could potentially be aspirated. We would therefore encourage targeted community awareness initiatives in order to publicise the dangers to which young children are exposed by inappropriately early presentation of hard foods.

Other studies have demonstrated cultural influences on both poison ingestion and foreign body aspiration. In Israel, children from Arab communities ingested poisonous pesticides more commonly than non-Arabic children.<sup>9</sup> In Malaysia, weaning children to soft food mixed with cooked items such as fish and prawns (which may contain hard shells and bones) or uncooked leafy vegetables resulted in incidents of aspiration.<sup>10</sup> In this study, the language spoken at home was considered an indicator of cultural practice.

In the current study, we accept that accurate assessment of the language(s) spoken at home may be difficult. Firstly, the triage clerk may not ask the question, depending on the urgency of triage, and may document 'English'. Secondly, many parents in the region may be bilingual, and speak their native language at home but state at the hospital that they speak English. Finally, although parents may be English speakers, they may still have strong cultural links and beliefs which affect the foods they give to their child, irrespective of the language they speak at home. Despite the observed statistically significant association between nut foreign body aspiration and language, it is still likely that this study underestimated the effect of a non-English-speaking background on food foreign body aspiration.

## Conclusion

Food foreign body aspiration, particularly of nuts, occurs significantly more in non-English-speaking

communities. Thus, language and cultural factors should be considered risk factors when assessing a child with airway obstruction. There is considerable potential for raising community awareness about this potentially fatal problem.

## References

- 1 Tan H, Brown K, McGill T, Kenna M, Lund D, Healy G. Airway foreign bodies (FB): a 10-year review. *Int J Pediatr Otorhinolaryngol* 2000;**56**:91–9
- 2 Aydogan L, Tuncer U, Soylu L, Kiroglu M, Ozsahinoglu C. Rigid bronchoscopy for the suspicion of foreign body in the airway. *Int J Pediatr Otorhinolaryngol* 2006;**70**:823–8
- 3 Kadmon G, Stern Y, Bron-Harlev E, Nahum E, Battat E, Schonfeld T. Computerized scoring system for the diagnosis of foreign body aspiration in children. *Ann Otol Rhinol Laryngol* 2008 Nov;**117**(11):839–43
- 4 Bent J. Pediatric laryngotracheal obstruction: current perspectives on stridor. *Laryngoscope* 2006;**116**:1059–70
- 5 Karakoc F, Cakir E, Ersu R, Uyan Z, Colak B, Karadag B *et al.* Late diagnosis of foreign body aspiration in children with chronic respiratory symptoms. *Int J Pediatr Otorhinolaryngol* 2007;**71**:241–6
- 6 Mathiasen R, Cruz R. Asymptomatic near-total airway obstruction by a cylindrical tracheal foreign body. *Laryngoscope* 2005;**115**:274–7
- 7 Kiyani G, Gocmen B, Tugtepe H, Karakoc F, Dagli E, Dagli T. Foreign body aspiration in children: the value of diagnostic criteria. *Int J Pediatr Otorhinolaryngol* 2009;**73**:963–7
- 8 Chung M, Jeong H, Ahn K, Park S, Cho J, Son Y *et al.* Pulmonary recovery after rigid bronchoscopic retrieval of airway foreign body. *Laryngoscope* 2007;**117**:303–7
- 9 Uziel Y, Adler A, Aharonowitz G, Franco S, Fainmnesser P, Wolach B. Unintentional childhood poisoning in the Sharon area in Israel: a prospective 5-year study. *Pediatr Emerg Care* 2005;**21**:248–51
- 10 Indudharan R, Ram S, Didek D. Tracheobronchial foreign bodies in relation to feeding practices in young children. *J Accid Emerg Med* 1997;**14**:341–3

Address for correspondence:

Dr S Choroomi, ENT Surgery Department,  
The Children's Hospital at Westmead, Locked Bag 4001,  
Westmead 2145 NSW,  
Australia

Fax: +61 2 9519 9926

E-mail: s\_choroomi@hotmail.com

---

Dr S Choroomi takes responsibility for the integrity  
of the content of the paper

Competing interests: None declared

---

# Ring versus ‘Mercedes-Benz’ cartilage-perichondrium graft tympanoplasty in management of pars tensa cholesteatoma

O A ALBIRMAWY

Otolaryngology Department, Tanta University Hospital, Egypt

## Abstract

**Objective:** To compare anatomical and audiological outcomes of ring versus ‘Mercedes-Benz’ cartilage-perichondrium graft tympanoplasty in patients with pars tensa cholesteatoma.

**Study design:** Prospective clinical study.

**Setting:** Otolaryngology department, Tanta University Hospital, Egypt.

**Patients and methods:** Over three years, 60 ears in 60 patients underwent surgery for either sinus or tensa retraction cholesteatoma, reconstructed using either a ring-shaped (30 ears) or Mercedes-Benz symbol shaped (30 ears) cartilage-perichondrium graft, with at least two years’ follow up. Post-operative drum perforation and retraction, cholesteatoma residue and recurrence, middle-ear effusion, and hearing acuity were monitored.

**Results:** Anatomical outcomes were equivalent in both groups, but slightly better in the Mercedes group. Hearing improved significantly in both groups (pre- vs post-operative results), but significantly more so in the ring group. Within-group hearing outcomes were unaffected by cholesteatoma type or tympanoplasty type.

**Conclusion:** The Mercedes-Benz technique may be superior to the ring technique in preventing neodrum retraction. However, the ring graft technique had better hearing outcomes, perhaps due to its more physiological design.

**Key words:** Cholesteatoma; Tympanoplasty; Graft; Cartilage

## Introduction

Cholesteatomas are one of the most important and controversial pathological conditions encountered during middle-ear surgery. Based on otoscopic appearances, they can be classified as attic cholesteatomas (developing from the Shrapnell membrane) or tensa cholesteatomas (originating in the pars tensa). Tensa cholesteatomas are further subdivided into sinus cholesteatoma (developing from posterosuperior retraction and spreading toward the stapes and the tympanic sinus) or tensa retraction cholesteatoma (involving retraction of the entire pars tensa, and extending into the hypotympanum, tubal orifice and posterior tympanum).<sup>1</sup>

Important aims of pars tensa cholesteatoma surgery are: complete cholesteatoma removal, with no residual disease; restoration of normal ear anatomy, in order to prevent recurrence; and improvement in quality of life (i.e. good hearing and no cavity problems). The ideal technique would allow the surgeon to achieve all these aims.<sup>2</sup>

Cartilage grafting has been used for eardrum reconstruction for decades, at various different otological

centres. The number of reports on clinical outcomes has increased in the last five to 10 years.<sup>3</sup> Cartilage confers increased stiffness to the reconstructed drum, and may be modified and shaped more readily depending upon the surgeon’s requirements. Thus, post-operative retraction or perforation can be avoided, and satisfactory functional hearing results ensured.<sup>4</sup>

The present study aimed to compare the anatomical and audiological outcomes of ring-shaped modified cartilage-perichondrium graft tympanoplasty with those of tympanoplasty using a Mercedes-Benz symbol shaped cartilage-perichondrium composite plate, after one-stage surgery, in patients with pars tensa cholesteatoma.<sup>5–8</sup>

## Patients and methods

### Patients

The study comprised a prospective, double-arm study of 60 ears in 60 patients operated upon for middle-ear pars tensa cholesteatoma at the otolaryngology

department of Tanta University Hospital, Egypt, over a three-year period (2005 to 2008).

The purpose, principles and potential complications of surgery were explained to the patients, or their parents, and accepted by them.

The patients were divided into two surgical groups. Thirty ears were grafted with a ring-shaped modified cartilage-perichondrium graft, while the other 30 ears were grafted with a cartilage-perichondrium composite plate fashioned in the shape of the Mercedes-Benz symbol. The choice between ring or 'Mercedes-Benz' technique was made at random.

Indications for surgery included sinus or tensa retraction cholesteatoma not extending to the attic, antrum or mastoid process.

The following patients were excluded from the study: any cases of previous ear surgery (except for tympanostomy), sensorineural hearing impairment, or intracranial or extracranial complications, and any patients who were not followed up for at least two years.

#### *Surgical technique*

All operations were performed by the same surgeon, under general anaesthesia.

A piece of tragal cartilage larger than the final graft size was harvested, with the perichondrium left attached to one side. The graft was trimmed to the required circular shape and size (9–12 mm diameter) and kept hydrated in saline, prior to being fashioned into a ring or Mercedes-Benz shape.

The mastoid cortex was exposed via a postauricular incision, the tympanomeatal flap raised and reflected anteriorly, the middle ear inspected, the cholesteatoma identified and the ossicular chain visualised. Because of radiological evidence of opacification of mastoid air cells, all patients underwent an intact canal wall mastoidectomy. Using a small cutting burr, the bone of the ear canal was widened from lateral to medial, until the pinkish colour of the mastoid air cell mucosa was encountered. Posterosuperomedial bone removal allowed early identification of the chorda tympani nerve, which was sectioned at its junction with the facial nerve, followed by posteroinferior drilling to identify the anterior surface of the vertical segment of the facial nerve canal.

The cholesteatoma was then removed using a minimally invasive technique. Care was taken not to miss any remnants draped over the stapedial tendon, pyramidal process, promontory, handle of the malleus, tubal orifice or jugular bulb. Because only sinus and tensa retraction types of tensa cholesteatoma were present in this series, there was no need for an atticotomy or canal wall down mastoidectomy. Complete removal of the cholesteatoma required near-total or total resection of the tympanic membrane, giving the appearance of a near-total or total perforation.

In the ring group, the cartilage-perichondrium segment was fashioned into a ring shape by dissecting

out a central disc of cartilage (5–7 mm in diameter), leaving a peripheral circular cartilaginous rim (2–3 mm in width) with an overstretched perichondrial sheet (Figure 1a).

In the Mercedes group, a channel was created by removing a strip of cartilage from the superior edge of the graft, which extended inferiorly to its centre, in order to accommodate the malleus handle. Two radial incisions were then made from the inferior end of this channel (giving a shape similar to the Mercedes-Benz car symbol), conferring adequate malleability and an almost conical contour (Figure 2a).

After graft shaping, each type of graft was inserted as an underlay with the perichondrium facing laterally; the graft fitted under the handle of the malleus in the ring group and over the handle in the Mercedes group. The graft was trimmed peripherally to size so that it fitted snugly within the tympanic bony annulus antero-inferiorly and filled the drilled annulus posterosuperiorly, in order to avoid the development of post-operative retraction pockets.

In patients with an intact ossicular chain, a type I tympanoplasty was performed (Figures 1b and 2b).

In ears with a defective long process of the incus but an intact stapes superstructure, a type II tympanoplasty

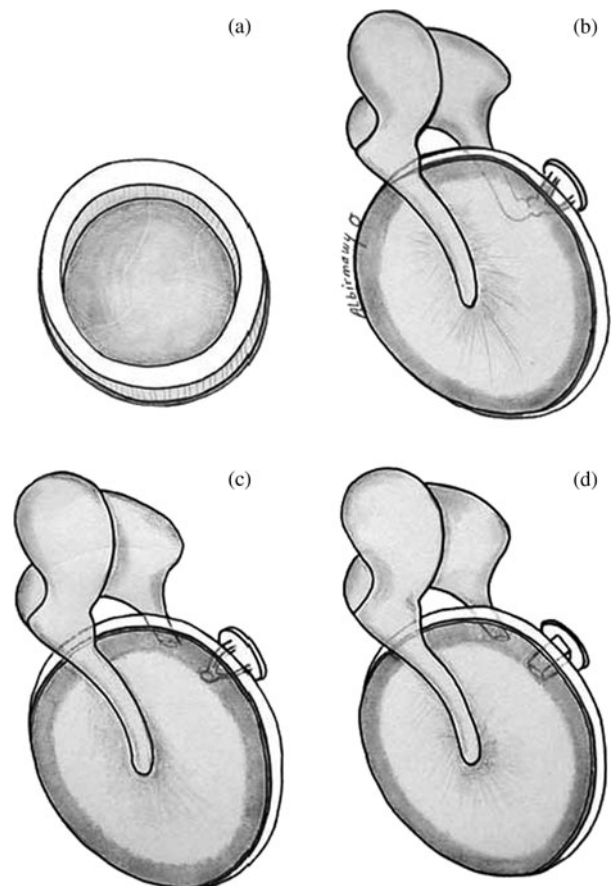


FIG. 1

Diagram showing (a) ring graft, (b) ring graft in type I tympanoplasty, (c) ring graft in type II tympanoplasty and (d) ring graft in type III tympanoplasty.

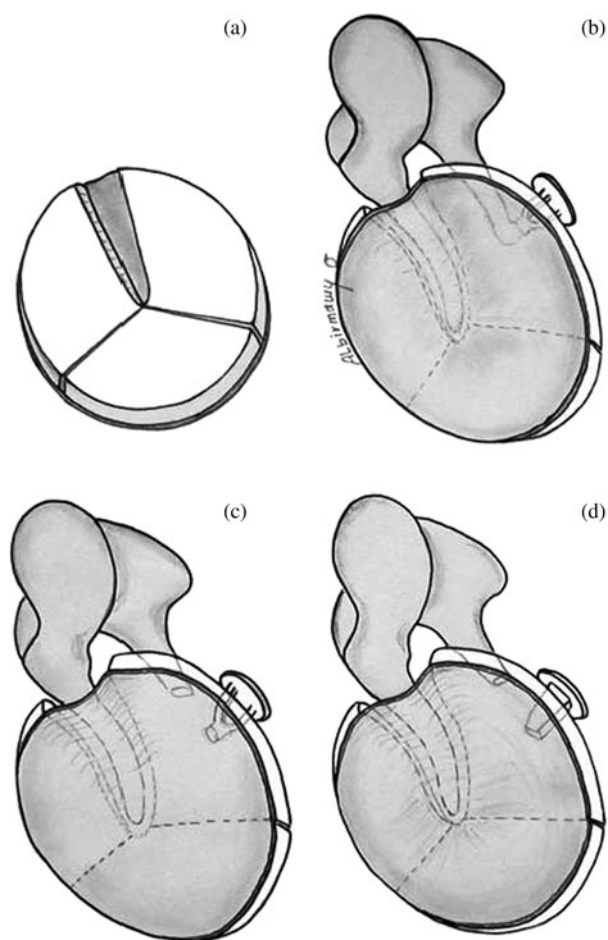


FIG. 2

Diagram showing (a) 'Mercedes-Benz' graft, (b) Mercedes-Benz graft in type I tympanoplasty, (c) Mercedes-Benz graft in type II tympanoplasty, and (d) Mercedes-Benz graft in type III tympanoplasty.

was performed. Care was taken to allow the peripheral cartilaginous rim of the ring graft and the posterosuperior plate of the Mercedes-Benz graft to rest upon the head of the stapes and the remnants of the long process of the incus, as much as possible, to compensate for the defect (Figures 1c and 2c).

Patients with a defective stapedial superstructure underwent type III tympanoplasty, using a cartilaginous columella between the footplate and the applied graft (Figures 1d and 2d).

#### Post-operative care and outcome assessment

After surgery, patients were seen every three months for at least two years. Routine follow up consisted of otomicroscopic examination and audiometric evaluation.

A successful anatomical outcome was defined as an intact, dry tympanic membrane without retraction pockets, and without residual or recurrent cholesteatoma. Any post-operative middle-ear effusion was noted.

Hearing was evaluated before and after surgery, with respect to absolute hearing (testing the pure tone

average (PTA)), speech reception threshold and air–bone gap. For absolute hearing and air–bone gap, mean thresholds were calculated at 500, 1000 and 2000 Hz.

Outcomes were assessed pre-operatively and one and two years post-operatively.

#### Statistical analysis

Data were analysed using the Statistical Package for the Social Sciences version 11.0 software program (SPSS Inc, Chicago, Illinois, USA). Summary statistics were calculated for all variables; means, standard deviations and 95 per cent confidence intervals were used for quantitative variables, and frequency distributions were used for categorical items. The Student *t*-test was used to compare hearing data which was normally distributed, while the chi-square test was used to compare categorical data (e.g. the number of cases with post-operative tympanic membrane retraction). A *p* value of less than 0.05 was considered statistically significant.

#### Results

The median age at operation was 15 years in the ring group (range, nine to 23 years) and 14 years in the Mercedes group (range, 10–22 years); this difference was not statistically significant. There was no statistically significant difference between the two groups regarding the incidence of sinus and tensa retraction cholesteatoma and the frequency of different types of tympanoplasty ( $p > 0.05$  for both; Table I).

A summary of post-operative anatomical outcomes is shown in Table II.

In the first post-operative year, a small central neodrum perforation developed in three ring group ears and two Mercedes group ears. These perforations healed with conservative measures, except for two cases (one in each group) which persisted for more than two years, eventually requiring myringoplasty with temporalis fascia grafting.

A mild degree of posterosuperior retraction was observed in one ring group patient during the first post-operative year, and in this patient and an additional ring group patient during the second post-operative year. In the Mercedes group, only one patient developed a similar retraction, during the

TABLE I  
SURGICAL GROUPS' CHOLESTEATOMA AND  
TYMPANOPLASTY TYPES

Tymp type	Ring group		Mercedes group	
	Sinus	Tensa	Sinus	Tensa
I	5	1	5	–
II	9	7	12	6
III	2	6	1	6
Total	16	14	18	12

Data represent patient numbers. Tymp = tympanoplasty; sinus = sinus cholesteatoma; tensa = tensa retraction cholesteatoma

TABLE II  
SURGICAL GROUPS' ANATOMICAL OUTCOMES

Outcome	Ring group	Mercedes group
Perforation		
– 1 y post-op	3 (10)	2 (7)
– 2 y post-op	1 (3)	1 (3)
Retraction pockets		
– 1 y post-op	1 (3)	–
– 2 y post-op	2 (7)	1 (3)
Rec cholesteatoma		
– 1 y post-op	–	–
– 2 y post-op	1 (3)	1 (3)
Discharge		
– 1 y post-op	–	–
– 2 y post-op	1 (3)	1 (3)
Effusion		
– 1 y post-op	1 (3)	1 (3)
– 2 y post-op	1 (3)	1 (3)

Data represent patient numbers (percentages). Y = years; post-op = post-operative; rec = recurrent

second post-operative year. At the end of the study period, none of these pockets had progressed, and no surgical treatment was required.

There was no evidence of residual cholesteatoma within the follow-up period. However, near to the end of the second year, one patient in each group experienced recurrent otorrhoea with evidence of recurrent cholesteatoma involving the attic and mastoid antrum. Both cases occurred in ears operated upon for tensa retraction cholesteatoma, and were managed subsequently using revision tympanoplasty and canal wall down mastoidectomy.

Four cases (two in each group) had a middle-ear effusion within the first and second year post-operatively. All of these patients were managed conservatively, and none required ventilation tube insertion.

Based on the statistical analysis, there was no significant difference between the anatomical outcomes of the two surgical groups.

Overall, patients' hearing improved significantly in each group, throughout the post-operative follow-up period (Table III; Figure 3).

In the ring group, 21 per cent of ears had a pre-operative PTA of 0 to 20 dB. After surgery, a

PTA of 20 dB or better was recorded in 69 and 88 per cent of ears in the first and second post-operative years, respectively (Table III).

In the Mercedes group, 23 per cent of ears had a pre-operative PTA of 20 dB or better. After surgery, first-year post-operative hearing results were generally good, while second-year results were even better, with 69 per cent of ears having a PTA of 0 to 20 dB (Table III).

The number of patients with post-operative PTA, speech reception threshold and air–bone gap values of 20 dB or less was significantly greater in the ring group compared with the Mercedes group ( $p < 0.05$ ).

The mean PTA, speech reception threshold and air–bone gap values were slightly better in the sinus cholesteatoma group (i.e. both graft types combined) than the tensa retraction cholesteatoma group, both pre- and post-operatively, although this difference was not statistically significant ( $p > 0.05$ ) (Figure 4).

The best results were obtained in ears with an intact ossicular chain. However, no statistically significant difference was found between the post-operative results of patients undergoing type I, II and III tympanoplasties ( $p > 0.05$ ) (Figure 5).

## Discussion

Studies of tympanic membrane reconstruction after pars tensa cholesteatoma surgery have found that cartilage with perichondrium may be a superior graft material, compared with other graft materials, as regards prevention of neodrum retraction and perforation. Some cartilage grafting techniques give better long term hearing results than others.<sup>1,3,4,9</sup> However, the opacity of cartilage impedes the detection of cholesteatoma recurrence or regrowth, necessitating strict follow up over long periods.<sup>4</sup>

To the author's best knowledge, there is little published information comparing different types of cartilage tympanoplasty.<sup>8</sup> Thus, clinical researchers face challenging questions regarding the best grafting source, thickness, shape and surgical technique for different types of middle-ear pathology. The present study compared the anatomical and audiological

TABLE III  
SURGICAL GROUPS' HEARING RESULTS

Group	PTA ≤ 20 dB (pts (n))	SRT ≤ 20 dB (pts (n))	ABG (pts (n))	
			0–10 dB	0–20 dB
Ring				
– Pre-op	21	33	4	42
– 1 y post-op	69	70	51	77
– 2 y post-op	88	91	76	90
Mercedes				
– Pre-op	23	35	3	40
– 1 y post-op	58	58	34	65
– 2 y post-op	69	70	62	79

PTA = pure tone average; pts = patients; SRT = speech reception threshold; ABG = air–bone gap; pre-op = pre-operative; y = year; post-op = post-operative

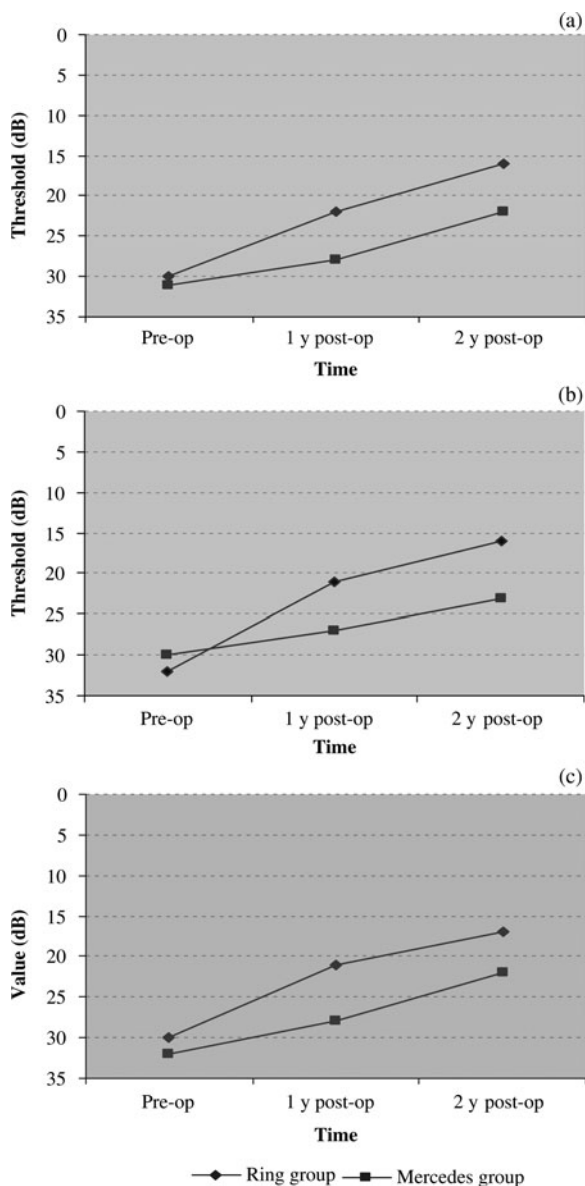


FIG. 3

Progressive results for (a) mean pure tone average, (b) mean speech reception threshold and (c) mean air-bone gap, in cholesteatoma ears reconstructed with ring or 'Mercedes-Benz' graft.

outcomes of ring and Mercedes-Benz cartilage-perichondrium grafts used during pars tensa cholesteatoma surgery, in an attempt to address these questions. Patients in the two graft groups were comparable in terms of age at operation, frequency and location of cholesteatoma, type of surgery used in addition to tympanoplasty, and type of tympanoplasty. As the thickness and shape of the external ear cartilage vary at different anatomical sites, the cartilage-perichondrium grafts used in the current series were harvested only from the tragus, in both groups. Cartilage from this site is ideal because it is thin, flat and available in sufficient quantities to permit reconstruction of the entire tympanic membrane.<sup>10</sup> Thus, the main study variable was graft shape.

Analysis of post-operative anatomical outcomes indicated that the Mercedes-Benz graft shape may be

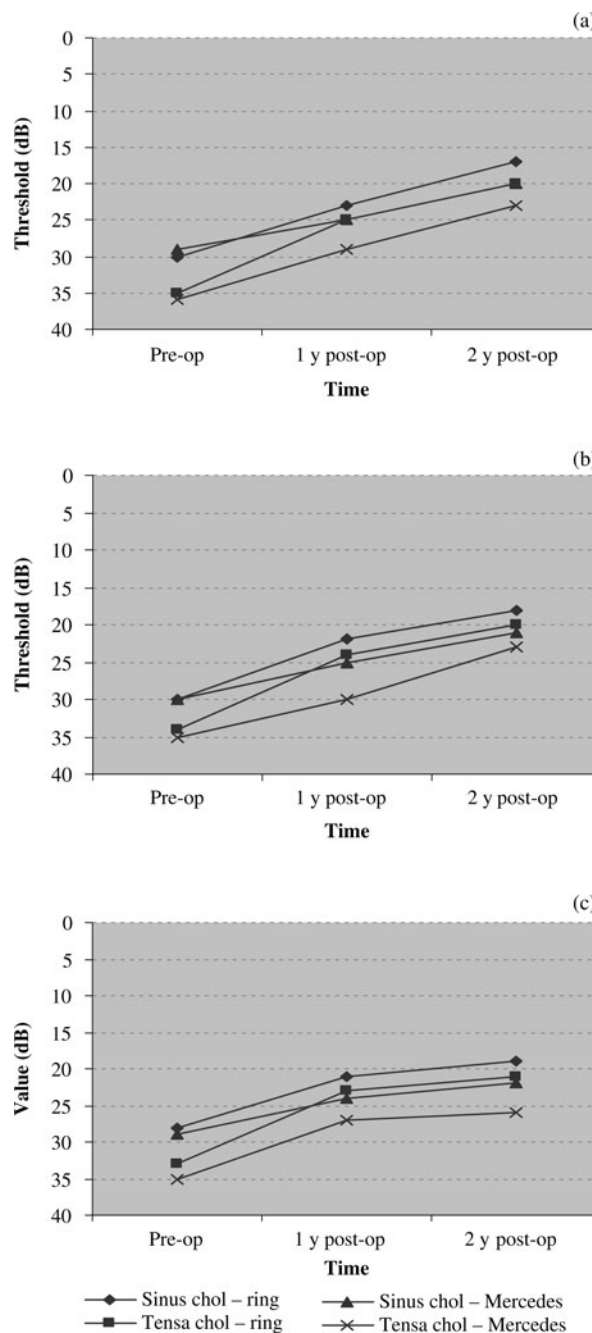


FIG. 4

Progressive results for (a) mean pure tone average, (b) mean speech reception threshold, and (c) mean air-bone gap, in ears operated upon for sinus or tensa retraction cholesteatoma and reconstructed with either ring or 'Mercedes-Benz' graft.

better at preventing neodrum retraction; however, this difference was not statistically significant. It may be the case that cartilage plates are more resistant to negative middle-ear pressure, compared with cartilage rings.

In the current series, residual cholesteatoma was not detected behind the neodrum in any patient. Furthermore, recurrent cholesteatoma (which may be related to the graft material)<sup>3</sup> occurred in both the ring and Mercedes groups (i.e. one case in each group), in ears operated upon for tensa retraction cholesteatoma. This implies that cholesteatoma recurrence

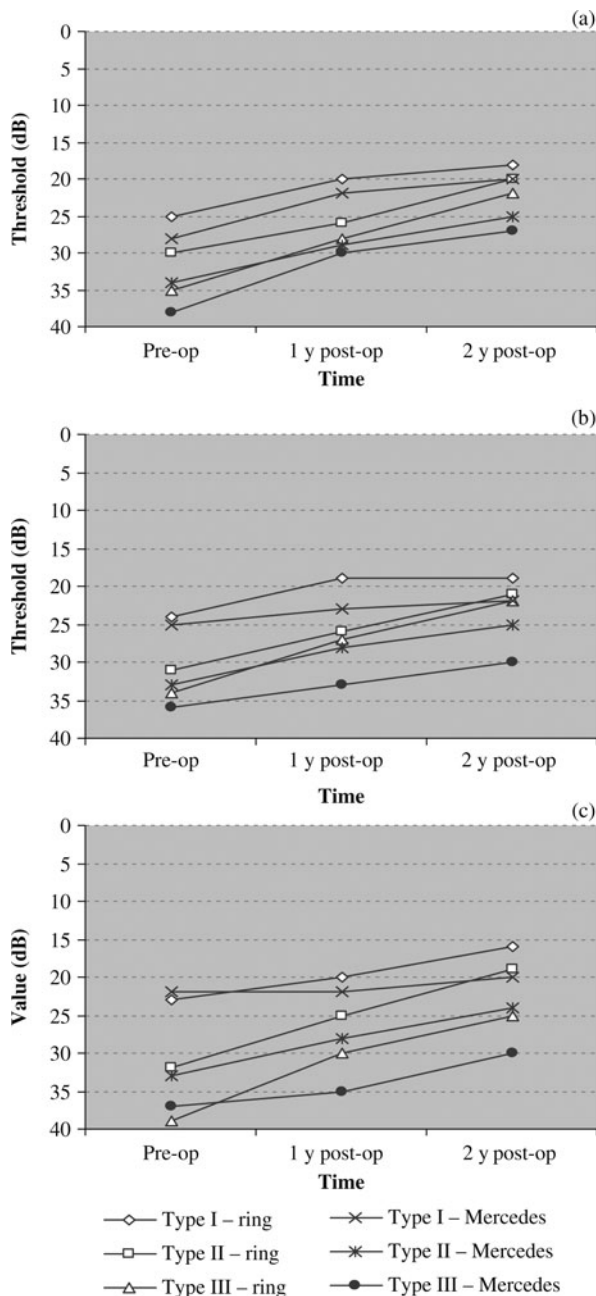


FIG. 5

Progressive results for (a) mean pure tone average, (b) mean speech reception threshold, and (c) mean air-bone gap, in cholesteatoma ears undergoing surgery with type I, II, or III tympanoplasty, with reconstruction of the eardrum using ring or Mercedes-Benz graft.

may be unaffected by graft shape. However, this result may be affected by a type two error (i.e. patient numbers too small).

According to Dornhoffer,<sup>10</sup> impedance tympanometry is unreliable after cartilage tympanoplasty, and usually yields a low-volume, type B tympanogram owing to the noncompliant nature of the graft, despite normal hearing. Thus, in the current study it was thought necessary to check air and bone conduction, using post-operative audiography, in order to determine whether an effusion was present. If an effusion is suspected, based on observation and conductive hearing

loss, then steroids are given, the Valsalva manoeuvre is encouraged, and the ear is examined frequently. In the current study, cases of post-operative middle-ear effusion in the Mercedes group did not require confirmatory myringotomy, as these patients' evident conductive deafness responded well to conservative treatment. In such cases, monitoring of conductive deafness may confirm resolution of suspected post-operative middle-ear effusion. However, in the ring group, the relative transparency and free mobility of the graft's central perichondrial sheet enabled simple, early clinical diagnosis of middle-ear effusion, and also facilitated audiological confirmation.

When fashioning the cartilage-perichondrial graft, it is essential to enable the graft to bend and conform to the conical contour of the natural tympanic membrane. In the case of Mercedes-Benz grafts, this was achieved by creating three separate but connected cartilaginous plates, forming a shape similar to the Mercedes-Benz car symbol; in the case of ring grafts, it was achieved using a circular cartilaginous ring with overstretched sheet of perichondrium, a tissue which is tough but malleable. Precise peripheral shaping of the cartilage prevented the graft from folding in the centre and enabled it to fit snugly in the desired position, giving a water-tight contact between the applied graft and the surrounding tissue, both anteroinferiorly, at the bony annulus, and posterosuperiorly, where recurrent cholesteatoma most frequently occurs. Likewise, in the Mercedes group, placing the entire graft in an underlay fashion, with the handle of the malleus filling in the groove medial to the perichondrium, prevented medial displacement of the cartilage graft, avoided contact with the promontory, and allowed for a larger middle-ear space. However, in the ring group, the graft's cartilage-free central perichondrial sheet allowed the laterally placed handle of the malleus to indent further into the perichondrium without touching the bulge of the promontory, creating much more middle-ear space.

Hearing improved significantly in both groups, compared with pre-operative values, but this increase was significantly greater in the ring group ( $p = 0.01$ ).

However, the best and most stable hearing results were obtained in ears with an intact ossicular chain. This is in keeping with the results of other authors,<sup>11,12</sup> who have found that the status of the ossicles, and their reconstruction, and the type of surgical technique are important factors for post-operative hearing restoration. Incus transposition and various biocompatible implants are frequently used for reconstructing ossicular discontinuities. Good, stable long term results have been reported.

In the current series, the peripheral cartilaginous rim of the ring graft, and the posterosuperior cartilaginous plate of the Mercedes-Benz graft, successfully closed the anatomical defect between the eroded long process of the incus and the stapes superstructure. Furthermore, in cases of absent stapes superstructure,



the superfluous graft cartilage (i.e. the dissected central cartilaginous disc of the ring graft, or the dissected vertical cartilaginous strip of the Mercedes-Benz graft) was modified for use as a columella between the footplate of the stapes and the opposing, cartilaginous part of the applied graft. Audiological results verified that both techniques resulted in a successful ossiculoplasty, without the need for incus transposition or a biocompatible implant.

- **This study of cholesteatoma patients found no significant difference in anatomical outcomes for tympanoplasty with ring vs 'Mercedes-Benz' cartilage-perichondrium grafts**
- **However, Mercedes-Benz grafting tended to give better prevention against neodrum retraction**
- **Ring grafting produced better audiological outcomes than Mercedes-Benz grafting**
- **In both groups, an intact ossicular chain and sinus cholesteatoma were associated with better hearing outcomes**

The superiority of hearing results in the ring group may be explained by the following. (1) Removal of the central cartilaginous disc of the ring graft may have created a larger middle-ear space between the neodrum and the bulge of the promontory. (2) The malleability of the central perichondrial sheet, positioned under the handle of the malleus, may have given the neodrum a more conical contour, approximating more closely the shape of the natural tympanic membrane. (3) Finally, from a mechanical point of view, while neither graft shape was a compact structure, the ring graft was as durable as, but more flexible than, the Mercedes-Benz graft, due to stretching of the central perichondrial sheet over the medially placed peripheral cartilaginous rim, which in turn fitted snugly within the bony tympanic sulcus and simulated the natural fibrous tympanic annulus.

### Conclusion

Comparison of ring and Mercedes-Benz cartilage-perichondrium grafting for tympanic membrane reconstruction after pars tensa cholesteatoma surgery indicated that the Mercedes-Benz technique may be superior in preventing neodrum retraction. Although the opacity of the cartilaginous plates of the Mercedes-Benz graft may compromise early detection of middle-ear effusion and cholesteatoma recurrence or regrowth, its flexible design allows it to bulge outward, facilitating diagnosis of any underlying

lesion. However, patients reconstructed with Mercedes-Benz grafts must be followed up more closely than ring graft patients, and for a longer period.

Hearing improved significantly in both groups, but this improvement was greater in the ring graft group. This may be due to the more physiological design of the ring graft, which has the advantages of cartilage, a rigid material, and of perichondrium, a soft and relatively transparent tissue, but without their disadvantages.

Study over a longer term follow-up period is recommended to enable further and more detailed comparison of both grafting techniques.

### References

- 1 Uzun C, Cayé-Thomasen P, Andersen J, Tos M. A tympanometric comparison of tympanoplasty with cartilage palisades or fascia after surgery for tensa cholesteatoma in children. *Laryngoscope* 2003;**113**:1751–7
- 2 Uzun C, Yagiz R, Tas A, Adali MK, Koten M, Karasalioglu AR. Combined Heermann and Tos (CHAT) technique in cholesteatoma surgery: surgical technique and preliminary results. *J Laryngol Otol* 2005;**119**:429–35
- 3 Cayé-Thomasen P, Andersen J, Uzun C, Hansen S. Ten-year results of cartilage palisades versus fascia in eardrum reconstruction after surgery for sinus or tensa retraction cholesteatoma in children. *Laryngoscope* 2009;**119**:944–52
- 4 Dornhoffer JL. Cartilage tympanoplasty: indications, techniques, and outcomes in a 1,000 patient series. *Laryngoscope* 2003;**113**:1844–56
- 5 Mansour MH, Askar MH, Albirmawy OA. How I do it. Repair of tympanic membrane perforation using a modified cartilage-perichondrium composite ring graft. *J Laryngol Otol* 2006;**120**:952–4
- 6 Albirmawy OA. Comparison between cartilage-perichondrium composite 'ring' graft and temporalis fascia in type one tympanoplasty in children. *J Laryngol Otol* 2010;**124**:967–74
- 7 Albirmawy OA, Erfan FA. Combined intact bridge mastoidectomy with ring graft tympanoplasty. *J Otolaryngol Head Neck Surg* 2011;**40**:122–30
- 8 Spielmann P, Mills R. Surgical management of retraction pockets of the pars tensa with cartilage and perichondrial grafts. *J Laryngol Otol* 2006;**120**:725–9
- 9 Anderson J, Cayé-Thomasen P, Tos M. A comparison of cartilage palisades and fascia in tympanoplasty after surgery for sinus or tensa retraction cholesteatoma in children. *Otol Neurotol* 2004;**25**:856–63
- 10 Dornhoffer JL. Cartilage tympanoplasty. *Otolaryngol Clin North Am* 2006;**39**:1161–76
- 11 Siddiq MA, East DM. Long-term hearing results of incus transposition. *Clin Otolaryngol* 2004;**29**:115–18
- 12 Stankovic M. Follow-up of cholesteatoma surgery: open versus closed tympanoplasty. *ORL J Otorhinolaryngology Relat Spec* 2007;**69**:299–305

Address for correspondence:

Dr O A Albirmawy,  
Reyad St 88, Tanta, 31211, Gharbeya, Egypt

E-mail: albirmawy@hotmail.com

---

Dr O A Albirmawy takes responsibility for the integrity of the content of the paper  
Competing interests: None declared

---

# Silent sinus syndrome: dynamic changes in the position of the orbital floor after restoration of normal sinus pressure

R SIVASUBRAMANIAM<sup>1</sup>, R SACKS<sup>2</sup>, M THORNTON<sup>3</sup>

*Ear, Nose and Throat Departments, <sup>1</sup>The Canberra Hospital, Australian Capital Territory, <sup>2</sup>Concord General Hospital, New South Wales, Australia, and <sup>3</sup>St Vincent's University Hospital, Dublin, Ireland*

## Abstract

**Background:** Silent sinus syndrome is characterised by spontaneous enophthalmos and hypoglobus, in association with chronic atelectasis of the maxillary sinus, and in the absence of signs or symptoms of intrinsic sinonasal inflammatory disease. Traditionally, correction of the enophthalmos involved reconstruction of the orbital floor, which was performed simultaneously with sinus surgery. Recently, there has been increasing evidence to support the performance of uncinectomy and antrostomy alone, then orbital floor reconstruction as a second-stage procedure if needed.

**Methods:** We performed a retrospective review of 23 cases of chronic maxillary atelectasis managed in our unit with endoscopic uncinectomy and antrostomy alone. All patients were operated upon by the same surgeon.

**Results:** Twenty-two of the 23 patients had either complete or partial resolution. One patient had ongoing enophthalmos, and was considered for an orbital floor reconstruction as a second-stage procedure.

**Conclusion:** Our case series demonstrates that dynamic changes in orbital floor position can occur after sinus re-ventilation. These findings support the approach of delaying orbital floor reconstruction in cases of silent sinus syndrome treated with sinus re-ventilation, as such reconstruction may prove unnecessary over time.

**Key words:** Maxillary Sinus; Pathology; Enophthalmos; Sinusitis; Surgical Procedures, Operative; Endoscopy

## Introduction

Spontaneous enophthalmos and hypoglobus, in association with chronic atelectasis of the maxillary sinus, and in the absence of signs or symptoms of intrinsic sinonasal inflammatory disease, is a condition first described by Montgomery in 1964, and termed the silent sinus syndrome by Soparkar *et al.* in 1994.<sup>1,2</sup> Maxillary sinus volume reduction, characterised radiologically by the inward bowing of one or more antral walls, develops as a result of osteomeatal occlusion. Over time, hypoventilation results in resorption of gases into the capillaries of the closed sinus cavity, creating negative pressure. This results in chronic subclinical inflammation, leading to maxillary atelectasis.<sup>3,4</sup> This displaces the medial infundibular wall laterally; when such collapse is significant, the orbital volume increases, with ensuing enophthalmos and hypoglobus.<sup>3,5,6</sup>

Silent sinus syndrome is a slow, progressive, unilateral disorder, with changes occurring over years. Most patients present in their third to fifth decade with no obvious preceding sinus symptoms. Examination

usually shows orbital asymmetry, with deepening of the superior orbital sulcus and eyelid retraction. All patients have a degree of hypoglobus, ranging from 2 to 6 mm, and enophthalmos, ranging from 2 to 5 mm, according to one of the largest published series.<sup>2</sup> Ocular motility and visual acuity are not always affected; occasionally, patients complain of diplopia. The mainstay of diagnosis also involves computed tomography scan of the paranasal sinuses.

Chronic maxillary atelectasis is another term used in the otolaryngology literature to describe spontaneous enophthalmos in association with a contracted ipsilateral maxillary sinus.<sup>7</sup> Chronic maxillary atelectasis is divided into three types: type I, with a membranous deformity; type II, with a bony deformity; and type III, with clinical features.<sup>7</sup> Although silent sinus syndrome can be considered a form of chronic maxillary atelectasis, and type III chronic maxillary atelectasis is similar to silent sinus syndrome, one of the main differences between them is the absence of nasal symptoms in the silent sinus syndrome patient.

Presented orally at the Australian Society of Otolaryngology Head and Neck Surgery Annual Scientific Conference, 29 March 2010, Sydney, New South Wales, Australia

Accepted for publication 23 February 2011 First published online 11 August 2011

For years, endoscopic uncinectomy and middle meatal antrostomy have been fundamental to the management of such cases, exposing the sinus ostium and re-establishing sinus ventilation. Correction of associated enophthalmos involved the reconstruction of the orbital floor, which was usually performed via a transconjunctival approach, simultaneously with sinus surgery.<sup>8,9</sup>

However, in 2003 Thomas *et al.* noted a return to normal globe position in two of four patients following uncinectomy and antrostomy alone.<sup>10</sup> This led them to recommend that orbital floor reconstruction be performed as a staged procedure for patients with persistent enophthalmos of greater than 2 mm, or related visual disturbances, after reassessment at six months.

In our unit, we have successfully managed a number of cases of silent sinus syndrome with endoscopic uncinectomy and antrostomy. During follow up of these cases, we monitored the position of the orbital floor using nasal endoscopy. In the presented series, we demonstrate the dynamic changes in orbital floor position that can occur after sinus re-ventilation, supporting the principle of delayed orbital floor reconstruction in cases of silent sinus syndrome.

## Materials and methods

We performed a retrospective review of the clinical records of all patients diagnosed with chronic maxillary atelectasis and silent sinus syndrome in our unit.

Our diagnostic criteria for chronic maxillary atelectasis was enophthalmos and/or hypoglobus, with sinus opacification noted on computed tomography or intra-operatively. Our diagnostic criteria for silent sinus syndrome included altered facial appearance, with enophthalmos and/or hypoglobus, computed tomography imaging showing a contracted ipsilateral maxillary sinus, and absence of sinusitis symptoms.

We performed a detailed analysis of patient demographics, clinical presentation, radiological findings, surgical management and clinical outcome.

Post-operative patient review was performed on a six-monthly basis, with the position of the orbital floor being monitored using nasendoscopy and clinical measurement of enophthalmos. Follow-up patients underwent computed tomography scanning of the paranasal sinuses only if clinically indicated. Our follow-up period ranged from 15 months to 10 years.

## Results and analysis

We have managed 23 cases of chronic maxillary atelectasis in our unit, of which 18 had clinical evidence of silent sinus syndrome. Fourteen of these patients were female and nine were male, giving a male:female ratio of 1:1.5. Patients' ages ranged from 19 to 54 years at the time of diagnosis. The right maxillary sinus was affected in 15 cases, the left in eight cases.

## Clinical presentation

Seven patients presented for investigation of progressive facial asymmetry and clinical enophthalmos. The remainder were referred following incidental radiological findings.

On direct questioning, six patients confirmed symptoms of nasal obstruction and/or snoring. One patient with a significant septal deviation reported a history of recurrent epistaxis. Such symptoms were experienced over a period of time ranging from months to a few years, but were not experienced by those with clinical enophthalmos with silent sinus syndrome. Eighteen patients were found to have evidence of clinical enophthalmos, and seven had obvious facial asymmetry (Figure 1).

## Radiological findings

All patients had radiological evidence of a hypoplastic maxillary antrum with associated opacification. Furthermore, in each case the uncinete process was atelectatic and loosely adherent to the lamina papyracea. Eleven patients also had a deviated nasal septum, with a bony spur to the side of the hypoplastic maxillary sinus.

## Management

All patients underwent endoscopic uncinectomy and maxillary antrostomy (Figure 2), which was combined with a septoplasty in 11 patients. Orbital floor reconstruction was not performed in any of the patients with enophthalmos.

## Outcome

Patients were followed up for a period ranging from 15 months to 10 years.

In this time period, one of the 23 patients had evidence of persistent clinical enophthalmos, at 18 months. In this patient, follow up with nasendoscopy demonstrated elevation of the orbital floor over time. However, he continued to have clinical features of enophthalmos, and consequently was considered to possibly require orbital floor reconstruction.

All patients were reviewed at routine intervals. There was no ongoing evidence of worsening enophthalmos or hypoglobus. Fourteen of the 18 patients with enophthalmos (78 per cent) had complete resolution of enophthalmos, while three (17 per cent) had partial resolution. Partial resolution was defined as some residual enophthalmos, but of no aesthetic concern to the patient. The time period over which improvement in enophthalmos became evident was up to 18 months post-surgery, with changes generally starting to appear from six months post-operatively.

None of the five chronic maxillary sinus atelectasis patients progressed to develop enophthalmos and silent sinus syndrome following sinus re-ventilation, during their follow-up period.

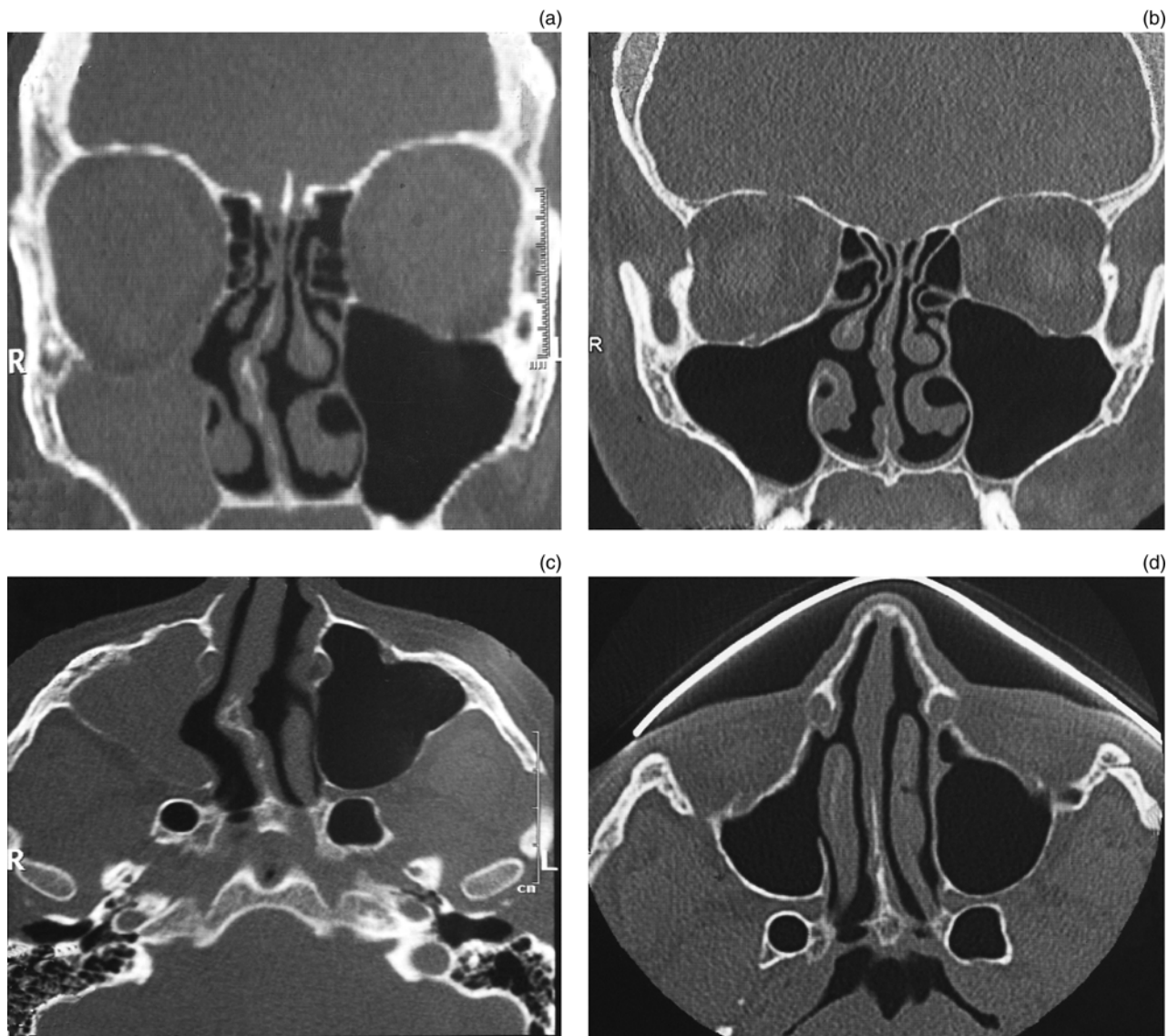


FIG. 1

(a) Coronal and (b) following uncinectomy and middle meatal antrostomy, parts (c) axial computed tomography views of a hypoplastic right maxillary antrum in a patient with silent sinus syndrome and (d) show corresponding views indicating remodelling of the orbital floor and orbital medial wall, 10 years post-surgery.

## Discussion

For years, the management of enophthalmos in silent sinus syndrome patients has included the re-establishment of sinus ventilation by endoscopic uncinectomy and antrostomy combined with simultaneous transconjunctival repair of the orbital floor.<sup>9</sup> However, there have been recent reports documenting the return of the globe to its normal position after sinus re-ventilation procedures, first by Wan *et al.* (one case) in 2000 and later by Thomas *et al.* (two cases) in 2003.<sup>10,11</sup> A number of review articles published in recent years have suggested the idea of delayed or staged orbital floor correction.<sup>12</sup> However, there are no studies, besides the above-mentioned ones, which clearly indicate that silent sinus syndrome should be initially treated by uncinectomy and antrostomy alone.

In our unit, all patients with silent sinus syndrome are followed up after sinus surgery, and the position of the orbital floor is monitored. In the presented silent sinus syndrome patients, dynamic changes in the position of the orbital floor were clearly evident, and were documented, at various time points following sinus re-ventilation.

These findings further support the need for a delay before proceeding with reconstruction of the orbital floor, as management of enophthalmos. At the time of writing, none of our subjects had required orbital floor reconstruction, although one patient may require such intervention in the future.

We would assume that the elimination of negative maxillary sinus pressure (demonstrated by Scharf *et al.*) following endoscopic uncinectomy and antrostomy removes the downward retractive pull on the

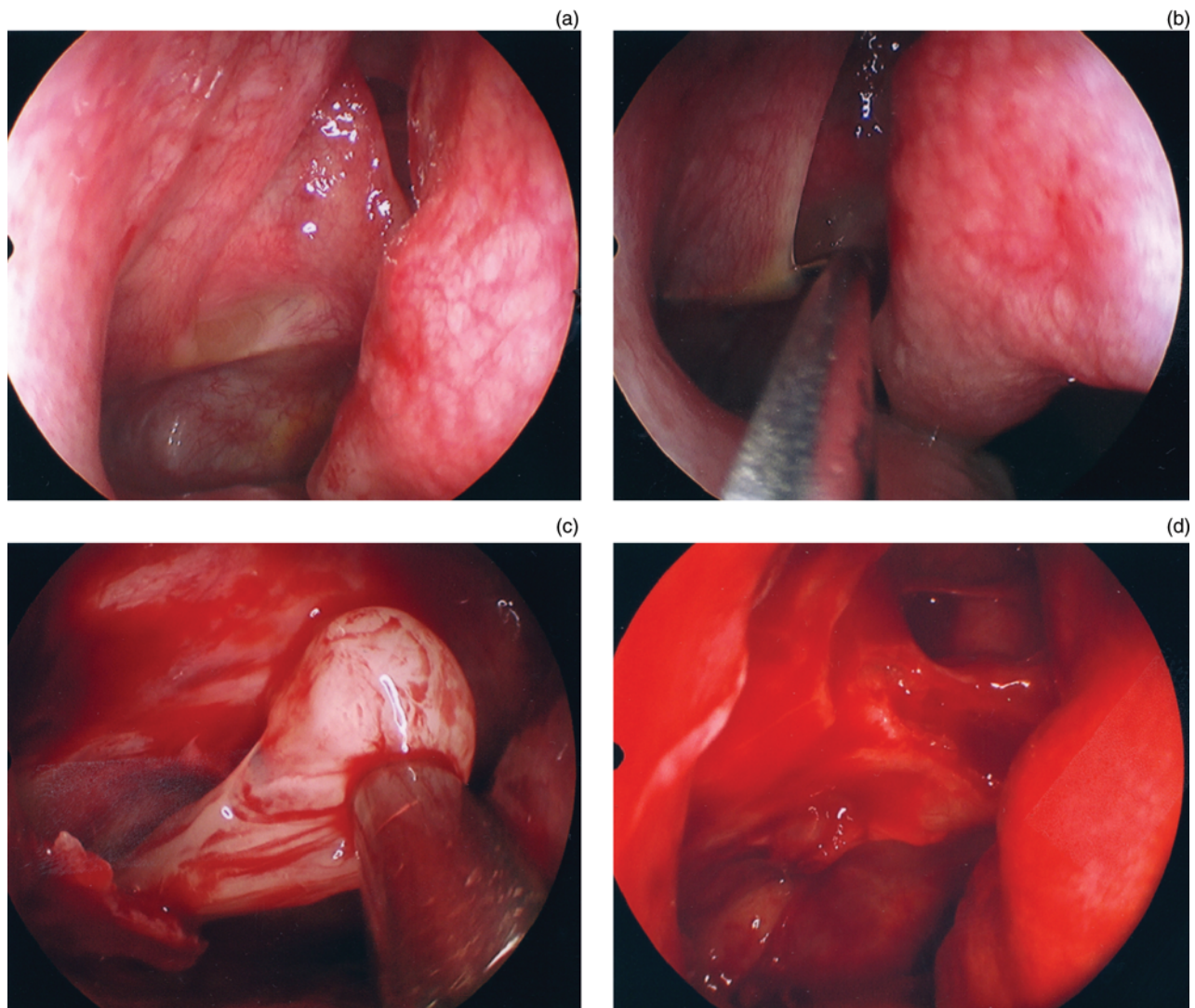


FIG. 2

Intra-operative, endoscopic images showing the uncinectomy and middle meatal antrostomy procedures.

orbital floor and contents, allowing a return to a normal or near-normal position.<sup>13</sup>

- **Silent sinus syndrome comprises spontaneous enophthalmos and hypoglobus, with chronic maxillary sinus atelectasis and without intrinsic sinonasal inflammatory disease**
- **This slow, progressive, unilateral disorder eventually causes 2–6 mm of hypoglobus and 2–5 mm of enophthalmos**
- **Endoscopic uncinectomy and antrostomy re-establish maxillary sinus ventilation, which usually corrects the orbital floor deformity, reversing enophthalmos and hypoglobus**
- **If there is no post-operative improvement, orbital floor reconstruction is recommended**

In the past, re-establishment of normal maxillary sinus configuration has been demonstrated with imaging;

however, this has not been demonstrated in all cases of silent sinus syndrome. The current study demonstrates that it is possible to monitor the post-operative position of the orbital floor with nasendoscopy. In addition to providing a simple means of monitoring, such nasendoscopy also enables assessment of the need for future reconstructive surgery. We performed computed tomography scanning in only two cases post-operatively; in both these cases, there was evidence of bony remodelling, restoring the orbital floor to a normal position.

As previously documented, the risk of orbital injury in such cases is high, because of the close adherence of the uncinete process to the lamina papyracea.<sup>14</sup> Consequently, we believe that it is essential to perform uncinectomy in a posterior-to-anterior direction, using a paediatric back-biting instrument, to avoid injury to the lamina papyracea (as opposed to using an anterior-to-posterior direction and a sickle knife).

In many cases, an associated septoplasty procedure may be necessary. This was the case in our series of

patients with chronic maxillary atelectasis and silent sinus syndrome, in which 11 out of 23 patients had significant associated nasal septal deviation.

### Conclusion

In patients with silent sinus syndrome and enophthalmos, the position of the orbital floor can improve following surgical restoration of normal maxillary sinus pressure. Therefore, orbital floor reconstruction, performed to treat enophthalmos in such patients, should be delayed for anything up to 18 months after sinus surgery. In many cases, uncinectomy and antrostomy may be sufficient management for silent sinus syndrome.

In such cases, the close adherence of the uncinate process to the lamina papyracea favours performance of the uncinectomy in a posterior-to-anterior direction.

### References

- 1 Montgomery WW. Mucocoele of the maxillary sinus causing enophthalmos. *Eye Ear Nose Throat Mon* 1964;**43**:41–4
- 2 Soparker CN, Patrinely JR, Cuaycong MJ, Dailey RA, Kersten RC, Rubin PA *et al*. The silent sinus syndrome: a cause of spontaneous enophthalmos. *Ophthalmology* 1994;**101**:772–8
- 3 Kass ES, Salman S, Montgomery W. Manometric study of complete ostial occlusion in chronic maxillary atelectasis. *Laryngoscope* 1996;**106**:1255–8
- 4 Davidson JK, Soparker CN, Williams JB, Patrinely JR. Negative sinus pressure and normal predisease imaging in silent sinus syndrome. *Arch Ophthalmol* 1999;**117**:1653–4
- 5 Kass ES. The diagnosis and treatment of chronic maxillary atelectasis in adults and children. *Curr Opin Otolaryngol Head Neck Surg* 1999;**7**:39–45
- 6 Annino DJ Jr, Goguen LA. Silent sinus syndrome. *Curr Opin Otolaryngol Head Neck Surg* 2008;**16**:22–5
- 7 Brandt MG, Wright ED. The silent sinus syndrome is a form of chronic maxillary atelectasis: a systematic review of all reported cases. *Am J Rhinol* 2008;**22**:68–73
- 8 Dailey RA, Cohen JL. Surgical repair of the silent sinus syndrome. *Ophthalm Plast Reconstr Surg* 1995;**11**:261–8
- 9 Vander Meer JB, Harris G, Toohill RJ, Smith TL. The silent sinus syndrome: a case series and literature review. *Laryngoscope* 2001;**111**:975–8
- 10 Thomas RD, Graham SM, Carter KD, Nerad JA. Management of the orbital floor in silent sinus syndrome. *Am J Rhinol* 2003;**17**:97–100
- 11 Wan MK, Francis IC, Carter PR, Griffiths R, van Rooijen ML, Coroneo MT. The spectrum of presentation of silent sinus syndrome. *J Neuroophthalmol* 2000;**20**:207–12
- 12 Numa WA, Desai U, Gold DR, Heher KL, Annino DJ. Silent sinus syndrome: a case presentation and comprehensive review of all 84 reported cases. *Ann Otol Rhinol Laryngol* 2005;**114**:688–94
- 13 Schraf KE, Lawson W, Shapiro JM, Gannon PJ. Pressure measurements in the normal and occluded rabbit maxillary sinus. *Laryngoscope* 1995;**105**:570–4
- 14 Hunt SM, Tami TA. Sinusitis-induced enophthalmos: the silent sinus syndrome. *Ear Nose Throat J* 2000;**79**:578–84

Address for correspondence:

A/Prof R Sacks,  
ENT Centre,  
Suite 12 The Madison, 25–29 Hunter Street, Hornsby, NSW,  
Australia 2077

Fax: + 61 2 94824695

E-mail: rsacks@commander360.com

---

Associate Professor R Sacks takes responsibility for the integrity of the content of the paper

Competing interests: None declared

---

## Rapid Rhino versus Merocel nasal packs in septal surgery

A HESHAM, A GHALI

<sup>1</sup>Department of Otorhinolaryngology, Faculty of Medicine, Cairo University, Egypt, and <sup>2</sup>Department of Anesthesiology, Faculty of Medicine, Tanta University, affiliated to Magrabi Eye and Ear Hospital, Sultanate of Oman

### Abstract

**Objective:** To compare Rapid Rhino and Merocel packs for nasal packing after septoplasty, in terms of patient tolerance (both with the pack in place and during removal) and post-operative complications.

**Material and methods:** Thirty patients (aged 18–40 years) scheduled for septoplasty were included. Following surgery, one nasal cavity was packed with Rapid Rhino and the other one with Merocel. Patients were asked to record pain levels on a visual analogue score, on both sides, with the packs in situ and during their removal the next day. After pack removal, bleeding was compared on both sides.

**Results:** The mean  $\pm$  standard deviation pain score for the Rapid Rhino pack in situ ( $4.17 \pm 1.78$ ) was less than that for the Merocel pack ( $4.73 \pm 2.05$ ), but not significantly so ( $p = 0.314$ ). The mean pain score for Rapid Rhino pack removal ( $4.13 \pm 1.76$ ) was significantly less than that for Merocel ( $6.90 \pm 1.67$ ;  $p = 0.001$ ). Bleeding after pack removal was significantly less for the Rapid Rhino sides compared with the Merocel sides ( $p < 0.05$ ).

**Conclusion:** Rapid Rhino nasal packs are less painful and cause less bleeding, compared with Merocel packs, with no side effects. Thus, their use for nasal packing after septal surgery is recommended.

**Key words:** Septoplasty; Tampons, Surgical; Nasal Cavity; Pain, Post Operative

### Introduction

Nasal packing materials are widely used in endonasal surgery, including septoplasty, turbinectomy and paranasal sinus surgery. They are also used to prevent synechiae and haematoma formation, to support septal flap apposition, and to close dead space between cartilage and subperichondrial flaps.<sup>1</sup>

Painful nasal pack removal is often the most uncomfortable aspect of septoplasty surgery for patients. Pain may be caused by dislodgement of the blood clot and adherent tissues, following adherence of traditional nasal tampons to the nasal septum over the original bleeding site.<sup>2</sup>

Two nasal tampon types in common use are Rapid Rhino and Merocel.

Rapid Rhino packs (Arthrocare, Knaresborough, UK) consist of two parts: an inflatable cuff and carboxymethylcellulose packing. When the latter contacts blood, it promotes platelet aggregation. The whole pack has a dual effect on haemostasis: it compresses arterial bleeding, and also promotes clotting to staunch active capillary and venous bleeding.<sup>3</sup>

Merocel packs (Medtronic Xomed, Jacksonville, Florida, USA) consist of a foam-like nasal packing

material which is a polymer of hydroxylated polyvinyl acetate. The pack material contains cavities capable of absorbing fluid. Once moistened with fluid, the material becomes softer and more elastic.<sup>4</sup>

This study aimed to compare the use of Rapid Rhino and Merocel packs for nasal packing after septoplasty, in terms of patient tolerance (both with the pack in place and during removal) and post-operative complications.

### Materials and methods

This prospective, randomised, controlled study was conducted at Magrabi Eye and Ear Hospital, Sultanate of Oman, from June 2009 to July 2010. The study was approved by the local ethical committee. Informed consent was obtained from all patients.

Thirty patients (aged 18–40 years) scheduled for septoplasty were enrolled in the study. We excluded patients with bleeding disorders and those receiving anticoagulants.

At the end of septoplasty surgery, one nasal cavity was packed with a Rapid Rhino pack (a Mannheim Gel-Knit nasal dressing, 8 cm without cuff) and the other with a Merocel pack (8 cm). Pack type was

allocated in a random manner, using sealed envelopes. Patients were blinded to the type of pack inserted on each side.

The Rapid Rhino pack was first soaked in sterile water for 30 seconds (not saline, as this inhibits the gelling characteristics), then inserted gently along the floor of the nasal cavity.

The Merocel pack was inserted along the floor of the nasal cavity first and then irrigated with 10 ml of saline, or water in case of no expansion within 30 seconds.

Patients were asked to record their pain levels on a visual analogue score, for both nasal cavities, both with the packs in situ and during pack removal.

Packs were removed the day after surgery. After removal, bleeding from both sides was recorded by the second author (AG, an anaesthetist), who was blinded to the pack type used, according to the following scale: 0 = no bleeding; 1 = mild trickle requiring no intervention; 2 = moderate bleeding requiring packing with small cottonoid pledgets soaked with vasoconstrictor drops for 5–10 minutes; 3 = significant bleeding requiring repacking after failure of the previous temporary pack. Patients were also asked to report any bleeding in the following two weeks. A follow-up visit was scheduled after two months to check for synechiae formation.

Data were statistically described in terms of range, mean  $\pm$  standard deviation, frequency (number of cases) and percentages when appropriate. Quantitative study group variables were compared using the Mann–Whitney U test for independent samples. Categorical data were compared using the chi-square test. The exact test was used when the expected frequency was less than 5. A probability value (*p* value) of less than 0.05 was considered statistically significant. All statistical calculations were performed using the software programs Microsoft Excel 2003 (Microsoft Corporation, New York, USA) and the Statistical Package for the Social Science version 15 for Microsoft Windows (SPSS Inc, Chicago, Illinois, USA).

## Results

Thirty patients were included in the study, with a mean age of 26 years. Twenty patients (66.67 per cent) were male and 10 (33.33) female.

The mean pain score with the pack in situ was less for the Rapid Rhino pack ( $4.17 \pm 1.78$ ) than for the Merocel pack ( $4.73 \pm 2.05$ ); however, this difference did not achieve statistical significance ( $p = 0.314$ ). The mean pain score for pack removal was significantly less for the Rapid Rhino pack ( $4.13 \pm 1.76$ ) than the Merocel pack ( $6.90 \pm 1.67$ ) ( $p = 0.001$ ).

After pack removal, there was significantly less bleeding noted in nasal cavities which had been packed with Rapid Rhino packs, compared with Merocel packs ( $p < 0.05$ ) (Table I).

None of the following were observed: bleeding requiring repacking (i.e. a score of 3); secondary

TABLE I  
BLEEDING SCORES AFTER NASAL PACK REMOVAL

Score	Rapid Rhino* (pts (n))	Merocel† (pts (n))
0	8	2
1	18	9
2	4	19

\**n* = 30; †*n* = 30. Pts = patients

bleeding within two weeks; or synechiae between the septum and the lateral nasal wall within two months.

## Discussion

The ideal nasal pack is one which conforms easily to the contour of the nasal cavity and stimulates haemostasis. It should also be: easy to insert and remove without causing undue discomfort; comfortable while in situ; secure, without forwards or backwards prolapse; capable of achieving haemostasis without damaging the nasal cavity mucosa; and should cause minimal tissue reaction.<sup>5</sup>

Several techniques have been used in an attempt to reduce the pain associated with nasal pack removal, e.g. intramuscular papaveratum injection, nitrous oxide gas inhalation and pack rehydration with lidocaine. Durvasula and colleagues<sup>6</sup> found that rehydration with a local anaesthetic solution (lidocaine) did not reduce the pain of pack removal after nasal surgery.

Since the introduction of Rapid Rhino nasal packs, four clinical trials have compared them with Merocel nasal packs: two trials studied patients with epistaxis,<sup>7,8</sup> while the other two assessed pack use after nasal surgery.<sup>9,10</sup>

Badran *et al.*<sup>7</sup> studied 52 patients with epistaxis, and concluded that both pack types were equally effective in epistaxis control, but that Rapid Rhino packs were more comfortable for patients and easier for healthcare workers to insert and remove. Similar results were reported by Moumoulidis *et al.*,<sup>8</sup> in their study of 42 patients.

In an attempt to minimise bias in our study findings, assessment of bleeding was performed by the second author, who was blinded to the type of nasal pack used in each nasal cavity.

From our findings, we conclude that Rapid Rhino and Merocel packs had similar pain scores whilst in situ, but that Rapid Rhino packs were less painful to remove, with less bleeding, compared with Merocel packs.

Our findings are similar to those reported by Arya and colleagues.<sup>9</sup> However, these authors used a different type of Rapid Rhino pack (a Goodman 5.5 cm pack, instead of a Mannheim 8 cm pack), for a wide range of nasal procedures (i.e. septoplasty, turbinectomy and functional endoscopic sinus surgery), in only 14 patients.

Similar results were also reported by Ozcan *et al.*<sup>10</sup> These authors concluded that Rapid Rhino packs



were associated with less post-operative pain and sensation of fullness, less pain during pack removal, and less reactionary bleeding. This study differed from our own in terms of larger patient numbers (51 patients), removal of the inflatable cuff Rapid Rhino pack after 48 hours, and an alternative bleeding assessment method (i.e. grading on a scale of 0 to 2).

- **After septoplasty, 30 patients received a Merocel nasal pack on one side and a Rapid Rhino pack on the other**
- **Both pack types were similarly painful in situ**
- **Rapid Rhino packs were less painful during removal than Merocel packs**
- **Removal of Rapid Rhino packs caused less bleeding than Merocel packs**

In our own study, the difference in pain scores between the two pack types was probably due to the elasticity and external gel coating of the Rapid Rhino pack, which reduce adhesion to the nasal mucosa and thus facilitate removal. The difference in bleeding was probably mostly due to the haemostatic properties of carboxymethylcellulose, which are similar to those of other known clotting agents such as Adenosine diphosphate (ADP), thrombin and collagen.<sup>9</sup>

Following pack removal, we encountered no complications in our patients, either early (e.g. significant bleeding) or late (e.g. synechia).

Two studies<sup>7,9</sup> have raised the issue of accidental expulsion of Rapid Rhino packs due to their slippery surface. This was not encountered in our study, probably because we used longer (8 cm) packs and tied both ends of the packs.

## Conclusion

Rapid Rhino nasal packs are less painful and cause less bleeding, compared with Merocel nasal packs, with no side effects. Therefore, our study findings can be added

to previously published reports recommending the use of Rapid Rhino packs after nasal surgery.

## References

- 1 Weber R, Hochapfel F, Draff W. Packing and stents in endonasal surgery. *Rhinology* 2000;**38**:49–62
- 2 Chheda N, Katz AE, Gyniziol L, Singer AJ. The pain of nasal tampon removal after nasal surgery: A randomized control trial. *Otolaryngol Head Neck Surg* 2009;**140**:215–17
- 3 Gudziol V, Mewes T, Mann WJ. Rapid Rhino: a new pneumatic nasal tamponade for posterior epistaxis. *Otolaryngol Head Neck Surg* 2005;**132**:152–5
- 4 Weber R, Keerl R, Hochapfel F, Draff W, Toffel PH. Packing in endonasal surgery. *Am J Otolaryngol* 2001;**22**:306–20
- 5 Corbridge RJ, Djazaeri B, Hellier WPL, Hadley J. A prospective randomised controlled trial comparing the use of Merocel nasal tampons and BIPP in the control of acute epistaxis. *Clin Otolaryngol* 1995;**20**:305–7
- 6 Durvasula VS, Brewis C, Syeda F, Leong P. Lignocaine as a topical analgesia for post-operative nasal pack removal: a prospective, randomized, double-blind, controlled trial. *J Laryngol Otol* 2005;**119**:348–51
- 7 Badran K, Malik TH, Belloso A, Timms MS. Randomized controlled trial comparing Merocel and Rapid Rhino packing in the management of anterior epistaxis. *Clin Otolaryngol* 2005;**30**:333–7
- 8 Moumoulidis I, Draper MR, Patel H, Jani P, Price T. A prospective randomized controlled trial comparing Merocel and Rapid Rhino nasal tampons in the treatment of epistaxis. *Eur Arch Otorhinolaryngol* 2006;**263**:719–22
- 9 Arya AK, Butt O, Nigam A. Double-blind randomized controlled trial comparing Merocel with Rapid Rhino nasal packs after routine nasal surgery. *Rhinology* 2003;**41**:241–3
- 10 Ozcan C, Vayisoglu Y, Kiliç S, Görür K. Comparison of Rapid Rhino and Merocel nasal packs in endonasal septal surgery. *J Otolaryngol Head Neck Surg* 2008;**37**:826–31

Address for correspondence:

Dr Ahmed Hesham,  
Magrabi Eye and Ear hospital  
106, Rumaila building,  
A1 Nohda St.,  
P.O. Box: 513, Postal Code 112,  
Muscat Oman

Fax: +968 24568874

E-mail: ahesham73@yahoo.com

---

Dr A Hesham takes responsibility for the integrity of the content of the paper  
Competing interests: None declared

---

# ‘How does that sound?’: objective and subjective voice outcomes following CO<sub>2</sub> laser resection for early glottic cancer

S E LESTER, M H RIGBY, M MACLEAN, S M TAYLOR

*Division of Otolaryngology-Head and Neck Surgery, Division of Surgery, Dalhousie University, Queen Elizabeth II Health Sciences Centre, Halifax, Nova Scotia, Canada*

## Abstract

**Objective:** To investigate the effect of transoral laser microsurgery for early glottic cancer on subjective and objective vocal outcome measures.

**Design:** Prospective cohort study.

**Setting:** Tertiary care cancer centre.

**Participants:** All patients scheduled for transoral laser microsurgery for untreated early primary glottic cancer over a 22-month period and offered voice assessment (31 patients; 19 tumour stage one, 12 tumour stage two).

**Main outcome measures:** Fundamental frequency, maximum phonation time, calculated jitter, shimmer and subjective voice rating, analysed by tumour stage.

**Results:** Tumour stage T<sub>1</sub> patients had significantly different fundamental frequencies and maximum phonation times at three months post-operatively, compared with pre-operative values; these differences resolved by 12 months. At 12 months, tumour stage T<sub>2</sub> patients had significantly shorter maximum phonation times, and all patients reported significantly worse subjective voice ratings, compared with pre-operative values.

**Conclusion:** We found no change in fundamental frequency, jitter and shimmer, one year post-operatively. Maximum phonation time deteriorated but stage one patients appeared to compensate, whereas stage two patients did not. Resection size may be a factor. All patients reported significantly worse subjective voice ratings at one year. Aerodynamic and subjective voice measures appear most sensitive to change in this patient group.

**Key words:** Laryngeal Neoplasms; Carcinoma; Lasers; Therapeutics

## Introduction

Early laryngeal cancer is commonly treated using either primary radiotherapy or transoral laser microsurgery. In our centre, all patients are offered both treatments; however, most opt for transoral laser microsurgery, due to the shorter duration of treatment (with at least similar local control rates).

When signing their written consent form for surgical treatment, patients are required to formally acknowledge the possibility of deterioration in their voice due to the surgery. However, it is difficult to quantify this risk. Therefore, we aimed to prospectively study the voices of patients undergoing transoral laser microsurgery within our institution.

## Methods

From January 2002 to November 2007, all patients opting for transoral laser microsurgery for early glottic cancer (i.e. American Joint Committee on

Cancer tumour-node-metastasis (TNM) staging of T<sub>1</sub> or T<sub>2</sub>, and N<sub>0</sub> and M<sub>0</sub>), who had not received other treatment for their cancer, were asked to undertake voice evaluation.

A pre-operative set of voice recordings was made during the same clinic appointment in which patients were booked for surgery. Follow-up recordings were made three and 12 months after surgery. The voice recordings were made in an isolated room away from the clinic, but without formal soundproofing. All recording was performed by a specifically trained speech and language pathologist or clinic nurse. All recordings were made using Computerized Speech Lab (CSL4300) software (Kay Elemetrics, Lincoln Park, NJ, USA). Data were transcribed at the time of recording.

A standardised protocol was used, as previously developed by the speech and language pathologist. The patient was given a short period of instruction on how to use the microphone, and was encouraged to

TABLE I  
SIGNIFICANT ACOUSTIC RESULTS: T<sub>1</sub> CASES

Parameter	Value (mean (range))			Difference*			
	Pre-op	3 mth post-op	12 mth post-op	3 mth post-op		12 mth post-op	
				Diff (95%CI)	<i>p</i>	Diff (95%CI)	<i>p</i>
F <sub>0</sub> (free speech) (Hz)	148.0 (109.9–216.6)	161.9 (122.9–229.0)	159.2 (100.1–255.4)	19.1 (4.2–34.0)	0.02	11.3 (– 2.0 to 24.5)	0.09
F <sub>0</sub> (reading) (Hz)	149.8 (103.6–220.7)	161.9 (122.9–229.0)	156.2 (112.1–212.5)	11.7 (1.7–21.7)	0.02	6.0 (– 5.6 to 17.6)	0.29
MPT (sec)	13 (5–24)	11 (6–22)	12 (5–22)	–2.7 (–5.3 to –0.2)	0.04	–1.4 (–4.7 to 2.0)	0.39

\*Compared with pre-operative (pre-op) values. T<sub>1</sub>=tumour stage one; mth = months; post-op = post-operative; diff = difference; CI = confidence interval; F<sub>0</sub> = fundamental frequency; MPT = maximum phonation time; sec = seconds

keep their mouth at a distance of 30 cm from the microphone, which was mounted on a microphone stand. A period of free speech was recorded, in which the patient described their journey to the clinic. The patient's fundamental frequency in free speech was calculated. The patient was then given the 'rainbow passage' to read, and their fundamental frequency in reading was calculated. The patient's 'jitter' (i.e. frequency perturbation) and 'shimmer' (i.e. amplitude perturbation) were calculated from a recorded segment of the rainbow passage. The patient was instructed to produce the sound 'a' on a full breath of air and to maintain it for as long as possible; the best of three attempts was recorded as the maximum phonation time. Finally, the patient was asked to rate their own voice on a simple ordinal scale of one to five, where one was the worst voice they could imagine having and five was the best.

Data were recorded manually and filed in each patient's individual chart, and a note made on the front sheet about the date of the study. Data were later transcribed into a database (Access 2003; Microsoft, Redmond, Washington, USA) of patients who had undergone laser surgery in our unit. Data were exported initially into a spreadsheet (Excel 2003, Microsoft) and then into a statistical analysis program (PASW version 17; SPSS Inc., Chicago, IL, USA).

Missing data were searched for by retrieving the case notes. We analysed only the data of patients for whom pre-operative and three- and 12-month post-operative voice recordings could be retrieved.

Cases were separated in stage T<sub>1</sub> and T<sub>2</sub> subgroups. Analysis was performed for the total group as well as for the two subgroups.

As the subjective voice rating was a discrete categorical variable, the median was calculated rather than the mean. For other variables, mean pre-operative, three-month post-operative and 12-month post-operative values were calculated. The null hypothesis was that there was a change (in an unspecified direction) between values recorded pre-operatively and those recorded three and 12 months post-operatively, for each variable. A two-tailed, paired Student *t*-test was calculated (using PASW version 17 software) to test the difference between the means of the pre-operative and the three- and 12-month post-operative values; the 95 per cent confidence interval and *p* value were also calculated. The Wilcoxon paired sign rank test was used to analyse the non-parametric subjective voice ratings. A *p* value of less than 0.05 was taken to represent a significant difference between pre- and post-operative recorded values.

#### Ethical considerations

Our research ethics board granted approval for the study of patient vocal outcomes, prior to patient data collection. Voice outcome data were collected at the time of obtaining consent for surgery; this did not require any additional hospital visits.

#### Results

Of the 54 patients with at least 24 months follow up, only 41 had undergone pre-operative voice recording. Reasons for lack of voice recording included machine failure, lack of a trained member of staff to make the recording, patient refusal and loss of records.

TABLE II  
SIGNIFICANT ACOUSTIC RESULTS: T<sub>2</sub> CASES

Parameter	Value (mean (range))			Difference*			
	Pre-op	3 mth post-op	12 mth post-op	3 mth post-op		12 mth post-op	
				Diff (95%CI)	<i>p</i>	Diff (95%CI)	<i>p</i>
MPT (sec)	16 (3–36)	10 (3–15)	8 (4–14)	–5.7 (–11.8 to 0.44)	0.07	–7.2 (–12.6 to –1.7)	0.02

\*Compared with pre-operative (pre-op) values. T<sub>2</sub>=tumour stage two; mth = months; post-op = post-operative; diff = difference; CI = confidence interval; MPT = maximum phonation time; sec = seconds

**TABLE III**  
SIGNIFICANT ACOUSTIC RESULTS: T<sub>1</sub> + T<sub>2</sub> CASES

Parameter	Value (mean (range))			Difference*			
	Pre-op	3 mth post-op	12 mth post-op	3 mth post-op		12 mth post-op	
				Diff (95%CI)	p	Diff (95%CI)	p
F <sub>0</sub> (free speech) (Hz)	151.1 (99.6–240.2)	164.8 (125.3–288.1)	157.1 (83.0–289.7)	13.7 (1.7–250.7)	0.03	6.0 (– 0.7 to 19.2)	0.36
MPT (sec)	16.5 (3–36)	10.3 (3–22)	10.4 (4–22)	–3.3 (–5.6 to –0.9)	0.01	–3.0 (–5.8 to –0.3)	0.03

\*Compared with pre-operative (pre-op) values. T<sub>1</sub>=tumour stage one; T<sub>2</sub> = tumour stage two; mth = months; post-op = post-operative; CI = confidence interval; F<sub>0</sub> = fundamental frequency; MPT = maximum phonation time; sec = seconds

**TABLE IV**  
SIGNIFICANT VOICE RATING RESULTS

Cases	Value (median (range))			Difference*			
	Pre-op	3 mth post-op	12 mth post-op	3 mth post-op		12 mth post-op	
				Diff (95%CI)	p	Diff (95%CI)	p
T <sub>1</sub>	3 (1–5)	3 (1–5)	2 (1–4)	–0.1 (–1.0 to 0.8)	0.90	–0.7 (–1.3 to –0.1)	0.03
T <sub>2</sub>	3.5 (2–5)	3 (2–5)	3 (1–5)	–0.5 (–1.2 to 0.09)	0.08	–0.9 (–1.0 to –0.02)	0.046
T <sub>1</sub> +T <sub>2</sub>	3.5 (1–5)	3 (1–5)	2.5 (1–5)	–0.3 (–0.8 to 0.3)	0.38	–0.8 (–1.3 to –0.3)	0.02

Data represent subjective voice rating scores unless otherwise indicated. \*Compared with pre-operative (pre-op) values. Mth = months; post-op = post-operative; CI = confidence interval; T<sub>1</sub> = tumour stage one; T<sub>2</sub> = tumour stage two

Of these 41 patients, 31 had all three sets of complete recordings available for analysis. These 31 patients comprised five women and 26 men, with a mean age of 67 years (range, 30–84 years). Nineteen patients had stage T<sub>1</sub> tumours and 12 had stage T<sub>2</sub> tumours. Table I summarises the significant results for the stage T<sub>1</sub> patients, Table II summarises results for the stage T<sub>2</sub> patients, and Table III summarises results for stage T<sub>1</sub> and T<sub>2</sub> patients combined.

As patients’ subjective voice ratings were non-parametric variables, these are summarised separately in Table IV and Figure 1.

At three months post-operatively, there was a statistically significant change in fundamental frequency (both free speech and reading) and maximum phonation time in the stage T<sub>1</sub> group, compared with pre-operative values. At this same time point, we also observed a significant difference in the free speech fundamental frequency and maximum phonation time for the whole patient group, compared with pre-operative values. However, at this time point there were no significant differences in jitter or shimmer in either subgroup, compared with pre-operative values.

At 12 months post-operatively, there were no statistically significant differences in fundamental frequency (free speech or reading), jitter or shimmer, either for the whole group or for the T<sub>1</sub> or T<sub>2</sub> subgroups, compared with pre-operative values. At this same time point, we also observed no significant difference in the maximum phonation time for the T<sub>1</sub> subgroup, compared with pre-operative values. However, at this time point the maximum phonation time of the T<sub>2</sub>

subgroup and the whole group was significantly shorter, compared with pre-operative values.

Three months after surgery, there was no statistically significant difference in subjective vocal rating for any of the groups, compared with pre-operative values.

However, a statistically significant difference was noted for subjective vocal rating in the whole group and in the T<sub>1</sub> and T<sub>2</sub> subgroups, comparing pre-operative and 12-month post-operative values. For subjective vocal ratings, the median pre-operative result, median 12-month post-operative result and median change were respectively 3.5, 2.5 and –1.0 for the whole

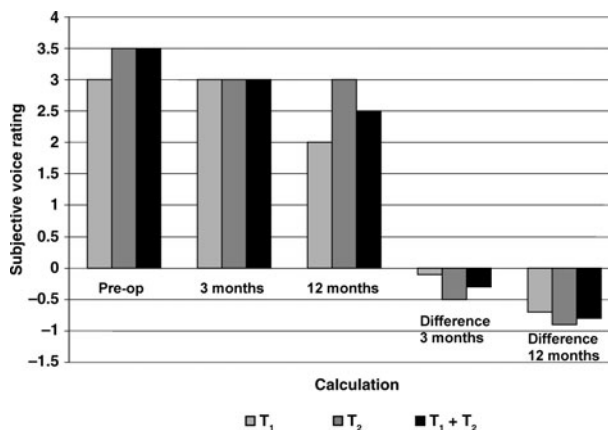


FIG. 1

Median subjective vocal ratings over time, and differences over time (compared with pre-operative values). Pre-op = pre-operative; T<sub>1</sub> = tumour stage one; T<sub>2</sub> = tumour stage two

group, 3.0, 2.0 and  $-1.0$  for the  $T_1$  subgroup, and 3.5, 3.0 and  $-0.5$  for the  $T_2$  subgroup.

## Discussion

In the treatment of early glottic cancer, it has become accepted that radiotherapy, open partial surgery and transoral laser microsurgery provide similar cure rates. Therefore, vocal outcome should be a high priority when assessing the success of these treatments.<sup>1,2</sup>

In this group of patients, it is usually not possible to conduct a pre-disease vocal assessment, as by the time of presentation the patient's voice is potentially altered by their vocal fold pathology. It has been suggested that patients with risk factors for glottic cancer (i.e. heavy smokers and drinkers, and those with pre-existing dysplasia) are also at risk of dysphonia due to these same factors.<sup>1</sup> Therefore, the concept of normative values for objective vocal assessment may not be relevant to these patients.<sup>3,4</sup>

Patients who present with dysphonia due to glottic cancer are often concerned about how the treatment will affect their voice. Although we have no pre-disease 'normal' baseline for such patients, we can assess the vocal effects of surgery using patients' pre-operative status as a baseline.<sup>2</sup> We can also assess patient's perception of their voice, while accepting the subjective, multifactorial nature of such self-evaluation.

This paper only reports our patients' vocal outcomes. Our patients' survival outcomes (published elsewhere) were comparable with published results when matched for stage. Therefore, we were keen to investigate how transoral laser microsurgery, in our hands, affected vocal outcomes, and thus to prospectively collect vocal data on all of these patients where possible.

### *Synopsis of key findings*

In our patients, aside from some initial changes in fundamental frequency for both free speech and reading in the  $T_1$  subgroup, the main changes noted were in maximum phonation time and subjective voice rating.

The fall in maximum phonation time seems logical, as this parameter is directly related to glottic competence. Resective surgery is likely to cause greater air loss through a persistent gap in the glottis, thus shortening the maximum phonation time. In the  $T_1$  subgroup, the maximum phonation time initially shortened by a mean of 2.7 seconds at three-month post-operative testing, compared with pre-operative baseline measurements. At 12 months post-operatively, the change from baseline was less, at only 1.4 seconds shorter. The opposite was seen in the  $T_2$  subgroup, in which the maximum phonation time deteriorated with time. There was a mean decrease of 5.7 seconds at three months post-surgery and of 7.2 seconds at 12 months post-surgery, compared with baseline. As  $T_1$  disease generally requires a smaller volume resection than  $T_2$  disease, it may be that patients compensate better following  $T_1$  resections.<sup>5</sup> This conclusion would be in keeping with other published findings indicating that

voices tend towards breathiness following transoral laser microsurgery.<sup>4,6-8</sup>

### *Comparison with other studies*

Our findings for objective voice measures are in keeping with published data, which indicate that transoral laser microsurgery for  $T_1$  glottic tumours leaves patients with a grossly normal voice in many cases.<sup>4-9</sup> The published information generally does not include voice results for larger tumours.

One problem with the published data is the lack of standardisation of vocal outcomes assessed. There have been attempts to provide a suggested minimum dataset for assessing dysphonias.<sup>10</sup> However, due to time and resource limitations it is probably more sensible to use those characteristics that have been shown to measure change in a given condition.

In our study, objective acoustic measures showed no significant change. One other study found an improvement in these measures, while others found a deterioration, or no change.<sup>4,5,8,11</sup>

It is not clear how these values relate to everyday speech, and, as previously discussed, it is not possible to compare them with normative values.

Of the objective measures assessed in the current study, the maximum phonation time showed the most change. There are many factors that can affect maximum phonation time, including underlying lung pathology, patient effort and compliance, and glottic competence. These confounding factors must be considered when assessing any change in this measure. However, other papers have also noted a fall in maximum phonation time following transoral laser microsurgery.<sup>8,11</sup>

Importantly, leakage of air through an incompetent glottis is treatable by various vocal fold medialisation techniques. Zeitels *et al.* reported normalisation in sound pressure level in nine patients who underwent vocal fold medialisation following transoral laser microsurgery.<sup>1</sup> This suggests that some of the voice abnormalities caused by transoral laser microsurgery may be treatable. Speech therapy has also been shown to improve outcomes following transoral laser microsurgery. Van Gogh *et al.* conducted a randomised, controlled trial of 23 patients (treated both with transoral laser microsurgery and with radiotherapy), and demonstrated improvements in both subjective and objective measures of vocal performance following speech therapy.<sup>12</sup>

The present study showed a significant deterioration in subjective voice rating at 12 months, for the whole group and both subgroups, compared with pre-operative values. Interestingly, there was no significant difference at the three-month assessment, compared with pre-operative values. This may be due in part to the complex relationship between patients perception of their voice and other psychological factors.

The subjective scale used was a very basic one to five scale, and as such was not very sensitive. No attempt was made to undertake expert-rated subjective

voice assessment, due to resource constraints. A visual analogue scale would have provided more information. The scale used had limitations, including lack of standardisation, reliance on past recall to measure the patient's 'best ever voice', and lack of normal values.

There are several validated scales in existence which have been used for self-assessment of vocal function. The most common is the Vocal Handicap Index, developed and validated by Jacobson *et al.* in 1997 to quantify the psychosocial consequences of voice disorders.<sup>13</sup> The use of such a scale in the future would provide a more sensitive indicator of patients' voice disorder severity, and would facilitate the assessment of intervention outcomes.

#### *Clinical application of study findings*

Transoral Laser Microsurgery achieves excellent local control in early glottic cancer. We believe that vocal outcomes are a significant factor when assisting patient choice of treatment. Our study will help clinicians inform patients fully about the quality of their voice after treatment with transoral laser microsurgery.

- **Patients suitable for transoral laser microsurgery of the larynx are often dysphonic at presentation**
- **Acoustic measures may not be sensitive assessors of the effect of laser surgery for early laryngeal cancer**
- **This study assessed voice effects of transoral laser microsurgery for early glottic cancer**
- **Three months post-operatively, maximum phonation time was worse in both tumour stage T<sub>1</sub> and T<sub>2</sub> patients; the latter were unable to compensate for this at 12 months**
- **All patients reported a subjective voice change, still present one year after surgery**

#### **Conclusion**

In the present study, we found acoustic objective measures to be unhelpful in this assessment. We noted a significant change in maximum phonation time at three months post-surgery, probably due to incompetent glottic closure. Patients with T<sub>1</sub> tumours seemed to have compensated for this effect by the end of the first post-operative year. However, the effect became greater with time in T<sub>2</sub> patients.

Patients' subjective vocal rating decreased in a statistically significant manner 12 months after transoral laser microsurgery, compared with pre-operative values. We consider this to be an important finding, consistent with the literature, which will help inform our future patient management. We found few previous reports of vocal outcomes for patients with T<sub>2</sub> glottic cancer treated with transoral laser microsurgery; the

present study provides evidence that these patients do almost as well as those with T<sub>1</sub> cancers.

#### **References**

- 1 Zeitels SM, Hillman RE, Franco RA, Bunting GW. Voice and treatment outcome from phonosurgical management of early glottic cancer. *Ann Otol Rhinol Laryngol Suppl* 2002;**190**:3–20
- 2 Peretti G, Piazza C, Balzanelli C, Mensi MC, Rossini M, Antonelli AR. Preoperative and postoperative voice in Tis-T1 glottic cancer treated by endoscopic cordectomy: an additional issue for patient counseling. *Ann Otol Rhinol Laryngol* 2003;**112**:759–63
- 3 Van Gogh CD, Mahieu HF, Kuik DJ, Rinkel RN, Langendijk JA, Verdonck-de Leeuw IM. Voice in early glottic cancer compared to benign voice pathology. *Eur Arch Otorhinolaryngol* 2007;**264**:1033–8
- 4 Tamura E, Itahara S, Ogura M, Kohno N. Voice quality after laser surgery or radiotherapy for T1a glottic carcinoma. *Laryngoscope* 2003;**113**:910–14
- 5 Jong-Lyel R, Dong-Hyun K, Sang Yoon K, Il Park C. Quality of life and voice in patients after laser cordectomy for Tis and T1 glottic carcinomas. *Head Neck* 2007;**29**:1010–16
- 6 Sjögren EV, van Rossum MA, Langeveld TP, Voerman MS, van de Kamp VA, Friebel MO *et al.* Voice outcome in T1a midcord glottic carcinoma laser surgery vs radiotherapy. *Arch Otolaryngol Head Neck Surg* 2008;**134**:965–72
- 7 Rosier JF, Grégoire V, Counoy H, Octave-Prignon M, Rombaut P, Scalliet P *et al.* Comparison of external radiotherapy, laser microsurgery and partial laryngectomy for the treatment of T1N0M0 glottic carcinomas: a retrospective evaluation. *Radiother Oncol* 1998;**48**:175–83
- 8 Vilaseca I, Huerta P, Blanch JL, Fernandez-Planas AM, Jimeinez C, Bernal-Sprekelsen M. Voice quality after CO<sub>2</sub> laser cordectomy — what can we really expect? *Head Neck* 2008;**30**:43–9
- 9 Cohen SM, Garrett CG, Dupont WD, Ossoff RH, Courey MS. Voice-related quality of life in T1 glottic cancer: irradiation versus endoscopic excision. *Ann Otol Rhinol Laryngol* 2006;**115**:581–6
- 10 Dejonckere PH, Bradley P, Clemente P, Cornut G, Crevier-Buchman L, Friedrich G *et al.* Committee on Phoniatics of the European Laryngological Society (ELS). A basic protocol for functional assessment of voice pathology, especially for investigating the efficacy of (phonosurgical) treatments and evaluating new assessment techniques: guideline elaborated by the Committee on Phoniatics of the European Laryngological Society (ELS). *Eur Arch Otorhinolaryngol* 2001;**258**:77–82
- 11 Núñez Batalla F, Caminero Cueva MJ, Señaris González B, Llorente Pendás JL, Gorriç Gil C, López Llamas A *et al.* Voice quality after endoscopic laser surgery and radiotherapy for early glottic cancer: objective measurements emphasizing the Voice Handicap Index. *Eur Arch Otorhinolaryngol* 2008;**265**:543–8
- 12 van Gogh CD, Verdonck-de Leeuw IM, Boon-Kamma BA, Rinkel RN, de Bruin MD, Langendijk JA *et al.* The efficacy of voice therapy in patients after treatment for early glottic carcinoma. *Cancer* 2006;**106**:95–105
- 13 Jacobson BH, Johnson A, Grywalski C, Silbergleit A, Jacobson G, Benninger MS. The Voice Handicap Index (VHI): development and validation. *Am J Speech Lang Pathol* 1997;**6**:66–70

Address for correspondence:

Mr Shane Lester,  
Consultant ENT Surgeon,  
Darlington Memorial Hospital,  
Darlington,  
Durham, DL3 6HX

E-mail: shanelester@nhs.net

---

Mr S Lester takes responsibility for the integrity of the content of the paper  
Competing interests: None declared

---

# Thyroid lymphoma: acute presentation and long-term outcome

S E PENNEY<sup>1</sup>, J J HOMER<sup>1,2</sup>

<sup>1</sup>University Department of Otolaryngology – Head and Neck Surgery, Manchester Royal Infirmary, and

<sup>2</sup>Department of Head and Neck Surgery, Christie Hospital, Manchester, UK

## Abstract

**Background:** Thyroid lymphomas are relatively uncommon. This study aimed to analyse our experience of thyroid lymphoma management and outcome.

**Materials and methods:** A retrospective case note analysis of 63 patients treated in the previous 13 years was conducted.

**Results:** The five-year survival rate was 68 per cent, with most patients dying of their lymphoma. This is at odds with the British Thyroid Association statement that the prognosis of this condition is ‘generally excellent’. The only presenting symptom found to be significantly associated with prognosis was dysphagia ( $p = 0.001$ ). Dual modality treatment provided a significantly better outcome than single modality treatment ( $p = 0.014$ ). Thyroid lymphoma can present to the head and neck surgeon ‘in extremis’; however, it can respond rapidly to appropriate treatment.

**Conclusion:** The outcome of thyroid lymphoma seems unrelated to the acuteness of its presentation. Thyroid surgery has no role other than for diagnosis. However, 51 per cent of the study patients underwent some form of thyroidectomy, indicating the need to implement better diagnostic pathways.

**Key words:** Thyroid Gland; Lymphoma; Prognosis

## Introduction

Thyroid cancer is the commonest endocrine malignancy, despite being responsible for less than 1 per cent of all cancers.<sup>1</sup> Between 1 and 5 per cent of these cancers are found to be non-Hodgkin’s lymphomas.<sup>2</sup> The disease is usually of B-cell origin, but Hodgkin’s lymphoma and T-cell lymphomas have also been described.<sup>3</sup> There is a strong correlation with Hashimoto’s thyroiditis, which is found concomitantly in 45<sup>4</sup> to 85 per cent<sup>3</sup> of cases. Consequently, thyroid lymphoma exhibits a female preponderance.<sup>4</sup>

Thyroid lymphoma classically presents as a rapidly enlarging thyroid mass in a patient aged over 50 years. The main differential diagnosis is anaplastic thyroid cancer. Fine needle aspiration cytology (FNAC) is often non-diagnostic (although it may raise suspicion). Definitive diagnosis is made after either open biopsy (when lymphoma or anaplastic carcinoma is suspected) or, less commonly, after more definitive surgery in the form of lobectomy or total thyroidectomy. The latter may be the case when the disease presents as a more indolent swelling.

The optimum treatment is with a combination of chemotherapy and radiotherapy. During the 1990s, it

became rapidly apparent that dual modality treatment provided a far better outcome than treatment with either chemotherapy or radiotherapy alone.<sup>5,6</sup> Surgery does not provide any additional benefit.<sup>6</sup>

The literature supplies only sparse evidence of factors related to eventual thyroid lymphoma outcome. Published results are often based on small groups of cases collected over lengthy periods of time. The overall five-year survival for thyroid lymphoma is generally 50–60 per cent.<sup>6</sup> The five-year survival for stage IE disease has been reported as 100 per cent.<sup>7</sup> Some factors have been identified as being related to adverse outcome, including old age<sup>5</sup> and the presence of high-grade pathology and extra-thyroidal disease.<sup>5,8</sup> In the UK, thyroid cancer guidance published in 2007 by the British Thyroid Association stated that ‘the prognosis is generally excellent’ for thyroid lymphomas.<sup>9</sup>

This study aimed to review our experience of thyroid lymphoma and to clarify whether adverse symptoms and signs at presentation could be related to outcome. We also sought to highlight the diagnostic dilemma posed by the patient with a rapidly enlarging thyroid mass, airway compromise and an unknown histological diagnosis.

**Materials and methods**

Seventy-one patients were identified with a primary diagnosis of thyroid lymphoma made between 1992 and 2004, using the hospital coding system. All cases were subject to histopathological review, as per the hospital service operational policy on lymphoma. Hospital records were scrutinised, and demographic, clinicopathological and outcome data were recorded.

Survival curves were produced, using the Kaplan–Meier method, and compared using the log rank test. Significant effects of symptom presentation on survival were then identified.

**Results**

*Demographic data*

Out of the 71 patients identified, it was possible to trace 63 sets of case notes with adequate available data.

The median patient follow-up time was 60 months (range, two to 135 months). There was a strong female preponderance (47 women (75 per cent) versus 16 men (25 per cent)). Age at presentation ranged from 38 to 91 years (median, 68 years). Diagnosis and initial surgical treatment (e.g. thyroidectomy or tracheostomy) were carried out at a number of referring hospitals.

*Presenting symptoms*

Two-thirds of patients (66 per cent) had symptoms for less than two months prior to presentation. The mean time to presentation was 2.8 months.

All patients presented with some form of neck mass, either fixed (87 per cent) or mobile (13 per cent). Sixty-eight per cent of patients were believed to have a retrosternal component to their thyroid mass, based on clinical or radiological findings. Other symptoms were frequently associated with the neck mass, e.g. stridor or dysphagia. Table I summarises the presenting symptoms and signs, and their frequency.

*Diagnostic procedures*

Table II summarises the diagnostic procedures carried out. Thirty patients (48 per cent) underwent biopsy (Tru-Cut or open), while 32 patients (51 per cent) underwent more formal surgery.

Symptom or sign	Pts (n (%))
Mobile neck mass	8 (13)
Fixed neck mass	55 (87)
Retrosternal extension	43 (68)
Dysphagia	14 (22)
Stridor	26 (41)
Dysphonia	19 (30)
Dyspnoea	29 (46)
SVC obstruction	6 (10)

Pts = patients; SVC = superior vena cava

Procedure	Pts (n (%))
Open biopsy	19 (30)
Partial (hemi-) thyroidectomy	16 (25)
Near-total thyroidectomy	9 (14)
Total thyroidectomy	7 (11)
Tru-Cut biopsy	11 (18)
Fine needle aspiration	11 (18)

Pts = patients

Thirteen patients (21 per cent) required a tracheostomy. Four tracheostomies were permanent and nine were temporary.

*Staging*

All patients were staged according to the Ann Arbor classification (Table III). Just over half the patients (n = 35) had localised disease within the thyroid gland (stage IE). A further 23 patients had disease within the thyroid as well as demonstrable local lymphadenopathy (stage IIE). The remaining five patients had disseminated disease. A total of 28 patients had systemic lymphoma, compared with 35 with disease solely within the thyroid.

*Pathology*

All patients were classified as having B-cell non-Hodgkin’s lymphoma. Forty-seven patients had their histology reviewed by the Christie Hospital histopathology department. The remaining 16 all had documented evidence (in the case notes) of a specimen showing B-cell non-Hodgkin’s lymphoma from the referring hospital, which had been reviewed by a specialist pathologist in that hospital’s pathology department. The majority of patients (n = 52) were classified as having a high-grade B-cell lymphoma or a diffuse large B-cell lymphoma. There were four definite and five possible diagnoses of mucosa-associated lymphoid tissue lymphoma. The remaining two patients had low-grade disease. Table IV illustrates these results.

Ten patients had evidence of Hashimoto’s thyroiditis, and a further six had evidence of a lymphocytic

Stage	Description
I	Disease within single lymph node or lymph node region
II	Disease in ≥2 lymph node regions on same side of diaphragm
III	Disease in lymph node regions on both sides of diaphragm
IV	Widespread disease, including involvement of one or more extranodal sites*

Suffixes: A = no systemic symptoms; B = symptoms including drenching night sweats, unexplained weight loss and fevers; E = extranodal disease. \*E.g. bone marrow, liver, lungs.



TABLE IV  
PATHOLOGICAL SUBTYPES

Subtype	Pts (n (%))
High grade or DLBCL	52 (83)
Low grade	3 (5)
B-cell lymphoma of uncertain grade	8 (13)

Pts = patients; DLBCL = diffuse large B-cell lymphoma

thyroiditis. In 34 patients, there was no identifiable thyroid tissue, as the gland had been very heavily infiltrated by tumour and therefore the presence or absence of thyroiditis could not be commented upon.

#### Treatment

Thirty-five per cent ( $n = 22$ ) of patients received radiotherapy alone, 13 per cent (eight) received chemotherapy alone, and the remaining 49 per cent (31) received dual modality treatment. Three patients did not receive any treatment.

Radiotherapy was given to 52 patients in total, either as an anterior single field or as an anterior–posterior parallel pair.

Chemotherapy consisted of either vincristine, adriamycin, prednisolone, etoposide, cyclophosphamide and bleomycin ('VAPEC-B'), or cyclophosphamide, doxorubicin, vincristine and prednisolone ('CHOP'). A total of 39 patients received chemotherapy; for eight, this was their only treatment. Patients in the later years of the study were more likely to receive radiotherapy and chemotherapy. However, no patient in this series received the cluster of differentiation 20 glycoprotein antibody rituximab.

#### Outcome

The estimated five-year survival was 62 per cent. Median survival has not been reached by the end of the study period. Of the patients who died ( $n = 28$ ), 23 died of their lymphoma (36.5 per cent of the series); there were also five (7.9 per cent) intercurrent deaths. The overall survival by stage was 73 per cent for stage IE and 48 per cent for stage IIE+ disease.

Of the 23 patients who died of their lymphoma, 17 did so within six months of diagnosis (73 per cent). Of those patients who died of their disease, 18 died following their initial presentation, without achieving a remission (78 per cent). The remaining five achieved a brief remission (median, 98 days) and then relapsed, eventually succumbing to their disease. There were no relapses after 18 months.

Four out of five of the intercurrent deaths were due to second malignancies.

#### Relapse pattern

In total of nine patients relapsed (14 per cent). The mean time to relapse was 260 days (range, 77–514 days). Of these nine patients, five died of their lymphoma (55 per cent), one died of lung cancer, and the

other three were alive and well at the time of writing. Six of the nine patients (66 per cent) who relapsed had been initially treated with radiotherapy alone, while the other three had received dual modality treatment.

Further treatment of the relapsed cases varied. Three patients were offered no treatment, three underwent chemotherapy, and three received a combination of chemotherapy and radiotherapy.

The site of relapse was also variable. One patient relapsed locally within the neck, and one in the axilla. Five patients had relapse within the abdomen: two developed nodal disease and three had intestinal involvement. One patient was found to have central nervous system infiltration, and the last patient developed disease in the humerus and femur (extra-nodal relapses).

#### Prognostic factors

The patients' presenting symptoms were correlated with their overall survival, in an attempt to predict which patients would fare worst in the long term. We also considered the effect on overall survival of thyroid lymphoma stage (i.e. stage IE versus stages IIE to IV), presence of Hashimoto's thyroiditis, tracheostomy requirement, surgical intervention (i.e. none, open biopsy or hemi-thyroidectomy (or more extensive procedure)) and single versus dual modality treatment (Table V).

It should be noted that only one death out of the 23 attributable to lymphoma occurred in a patient considered to have low-grade histology.

The only factor found to adversely affect the overall survival of these patients was the presence of dysphagia (Figure 1).

Disease stage was of borderline significance, those patients with more extensive disease having a worse prognosis (Figure 2). Those patients with stage IE disease were considered to have localised disease, as opposed to those with involvement of more than one organ or group of nodes.

TABLE V  
OVERALL SURVIVAL ESTIMATION FOR POSSIBLE  
PROGNOSTIC FACTORS

Factor	$p^*$
Neck mass	0.21
Retrosternal extension	0.11
Dysphagia	0.01 <sup>†</sup>
Stridor	0.36
Dysphonia	0.26
SVC obstruction	0.69
Dyspnoea	0.26
Hashimoto's thyroiditis	0.83
Tracheostomy	0.87
Disease stage	0.063
Surgical procedure	0.16
Single vs dual modality treatment	0.014 <sup>†</sup>

\*Kaplan–Meier analysis. <sup>†</sup> $p < 0.05$ . SVC = superior vena cava

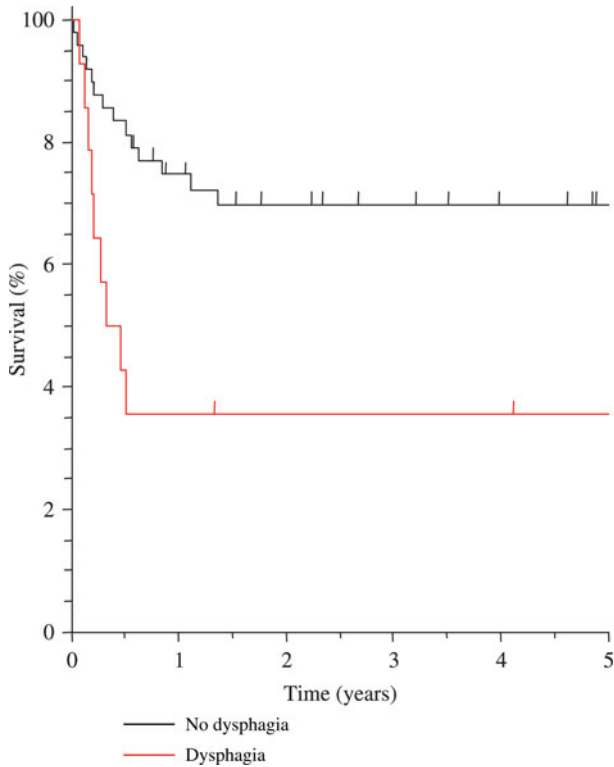


FIG. 1

Patient five-year survival by dysphagia.  $p = 0.01$ , dysphagic vs non-dysphagic patients.

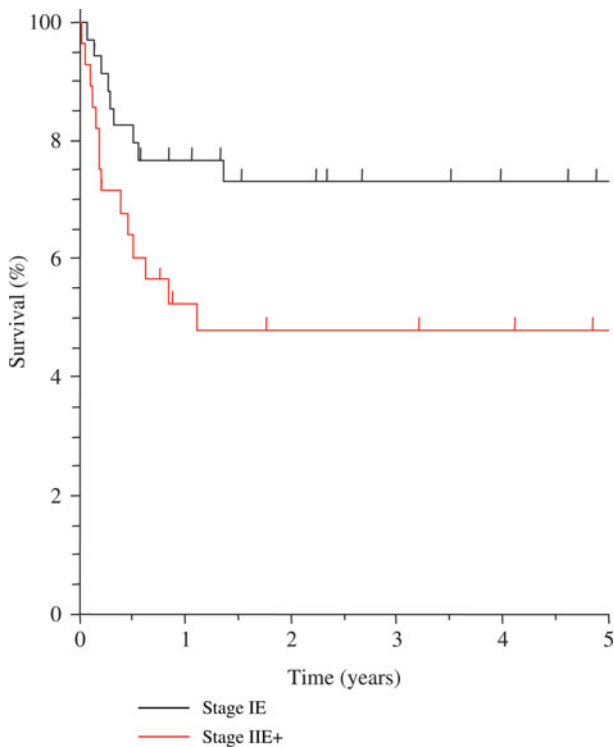


FIG. 2

Patient five-year survival by stage.  $P = 0.06$ , stage IE vs stage IIE+.

The presence of airway symptoms and the need for tracheostomy had no bearing on the patients' overall prognosis.

The type of surgery appeared to be unrelated to survival. Whether patients underwent a total or partial thyroidectomy had no relationship to their overall disease outcome.

Likewise, the presence of Hashimoto's thyroiditis appeared to have no influence on patient survival.

However, treatment with dual modality therapy significantly improved patient survival, compared with treatment with a single modality alone (Figure 3).

**Discussion**

We report a large series of patients with thyroid lymphoma. The majority of published series consist of smaller numbers of patients, or have been carried out over much longer time periods, making the identification of prognostic factors at presentation difficult.

Most patients in our series had a short history of presenting symptoms, usually related to the presence of the mass, which was fixed in 87 per cent of cases. Interestingly, our study findings suggest that only dysphagia is an adverse prognostic factor ( $p = 0.01$ ). This may be related to the thyroid mass size that is necessary to cause swallowing difficulties. However, we did not find that stridor or airway compromise represented a significant adverse event.

A previous, 1992 analysis of 70 Christie Hospital patients managed over 20 years found that stridor, retrosternal extension and fixation were all adverse prognostic signs.<sup>8</sup> It should be noted that, at that time, treatment

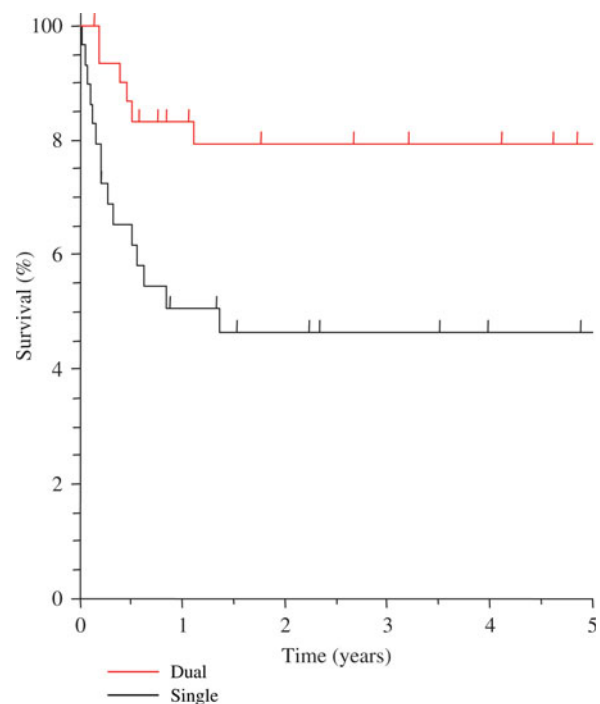


FIG. 3

Patient five-year survival by treatment modality.  $p = 0.014$ , dual vs single modality treatment.

was almost exclusively single modality rather than the combination of radiotherapy and chemotherapy currently recommended for the majority of patients. Thus, treatment improvements may be responsible for the fact that fixation, stridor and retrosternal extension are no longer prognostic factors for poor outcome.

Patients who present with respiratory compromise due to airway obstruction from thyroid lymphoma provide otolaryngologists with a considerable management dilemma. In our series, 13 (12 per cent) patients required an emergency tracheostomy. Reassuringly, the majority of these ( $n = 9$ ) were temporary. Of the four that were permanent, one patient was lost to follow up, and three patients died with their tracheostomy tube in situ within two months of diagnosis.

Thyroid lymphoma patients who present in extremis pose an extremely difficult clinical problem. We know that thyroid lymphoma responds readily to steroids, but these can only be given after enough tissue has been taken for diagnosis and typing. However, it should be emphasised that a tracheostomy can be a life-saving procedure, and if deemed necessary it does not adversely affect the eventual treatment outcome for that individual patient.

The diagnosis of thyroid lymphoma can be problematic when FNAC is unreliable or difficult to interpret.<sup>3</sup> Fine needle aspiration cytology is the first-line diagnostic investigation in any patient with a thyroid mass and, with optimal technical and cytological expertise (e.g. using ultrasound when necessary), lymphoma should be at least suspected<sup>2</sup> in most such cases (e.g. as a differential diagnosis to anaplastic carcinoma). However, treatment regimens are linked to the subtype of lymphoma, and FNAC will not usually give enough information for typing purposes. It is therefore usually necessary to proceed to either Tru-Cut or open biopsy.<sup>10</sup>

In our series, only 17 patients were diagnosed using either Tru-Cut biopsy or FNAC, and this reflects the diversity of the referring hospitals. More radical surgery should not be considered.

Thirty-two (51 per cent) of our patients had either a partial or total thyroidectomy, possibly unnecessarily. As progress is made in the establishment of specialist thyroid services in all geographic areas of the UK, it is hoped that the use of thyroid surgery for diagnostic purposes will decrease (for all diseases). However, the role of specialist cyto-pathologists is crucial to this.

All our cases had pathologically confirmed B-cell non-Hodgkin's lymphoma. As diagnosis of the underlying lymphoma subtype can be difficult, and indeed may change in up to 30 per cent of cases reviewed at specialist centres, it is recommended that all cases should undergo specialist histopathology review and be discussed in a specialist multidisciplinary team setting. In this series, the patients who were treated without histopathological review all presented with very aggressive disease requiring emergency treatment.

Subsequent review after initial treatment confirmed the original diagnosis.

The commonest subtype of thyroid lymphoma is diffuse large B-cell type.<sup>8</sup> Low-grade mucosa-associated lymphoid tissue lymphoma is also common, comprising 6–27 per cent of cases.<sup>2</sup> In our series, there were four definite diagnoses of mucosa-associated lymphoid tissue lymphoma (6 per cent), with a further five possible cases, which if confirmed would have brought the total to nine (14 per cent). It is postulated that this particular subtype has a much better long-term prognosis, approaching 90 per cent survival at five years.<sup>11</sup> In our series, only one of the deaths was in a patient with mucosa-associated lymphoid tissue lymphoma, and this patient was so frail at presentation that she was offered only palliative treatment. Despite this, she died over three years from the date of diagnosis, illustrating the indolent course of this particular thyroid lymphoma subtype. The remaining deaths were all in patients with high-grade diffuse large B-cell disease.

Thyroid lymphoma can arise within a previously abnormal gland. Hashimoto's thyroiditis has been reported to occur in as many as 85 per cent of thyroid lymphoma cases.<sup>3</sup> In the present series, 10 (34 per cent) of the 29 patients with thyroid tissue present in the histopathological specimen had evidence of Hashimoto's thyroiditis. In these patients, no significant survival benefit was conferred by concurrent Hashimoto's thyroiditis. However, since Hashimoto's thyroiditis has a strong association with low-grade lymphoma, such cases may have a better outcome.<sup>7</sup> It should be noted that this entity can later transform into high-grade disease.<sup>4</sup>

A further six patients had evidence of lymphocytic thyroiditis. This condition has also been reported as having an increased probability of malignant transformation to thyroid lymphoma.<sup>12</sup>

In cases of thyroid lymphoma, surgery is used as a diagnostic tool and has no favourable effect on prognosis.<sup>13</sup>

The main treatment modalities for thyroid lymphoma are chemotherapy and radiotherapy (as for other forms of non-Hodgkin's lymphoma). The precise treatment varies depending on the underlying histological subtype. Treatment for high-grade or diffuse large B-cell lymphoma consists of chemotherapy combined with radiotherapy for better loco-regional control.<sup>6</sup> Chemotherapy is anthracycline-based, the most popular regimen being a combination of cyclophosphamide, doxorubicin, vincristine and prednisolone. In more recent years, the addition of rituximab, a monoclonal antibody against cluster of differentiation 20 glycoprotein, which promotes lysis and apoptosis of normal and malignant B-cells as well as sensitising them to chemotherapy, has significantly increased these patients' overall survival.<sup>14</sup> Treatment is then consolidated with radiotherapy to the neck. Dual modality treatment has been shown on numerous occasions to confer greater

survival benefits than single modality treatment.<sup>13</sup> Our study results support these findings.

Low-grade disease is often treated with radiotherapy alone. If surgery has resulted in removal of the entire disease, radiotherapy may be considered unnecessary, and the patient may just be followed up regularly. Radiotherapy for thyroid lymphoma (either high or low grade) uses lower doses than that applied for squamous cell carcinoma of the head and neck. This means that it is associated with much less morbidity during and after treatment.

Thyroid lymphoma treatment can be complicated by the advanced age and consequential co-morbidity of some patients. One study found that age itself was a significant prognostic factor for outcome, and that patients under the age of 65 years fared much better than older patients.<sup>5</sup> Radical anti-cancer treatment produces problems of its own in the elderly, and this must be considered when calculating survival.

In thyroid lymphoma relapse rates of approximately 30% are reported.<sup>3,5,15</sup> In our series, nine patients (14 per cent) relapsed; the relapse was in the neck in only one patient. Low patient numbers make it difficult to analyse factors possibly associated with relapse. Relapse itself did not necessarily imply an adverse long-term outcome, as one-third of relapsed patients went on to become disease-free. Treatment for relapse varied.

- **Thyroid lymphoma is relatively uncommon, resulting in a lack of outcome data**
- **It classically presents as a rapidly enlarging thyroid mass; the main differential diagnosis is anaplastic thyroid cancer**
- **Treatment is with combination chemoradiotherapy; surgery gives no extra treatment benefit**
- **The reported, large series had an overall five-year survival of 62 per cent**
- **Most patients dying of lymphoma did not achieve remission or relapse within six months**

In our patients, the estimated five-year survival rate was 62 per cent. Of those patients who died of lymphoma, 73 per cent did so within six months of diagnosis, and 78 per cent did not achieve remission. This suggests that it is possible to identify those patients with a poor prognosis in the early stages of treatment. Conversely, it also suggests that patients who achieve and maintain complete remission in the first six months after treatment tend to survive long term.

Based on our study findings, we believe that the British Thyroid Association 2007 guidelines for the treatment of thyroid lymphoma should probably be revised, as regards their advice on the prognosis of thyroid lymphoma patients, as patients' overall survival

certainly does not seem to be 'generally excellent'. Our study findings allow diagnosing thyroid surgeons to give their patients some indication of the likely prognosis. Patients who achieve remission and maintain it for six months do indeed appear to have an 'excellent' prognosis.

## Conclusion

The rapidly enlarging thyroid mass presents a diagnostic dilemma for otolaryngologists. Thyroid lymphoma, although rare, has a much more favourable prognosis than the other main differential diagnosis, anaplastic thyroid cancer. The overall estimated survival of thyroid lymphoma patients is in the region of 62 per cent at five years; in contrast, few patients with anaplastic thyroid cancer live beyond six months.

It is of paramount importance that thyroid lymphoma is diagnosed rapidly, and that treatment is initiated at the earliest opportunity. Surgery has no definitive role; however, many patients are still operated upon, which may reflect inadequacies in current diagnostic pathways. Symptomatology should not be a barrier to treatment, as only dysphagia appears to be an adverse prognostic factor, and many patients who present in extremis can still be cured.

## Acknowledgments

We thank Professor John Radford and Dr Richard Cowan, Consultant Medical Oncologists, Christie Hospital, and Mr Ric Swindell, Medical Statistician, Christie Hospital, Manchester.

## References

- 1 Weetman AP. Endocrine disorders – Thyroid cancer. In: Warell DA, Cox TM, Firth JD, Benz EJ, eds. *Oxford Textbook of Medicine*. Oxford: Oxford University Press, 2003;4th Edition, volume 3, pages 225–230
- 2 Widder S, Pasiaka JL. Primary thyroid lymphomas. *Curr Treat Options Oncol* 2004;**5**:307–13
- 3 Pasiaka JL. Hashimoto's disease and thyroid lymphoma: role of the surgeon. *World J Surg* 2000;**24**:966–70
- 4 Scholefield JH, Quayle AR, Harris SC, Talbot CH. Primary lymphoma of the thyroid, the association with Hashimoto's thyroiditis. *Eur J Surg Oncol* 1992;**18**:89–92
- 5 DiBase SJ, Grigsby PW, Guo C, Lin HS, Wasserman TH. Outcome analysis for stage IE and IIE thyroid lymphoma. *Am J Clin Oncol* 2004;**27**:178–84
- 6 Ansell SM, Grant CS, Habermann TM. Primary thyroid lymphoma. *Semin Oncol* 1999;**26**:316–23
- 7 Belal AA, Allam A, Kandil A, El Hussein G, Khafaga Y, Al Rajhi N *et al*. Primary thyroid lymphoma. A retrospective analysis of prognostic factors and treatment outcome for localised intermediate and high-grade lymphoma. *Am J Clin Oncol* 2001;**24**:299–305
- 8 Logue JP, Hale RJ, Stewart AL, Duthie MB, Banerjee SS. Primary malignant lymphoma of the thyroid: a clinicopathological analysis. *Int J Radiat Oncol Biol Phys* 1992;**22**:929–33
- 9 British Thyroid Association, Royal College of Physicians. *Guidelines for the management of thyroid cancer* (Perros P, ed) 2nd edition. Report of the Thyroid Cancer Guidelines Update Group. London: Royal College of Physicians, 2007
- 10 Matsuzuka F, Miyauchi A, Katayama S, Narabayashi I, Ikeda H, Kuma K *et al*. Clinical aspects of primary thyroid lymphoma: diagnosis and treatment based on our experience of 119 cases. *Thyroid* 1993;**3**:93–9
- 11 Laing RW, Hoskin P, Vaughan Hudson B, Vaughan Hudson G, Harmer C, Bennett MH *et al*. The significance of MALT histology in thyroid lymphoma: a review of patients from

- the BNLI and Royal Marsden Hospital. *Clin Oncol* 1994;**6**: 300–4
- 12 Holm L, Blomgren H, Lowhagen T. Cancer risks in patients with chronic lymphocytic thyroiditis. *New Eng J Med* 1985;**312**: 601–4
- 13 Sippel RS, Gauger PG, Angelos P, Thompson NW, Mack E, Chen H. Palliative thyroidectomy for malignant lymphoma of the thyroid. *Ann Surg Oncol* 2002;**9**:907–11
- 14 Cvetkovic RS, Perry CM. Spotlight on rituximab in non-Hodgkin's lymphoma and chronic lymphocytic leukaemia. *BioDrugs* 2006;**20**:253–7
- 15 Doria R, Jekel JF, Cooper DL. Thyroid lymphoma: the case for combined modality therapy. *Cancer* 1994;**73**:200–6

## Address for correspondence:

Miss Susannah Penney,  
University Dept of Otolaryngology – Head and Neck Surgery,  
Manchester Royal Infirmary,  
Oxford Road,  
Manchester M13 9WL, UK

Fax: +44 (0)161 276 5003

E-mail: susannahpenney@btinternet.com

---

Miss S E Penney takes responsibility for the integrity of the  
content of the paper  
Competing interests: None declared

---

# An anatomical study of the myelination of human laryngeal nerves

J C FLEMING<sup>1</sup>, N GIBBINS<sup>1</sup>, P J INGRAM<sup>2</sup>, M HARRIES<sup>1</sup>

<sup>1</sup>ENT Department, Royal Sussex County Hospital, Brighton, and <sup>2</sup>Mathematics Department, Imperial College, London, UK

## Abstract

**Objective:** To determine the differences in myelination between the human recurrent laryngeal nerve and superior laryngeal nerve.

**Methods:** Fifteen confirmed laryngeal nerve specimens were harvested from five cadavers. Cross-sections were examined under a photomicroscope and morphometric analysis performed.

**Results:** There was a significantly greater number of myelinated fibres than unmyelinated fibres, in both the recurrent laryngeal nerve ( $p = 0.018$ ) and the superior laryngeal nerve ( $p = 0.012$ ). There was a significantly greater number of myelinated fibres in the superior laryngeal nerve, compared with the recurrent laryngeal nerve ( $p = 0.028$ ). However, there was no significant difference in the number of unmyelinated fibres, comparing the two nerves ( $p = 0.116$ ).

**Conclusion:** These findings support those of previous studies, and provide further evidence against the historical plexus theory of laryngeal nerve morphology. The differences in the degree of myelination, both within and between the human laryngeal nerves, may have clinical consequence regarding recovery of function following nerve injury.

**Key words:** Larynx; Recurrent Laryngeal Nerve; Laryngeal Nerves; Myelin Sheath; Cadaver; Anatomy

## Introduction

The human larynx is classically described as receiving its nerve supply principally from two vagal branches: the superior laryngeal nerve and the recurrent laryngeal nerve, contributing both motor and sensory innervation.<sup>1</sup>

Early neurophysiological studies demonstrated that most fibres in the superior laryngeal nerve are sensory, innervating the supraglottic mucosa through the internal branch, with a motor supply to the cricothyroid via the external branch.<sup>2,3</sup> These internal branch fibres are predominantly smaller diameter afferent myelin fibres, and those in the external branch are medium diameter efferent fibres.<sup>4,5</sup>

By contrast, the recurrent laryngeal nerve contains both afferent and efferent myelin fibres. It innervates all the intrinsic muscles of the larynx except for the cricothyroid, and supplies sensation to all the subglottic mucosa.<sup>3,6</sup>

In the last century, the so-called plexus theory proposed that the laryngeal nerves were derived from a single plexus within the vagus; thus, a small number

of fibres in the superior laryngeal nerve would be associated with a corresponding high number in the recurrent laryngeal nerve.<sup>7</sup>

Numerous anatomical studies have also identified internal laryngeal anastomoses between the superior laryngeal nerve and recurrent laryngeal nerve. For example, Steiberg *et al.*<sup>8</sup> confirmed that the posterior branch of the laryngeal nerve (one of the extralaryngeal divisions of the recurrent nerve) supplied sensory innervation to the mucosa inferior to the vocal fold and then anastomosed with the internal laryngeal nerve, forming the loop of Galen. This arrangement has also been described in other studies.<sup>9</sup> Such anastomoses may account for the delayed reinnervation of contralateral intrinsic laryngeal muscles following ipsilateral nerve transection. They may also explain the different final position of a paralysed vocal fold (i.e. median, paramedian or lateralised), depending on the degree of synkinesis in different intrinsic laryngeal muscle groups.

The proportions of sensory and motor fibres in the laryngeal nerves are not clearly defined. Few human

studies exist on the neuroanatomy of these nerves, and there has been little investigation of the effects of injury upon axonal populations of both large myelinated fibres and smaller unmyelinated fibres. However, a recent study has demonstrated rapid unmyelinated fibre degeneration following acute injury in the central nervous system of rats, following traumatic brain injury.<sup>10</sup> Therefore, the degree of myelination of the laryngeal nerves could have important prognostic implications for the recovery of laryngeal function and sensation following injury.

Our study aimed to compare the numbers of myelinated versus unmyelinated fibres in the human laryngeal nerves.

### Materials and methods

Cadaveric dissection was performed on five specimens (four fixed, one fresh frozen), by three dissectors of varying otolaryngological experience (one consultant, two registrars).

The superior laryngeal nerve was identified 3 cm from the thyrohyoid membrane, in line with previous studies.<sup>11</sup> The recurrent laryngeal nerve was sampled 4 cm from the lower border of the cricoid cartilage. This harvesting involved two cross-sectional cuts perpendicular to the long axis of the nerve, to obtain a 1 cm specimen. Five nerve samples were lost to analysis: four because previous cadaveric dissections prevented nerve identification, and one because of mistaken vessel identification and harvesting.

Following standard blocking and cutting of the remaining 15 nerve samples, 7 µm thick sections were produced and stained using standard Solochrome R techniques.<sup>12</sup> The first slide from each of these specimens was examined under a Leica photomicroscope system (Leica Microsystems; Wetzlar, Germany), comprising a DM5000B microscope with DFC300FX camera.

Any specimens subsequently found to be non-neurological in nature were discarded.

No further dissection was performed.

Image analysis equipment (Leica Analysis Suite) was then utilised to electronically count both myelinated and unmyelinated nerve fibres in the whole cross-section, under ×40 magnification. An example of such an image is shown in Figure 1. All slides were counted, using analysis software, by two independent, non-blinded counters. The mean of the counts was taken as the final value. If the two researchers' counts differed by more than 10 per cent of the lower total, both parties performed a re-count.

Analysis of results was performed using the Statistical Package for the Social Sciences version 17.0 for Windows software program (SPSS Inc, Chicago, Illinois, USA). The (non-parametric) Wilcoxon signed rank test was utilised for statistical analysis. A *p* value of 0.05 or less was considered significant.

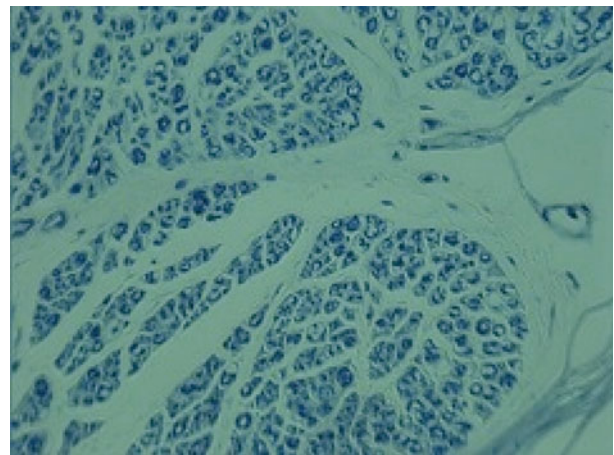


FIG. 1

Photomicrograph of typical cross-section of a right superior laryngeal nerve. (Solochrome R; ×40)

### Results and analysis

Post-mortem cadaveric dissections were performed on five patients aged between 60 and 96 years (mean age 76.8 years, standard deviation (SD) 13.1 years). There was no known history of significant chronic neurological disease or laryngeal disease affecting any of the cadavers. Figures 1 and 2 show typical photomicrographs obtained.

Tables I and II show descriptive data for the subdivided and total nerve counts. The number of fascicles in each nerve section ranged from one to 13 (median three, SD 3.03).

Combining results for both nerves, there was a significant difference in the total number of myelinated versus unmyelinated fibres ( $p = 0.001$ ). Furthermore, subset analyses demonstrated a significantly larger proportion of myelinated fibres, compared with unmyelinated fibres, for both the recurrent laryngeal nerve ( $p = 0.018$ ) and the superior laryngeal nerve ( $p = 0.012$ ).

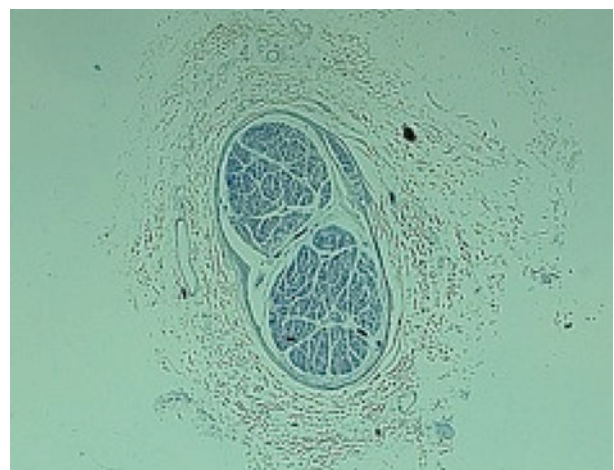


FIG. 2

Photomicrograph of typical cross-section of a right superior laryngeal nerve. (Solochrome R; ×2.5)

TABLE I  
RIGHT LARYNGEAL NERVE DATA

Nerve fibre type	Specimen number (age; years)							
	1 (60)		2 (76)		3 (80)		4 (72)	5 (96)
	RLN	SLN	RLN	SLN	NRLN	SLN	RLN	SLN
Myelinated	2696	11249	2170	3558	1404	1471	852	2279
Unmyelinated	236	548	509	384	120	137	94	186
Total	2932	11797	3942	3942	1524	1608	946	2465

Data represent numbers of nerve fibres. RLN = recurrent laryngeal nerve; SLN = superior laryngeal nerve; NRLN = non-recurrent laryngeal nerve

Comparison between the two nerves identified a significantly greater number of myelinated fibres in the superior laryngeal nerve compared with the recurrent laryngeal nerve ( $p = 0.028$ ). However, there was no significant difference between the numbers of unmyelinated fibres, comparing the two nerves ( $p = 0.116$ ).

## Discussion

Our results demonstrate significantly greater total fibre counts than many previous anatomical studies.

Murtagh and Campbell<sup>13</sup> reported fibre counts in four human recurrent laryngeal nerves, but did not provide information on the level of the sections. The number of myelinated fibres ranged from 1598 to 2891.

Scheur<sup>7</sup> specified the level of sectioning for both internal and recurrent laryngeal nerves in three hemilarynges, finding total fibre counts of 2012, 3646 and 4668, and 1493, 788 and 687, respectively.

A 1986 French study<sup>14</sup> of 100 fresh larynxes demonstrated that the number of fibres per nerve ranged from 511 to 2244, with the number of fascicles ranging from three to 14.

Our findings are more in keeping with those of Tiago and colleagues' recent studies.<sup>11,15</sup> This group described the superior laryngeal nerve as having over double the number of myelinated fibres of the recurrent laryngeal nerve. Our results also concur with this and other studies<sup>14</sup> showing a significantly greater number of myelinated nerves in the superior laryngeal nerve compared with the recurrent laryngeal nerve. However, there is no evidence of a difference between the number of unmyelinated fibres in the two nerves.

This is further evidence against the historical plexus theory, which assumed that high counts in one superior laryngeal nerve would be compensated by low counts in the ipsilateral recurrent laryngeal nerve.<sup>7</sup> Alternatively, in the words of Dilworth, 'these nerves were a plexus [with the] vagus represented by a continuous nerve joining the internal and recurrent nerves and [...] separation from this strand form[ing] the individual nerves of the larynx'.<sup>16</sup>

Interestingly, the greatest number of fibres found in our study was from the cadaver with the youngest age of death (60 years); this was especially so for the superior laryngeal nerve. We accept that this finding represents at most a notable point of interest; however, it does correspond with findings from Tiago and colleagues' studies,<sup>11,15</sup> which clearly demonstrated a significant decrease in the total number of myelin fibres in elderly patients. These authors proposed that this reduction in fibre numbers may be a factor in the impairment of protective reflexes seen in the elderly, increasing the risk of aspiration and resultant pneumonia.

Recent neurophysiological studies have demonstrated a differing response to traumatic injury, with preferential vulnerability of small, unmyelinated axons, which show more dramatic and persistent electrophysiological changes.<sup>10</sup> This implies that this axonal subpopulation is uniquely susceptible to injury; furthermore, the changes observed may influence the potential for recovery.

This is of obvious significance in cases of traumatic injury, and when considering laryngeal nerves and the risk of injury during neck and thyroid surgery. The

TABLE II  
LEFT LARYNGEAL NERVE DATA

Nerve fibre type	Specimen number (age; years)						
	1 (60)		2 (76)		3 (80)		5 (96)
	RLN	SLN	RLN	SLN	RLN	SLN	SLN
Myelinated	1384	9345	267	2882	668	1920	331
Unmyelinated	145	512	42	236	38	123	29
Total	1529	9857	309	3118	706	2043	360

Data represent numbers of nerve fibres. SLN = superior laryngeal nerve; RLN = recurrent laryngeal nerve



significantly greater proportion of myelinated fibres in the laryngeal nerves suggests that they may have greater recovery potential, compared with other nerves with a greater proportion of unmyelinated fibres. More interestingly, in our day-to-day clinical practice we are presented with vocal fold motor deficits much more commonly than laryngeal sensory deficits (although historically this may have been partly a diagnostic problem). This is despite the fact that, during thyroidectomy, the frequency of iatrogenic nerve injury is estimated at between <1 to 8 per cent for the recurrent laryngeal nerve, but 14 to 68 per cent for the external branch of the superior laryngeal nerve.<sup>17</sup>

A combination of electromyography and judicious frequency range testing may hold promise as a more reliable form of diagnosis, compared with laryngoscopic findings. However, until the natural history, treatment and overall significance of superior laryngeal nerve dysfunction is clarified, the degree to which we should be investigating and treating disorders relating to abnormal laryngeal sensory innervations (e.g. chronic cough) is unclear.

Although not examined in this study, the results of the previously cited studies suggest that the greater proportion of myelinated fibres in the superior laryngeal nerve, and the resulting reduced susceptibility to injury, compared with the recurrent laryngeal nerve, may be a possible explanation for the more common presentation of vocal fold paralysis to the otolaryngologist.

We believe that neurophysiological studies on the susceptibility of human laryngeal nerves to injury, and their potential for recovery, are vital in order to elucidate the natural history of laryngeal nerve disease.

Characterisation of the degree of human laryngeal nerve myelination takes on increased importance when discussing options for laryngeal reinnervation surgery. When considering nerve anastomosis techniques, it would seem prudent to use a transfer nerve with similar morphometric and neuroanatomical qualities, especially as there is considerable evidence that reinnervated muscle takes on the characteristics of the donor nerve.<sup>18</sup> The ansa cervicalis is a commonly used donor nerve for laryngeal reinnervation techniques. Although the anatomical variations in this nerve have been extensively investigated, its degree of myelination has not undergone the same level of study. This could have important implications for the success of these surgical techniques.

Published studies of human laryngeal nerve morphology, dating back to the 1950s, have suffered from numerous well documented methodological flaws. As well as the inevitable limitation of the small sample sizes involved in cadaveric studies, a broad range of analytical techniques have been used, ranging from manual counting with printed photographs to automated image analysis. Two notable criticisms of many previous studies are (1) their failure to

report the level of nerve sectioning, and (2) their attempt to compare results from studies with differing data measurement techniques.<sup>19</sup> In the present study, we took a similar approach to Tiago and colleagues<sup>11</sup> regarding definition of nerve sectioning level, based on previous anatomical studies.

More recently, nerve morphometry studies have had the benefit of image analysers and adjunctive software to minimise error. However, there has still been a tendency to use well recognised sampling techniques<sup>20</sup> to estimate fibre frequency. Although steps to reduce error (e.g. margin effect) have often been taken,<sup>15</sup> we believe that the use of such new techniques as image-intensified photographic magnification to calculate a complete nerve count, whilst time-consuming, would ultimately enable more accurate results.

We acknowledge a number of methodological problems in the present study, which need to be addressed in future studies.

- **The plexus theory states that high nerve fibre counts in one superior laryngeal nerve are compensated for by low counts in the ipsilateral recurrent laryngeal nerve**
- **Nerve fibre counts range from 511 to 4668 per laryngeal nerve**
- **There are more myelinated fibres than unmyelinated fibres in both the recurrent and superior laryngeal nerves**
- **There are more myelinated fibres in the superior laryngeal nerve than the recurrent laryngeal nerve**
- **This evidence argues against the plexus theory**

Firstly, the problem of limited sample size, which has affected previous, similar studies, was unfortunately still evident in this study. However, the study method of avoiding sampling by utilising individual fibre counts means that any larger study with a greater sample size would involve significantly more time-consuming data collection.

Secondly, a number of nerve samples were lost in the present study. Whilst the majority were due to previous cadaveric dissection, there was one error of mistaken vessel harvesting. In future, the provision of a light microscope close to the dissecting room, to confirm correct specimen collection, would help prevent this mistake.

## Conclusion

This anatomical study of human laryngeal nerves demonstrated that both the recurrent laryngeal nerve and the superior laryngeal nerve have a significantly greater number of myelinated fibres than unmyelinated fibres. This result adds to the body of evidence arguing

against the historical plexus theory of laryngeal nerve morphology.

In addition, this study demonstrated a significantly greater proportion of myelinated fibres in the superior laryngeal nerve, compared with the recurrent laryngeal nerve. The clinical significance of this finding, in relation to the susceptibility to and recovery from nerve injury, is yet to be determined.

### Acknowledgement

This research was funded by the Voice Research Fund, Royal Sussex County Hospital.

### References

- Wyke BD, Kirchner JA. Neurology of the larynx. In: Hinchcliff R, Harrison D, eds. *Scientific Foundations of Otolaryngology*. London: Heineman, 1976;546–74
- Onodi A. *The Anatomy and Physiology of the Laryngeal Nerves* [in German]. Berlin: Oscar Coblentz Verlag, 1902;35
- Lemere F. Innervation of the larynx II. *Anat Rec* 1932;**54**: 389–407
- Tomasch J, Britton WA. A fibre analysis of the laryngeal nerve supply in man. *Acta Anat* 1955;**23**:386–98
- Domeij S, Carlsoo B, Dahlqvist A, Hellstrom S, Kortopoulos H. Motor and sensory fibers of the superior laryngeal nerve in the rat. A light and electron microscopic study. *Acta Otolaryngol* 1989;**108**:469–77
- Suzuki M, Kirchner JA. Sensory fibers in the recurrent laryngeal nerve. *Ann Otol Rhinol Laryngol* 1969;**78**:21–31
- Scheur JL. Fibre size frequency distribution in normal human laryngeal nerves. *J Anat* 1964;**98**:99–104
- Steinberg J, Khane GJ, Fernandes CMC. Anatomy of the recurrent laryngeal nerve: a redescription. *J Laryngol Otol* 1986;**100**: 919–27
- Nguyen M, Junien-Lavillauroy C, Faure C. Anatomical intra-laryngeal anterior branch study of the recurrent laryngeal nerve. *Surg Rad Anat* 1989;**11**:123–7
- Reeves TM, Phillips LL, Povlishock JT. Myelinated and unmyelinated axons of the corpus callosum differ in vulnerability and functional recovery following traumatic brain injury. *Exp Neurol* 2005;**196**:126–37
- Tiago RS, Pontes PA, Brasil Ode O. Quantitative analysis of myelinated fibers in human laryngeal nerves according to age. *Braz J Otorhinolaryngol* 2008;**74**:45–52
- Clark G. Staining with chromoxane cyanine R. *Stain Technol* 1979;**54**:6
- Murtagh JA, Campbell CJ. The respiratory function of the larynx. III. The relation of fibre size to function in the recurrent laryngeal nerve. *Laryngoscope* 1951;**61**:581–90
- Germain MA, Trotoux J, Bruneau X. The laryngeal nerves: histomorphometric study and mapping [in French]. *Ann Otolaryngol Chir Cervicofac* 1986;**103**:379–88
- Tiago R, Pontes P, do Brasil OC. Age-related changes in human laryngeal nerves. *Otolaryngol Head Neck Surg* 2007;**136**: 747–51
- Dilworth TFM. The nerves of the human larynx. *J Anat* 1921; **56**:48–52
- Kierner AC, Aigner M, Burian M. The external branch of the superior laryngeal nerve: its topographical anatomy as related to surgery of the neck. *Arch Otolaryngol Head Neck Surg* 1998;**124**:301–3
- Hengerer AS, Tucher HM. Restoration of abduction in the paralyzed canine vocal cord. *Arch Otolaryngol* 1973;**97**:247–50
- Harrison DFN. Detailed morphology. In: *The Anatomy and Physiology of the Human Larynx*. Cambridge: Cambridge University Press, 1995:48–185
- Mayhew TM, Sharma AK. Sampling schemes for estimating nerve fibre size. I. Methods for nerve trunks of mixed fascicularity. *J Anat* 1984;**139**:45–58

Address for correspondence:

Mr J C Fleming,  
Specialty Registrar,  
ENT Department,  
Royal Sussex County Hospital,  
Eastern Road, Brighton BN2 5BE, UK

E-mail: JCFleming@doctors.net.uk

---

Mr J C Fleming takes responsibility for the integrity of the content of the paper  
Competing interests: None declared

---

## Infected tracheocele (acquired tracheal diverticulum): case report and literature review

B M TEH, C HALL, S KLEID

*Department of Otolaryngology, Head and Neck Surgery, Western Health Melbourne, Victoria, Australia*

### Abstract

**Background:** Paratracheal air-filled cysts are rare. Tracheocele or acquired tracheal diverticulum is the term given to these acquired abnormalities, which usually arise in adults. The majority is asymptomatic, being discovered as incidental findings on radiological imaging.

**Methods:** We report the case of a 72-year-old man with a previously identified tracheocele which became symptomatic following an upper respiratory tract infection. A literature is presented and nomenclature is discussed.

**Results:** The clinical presentation, differential diagnosis and management of paratracheal air-filled cysts are discussed.

**Conclusion:** While most of these rare abnormalities are discovered incidentally, this case illustrates the fact that significant symptoms can develop; excision should therefore be considered.

**Key words:** Trachea; Diverticulum; Cysts; Diagnosis

### Introduction

Air-containing cysts in the paratracheal region were first described in 1838 by Rokitansky as retention cysts of the mucous glands.<sup>1</sup> These cysts are usually found incidentally on chest imaging and are managed conservatively. Their incidence has been reported as 1 per cent on autopsy<sup>2</sup> and 0.75–2 per cent on computed tomography (CT) imaging.<sup>3,4</sup> They have also been reported on fibre-optic bronchoscopy in 0.3 per cent of children aged over 10 years.<sup>5</sup>

As with many rare clinical entities, numerous terms have been used to describe these lesions over the years. These include paratracheal air cyst, tracheal diverticulum, tracheal diverticulosis, intratracheal diverticulum, bronchogenic cyst, aerocoele, bronchocoele and aerial goitre (air-goitre).

By recent convention, the term tracheocele has become synonymous with acquired tracheal diverticulum.

We present the case of a 72-year-old man with an acquired tracheal diverticulum.

### Case report

A 72-year-old Indian man presented with an eight-week history of right lower neck pain and cough productive of yellow sputum. He also complained of night sweats, low-grade fever, weight loss (6 kg in two months) and loss of appetite. His past medical history included chronic obstructive pulmonary disease (COPD), myocardial infarction, a cerebrovascular event and gastroesophageal reflux disease. He had been an ex-smoker for 40 years but had a previous 120 pack-year history.

On examination, there was an expansile mass arising from the right supraclavicular fossa, which increased in size when

the patient performed the Valsava manoeuvre. This sign has been previously described in a case of air-goitre.<sup>6</sup>

Five years previously, during a hospital admission for gastroenteritis, a routine chest radiograph and subsequent CT scan had demonstrated an air cyst in the right upper mediastinum (3.6 × 2.7 × 2.5 cm). The cyst had been seen to cause some displacement of surrounding structures (trachea, right subclavian vessels and common carotid arteries) but otherwise had not displayed any adverse features. The remaining lung fields had been mildly hyper-inflated, with appearances consistent with COPD, but had no other significant abnormalities. Subsequent investigation with flexible nasendoscopy and formal bronchoscopy had failed to reveal any abnormalities. The air cyst had been considered an incidental finding and thus ignored.

During the current presentation, a repeated chest CT scan (Figure 1) demonstrated that the lesion had increased in size, to 4.1 × 3.4 × 4.8 cm. An air–fluid level was now apparent within the cyst. In the lung fields, non-specific pulmonary nodules were seen in the right upper lobe and left lower lobe, together with scarring of the right middle lobe. Other investigations included negative sputum microscopy and microbiological culture (including mycobacterial culture). Arterial blood gases were normal.

The patient's clinical symptoms had initially responded to a short course of antibiotics.

Micro-laryngobronchoscopy demonstrated one tract and two further indentations in the posterolateral aspect of the upper trachea at the junction of the trachealis muscle and tracheal cartilages (Figure 2). Pharyngoesophagoscopy was normal.

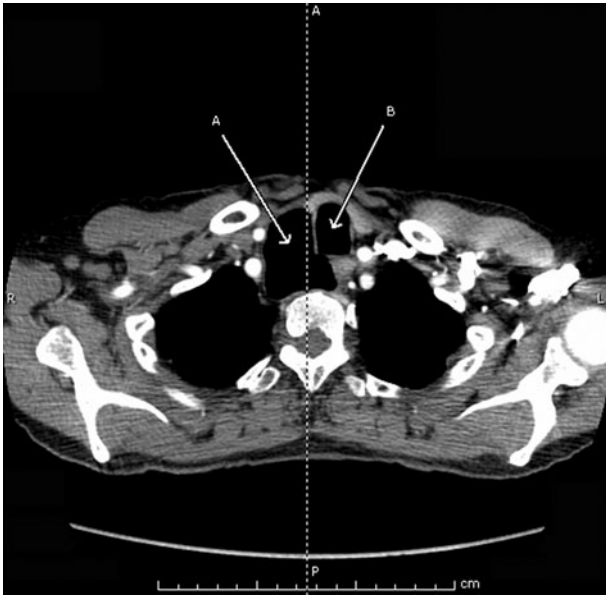

FIG. 1

Typical axial computed tomography appearance of a tracheocele (A) as a thin-walled cyst in the right paratracheal region (trachea is shown as B). The absence of cartilage within the wall differentiates it from a congenital diverticulum. A = anterior; R = right; L = left; P = posterior

Two days after endoscopy, the patient re-presented with a further significant episode of fever, this time with odynophagia. A repeated CT excluded any post-operative complication. In light of his persistent and recurrent symptoms, a decision was made to undertake surgical resection.

Surgery was performed under general anaesthesia, via a right collar neck incision. The inferior thyroid vessels were ligated and the right lobe of the thyroid mobilised to expose the paratracheal region. The cyst was identified (Figure 3) and a capsular dissection performed. Two fibrous connections to the posterolateral aspect of the trachea were identified and ligated. The recurrent laryngeal

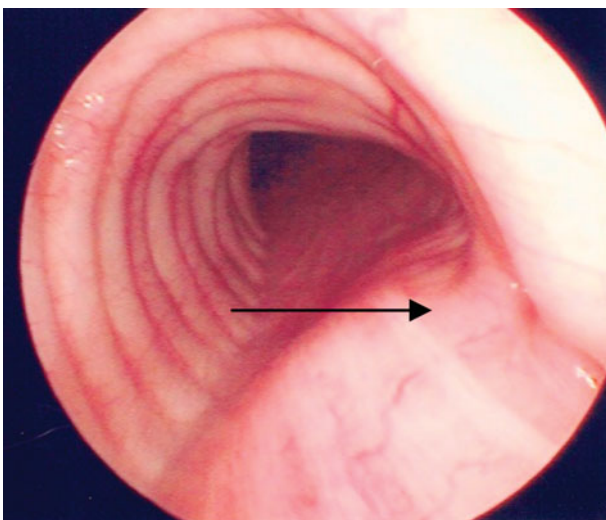


FIG. 2

Endoscopic view showing indentations (black arrow) representing an unusually narrow connection between trachea and tracheocele.

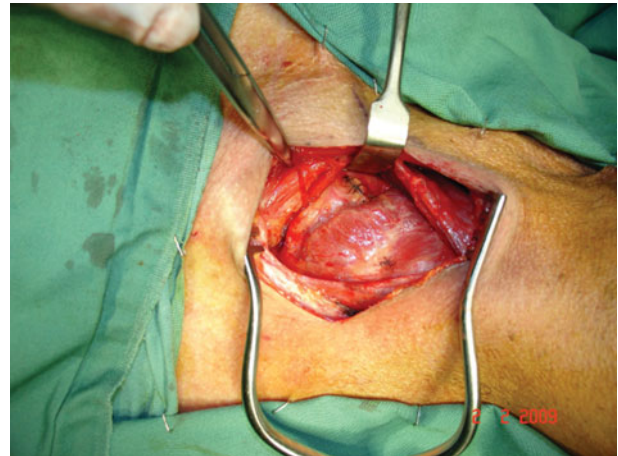


FIG. 3

Operative view showing a thin-walled cyst identified during surgical resection.

nerve was identified, intimately related to the deep surface of the cyst, and was preserved.

The post-operative period was complicated by a temporary ipsilateral recurrent laryngeal nerve palsy, which resolved over nine months.

Histologically, the specimen consisted of a simple cyst lined by ciliated columnar epithelium, with a fibrous tissue wall up to 2 mm thick containing small foci of smooth muscle. The lumen was filled with frothy mucus.

## Discussion

We performed a literature review of all English language reports describing paratracheal air-filled abnormalities in adults (Table I). Changing trends in nomenclature made accurate comparison of cases difficult. We therefore separated cases into four groups according to the original description: tracheocele, tracheal diverticulum, congenital tracheal diverticulum and others (predominantly tracheal diverticulosis). We identified 18 cases described as tracheocele, 18 as tracheal diverticulum and five as congenital tracheal diverticulum; a further 14 we grouped together as 'other'.

By recent convention,<sup>30,40</sup> those lesions are now defined as tracheal diverticula and sub-divided into congenital or acquired lesions (See Table II).

Acquired tracheal diverticula are true diverticula resulting from mucosal herniation through weak points, most commonly in the right posterolateral trachea (98 per cent) and usually at the level of the thoracic inlet. They are thin-walled and consist of normal respiratory epithelium on a narrow layer of fibrous stroma. These lesions were previously commonly referred to as tracheoceleles.

A congenital tracheal diverticulum represents a malformed, vestigial, supernumerary budding of the trachea.<sup>51</sup> The wall of a congenital diverticulum is similar to the wall of the trachea, containing smooth muscle fibres, cartilage and respiratory epithelium. While congenital tracheal diverticula may occur in isolation, their embryological origins mean they are more likely to occur in association with other upper aerodigestive tract anomalies. These include Mounier-Kuhn disease (congenital dilatation of the trachea and bronchi),<sup>46</sup> tracheoesophageal fistula<sup>52</sup> and tracheobronchomegaly.<sup>40</sup>

TABLE I  
PREVIOUS ENGLISH-LANGUAGE REPORTS OF PARATRACHEAL AIR-FILLED ABNORMALITIES IN ADULTS\*

Study	Pt age (y) + sex	Description	Presentation	Surgical approach
<i>Tracheocele</i>				
Addington <i>et al.</i> <sup>7</sup>	32M	Tracheocele	Choking, coughing, SOB	Nil
Andersen <i>et al.</i> <sup>8</sup>	52M	Tracheocele	Cough productive of large amount of purulent sputum	Sternotomy
Sullivan & Mangiardi <sup>9</sup>	59F	Tracheocele	Chronic, recurrent, productive cough	Left lateral thoracotomy
Gronner & Trevino <sup>6</sup>	59F	Tracheocele	Hoarseness	Total laryngectomy & neck dissection (for concurrent laryngeal SCC)
Scholl <sup>10</sup>	79F	Tracheocele	Globus sensation	Nil
Moller <i>et al.</i> <sup>11</sup>	90F	Tracheocele	Difficult intubation	Nil
Henderson <i>et al.</i> <sup>12</sup>	50F	Tracheocele	During tracheostomy for trauma	Oversewing of communication with trachea
Mathur <i>et al.</i> <sup>13</sup>	50M	Tracheocele	Progressive right neck swelling	Y-shaped neck incision
Grassi <i>et al.</i> <sup>14</sup>	44M	Tracheocele	Pain in anterior neck	Nil
	74M	Tracheocele	Coughing paroxysms & recurrent chills	Nil
	86M	Tracheocele	Acute respiratory infection	Nil
Piazza <i>et al.</i> <sup>15</sup>	27M	Tracheocele	Left paratracheal swelling noticed during assisted ventilation	Nil
Endo <i>et al.</i> <sup>16</sup>	78F	Tracheocele	Cough, neck irritability; incidental finding on pre-operative CT for hemithyroidectomy	Neck collar incision prior to hemithyroidectomy
Porubsky & Gourin <sup>17</sup>	58M	Tracheocele	Intermittent productive cough, dysphagia, worsening dyspnoea	Transverse cervical approach
Teker <i>et al.</i> <sup>18</sup>	67M	Tracheocele	Pain & swelling to right of clavicle	Resection of cyst then repair of posterior tracheal wall
Shah <i>et al.</i> <sup>19</sup>	50F	Tracheocele	Neck swelling, pulling sensation, intermittent hoarseness & SOB	Nil
Danielson <i>et al.</i> <sup>20</sup>	81M	Tracheocele	Chronic cough following retropharyngeal abscess	Nil
Yazkan <i>et al.</i> <sup>21</sup>	66M	Tracheocele	Intermittent chest pain aggravated by exercise	Nil
<i>Tracheal diverticulum</i>				
Nielsen <sup>22</sup>	51M	Tracheal diverticulum	Recurrent lung infections, copious expectoration decreased after postural drainage	Nil
Surprenant & O'Loughlin <sup>23</sup>	28M	Tracheal diverticulum	Right frontal headache, rhinitis, productive cough, fever & chest pain (tracheobronchomegaly)	Nil
Infante <i>et al.</i> <sup>24</sup>	59M	Tracheal diverticulum	Chronic productive cough, coughing fits, stridor	Right lateral cervicotomy
Caversaccio <i>et al.</i> <sup>25</sup>	70F	Tracheal diverticulum	Severe dyspnoea, stridor, dysphagia, recurrent laryngeal nerve paralysis	Nil
Davies <sup>26</sup>	77F	Tracheal diverticulum	Difficult tracheal intubation	Nil
Ching <i>et al.</i> <sup>27</sup>	67M	Tracheal diverticulum	Difficult lung isolation during intubation	Nil
Rahalkar <i>et al.</i> <sup>28</sup>	47F	Tracheal diverticulum	Chronic cough, dysphonia	Nil
Narimatsu <i>et al.</i> <sup>29</sup>	59M	Tracheal diverticulum	Incidental finding on CT post-trauma	Nil
Soto-Hurtado <i>et al.</i> <sup>3</sup>	49M	Tracheal diverticulum	Incidental finding on CXR	Nil
	63F	Tracheal diverticulum	Haemoptysis	Nil
Ampollini <i>et al.</i> <sup>31</sup>	77M	Tracheal diverticulum	Incidental findings on CT	Nil
Modrykamien <i>et al.</i> <sup>32</sup>	45F	Tracheal diverticula	Fever, productive cough, constitutional symptoms (history of cystic fibrosis)	Bilateral lung transplant, tracheal diverticulum managed conservatively
Han <i>et al.</i> <sup>33</sup>	50M	Tracheal diverticulum	Mild dysphagia, sensation of friction	Right semi-collar incision
Kokkonouzis <i>et al.</i> <sup>34</sup>	62M	Tracheal diverticulum	Chronic cough	Nil
Morgan <i>et al.</i> <sup>35</sup>	40M	Tracheal diverticulum (paratracheal air collection)	Incidental finding on CXR & CT post-trauma	Nil
Pinot <i>et al.</i> <sup>36</sup>	34M	Acquired tracheal diverticulum	Productive cough, haemoptysis	Nil
Haghi <i>et al.</i> <sup>37</sup>	72M	Tracheal diverticulum (paratracheal air cyst)	Productive cough, haemoptysis, exertional dyspnoea	Nil
Sato <i>et al.</i> <sup>38</sup>	65F	Tracheal diverticulum (paratracheal air cyst)	Throat & neck pain	Nil
<i>Congenital tracheal diverticulum</i>				
Peytz <sup>39</sup>	50M	Congenital tracheal diverticulum	Severe cough	Nil
Sharma <sup>40</sup>	50F	Tracheal diverticulum	Incidental finding on CXR	Nil
	55F	Tracheal diverticulum	Incidental finding on CXR	Nil
	35F	Tracheal diverticulum	Incidental finding on CXR post-trauma	Nil

Continued

Table I *Continued*

Study	Pt age (y) + sex	Description	Presentation	Surgical approach
Oizumi <i>et al.</i> <sup>41</sup>	66M	Congenital bronchial diverticulum	Positional localised wheezing	Nil
<i>Other</i>				
Morlock & Pinchin <sup>42</sup>	50M	Bronchial diverticulosis	Productive cough	Nil
Goldman & Wilson <sup>43</sup>	43M	Tracheal diverticulosis	'Chicken bone in throat', chronic non-productive cough	Foreign body removed, tracheal diverticulosis managed conservatively
Ettman & Keel <sup>44</sup>	40M	Tracheal diverticulosis	Acute respiratory infection	Nil
	32M	Tracheal diverticulosis	Productive cough, fever, SOB	Nil
	43M	Tracheal diverticulosis	Productive cough, SOB on exertion	Nil
Collins & Wight <sup>45</sup>	67F	Posterior tracheal wall diverticula (both pts)	Incidental finding during total laryngectomy (both pts)	Nil
	50M			Nil
Lazzarini de Oliveira <i>et al.</i> <sup>46</sup>	38M	Tracheal diverticulosis	Chronic productive cough (Tracheomegaly, bronchiectasis)	Nil
Kim <i>et al.</i> <sup>47</sup>	43F	Paratracheal air cyst	Incidental finding on neck US	Nil
	65M	Paratracheal air cyst	Anterior neck pain	Nil
Saito <i>et al.</i> <sup>48</sup>	74M	Tracheobronchial diverticula	Productive cough, right middle lobe atelectasis	Nil
Levin <i>et al.</i> <sup>49</sup>	19M	Tracheal diverticulosis	Worsening SOB & productive cough in congenital HIV pt	Nil
Hernández Pérez <i>et al.</i> <sup>50</sup>	44M	Intratracheal diverticulum	Dyspnoea, cough, haemoptysis, stridor	Nil
Sharma <sup>40</sup>	20M	Tracheal diverticulosis	Cough, dyspnoea, fever (congenital tracheobronchomegaly)	Nil

\*Older than 18 years. Pt = patient; y = years; M = male; F = female; SOB = shortness of breath; SCC = squamous cell carcinoma; CT = computed tomography; CXR = chest X-ray; US = ultrasound; HIV = human immunodeficiency virus

TABLE II  
DISTINGUISHING FEATURES OF CONGENITAL AND ACQUIRED TRACHEAL DIVERTICULA

Parameter	Congenital tracheal diverticulum	Acquired tracheal diverticulum*
Aetiology	Congenital developmental defect	Acquired mucosal herniation usually associated with raised intra-luminal pressure
Size	Small	Large
Site	Posterior (4–5 cm below carina)	Right posterolateral (thoracic inlet)
Structure	Multiple sacs Narrow communication	Single sac Wide communication
Histology	Complete tracheal anatomy (respiratory epithelium, smooth muscle & cartilage)	Thin-walled, fibrous cyst lined with normal respiratory epithelium
Contents	Mucus	Predominantly air-filled
Associated conditions	Tracheoesophageal fistula	Chronic obstructive airway disease

\*Also known as tracheocoele

Tracheal diverticula have also been reported in association with: tracheiectasis (dilatation of the trachea with multiple small herniations of the membranous portion of the trachea),<sup>8</sup> congenital human immunodeficiency virus infection,<sup>49</sup> cystic fibrosis<sup>32</sup> and Duchenne muscular dystrophy.<sup>15</sup>

Other air-filled abnormalities can occur at the thoracic inlet. The differential diagnosis includes lymphoepithelial cyst, bronchogenic cyst, laryngocoele, pharyngocoele, Zenker's diverticulum, pneumomediastinum, apical hernia of the lung, and apical paraseptal blebs or bullae.<sup>4,18,30</sup>

Acquired tracheal diverticula are thought to occur as a result of a persistently raised intratracheal pressure associated with chronic respiratory conditions. They occur in pre-existing areas of potential weakness in the posterolateral tracheal wall between the tracheal cartilage and trachealis muscle. They occur almost exclusively on the right side, probably due to the relative positions of the trachea and oesophagus on the left. Previous reports suggest that they should have relatively wide connections to the trachea, compared with congenital diverticula; however, this was not the case in our patient.

It is likely that the majority of cases are asymptomatic, being discovered incidentally on routine radiological investigation, including X-ray,<sup>30,40</sup> CT<sup>16,31</sup> and ultrasound.<sup>47</sup> Most reported cases are symptomatic, usually due to a local mass effect and direct compression, resulting in cough, dyspnoea, stridor, dysphagia, and chest, neck and/or right clavicular pain. Symptoms can also arise due to vagal irritation (resulting in cough, dysphonia or vocal fold paralysis) or alternatively due to retained secretions (serving as a reservoir of chronic infection) or recurrent irritation of the upper airways. Tracheal diverticula have also been found incidentally during tracheostomy,<sup>12</sup> laryngectomy,<sup>45</sup> difficult intubation,<sup>11,26,27</sup> and following trauma.<sup>40,29,35</sup>

CT scanning has been shown to be the most effective method for evaluating the presence and features of tracheal diverticula.<sup>53</sup> In most cases, a CT scan and barium swallow will exclude the differential diagnoses listed above.

Previous authors have suggested that surgery is only indicated in young, symptomatic patients in whom conservative measures (e.g. antibiotics, mucolytics and physiotherapy) have been unsuccessful. The current case demonstrates that asymptomatic lesions can become problematic over time. It also demonstrates that age and other pre-existing co-morbidities should not be considered as absolute contraindications to surgery.

- **Tracheal diverticulum is a rare anomaly of the tracheobronchial tree**
- **The nomenclature describing paratracheal air cysts is confusing**
- **Such lesions are now divided into congenital and acquired tracheal diverticula (the latter also known as tracheoceles); these subtypes have different aetiologies and characteristics**
- **This case report illustrates the necessity of surgical resection in cases of symptomatic tracheal diverticulum**

Where surgery is considered, the most commonly described approach is resection via a transverse or lateral neck incision.<sup>17,24</sup> Other reported options have included fulguration,<sup>54</sup> endoscopic cauterisation with laser or electrocoagulation,<sup>30,32</sup> and endoscopic division with biopsy forceps.<sup>55</sup>

## Conclusion

Most of the cases identified in our literature review, other than those reported as congenital tracheal diverticula, probably represent similar clinical entities. However, an inconsistent approach to the naming of these lesions makes accurate comparison of previously reported cases difficult. With regards to the clinical management, it is important to identify congenital lesions so that associated abnormalities can be investigated and managed appropriately. For the remaining acquired lesions, any further sub-classification has little bearing on clinical decision-making. We would therefore advocate the simple classification of cases into congenital or acquired lesions. For acquired lesions, surgery should be considered in symptomatic cases in which simple medical treatment options have been unsuccessful.

## References

- 1 Rokitsky K. On the diverticulum similar to the dilatation of the trachea [in German]. *Med Jahrb Kais Königl Ost St* 1838; **16**:374–84
- 2 MacKinnon D. Tracheal diverticula. *J Pathol Bacteriol* 1953; **65**: 513–17
- 3 Mineshita M, Tajima O, Kondo T. Paratracheal air cysts in middle-aged Japanese men. *J Bronchol Intervent Pulm* 2006; **13**:6–8
- 4 Goo J, Im J, Ahn J, Moon W, Chung J, Park J *et al*. Right paratracheal air cysts in the thoracic inlet: clinical and radiologic significance. *Am J Roentgenol* 1999; **173**:65–70
- 5 Abramovic M, Zoric M. Abnormalities and variations of the tracheo-bronchial trunk. *Bronches* 1974; **24**:341–9
- 6 Gronner A, Trevino R. Tracheocele. *Br J Radiol* 1971; **44**: 979–81
- 7 Addington E, Rusk P, Cohen W. Tracheocele. *Am J Roentgenol* 1944; **52**:412–14
- 8 Andersen H, Clagett O, Good C. Tracheiectasis with tracheocele: report of case in which a tracheocele was resected. *Chest* 1953; **24**:553–7
- 9 Sullivan J Jr, Mangiardi J. Acquired tracheocele: an unusual lesion. Surgical resection in a case associated with tracheiectasis and bronchiectasis. *J Thorac Cardiovasc Surg* 1960; **39**: 597–601
- 10 Scholl P. Adult tracheocele. *Otolaryngol Head Neck Surg* 1994; **111**:519–21
- 11 Möller G, Ten Berge E, Stassen C. Tracheocele: a rare cause of difficult endotracheal intubation and subsequent pneumomediastinum. *Eur Respir J* 1994; **7**:1376–7
- 12 Henderson C, Harrington R, Izenberg S, Dyess D, Silver F. Tracheocele after routine tracheostomy. *Otolaryngol Head Neck Surg* 1995; **113**:489–90
- 13 Mathur N, Sardana P, Singh V, Bais A. Adult tracheocele with large cervical presentation. *J Laryngol Otol* 1999; **113**:364–5
- 14 Grassi R, Rea G, Scaglione M, Brunese L, Scialpi M. Imaging of tracheocele: report of three cases and review of the literature. *Radiol Med (Torino)* 2000; **100**:285–7
- 15 Piazza C, Bolzoni A, Cavaliere S, Peretti G. Tracheocele in a Duchenne muscular dystrophy patient. Case report. *Acta Otorhinolaryngol Ital* 2003; **23**:194–8
- 16 Endo S, Saito N, Hasegawa T, Sato Y, Sohara Y. Tracheocele: surgical and thoracoscopic findings. *Ann Thorac Surg* 2005; **79**:686–7
- 17 Porubsky E, Gourin C. Surgical treatment of acquired tracheocele. *Ear Nose Throat J* 2006; **85**:386–7
- 18 Tekler A, Lorenz R, Lee W, Murthy S. Radiology quiz case 1. Diagnosis: tracheocele. *Arch Otolaryngol Head Neck Surg* 2007; **133**:940, 942–3
- 19 Shah R, Parikh S, Johns M. Radiological quiz case 1. Diagnosis: tracheocele in PubMed. *Arch Otolaryngol Head Neck Surg* 2007; **133**:724, 726
- 20 Danielson G, Jedlovsky V, Landrigan G. Tracheal diverticulum: a rare finding in a patient with worsening chronic cough. *Ear Nose Throat J* 2008; **87**:474–5
- 21 Yazkan R, Özpölat B, Firat H. Tracheocele; a case of rare clinical entity. *Tuberk Toraks* 2008; **56**:315–18
- 22 Nielsen K. A case of multiple tracheal diverticula. *Acta Radiol* 1948; **29**:331–4
- 23 Surprenant E, O'Loughlin B. Tracheal diverticula and tracheobronchomegaly. *Dis Chest* 1966; **49**:345–51
- 24 Infante M, Mattavelli F, Valente M, Alloisio M, Preda F, Ravasi G. Tracheal diverticulum: a rare cause and consequence of chronic cough: case report. *Eur J Surg* 1994; **160**:315–16
- 25 Caversaccio M, Becker M, Zbären P. Tracheal diverticulum presenting with recurrent laryngeal nerve paralysis. *Ann Otol Rhinol Laryngol* 1998; **107**:362–4
- 26 Davies R. Difficult tracheal intubation secondary to a tracheal diverticulum and a 90 degree deviation in the trachea. *Anaesthesia* 2000; **55**:923–5
- 27 Ching S, Chow M, Ng H. Difficult lung isolation in a patient with an undiagnosed tracheal diverticulum. *J Cardiothorac Vasc Anesth* 2003; **17**:355–6
- 28 Rahalkar M, Lakhkar D, Joshi S, Gundawar S. Tracheal diverticula-report of 2 cases. *Indian J Radiol Imaging* 2004; **14**:197–8
- 29 Narimatsu E, Yama N, Danjoh W, Kurimoto Y, Asai Y. A paratracheal cystic lesion in a patient with potential high-energy trauma. *J Emerg Med* 2005; **28**:333–5
- 30 Soto-Hurtado E, Penuela-Ruiz L, Rivera-Sánchez I, Torres-Jimenez J. Tracheal diverticulum: a review of the literature. *Lung* 2006; **184**:303–7
- 31 Ampollini L, Bobbio A, Carbognani P, Rusca M. Incidental radiological finding of tracheal diverticulum. *Eur J Cardiothorac Surg* 2007; **31**:545
- 32 Modrykamien A, Abdallah R, Kanne J, Mehta A. Multiple tracheal diverticuli in a cystic fibrosis patient. *J Bronchol Intervent Pulm* 2008; **15**:194–6
- 33 Han S, Dikmen E, Aydin S, Yapakci O. Tracheal diverticulum: a rare cause of dysphagia. *Eur J Cardiothorac Surg* 2008; **34**: 916–17
- 34 Kokkonouzis I, Haramis D, Kornezos I, Moschouris H, Katsenos S, Bouchara S. Tracheal diverticulum in an asymptomatic male: a case report. *Cases J* 2008; **1**:181
- 35 Morgan J, Perone R, Yeghiayan P. Paratracheal air collection in a trauma patient: a case report. *Clin Imaging* 2009; **33**:67–9
- 36 Pinot D, Breen D, Peloni J, Gaubert J, Dutau H, Vervloet D. An incidental finding in a 34-year-old male under investigation for haemoptysis. *Eur Respir J* 2009; **33**:1227–9
- 37 Haghi Z, Towhidi M, Fattahi H, Lari S. Right paratracheal air cyst (tracheal diverticulum). *Respir Care* 2009; **54**:1409–11

- 38 Sato T, Sasaki Y, Yamasaki M, Aragaki M, Mae S, Irie T *et al.* A right paratracheal air cyst caused by tracheal diverticula. *Intern Med* 2010;**49**:315–19
- 39 Peytz F. Congenital tracheal diverticulum. *Acta Otolaryngol (Stockh)* 1964;**58**:81–6
- 40 Sharma B. Tracheal diverticulum: a report of 4 cases. *Ear Nose Throat J* 2009;**88**:E11
- 41 Oizumi S, Ishida T, Kamachi M, Takahashi T, Ogura S, Munakata M *et al.* Congenital bronchial diverticulum. *J Bronchol Intervent Pulm* 1999;**6**:101–3
- 42 Morlock H, Pinchin S. Bronchial diverticulosis. *Lancet* 1933;**222**:236–7
- 43 Goldman L, Wilson J. Tracheal diverticulosis. *Arch Otolaryngol Head Neck Surg* 1957;**65**:554–7
- 44 Ettman I, Keel D Jr. Tracheal diverticulosis. *Radiology* 1962;**78**:187–91
- 45 Collins M, Wight R. Posterior tracheal wall diverticula – an unexpected finding. *J Laryngol Otol* 1997;**111**:663–5
- 46 Lazzarini de Oliveira L, de Barros Franco C, de Salles C, de Oliveira A. A 38-year-old man with tracheomegaly, tracheal diverticulosis, and bronchiectasis. *Chest* 2001;**120**:1018–20
- 47 Kim Y, Kim E, Kim J, Park C. Paratracheal air cysts: sonographic findings in two cases. *Korean J Radiol* 2003;**4**:136–9
- 48 Saito W, Kobayashi H, Motoyoshi K. A case of tracheobronchial diverticula. *J Bronchol Intervent Pulm* 2003;**10**:48–50
- 49 Levin T, Weingart L, Adam H, Vicencio A. Congenital HIV and tracheal diverticulosis. *Am J Roentgenol* 2004;**183**:1115–16
- 50 Hernández Pérez J, Negrín L, Batista Martín J, Hernández F. Intratracheal diverticulum. *J Bronchol Intervent Pulm* 2005;**12**:104–5
- 51 Boyden EA. Developmental anomalies of the lungs. *Am J Surg* 1955;**89**:79–89
- 52 Dinner M, Ward R, Yun E. Ventilation difficulty secondary to a tracheal diverticulum. *Anesthesiology* 1992;**77**:586–7
- 53 Polverosi R, Carloni A, Poletti V. Tracheal and main bronchial diverticula: the role of CT. *Radiol Med (Torino)* 2008;**113**:181–9
- 54 Early E, Bothwell M. Congenital tracheal diverticulum. *Otolaryngol Head Neck Surg* 2002;**127**:119–21
- 55 Johnson L, Cotton R, Rutter M. Management of symptomatic tracheal pouches. *Int J Pediatr Otorhinolaryngol* 2007;**71**:527–31

Address for correspondence:

Dr Bing Mei Teh,  
School of Surgery,  
University of Western Australia,  
M507, 35 Stirling Highway,  
Crawley, Western Australia,  
Australia 6009

Fax: +61 (08)93464374  
E-mail: bm\_teh@yahoo.co.uk

---

Dr B M Teh takes responsibility for the integrity of the content of the paper  
Competing interests: None declared

---



# Coblation for epistaxis management in patients with hereditary haemorrhagic telangiectasia: a multicentre case series

H JOSHI<sup>1</sup>, B A WOODWORTH<sup>2,3</sup>, A S CARNEY<sup>1</sup>

<sup>1</sup>Department of Otolaryngology – Head and Neck Surgery, Flinders Medical Centre and Flinders University, Adelaide, South Australia, Australia, <sup>2</sup>Division of Otolaryngology, Department of Surgery, and <sup>3</sup>Gregory Fleming James Cystic Fibrosis Research Center, University of Alabama at Birmingham, Alabama, USA

## Abstract

**Objective:** To propose radiofrequency coblation as a potential treatment modality for mild to moderate epistaxis in patients with hereditary haemorrhagic telangiectasia.

**Method:** Case reports and review of the world literature concerning coblation and other treatment modalities for epistaxis in patients with hereditary haemorrhagic telangiectasia.

**Results:** Effective epistaxis control was achieved in four out of five cases of hereditary haemorrhagic telangiectasia. In the fifth case, we struggled to achieve haemostasis due to disease severity.

**Conclusion:** Radiofrequency coblation is a novel technique, which was found to be a safe, effective, quick and well tolerated treatment option for epistaxis management in patients with hereditary haemorrhagic telangiectasia.

**Key words:** Hereditary Haemorrhagic Telangiectasia; Epistaxis; Surgical Techniques, Operative; Coblation; Nasal Cavity

## Introduction

Hereditary haemorrhagic telangiectasia is an autosomal dominant disorder characterised by diffuse telangiectasia and arteriovenous malformations on both cutaneous and mucosal surfaces.<sup>1</sup>

The clinical course of the illness is dominated by chronic, recurrent epistaxis which can be difficult to manage.<sup>2</sup> Many techniques have been used to control epistaxis in such patients, including hormonal manipulation,<sup>3,4</sup> various lasers,<sup>5–8</sup> microdebriding,<sup>9</sup> chemical and electrical cautery,<sup>10</sup> septodermoplasty,<sup>11</sup> and nasal closure (Young's procedure).<sup>12</sup>

The ideal technique for hereditary haemorrhagic telangiectasia would be effective, long-lasting and minimally invasive while preserving mucociliary function.

The KTP laser can arguably claim to be the current 'gold standard' for hereditary haemorrhagic telangiectasia management.<sup>5</sup> However, it is an expensive piece of equipment and can be difficult to use in a bloody field.

Microdebriders have been successfully used to remove telangiectasia, but also require bipolar diathermy to seal the feeding vessels.

Radiofrequency coblation is a relatively new technique which is being increasingly used in ENT surgery. This technique destroys tissue by a process of radiofrequency energy application to a conductive medium (e.g. normal saline), which produces a localised plasma field that breaks molecules into inert, low molecular weight gases at low

temperature (classically 60–70°C). This contrasts with conventional electrosurgery, in which direct electric energy applied to tissue causes temperatures of over 400°C. Coblation has been demonstrated to promote good healing and to preserve surrounding normal tissue.<sup>13</sup> Despite low temperatures, small blood vessels are sealed by this process. Additional, prospective studies have demonstrated that radiofrequency coblation significantly decreases blood loss during endoscopic tumour removal,<sup>14</sup> and is a fast, effective method for reducing encephaloceles.<sup>15</sup>

Radiofrequency coblation can therefore theoretically achieve both ablation and haemostasis of telangiectatic and arteriovenous malformations, using the same instrument. The use of coblation in patients with hereditary haemorrhagic telangiectasia has not previously been formally reported. However, informal discussion has indicated that several surgeons worldwide have now begun to use coblation to treat hereditary haemorrhagic telangiectasia.

We describe a multicentre series of five patients with hereditary haemorrhagic telangiectasia, in whom radiofrequency coblation was used for disease management.

## Case reports

We present the experience of two surgeons from different centres, both of whom have used coblation to manage epistaxis related to hereditary haemorrhagic telangiectasia. Cases one and two were treated at the Division of

TABLE I  
OVERVIEW OF CASES WITH REGARDS TO INTERVENTIONS AND OUTCOMES

Age/sex	Symptom duration	Prior intervention?	Operating time (min)	Epistaxis control?
45/F	2 years	Yes	8	Yes
70/F	4 months	Yes	10	Yes
54/M	5 years	Yes	40	No
61/M	2 years	Yes	10	Yes
61/M	2 months	No	8	Yes

Min = minutes; F = female; M = male

Otolaryngology, Department of Surgery, University of Alabama at Birmingham, USA, while cases three to five were treated at Flinders Medical Centre, Adelaide, Australia.

The operating time for all procedures ranged from 8 to 40 minutes (Table I). All procedures were performed under general anaesthesia using the Coblation PROcise EZ View Sinus Wand (Arthrocare ENT, TX, USA).

#### Case one

A 45-year-old woman with hereditary haemorrhagic telangiectasia presented with recurrent episodes of epistaxis for two years, despite previous septodermoplasties. Bleeding was from hereditary haemorrhagic telangiectatic lesions involving the lateral nasal wall (Figure 1). She received several four-weekly coblation treatments (Figure 2), after which she remained symptom-free.

#### Case two

A 70-year-old woman was diagnosed with hereditary haemorrhagic telangiectasia four months before presentation. She was referred after several attempts at embolisation had failed to improve her recurrent, bilateral epistaxis.

The patient received two coblation treatments six weeks apart, resulting in excellent epistaxis control.

#### Case three

A 54-year-old man with a long history of hereditary haemorrhagic telangiectasia and secondary pulmonary hypertension presented with life-threatening epistaxis. Previous treatments included septodermoplasty, septectomy, ND:YAG laser and KTP laser (Figure 3).

Despite an extensive coblation procedure, the wand failed to clear blood clots, and the patient required nasal packing and subsequent embolisation. A second coblation procedure gained control for a further six months, but another episode of life-threatening epistaxis necessitated further embolisation and a Young's procedure. The patient then developed telangiectasia on the skin over his Young's closure, but these were easily controlled with coblation. He remained well following this procedure.

#### Case four

A 61-year-old woman presented with a two-year history of hereditary haemorrhagic telangiectasia. Previous

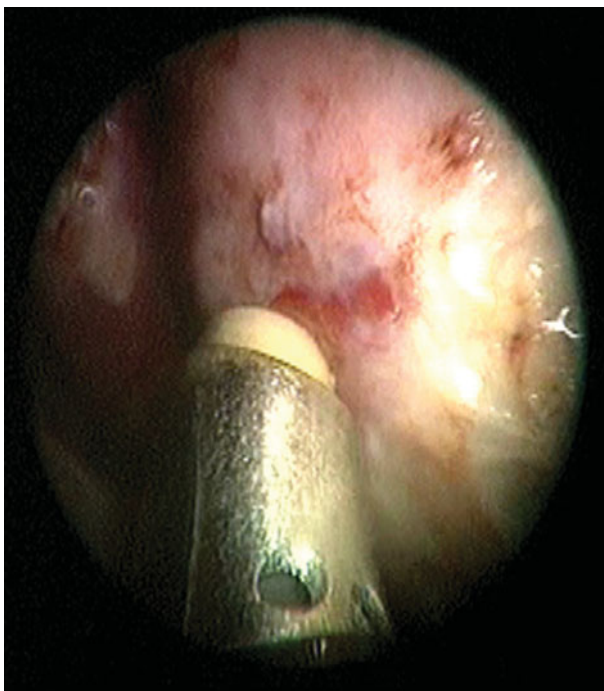


FIG. 1

Case one: telangiectasia involving the nasal septum.

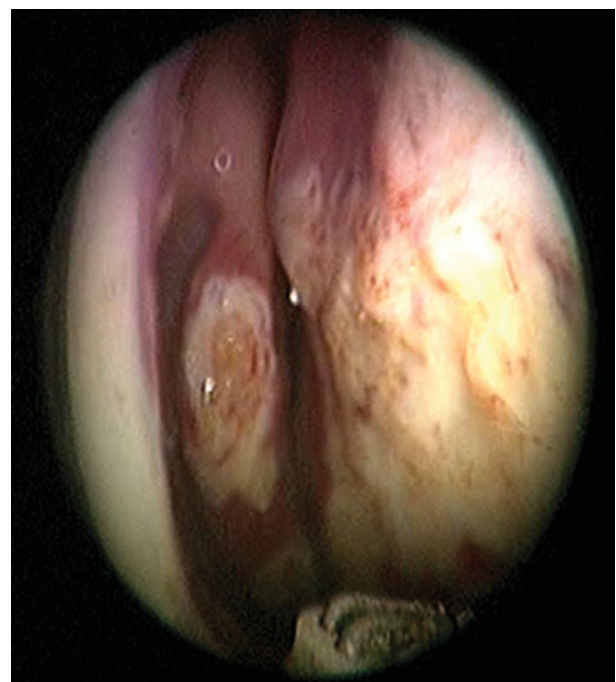


FIG. 2

Case one: excision of the lesion and haemostasis achieved with coblation.

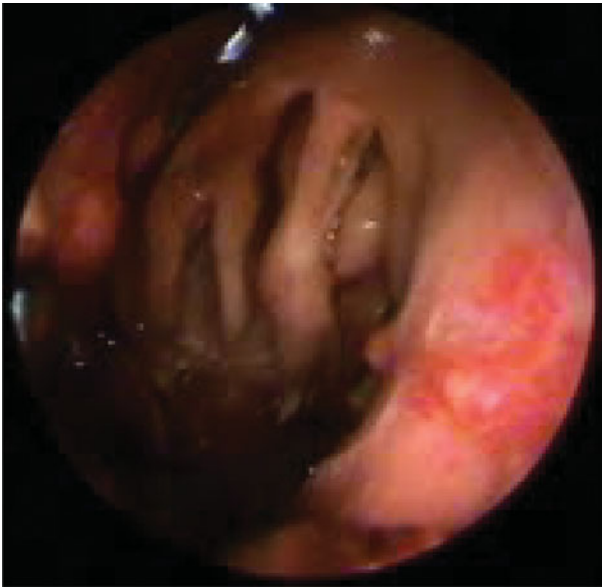


FIG. 3

Case three: recurrence of telangiectasia despite extensive surgery.

lesions had been treated with silver nitrate cautery. A single, quick coblation procedure ablated all lesions (Figure 4), and the patient remained well eight months post-operatively.

#### Case five

A 61-year-old man presented with recently diagnosed hereditary haemorrhagic telangiectasia. Coblation was used to ablate all hereditary haemorrhagic telangiectatic lesions.

However, the patient presented one year later with a large arteriovenous malformation on the floor of the right nasal cavity (Figure 5). Coblation ablated this arteriovenous malformation with ease. Ten months later, the patient remained symptom-free (Figure 6).

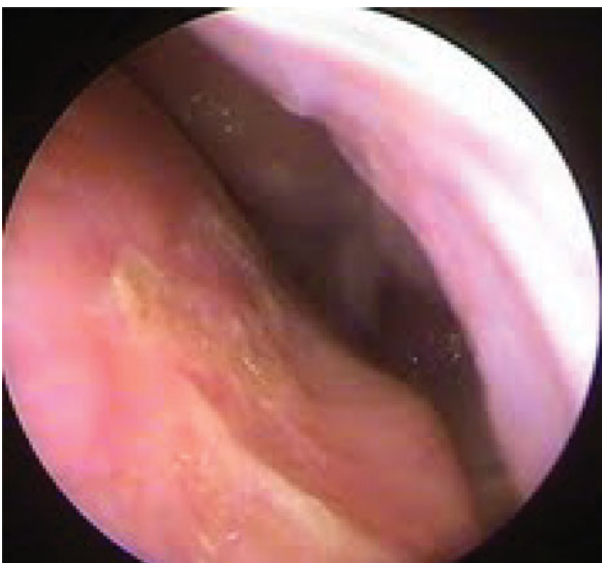

FIG. 4

Case four: minimal post-operative crusting following coblation.

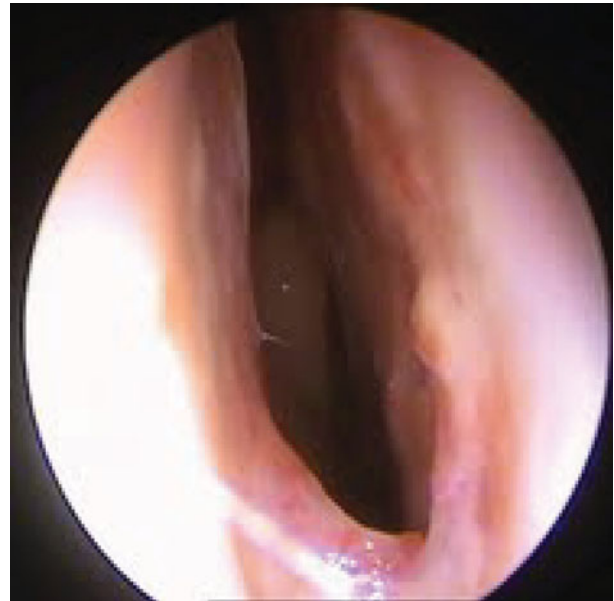


FIG. 5

Case five: telangiectasia on the floor of the nasal cavity.

#### Discussion

Hereditary haemorrhagic telangiectasia usually presents with recurrent epistaxis from the anterior third of the nasal septum or the anterior ends of the turbinates.<sup>16</sup>

A myriad of surgical modalities have been described to manage epistaxis in patients with this condition.<sup>5–12</sup>

As regards laser treatment of hereditary haemorrhagic telangiectasia, there is controversy over which type of laser is best. Carbon dioxide,<sup>2</sup> ND:YAG,<sup>3</sup> pulsed dye laser, diode<sup>4</sup> and KTP<sup>5</sup> lasers have all been used for this purpose, with the KTP laser now gaining consensus as the most popular device. It has been suggested that laser can easily ablate the periphery of larger lesions to reduce central blood flow,

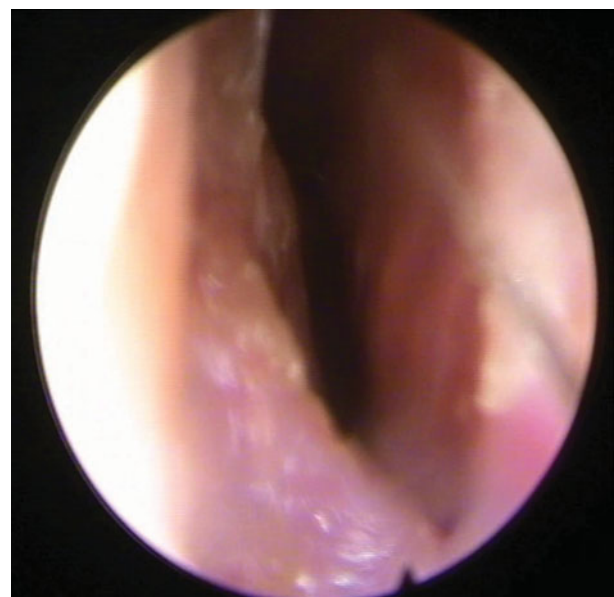


FIG. 6

Case five: a good result following coblation of telangiectasia.

but that direct laser focussed on the centre of a lesion causes extensive bleeding and makes further treatment difficult.<sup>6</sup> In one study, the majority of hereditary haemorrhagic telangiectasia patients with moderate to severe bleeding reported no change in bleeding severity and no improvement in quality of life following laser ablation of telangiectasias.<sup>17</sup> In fact, the use of carbon dioxide laser has been found to provoke lesions on the mucosal surface,<sup>18,19</sup> in contrast with other laser types which target submucosal tissues.<sup>20</sup> Whilst in the USA and UK most teaching centres will have access to a wide spectrum of lasers for treatment, this is not the case in Australian hospitals, nor in the private clinic. Hereditary haemorrhagic telangiectasia remains a rare condition, and it is difficult to justify the cost of a US\$100 000 (or more) laser which may only be used a few times a year. Unlike the laser, coblation works at low temperatures (classically less than 60°C), thereby causing less thermal injury to adjacent tissues, and theoretically reducing the amount of crusting and scarring.<sup>13</sup>

Microdebriders have also been trialled and found to be beneficial for the removal of telangiectasias on nasal mucous membranes; however, bipolar cautery is also needed to achieve haemostasis after lesion removal.<sup>9</sup> There is a risk of septal perforation if both sides of the nose are treated simultaneously. In contrast, the use of coblation enables both lesion removal and haemostasis, with the same instrument. The low temperatures minimise the risk of septal perforation. As well as traditional coblation probes (e.g. the Evac 70; Arthrocare ENT, TX, USA), newer probes designed for the nasal wall are now available (e.g. the PROcise EZ View Sinus; Arthrocare ENT, TX, USA).

Bipolar cautery<sup>10</sup> remains an option for hereditary haemorrhagic telangiectasia treatment. However, it produces thermal injury, with secondary crusting, mucosal damage and an inevitable reduction in mucociliary function. As such, it has fallen from the list of recommended techniques for the management of hereditary haemorrhagic telangiectasia.

- **Hereditary haemorrhagic telangiectasia can present with chronic, recurrent epistaxis**
- **There is currently no single standard treatment**
- **Radiofrequency coblation is an effective, logical and well tolerated treatment for mild to moderate cases of epistaxis due to hereditary haemorrhagic telangiectasia**
- **In severe epistaxis cases, coblation may struggle to achieve control (as may other treatment modalities)**

Septodermoplasty<sup>11</sup> involves removal of nasal mucosa from the anterior part of the nasal cavity and replacement by a split skin graft. This technique has been found to have good initial outcomes in patients with hereditary hemorrhagic telangiectasia patients, which unfortunately decline over time due to contraction and revascularisation of the graft. The technique has also been found to be associated with nasal crusting and halitosis.<sup>21</sup>

Young's procedure<sup>22</sup> is a radical technique involving closure of the nasal vestibule. Although it provides long term relief in patients with moderate to severe epistaxis

secondary to hereditary haemorrhagic telangiectasia,<sup>12</sup> the disadvantages (dry mouth, loss of smell and complete nasal obstruction) are often not tolerated by patients. Upon reviewing the procedure, Young himself found that many patients had to have the procedure reversed because of these problems. Young's procedure is best reserved for cases of hereditary haemorrhagic telangiectasia unresponsive to other treatment modalities. One patient in the current series failed coblation management and required a Young's procedure to control his disease.

The use of coblation for hereditary haemorrhagic telangiectasia epistaxis is a much more conservative procedure, which can be safely repeated without significant complications.

One limitation of coblation for hereditary haemorrhagic telangiectasia related epistaxis is the difficulty experienced when manoeuvring the instrument inside the nasal cavity, along with the endoscope, due to its width and angulation. Smaller coblation wands are being developed which will hopefully enable easier manipulation. We have also found that severe bleeding can block the suction port of the coblation wand. This potentially limits its use in severe cases of hereditary haemorrhagic telangiectasia. However, in the current series coblation was successful in managing a patient with a large arteriovenous malformation. We must concede that more experience with coblation is required in order to clarify the ideal candidates for, and limitations of, its use in hereditary haemorrhagic telangiectasia therapy.

## References

- 1 AAssar OS, Friedman CM, White RI Jr. The natural history of epistaxis in hereditary hemorrhagic telangiectasia. *Laryngoscope* 1991;**101**:977–80
- 2 Haitjema T, Westermann CJ, Overtoom TT, Timmer R, Disch F, Mauser H *et al.* Hereditary hemorrhagic telangiectasia (Osler-Weber-Rendu disease): new insights in pathogenesis, complications, and treatment. *Arch Intern Med* 1996;**156**:714–19
- 3 Sadick H, Riedel F, Oulmi J, Hörmann K, Bergler WF. Argon plasma coagulation and topically applied estriol – long-term results in the treatment of hereditary hemorrhagic telangiectasia of the nasal mucosa [in German]. *HNO* 2003;**51**:118–24
- 4 Jameson JJ, Cave DR. Hormonal and antihormonal therapy for epistaxis in hereditary hemorrhagic telangiectasia. *Laryngoscope* 2004;**114**:705–9
- 5 Harvey RJ, Kanagalingam J, Lund VJ. The impact of septodermoplasty and potassium-titanyl-phosphate (KTP) laser therapy in the treatment of hereditary hemorrhagic telangiectasia-related epistaxis. *Am J Rhinol* 2008;**22**:182–7
- 6 Illul P, Bjerring P. Hereditary haemorrhagic telangiectasia treated by laser surgery. *Rhinology* 1988;**26**:19–24
- 7 Levine HL. Endoscopy and KTP/532 laser for nasal sinus disease. *Ann Otol Rhinol Laryngol* 1989;**98**:46–51
- 8 Jovancević L, Mitrović SM. Epistaxis in patients with hereditary hemorrhagic telangiectasia [in Serbian]. *Med Pregl* 2006;**59**:443–9
- 9 Bublik M, Sargi Z, Casiano RR. Use of the microdebrider in selective excision of hereditary hemorrhagic telangiectasia: a new approach. *Otolaryngol Head Neck Surg* 2007;**137**:157–8
- 10 Ghaheri B, Fong KJ, Hwang PH. The utility of bipolar electrocautery in hereditary hemorrhagic telangiectasia. *Otolaryngol Head Neck Surg* 2006;**134**:1006–9
- 11 Saunders WH. Permanent control of nosebleeds in patients with hereditary hemorrhagic telangiectasia. *Ann Intern Med* 1960;**53**:147–52
- 12 Gluckman JL, Portugal LG. Modified Young's procedure for refractory epistaxis due to hereditary haemorrhagic telangiectasia. *Laryngoscope* 1994;**104**:1174–7

- 13 Grobler A, Carney AS. Radiofrequency coblation tonsillectomy. *Br J Hosp Med (Lond)* 2006;**67**:309–12
- 14 Kostrzewa JP, Sunde J, Riley KO, Woodworth BA. Radiofrequency coblation decreases blood loss during endoscopic sinonasal and skull base tumor removal. *ORL J Otorhinolaryngol Relat Spec* 2010;**72**:38–43
- 15 Smith N, Kostrzewa J, Riley KO, Woodworth BA. Endoscopic coblation-assisted management of encephaloceles. *Laryngoscope* 2010;**120**:2535–9
- 16 Stecker RH, Lake CF. Hereditary hemorrhagic telangiectasia; review of 102 cases and presentation of an innovation to septo-dermoplasty. *Arch Otolaryngol* 1965;**82**:522–6
- 17 Lennox PA, Hitchings AE, Lund VJ, Howard DJ. The SF-36 health status questionnaire in assessing patients with epistaxis secondary to hereditary hemorrhagic telangiectasia. *Am J Rhinol* 2005;**19**:71–4
- 18 Kardos T, Holt T, Ferguson M. Histological evaluation of the effect of a miniature carbon dioxide laser on oral mucosa. *Int J Oral Maxillofac Surg* 1989;**18**:117–20
- 19 Shapshay S, Rebeiz E, Bohigian R, Hybels R. Benign lesions of the larynx: should the laser be used? *Laryngoscope* 1990;**100**: 953–7
- 20 Byahatti S, Rebeiz E, Shapshay S. Hereditary hemorrhagic telangiectasia: what the otolaryngologist should know. *Am J Rhinol* 1997;**11**:55–62
- 21 Lund VJ, Howard DJ. A treatment algorithm for the management of epistaxis in hereditary haemorrhagic telangiectasia. *Am J Rhinol* 1999;**13**:319–22
- 22 Taylor M, Young A. Histopathological and histochemical studies on atrophic rhinitis. *J Laryngol Otol* 1961;**75**:574–90

Address for correspondence:  
Dr H Joshi,  
Flinders Medical Centre,  
94 Broadmeadow Drive,  
Flagstaff Hill, SA  
Australia 5159

E-mail: joshihims@gmail.com

---

Dr H Joshi takes responsibility for the integrity of the content of the paper  
Competing interests: None declared

---