

Review Article

The clinical significance of the communicating branches of the somatic sensory supply of the middle and external ear

PHILIP GREY, F.R.A.C.S.

Abstract

The sensory supply of the middle and external ear is complicated by multiple neural communications. The anatomy of these communications and their clinical significance will be described in this paper.

Key words: Ear, external; Ear, middle; Nerve supply

Introduction

The somatic sensory supply of the middle and external ear is characterized by multiple neural communications. These communications arise because of the complex embryological development of the branchial arches and their derivatives. Using the available literature the anatomy of these communications will be described. The fascinating clinical syndromes which arise secondary to these communications will also be discussed.

Anatomy

The middle and external ear arise from the first and second branchial arches, clefts and pouches (Williams *et al.*, 1989). Two points may help in the understanding of the nervous supply to these structures:

- (1) Pre-trematic nerves. In fish, each branchial arch receives a nerve trunk which divides to a post-trematic nerve for its own arch and a pre-trematic branch to the arch cranial to it. In the human embryo however, this distribution has not been confirmed (Williams *et al.*, 1989). Table I shows suggested pre- and post-trematic nerves relevant to the ear.
- (2) Somatic sensory fibres to the head and neck eventually synapse in the trigeminal nuclei of the brain stem. This includes fibres travelling with the facial, glossopharyngeal, vagal and upper cervical dorsal roots (Williams *et al.*, 1989).

External ear

1. *The auriculotemporal nerve.* A branch of the

mandibular division of the trigeminal nerve, it winds around the neck of the mandible behind the temporomandibular joint and divides. It sends two auricular branches to supply the tragus and antero-superior helix and two small branches which pass between the bony and cartilaginous external auditory meatus (EAM) to supply the EAM and the tympanic membrane (Last, 1984; Glasscock and Shambaugh, 1990).

2. *The greater auricular nerve.* Formed from the cervical roots C2/3, this nerve courses around the sternocleidomastoid muscle to divide. The posterior branch supplies skin over the mastoid, posterior surface of the auricle and lower half of the anterior surface of the auricle (Hollinshead, 1982; Glasscock and Shambaugh, 1990). The anterior branch then ascends to pass through the substance of the parotid gland to supply the area of skin over the angle of the mandible.

3. *The lesser occipital nerve.* Also from C2, this nerve may overlap on the very superior part of the pinna (Hollinshead, 1982; Williams *et al.*, 1989).

4. *The auricular branch of the vagus (Arnold's nerve).* This is a complicated composite nerve (see

TABLE I
SUGGESTED POST-TREMATIC AND PRE-TREMATIC NERVES RELATED TO SOMATIC SENSORY INNERVATION OF THE EAR

Branchial arch	Post-trematic nerve	Pre-trematic nerve
1st arch	Mandibular nerve	?
2nd arch	Facial nerve	Chorda tympani
3rd arch	Glossopharyngeal nerve	Tympanic branch (Jacobsen's nerve)
4th arch	Vagus	Auricular branch (Arnold's nerve)

From the Department of Otolaryngology, Addenbrookes Hospital, Cambridge, UK.
Accepted for publication: 23 July 1995.

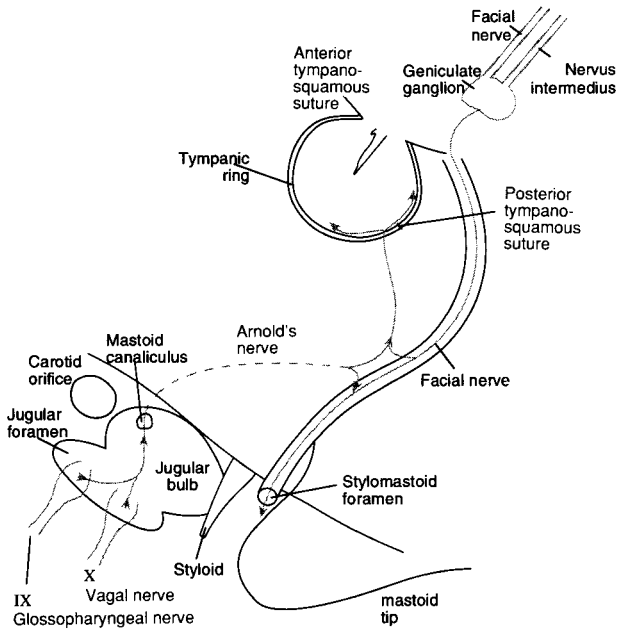


FIG. 1

Diagram of Arnold's nerve and its communications

Figure 1). It begins as a branch of the superior vagal ganglion (Arnold, 1831), and receives some fibres from the inferior ganglion of the glossopharyngeal nerve and from the cervical sympathetic trunk (Arnold, 1831; Guild, 1953). It then enters the mastoid canaliculus on the lateral wall of the jugular fossa (Proctor, 1989), or runs in a groove on the inferior surface of the temporal bone (Guild, 1953).

Arnold's nerve then ascends in close proximity to the fallopian canal before dividing. The superior branch supplies the facial nerve sheath while the inferior branch receives sensory fibres from the facial nerve itself (Foley and Dubois, 1943). Alternatively, Arnold's nerve may receive sensory fibres from the posterior auricular branch of the facial nerve on the inferior surface of the temporal bone (Hollinshead, 1982). These somatic sensory fibres have their cell bodies in the geniculate ganglion, and the secondary order neurones run in the nervus intermedius (Kure and Sano, 1936; Williams *et al.*, 1989).

Arnold's nerve then enters the posterior tympano-

squamosal suture to enter the EAM halfway along the bony canal (Proctor, 1989). Here it supplies a posterior portion of the tympanic membrane, EAM and concha, and a small portion of post-auricular skin.

Despite this multiple somatic sensory supply, the trigeminal nerve, via its mandibular division, gives the principal supply to the tympanic membrane and deep EAM. It is supplemented inconsistently and incompletely by the other cranial nerves mentioned (Saunders and Weider, 1985) (see Figures 2 and 3).

Middle ear

The major somatic sensory (and parasympathetic) supply to the middle ear leaves the brain stem in the glossopharyngeal nerve (Williams *et al.*, 1989). The auricular branch (Jacobsen's nerve), originates near the inferior ganglion. It enters the inferior tympanic canaliculus on the crest between the internal jugular vein and the internal carotid artery (Proctor, 1989). Jacobsen's nerve ascends to enter the middle ear and run across the promontory of the cochlea.

The sympathetic supply comes from the superior cervical ganglion, ascends with the internal carotid artery and enters the middle ear anteriorly as the caroticotympanic nerves (Mitchell, 1953). With Jacobsen's nerve this forms the tympanic plexus. Tympanic fibres that do not supply the middle ear unite to form the lesser superficial petrosal nerve which eventually gives secretomotor supply to the parotid gland.

The chorda tympani is also believed to carry somatic sensory fibres to the tongue (Hunt, 1915) although their exact position in the nerve is uncertain (Saito *et al.*, 1970). These fibres come from the nervus intermedius, via the geniculate ganglion and facial nerve, to leave with the chorda tympani in the middle ear.

Clinical significance

The clinical significance of these nerves and communications lies in the fascinating presentations of pathology affecting them (see Table II).

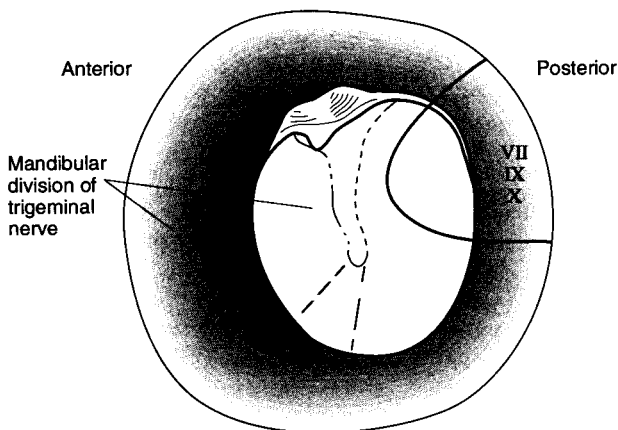


FIG. 2

Distribution of somatic sensory fibres to the external auditory meatus and tympanic membrane.

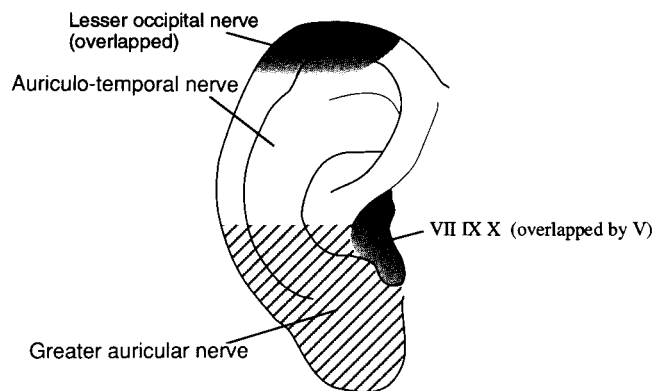


FIG. 3

Somatic sensory supply of the concha and anterior surface of the pinna.

1. Referred otalgia

Pain may be referred to the ear via any of the nerves supplying somatic sensation to the ear. Therefore distant lesions in the sensory field of cervical nerves 2/3, or cranial nerves 5, 7, 9 and 10 can cause otalgia. The physiological explanation for referred pain is uncertain (Walton, 1993).

2. Idiopathic otalgia/neuralgia

Idiopathic otalgia/neuralgia is diagnosed when the pain occurs without any demonstrable lesion. It is likely that vascular compression at the root entry zone of the cranial nerves is the cause of some cases of idiopathic otalgia. Idiopathic otalgia can be subclassified according to the sensory ganglion affected, however, because of sensory overlap differentiation can be difficult (Rupa *et al.*, 1991).

(A) *Trigeminal neuralgia*. This clinical syndrome is well known, and otalgia may occasionally be part of the syndrome (Gray and Hawthorne, 1992). Isolated otalgia, however, has not been described as part of trigeminal neuralgia (Rupa *et al.*, 1991).

(B) *Geniculate neuralgia*. The pain of geniculate neuralgia is sited deep in the ear with referral to the pinna or auditory tube, or even facial structures (Hunt, 1915; Ouaknine *et al.*, 1980). It may be triggered by touching the EAM (Furlow, 1942). There are many reports which implicate the somatic sensory fibres that travel in the nervus intermedius to the geniculate ganglion as the source of the neuralgia (Hunt, 1915; Pulec, 1976; Rupa *et al.*, 1991).

Surgical remedies employed for geniculate neuralgia have included section of the nervus intermedius (Clark and Taylor, 1909) and geniculate gangliectomy (Pulec, 1976). More recently, microvascular decompression of the nervus intermedius/facial nerve complex has relieved otalgia (Ouaknine *et al.*, 1980).

(C) *Glossopharyngeal neuralgia (vago-glossopharyngeal)*. This syndrome is similar to stylalgia, where an elongated or medially displaced styloid process leads to glossopharyngeal pain. It is characterized by paroxysms of pain in the tonsillar region, tongue or ear. It is commonly triggered by chewing, swallowing or coughing (Rushton *et al.*, 1981; Walton, 1993). The otalgia may be deeply sited or radiate to the EAM. Anaesthetizing the tonsillar region often relieves the pain and aids in diagnosis (Rushton *et al.*, 1981).

Surgical treatments employed include tympanic

neurectomy (Cook and Irving, 1990), or glossopharyngeal nerve section in the neck or posterior cranial fossa. In 1945, Dandy also included the upper rootlets of the vagus as these fibres contribute to the aural sensation (Rushton *et al.*, 1981). Microvascular decompression has also cured glossopharyngeal neuralgia related to vascular loops (Laha and Janetta, 1977; Rushton *et al.*, 1981).

3. Mastoid ache

Aching over the mastoid bone has been described in 25 per cent of documented vestibular schwannomas (Moffat *et al.*, 1989), and this was found to be associated with facial numbness suggesting the ache is trigeminal in origin. Alternative theories are that the nervus intermedius is compressed, or the tumour is irritating the posterior fossa meninges which are innervated by cervical roots 2/3.

4. Hitselberger's sign

In 1966, Hitselberger noted that many patients with vestibular schwannomas had hypoaesthesia of the EAM (Hitselberger and House, 1966). In a recent study of 50 vestibular schwannomas and seven other cerebellopontine angle lesions, Hitselberger's sign was 88 per cent sensitive and 87 per cent specific for vestibular schwannoma (Ballagh *et al.*, 1994). A separate group of 44 post-operative vestibular schwannoma patients was also studied with only 59 per cent having a positive Hitselberger's sign (Ballagh *et al.*, 1994). The sign is presumably due to compression of the nervus intermedius in the internal auditory canal. If this was the case, for 59 per cent of patients to have the sign post-operatively the damage to the nervus intermedius must be irreversible or, alternatively, the nerve is damaged during surgery on the internal auditory canal.

5. Reflex irritation

It is well recognized that stimulation of the EAM, particularly during aural toilet, often causes reflex coughing or gagging. In one paper, simply touching the pinna elicited the reflex (Hammond and Ebers, 1992). The stimulus is believed to travel via Arnold's nerve to the vagus and its nuclei. The cough reflex arc is initiated by the vagal nuclei which send impulses to the respiratory centre to co-ordinate forced expiration by the phrenic and intercostal nerves.

6. Herpes zoster oticus

Typical zoster virus infection presents as a vesicular eruption in a belt-like distribution following sensory dermatomes and is commonly termed shingles. In the head and neck it most commonly affects the ophthalmic division of the trigeminal ganglion, but can affect the mandibular division, the geniculate ganglion or the cervical ganglia. The Ramsay-Hunt syndrome has evolved to define

TABLE II

CLINICAL SYNDROMES RELATED TO THE SOMATIC SENSORY COMMUNICATIONS OF THE EAR

1	Referred otalgia
2	Idiopathic otalgia/neuralgia
3	Mastoid ache
4	Hitzelberger's sign
5	Reflex irritation
6	Herpes zoster oticus
7	Herpes simplex
8	Greater auricular nerve in parotid surgery
9	Sites for local anaesthesia

herpes zoster of the pinna with otalgia and facial paralysis. It is due to zoster infection of the geniculate ganglion (Baringer and Townsend, 1993), with the virus passing along the somatic sensory fibres to the periphery. The vesicles typically occur on the posterior EAM, but also involve the tympanic membrane, retromental sulcus, anterior portion of the tongue, and tonsillar fossa (possibly via petrosal nerve communications (Hunt, 1915)).

7. Herpes simplex

Both type I and type II herpes simplex virus are a rare cause of blisters of the external ear (Alberti and Ruben, 1988). Clinically they appear as clusters of closely grouped vesicles on an erythematous base, often preceded by tingling or pain. It is likely the virus persists in a latent fashion in the sensory ganglia, usually the trigeminal ganglion (Rook *et al.*, 1986), and can propagate down the axon to produce recurrent, highly localized lesions (Baringer and Townsend, 1993). There is also some evidence that herpes simplex infection of the geniculate ganglion secondarily leads to idiopathic Bell's palsy (McCormick, 1972; Adour, 1980; Burgess *et al.*, 1994).

8. Greater auricular nerve in parotid surgery

The greater auricular nerve is regularly divided during surgery on the parotid gland, indeed it is impossible to preserve the anterior branch. Preservation of the posterior branch of the nerve significantly reduces the incidence of numbness of the pinna, especially the ear lobe. This is clinically important because numbness of the ear lobe may be poorly tolerated in patients who wear earrings (Brown and Ord, 1989).

9. Sites for local anaesthetic infiltration

These are well described in otological textbooks (Glasscock and Shambaugh, 1990).

Conclusion

The complexity of the somatic sensory supply of the ear is mainly due to the auricular branch of the vagus and its communications. Many unusual and interesting clinical conditions are presented via these communications and a thorough anatomical knowledge is essential in the diagnosis and treatment of these conditions.

Acknowledgements

The author wishes to thank Mr David Moffat for invaluable assistance in the preparation of this paper.

References

Adour, K. A. (1980) Treatment for acute facial paralysis. In *Controversy in otolaryngology*. (Snow, J. B., ed.) W. B. Saunders Co., Philadelphia, pp 395–403.

- Alberti, P. W., Ruben, R. J. (1988) *Otologic Medicine and Surgery*. Vol 1, Churchill Livingstone, New York, p 587.
- Arnold, F. (1831) *Der Kopftheil des vegetativen Nervensystems beim Menschen*. Karl Groos, Heidelberg.
- Ballagh, R. H., Moffat, D. A., Harada, T., Baguley, D. (1994) Hitselberger sign and acoustic neuroma diagnosis. *Journal of Laryngology and Otolaryngology (Abstract)* **108**: 909.
- Baringer, J. R., Townsend, J. J. (1993) Herpes virus infections of the peripheral nervous system. In *Peripheral Neuropathy*. (Dyck, P. J., Thomas, P. K., eds.), W. B. Saunders Co., Philadelphia, pp 1333–1342.
- Brown, J. S., Ord, R. A. (1989) Preserving the greater auricular nerve in parotid surgery. *British Journal of Oral and Maxillofacial Surgery* **27**: 459–466.
- Burgess, R. C., Bale, J. F., Michaels, L., Smith, R. J. H. (1994) Polymerase chain reaction amplification of herpes simplex viral DNA from the geniculate ganglion of a patient with Bell's palsy. *Annals of Otolaryngology, Rhinology and Laryngology* **103**: 775–779.
- Clark, L. P., Taylor, A. S. (1909) True tic douloureux of the sensory filaments of the facial nerve. *Journal of the American Medical Association* **55**: 2144–2146.
- Cook, J. A., Irving, R. M. (1990) Role of tympanic neurectomy in otalgia. *Journal of Laryngology and Otolaryngology* **104**: 114–117.
- Foley, J. O., Dubois, F. S. (1943) An experimental study of the facial nerve. *Journal of Comparative Neurology* **79**: 79–101.
- Furlow, L. T. (1942) Tic douloureux of the nervus intermedius (so-called geniculate ganglion neuralgia). *Journal of the American Medical Association* **119**: 255–259.
- Glasscock, M. E., Shambaugh, G. E. (1990) *Surgery of the ear*. 4th Edition, W. B. Saunders Co., Philadelphia, p 36.
- Gray, R. F., Hawthorne, M. (1992) *Synopsis of otolaryngology*. 5th Edition, Butterworth, Oxford, p 585.
- Guild, S. R. (1953) The glomus jugulare, a nonchromaffin paraganglion, in man. *Annals of Otolaryngology, Rhinology and Laryngology* **62**: 1045–1068.
- Hammond, R. R., Ebers, G. C. (1992) Chronic cough following cardiac transplantation: vagal mitempfingung? *Journal of Neurology, Neurosurgery and Psychiatry* **55**: 723–724.
- Hitselberger, W. E., House, W. F. (1966) Acoustic neuroma diagnosis. *Archives of Otolaryngology* **83**: 218–221.
- Hollinshead, W. H. (1982) *Anatomy for surgeons: Volume 1—The head and neck*. 3rd Edition, Harper and Row, Philadelphia, p 163.
- Hunt, J. R. (1915) The sensory field of the facial nerve: a further contribution to the symptomatology of the geniculate ganglion. *Brain* **38**: pp 418–446.
- Kure, K., Sano, T. (1936) Faserarten im *N. facialis* und die funktionelle Bedeutung der ganglion geniculi. *Zeitschrift für Zellforschung und Mikroskopische Anatomie* **23**: 495.
- Laha, R. K., Janetta, P. J. (1977) Glossopharyngeal neuralgia. *Journal of Neurosurgery* **47**: 316–320.
- Last, R. J. (1984) *Anatomy regional and applied*. 7th Edition, Churchill-Livingstone, Edinburgh, p 35.
- McCormick, D. P. (1972) Herpes simplex virus as a cause of Bell's palsy. *Lancet* **1**: 937–939.
- Mitchell, G. A. G. (1953) Cranial extremities of the sympathetic trunk. *Acta Anatomica* **18**: 195.
- Moffat, D. A., Baguley, D. M., Evans, R. A., Hardy, D. G. (1989) Mastoid ache in acoustic neuroma. *Journal of Laryngology and Otolaryngology* **103**: 1043–1044.
- Ouaknine, G. E., Robert, F., Molina-Negro, P., Hardy, J. (1980) Geniculate ganglion neuralgia and audio-vestibular disturbances due to compression of the intermediate and eighth nerves by the postero-inferior cerebellar artery. *Surgical Neurology* **13**: 147–150.
- Proctor, B. (1989) *Surgical anatomy of the ear and temporal bone*. Thieme Medical, New York, p 11.
- Pulec, J. L. (1976) Geniculate ganglion neuralgia: Diagnosis and surgical management. *Laryngoscope* **86**: 955–964.
- Rook, A., Wilkinson, D. S., Ebling, F. G. J., Champion, R. H. (1986) *Textbook of dermatology*. 4th Edition, Vol 1, Blackwell Scientific Publications, Oxford, p 686.
- Rupa, V., Saunders, R. L., Weider, D. J. (1991) Geniculate ganglion neuralgia: the surgical management of primary otalgia. *Journal of Neurosurgery* **75**: 505–511.

- Rushton, J. G., Stevens, J. C., Miller, R. H. (1981) Glossopharyngeal (vagoglossopharyngeal) neuralgia. A study of 217 cases. *Archives of Neurology* **38**: 201–205.
- Saito, H., Ruby, R. R. F., Schuknecht, H. F. (1970) Course of the sensory component of the nervus intermedius in the temporal bone. *Annals of Otolaryngology and Laryngology* **79**: 960–965.
- Saunders, R. L., Weider, D. (1985) Tympanic membrane sensation. *Brain* **108**: 387–404.
- Walton, J. (1993) *Brain's Diseases of the Nervous System*. 10th Edition. (Walton, J., ed.) Oxford University Press, Oxford, p 684.
- Williams, P. L., Warwick, R., Dyson, M., Bannister, L. H. (1989) *Gray's Anatomy*. 37th Edition, (Williams, P. L., Warwick, R., Dyson, M., Bannister, L. H., eds.), Churchill-Livingstone, Edinburgh, pp 172, 1122, 1128.

Address for correspondence:
Mr P. Grey,
Department of Otolaryngology,
West Suffolk Hospital,
Bury St Edmunds,
Suffolk IP33 2QZ.

Fax: 01284 701993