

# Imaging Findings in an Early Symptomatic Dystopic Os Odontoideum

Paola Zarantonello<sup>1</sup>, Paolo Spinnato<sup>2</sup>, Francesco Vommaro,  
Tiziana Greggì, Alessandro Gasbarrini, Maria Pilar Aparisi Gomez

**Keywords:** Orthopedics, Pediatrics, Pediatric spine surgery

doi:10.1017/cjn.2020.223

Can J Neurol Sci. 2021; 48: 565–566

We describe the case of a symptomatic early dystopic os odontoideum in a very young child. Os odontoideum is a rare congenital anomaly of C2, first described by Giacomini in 1886<sup>1</sup> and characterized by a smooth, independent ossicle separated from the base of an abnormal odontoid process and without osseous connection to the body of C2.<sup>2,3</sup> The normal odontoid process develops from two ossification centers that fuse in the midline during the seventh fetal month. The odontoid process fuses with the body of C2 (cartilaginous synchondrosis) by 3–6 years of age.<sup>4</sup>

A 2-year-old girl was evaluated with the concern of lack of development of gait. The child was born through cesarean section, after an uneventful pregnancy, except for the late development of preeclampsia. Parents reported no problems after birth and early growth and development appeared regular. Milestones appeared timely. At 5 months, she started to crawl, but never began to walk. The language developed normally.

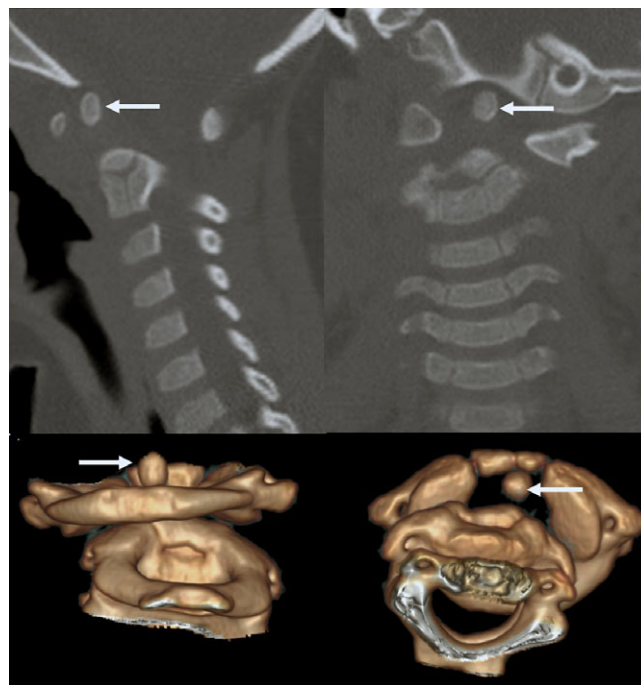
On examination, there was a limitation in the range of motion of the cervical spine, especially during flexion and right rotation. There were no pathological reflexes and other neurological assessments appeared normal. Imaging evaluation was performed with X-ray, CT, and MRI of the cervical spine.

CT scan with 3D reconstructions demonstrated the presence of a small, rounded, well-corticated ossicle posterior to the anterior arch of the atlas, separated from the body of C2, suggesting an os odontoideum (Figure 1). This was located more cranial and left lateral than expected. In addition, significant rotatory atlantoaxial subluxation was noticed.

With a rotation of approximately 32°, the subluxation was defined as grade I, according to Fielding–Hawkins.<sup>5</sup> C1 appeared partially left-lateralized compared to the body of C2, while the os odontoideum remained at a regular distance to the anterior arch of the atlas (<3 mm).

MRI demonstrated the presence of myelopathy at the level of the dystopic os odontoideum – the body of C2 (Figure 2).

Since the presence of any neurological symptom or deficit represents an indication for surgical intervention,<sup>1</sup> the patient was taken to surgery. A posterior instrumented stabilization of C1 and C2 with a single bar (rigid fixation of C1 lateral masses and C2 right laminar screw) was performed. Immediately after surgical treatment, the child developed spontaneous movements of the lower extremities. On the clinical follow-up of 2 months after surgery, the patient was able to stand unassisted and to walk with help.



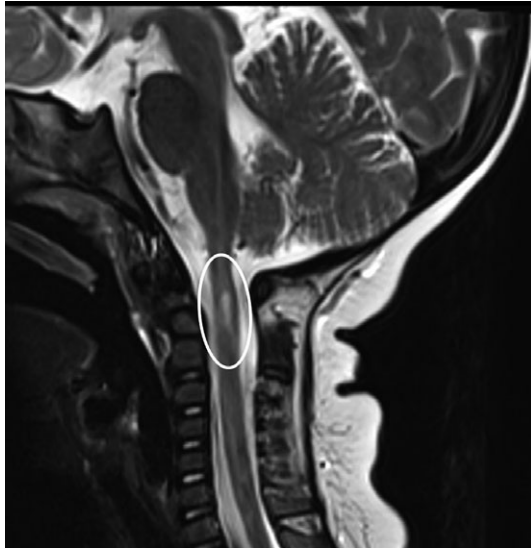**Figure 1:** CT of the cervical spine with 2D (up) and 3D (down) reconstructions shows a dystopic os odontoideum (arrows). C1–C2 rotatory subluxation is also appreciable.

We present the case of a very young child with a symptomatic atlantoaxial instability due to a dystopic os odontoideum<sup>6</sup> that prevented gait development. An os odontoideum may significantly compromise the atlantoaxial stability,<sup>7</sup> with a huge spectrum of clinical presentations. Usually, a minor or major trauma during adolescence and early adulthood could reveal its presence.<sup>8,9</sup> Few scientific studies concern this topic in pediatric

From the Department of Pediatric Orthopedics and Traumatology, IRCCS Istituto Ortopedico Rizzoli, Bologna, Italy (PZ); Diagnostic and Interventional Radiology, IRCCS Istituto Ortopedico Rizzoli, Bologna, Italy (PS); Spine Deformities Surgery Division, IRCCS Istituto Ortopedico Rizzoli, Bologna, Italy (FV, TG); Department of Oncologic and Degenerative Spine Surgery, IRCCS Istituto Ortopedico Rizzoli, Bologna, Italy (AG); and Auckland City Hospital, Auckland, New Zealand (MPAG)

RECEIVED JUNE 2, 2020. FINAL REVISIONS SUBMITTED AUGUST 28, 2020. DATE OF ACCEPTANCE OCTOBER 3, 2020.

Correspondence to: Paola Zarantonello, Department of Pediatric Orthopedics and Traumatology, IRCCS Istituto Ortopedico Rizzoli, Bologna, Italy. Email [paola.zarantonello@ior.it](mailto:paola.zarantonello@ior.it)



**Figure 2:** MRI demonstrated the presence of myelopathy at the level of the dystopic os odontoideum (circle).

population,<sup>7,10</sup> but the literature lacks reports about very young children with significant manifestations. In our case, the considerable improvement after surgical fixation suggests that the os odontoideum determined an atlaxial instability and caused symptoms.

#### CONFLICT OF INTEREST

There are no conflicts of interest.

#### STATEMENT OF AUTHORSHIP

Each author has participated in the work. Study conception and design: PZ and PS. Data acquisition: FV, AG, and TG. Drafting of the manuscript: PZ, PS, and MPAG. Critical revision: MPAG and PS.

#### REFERENCES

1. Giacomini C. Sull'esistenza dell'os odontoideum' nell'uomo. *Gior Accad Med Torino*. 1886;49:24–8
2. Fielding JW, Hensinger RN, Hawkins RJ. Os odontoideum. *J Bone Joint Surg Am*. 1980;62(3):376–83.
3. Jumah F, Alkhdour S, Mansour S, He P, Hroub A, Adeeb N, et al. Os odontoideum: a comprehensive clinical and surgical review. *Cureus*. 2017;9(8):e1551.
4. Lustrin ES, Karakas SP, Ortiz AO, Cinnamon J, Castillo M, Vaheesan K, et al. Pediatric cervical spine: normal anatomy, variants, and trauma. *Radiographics*. 2003;23(3):539–60.
5. Fielding JW, Hawkins RJ. Atlanto-axial rotatory fixation. (Fixed rotatory subluxation of the atlanto-axial joint). *J Bone Joint Surg Am*. 1977;59(1):37–44.
6. Goel A, Patil A, Shah A, Dandpat S, Rai S, Ranjan S. Os Odontoideum: analysis of 190 surgically treated cases. *World Neurosurg*. 2020;134:e512–23.
7. Watanabe M, Toyama Y, Fujimura Y. Atlantoaxial instability in os odontoideum with myelopathy. *Spine*. 1996;21(12):1435–9.
8. Klimo P Jr, Kan P, Rao G, Apfelbaum R, Brockmeyer D. Os odontoideum: presentation, diagnosis, and treatment in a series of 78 patients. *J Neurosurg Spine*. 2008;9(4):332–42.
9. Spinnato P, Renò E, Girolami M, de Pasqua S, Gasbarrini A. An unexpected cause of transient tetraplegia. *Indian J Pediatr*. 2019;86(12):1164–5.
10. Helenius IJ, Bauer JM, Verhofste B, Sponseller PD, Krengel WF, Hedequist D, et al. Os odontoideum in children: treatment outcomes and neurological risk factors. *J Bone Joint Surg Am*. 2019;101(19):1750–60.