

How I Do It

Posterior nasal cautery with silver nitrate

C.J. WEBB, M.R.C.S.(ED.), H. BEER, M.R.C.S. (ED.)

Abstract

A method of cauterizing the posterior parts of the nose without damage to the anterior mucosa is presented. A silver nitrate stick was sheathed within a cut segment of a nasogastric (NG) tube and endoscopically advanced within the nose until the vessel was reached. The stick was then pushed until the silver nitrate protruded and the vessel was cauterized.

Key words: Epistaxis; Cautery; Silver nitrate

Introduction

Epistaxis due to posteriorly placed vessels can be difficult to cauterize with silver nitrate. Often the silver nitrate on the end of the cautery stick touches the nasal mucosa of the anterior septum, or turbinate, leading to unintentional cautery to these areas, as well as using up the small amount of silver nitrate on the stick. The authors' method of cautery to the posterior parts of the nose avoids this problem.

Method

Malleable silver nitrate sticks from Bray Healthcare were used. A 10 cm section of 16 French gauge nasogastric (NG) tube was cut. The cautery stick was inserted into the lumen of the tube, which then acted as a sheath. The silver nitrate

on the tip of the stick was kept within the sheath and 2.5 cm of the opposite end of the stick was bent at a right angle (Figure 1).

The sheath was held between the index and middle finger. The sheath was then inserted into the patient's anaesthetized and decongested nasal cavity and guided into position by a 0 degree or 30 degree 4 mm rigid endoscope (Figure 2).

When the tip of the sheath was 3 to 4 mm anterior to the bleeding vessel the cautery stick was advanced, by pushing with the thumb on the bent over end of the stick, until the silver nitrate protruded (Figure 3). The vessel could then be cauterized in the usual fashion. After cautery the stick was once again withdrawn into the sheath and then removed from the nose.



FIG. 1

The silver nitrate stick sheathed within the cut NG tube.



FIG. 2

The sheath and endoscope introduced into the nasal cavity.

From the Department of Otorhinolaryngology, Warrington General Hospital, Warrington, Cheshire, UK.
Accepted for publication: 12 May 2004.

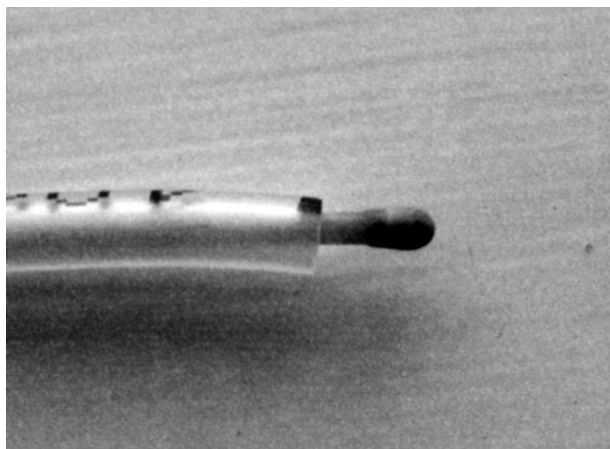


FIG. 3

Close-up view of the silver nitrate protruding beyond the sheath.

Address for correspondence:
Mr Chris Webb,
Specialist Registrar,
Department of Otolaryngology,
Warrington General Hospital,
Lovely Lane,
Warrington,
Cheshire WA5 1QG, UK.

E-mail: cj.webb@ntlworld.com

Mr C.J. Webb takes responsibility for the integrity of the content of the paper.
Competing interests: None declared.
