

Erratum

Basso, W., Edelhofer, R., Zenker, W., Möstl, K., Kübber-Heiss, A. and Prosol, H.
(2004) Toxoplasmosis in Pallas' cats (*Otocolobus manul*) raised in captivity. *Parasitology*
Published online: 21 October 2004. DOI 10.1017/S0031182004006584

During the production stages in the preparation of the above article, published online ahead of print, the wrong image for Fig. 3 was used. The correct version is reproduced below. Please note that the legend is unchanged.

We apologise to the authors and readers for this error.

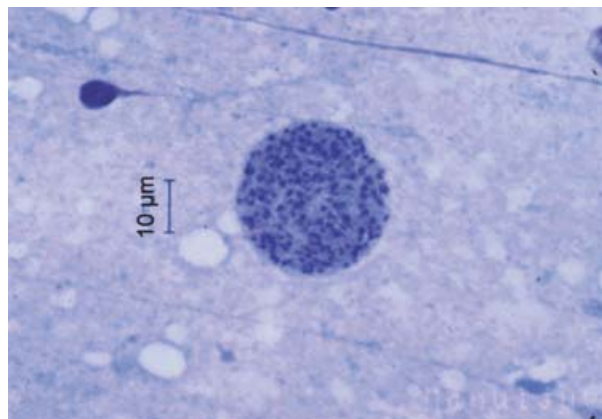


Fig. 3. Tissue cyst of *T. gondii* in Diff Quik[®]-impression smears of brain of the Pallas' cat kitten no. 5.