



Case report: double lung en bloc procurement from a donor after arterial switch operation

Yuriy Stukov^{1,2}, Edward D. Staples^{1,2}, Jeffrey P. Jacobs¹ , Giles J. Peek¹ ,
Tiago N. Machuca² and Mark S. Bleiweis¹

Original Article

Cite this article: Stukov Y, Staples ED, Jacobs JP, Peek GJ, Machuca TN, and Bleiweis MS (2021) Case report: double lung en bloc procurement from a donor after arterial switch operation. *Cardiology in the Young* 31: 1238–1240. doi: [10.1017/S1047951121003589](https://doi.org/10.1017/S1047951121003589)

Received: 31 July 2021
Revised: 5 August 2021
Accepted: 7 August 2021

Keywords:

Double lung transplant; organ donation; organ procurement; transposition of great arteries

Author for correspondence:

M. S. Bleiweis, MD, Congenital Heart Center, UF Health Shands Hospital, Division of Cardiovascular Surgery, Departments of Surgery and Pediatrics, University of Florida, 1600 SW Archer Road, Gainesville, FL 32608, USA. E-mail: bleiweis@ufl.edu

¹Division of Cardiovascular Surgery, Departments of Surgery and Pediatrics, Congenital Heart Center, University of Florida, Gainesville, FL, USA and ²Division of Thoracic Surgery, Department of Surgery, University of Florida, Gainesville, FL, USA

Abstract

The growing unmet demand for suitable organ donors increases each year. Despite relative contraindications for thoracic organ donation after previous cardiac surgery, experienced programmes and surgeons can successfully utilise the lungs from select donors who have undergone prior cardiac surgery. This is the first reported case of double lung en bloc procurement from a donor who had a previous arterial switch operation as an infant.

Case report

A 25-year-old donor with a self-inflicted gunshot to the head was airlifted to a regional hospital. Of note, the donor had undergone a previous arterial switch operation as a treatment for transposition of the great arteries and had a history of reduced ventricular function. The patient was intubated with fixed dilated pupils and absence of reflexes. Computerised axial tomography of the head revealed bilateral cranial injury with anterior frontotemporal brain injury, intraventricular haemorrhage, significant skull base fracture, and diffuse cerebral oedema. The patient rapidly deteriorated and was declared brain dead. Physical examination revealed a vertical sternotomy scar. Computerised axial tomographic angiography of the chest confirmed the presence of radiological evidence of a Lecompte manoeuvre (Fig 1), and revealed that the coronary arteries were patent with no evidence of compression or kinking (Figs 2 and 3). The patient remained haemodynamically stable in the ICU and qualified for the donation of the lungs, liver, and kidneys, after appropriate authorisation from his healthcare surrogate.

Our team learned that this donor had undergone a prior arterial switch operation when we reviewed the United Network for Organ Sharing donor sheet. We then reviewed the already available computerised axial tomographic angiography of the chest of the donor, in order to evaluate the lung donor and plan the operation. Once we accepted the lungs, equipment for a safe reoperative sternotomy was requested from the donor centre ahead of the arrival of the lung donor team, including the Rultract sternal retractor (Rultract Incorporated, 5663 Brecksville Rd., Cleveland Ohio, 44131, United States of America [<http://www.rultract.com/>]).¹

After sterile draping, a midline incision from the neck to the pubis was performed. No sternal wires were detected. The xiphoid was resected. The abdominal team gained access to the abdominal aorta in case cardiac injury occurred during reoperative sternotomy. The Rultract Sternal retractor elevated the sternum away from the heart. Dense pericardial adhesions were cauterised, allowing eventual visualisation of the manubrium from behind. The sternum was divided longitudinally with an oscillating saw. The Rultract was then used to elevate the left half of the sternum to carefully separate the anteriorly located pulmonary artery from the anterior left chest wall. The main pulmonary artery and neo-aorta were identified. The pulmonary arterial pressure was palpably low. The pleural spaces were opened widely, and both lungs were inspected for compliance and anatomy. Both lungs were found to be suitable for transplantation. Zones of atelectasis were inflated to 30 cm of water pressure with a Valsalva manoeuvre. The lungs met acceptable performance and anatomic criteria for this recipient. A circular 4-0 polypropylene (Prolene, Ethicon, Somerville, New Jersey [<https://www.jnjmedicaldevices.com/en-US/companies/ethicon>]) pursestring suture was placed on the anterior main pulmonary artery. After the dissection of the abdominal team was complete, 30,000 units of heparin were administered intravenously and the main pulmonary artery was cannulated. The abdominal aorta was cross-clamped below the diaphragm. The heart was vented through a transverse incision in the neo-aortic root and introduction of a Poole sucker in the right atrium into the inferior caval vein. The lungs were perfused antegrade with 4 L of Perfadex solution (XVIVO Perfusion AB, Box 53015, SE-400 14 Göteborg, Sweden [<https://www.xvivoperfusion.com/wp-content/uploads/2017/12/PERFADEX-PLUS-w-Click-web.pdf>]) through the pulmonary arterial cannula. Five hundred milligrams of prostaglandin E-1 were added to the first bag of Perfadex prior to

© The Author(s), 2021. Published by Cambridge University Press. This is an Open Access article, distributed under the terms of the Creative Commons Attribution licence (<http://creativecommons.org/licenses/by/4.0/>), which permits unrestricted re-use, distribution, and reproduction in any medium, provided the original work is properly cited.

CAMBRIDGE
UNIVERSITY PRESS

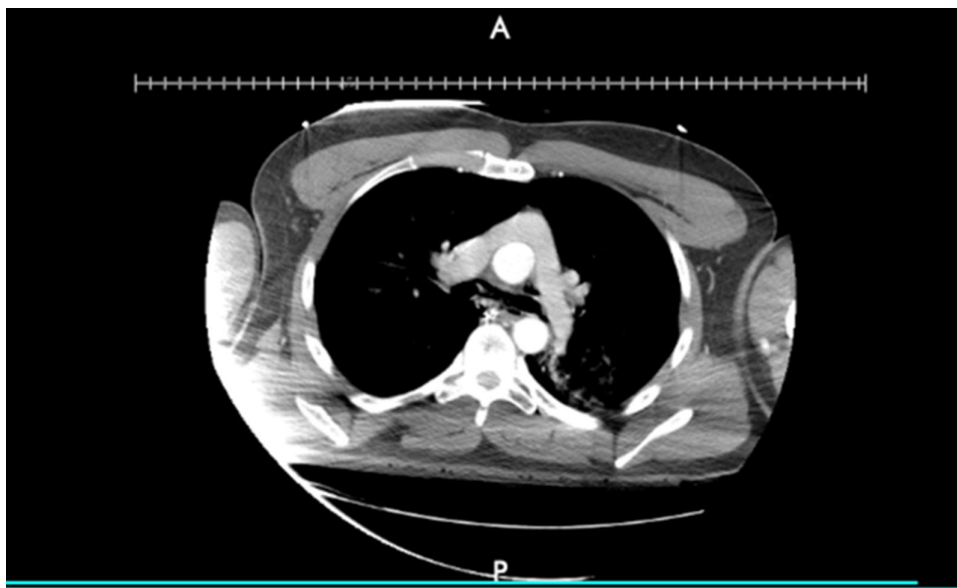


Figure 1. Computerised axial tomographic angiography of the chest: Visualisation of the Lecompte manoeuvre (main pulmonary artery translocated anterior to the aorta).

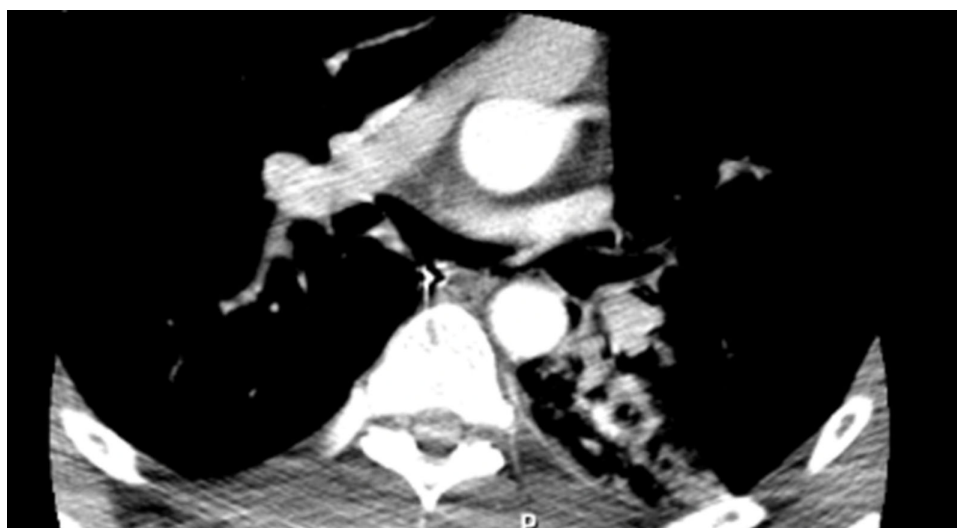


Figure 2. Computerised axial tomographic angiography of the chest: Visualisation of the left main coronary artery.

cross-clamping and administration of pulmonoplegia. Topical ice cooling was performed. No dissection of the pulmonary artery from the aorta was done prior to delivery of pulmonoplegia. After the delivery of pulmonoplegia, the main pulmonary artery was completely transected at the level of the pulmonary valve. The aorta was smaller than the pulmonary artery and was clearly surgically reconstructed. The aorta was sacrificed to allow complete and safe dissection of the pulmonary arteries. Separation of the aorta, right atrium, and ventricular mass was performed slowly and without blood within the vessels.

The heart was removed with the aorta and caval veins, leaving the posterior left atrium intact. Up to 500cc of Perfadex were introduced through each pulmonary vein until the effluent coming out of the pulmonary artery was clear. The trachea was exposed and encircled with a 30 mm stapler. The pericardium was then divided transversely along both diaphragmatic surfaces. Both inferior pulmonary ligaments were divided and the pericardium elevated off of

the oesophagus and aorta superiorly to the level of the tracheal exposure. The lungs were inflated to accomplish the full expansion. The trachea was stapled twice and divided in between the staple lines. The double lung block was removed from the chest and placed into a sterile bag of 4°C Perfadex solution. Two more sterile bags held the inflated lungs, which were transported in an ice-filled cooler to the recipient. Total cold ischaemic time for right and left lungs were 381 and 503 minutes, respectively. The recipient tolerated the procedure well and was discharged from the hospital 19 days after bilateral sequential lung transplantation.

Discussion

Lung transplantation has become the standard of care for suitable patients with end-stage lung disease. The number of patients on the waiting list has been steadily increasing in the recent years, creating even greater pressure to use every possible lung donor. The

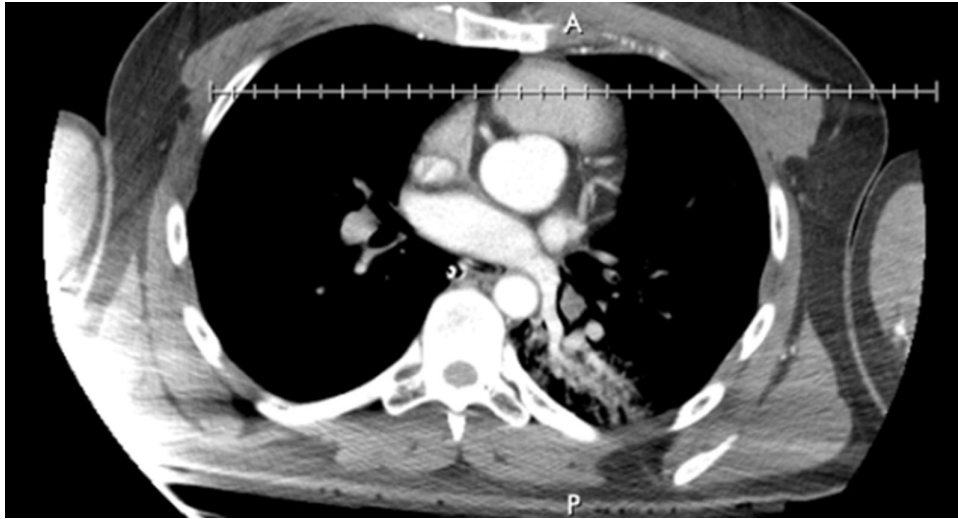

Figure 3. Computerised axial tomographic angiography of the chest: Visualisation of the proximal right coronary artery.

Coronavirus Disease 2019 (COVID-19) pandemic has changed the donor pool and has increased the number of patients requiring lung transplantation after inadequate recovery from infection.^{2,3,4,5} Furthermore, testing accuracies, testing policies, and the prevalence of COVID-19 have impacted the processes of decision-making for the acceptance of donated organs. Lung transplant programmes have extended their selection criteria to donation after circulatory death as well as for donors who are on mechanical circulatory support. Such aggressive strategies for organ acceptance exemplify the importance of in-depth individual evaluation by experienced surgeons in the selection of donors and recipients, as well as in the procurement and transplantation operations. This donor had a history of reduced ventricular function and was therefore not considered for cardiac procurement. It is provocative to think that a heart might be procured from a donor after a prior arterial switch operation if the biventricular function is good.

A donor hospital may not have equipment available for a safe reoperative sternotomy; and therefore, it is important to either ask for this equipment ahead of time or bring it yourself. Our procuring surgeon preferred to use a Rultract Sternal retractor to aid in the safe reoperative sternotomy during this procurement. Consequently, once we accepted the lungs, equipment for a safe reoperative sternotomy was requested from the donor centre ahead of the arrival of the lung donor team, including the Rultract sternal retractor.

This unique case exemplifies all of these considerations.

Conclusions

Procurement of the lungs after previous cardiac surgery is safe with an experienced surgeon and adequate preoperative evaluation. Preoperative comprehensive computerised axial tomographic angiography of the chest is crucial to avoid intraoperative injury.

Technical difficulties with reoperative sternotomy can be overcome with utilisation of the Rultract sternal retractor.

Acknowledgements. None.

Financial support. None.

Conflicts of interest. None.

Ethical standards. The authors assert that all procedures contributing to this work comply with the ethical standards of the relevant national guidelines on human experimentation and with the Helsinki Declaration of 1975, as revised in 2008.

References

- Jacobs JP, Mavroudis C, Quintessenza JA, et al. Reoperations for pediatric and congenital heart disease: an analysis of the society of thoracic surgeons (STS) congenital heart surgery database. *Semin Thorac Cardiovasc Surg Pediatr Card Surg Annu* 2014; 17: 2–8. DOI [10.1053/j.pcsu.2014.01.006](https://doi.org/10.1053/j.pcsu.2014.01.006).
- Lang C, Jaksch P, Hoda MA, et al. Lung transplantation for COVID-19-associated acute respiratory distress syndrome in a PCR-positive patient. *Lancet Respir Med* 2020; 8: 1057–1060. DOI [10.1016/S2213-2600\(20\)30361-1](https://doi.org/10.1016/S2213-2600(20)30361-1).
- Han W, Zhu M, Chen J, et al. Lung transplantation for elderly patients with end-stage COVID-19 pneumonia. *Ann Surg* 2020; 272: e33–e34. DOI [10.1097/SLA.0000000000003955](https://doi.org/10.1097/SLA.0000000000003955).
- Machuca TN, Cypel M, Bharat A. Comment on Let's Build Bridges to Recovery in COVID-19 ARDS, not Burn Them! *Ann Surg* 2020. Epub ahead of print. DOI [10.1097/SLA.0000000000004623](https://doi.org/10.1097/SLA.0000000000004623).
- Jacobs JP, Falasa MP, Machuca TN. Commentary: Extracorporeal membrane oxygenation for patients with refractory Coronavirus Disease 2019 (COVID-19): What do we know and what do we need to learn? *J Thorac Cardiovasc Surg* 2020. Online ahead of print, S0022-5223(20)33219-0. DOI [10.1016/j.jtcvs.2020.11.128](https://doi.org/10.1016/j.jtcvs.2020.11.128).