




## Letter to the Editor: New Observation

# Generalized Dystonia With Tremor and Myoclonus Associated With ANO3 Variant

Daniel G. Di Luca<sup>1,2,3,4</sup> , Talyta C. Grippe<sup>1,2,3</sup> , John Adams<sup>5</sup>, Robert Chen<sup>1,2,3</sup>, Alfonso Fasano<sup>1,2,3</sup> , Andres Lozano<sup>3,6</sup>  
and Anthony E. Lang<sup>1,2,3</sup>

<sup>1</sup>Edmond J. Safra Program in Parkinson's Disease, Morton and Gloria Shulman Movement Disorders Clinic, Toronto Western Hospital, UHN, Toronto, ON, Canada, <sup>2</sup>Division of Neurology, University of Toronto, Toronto, ON, Canada, <sup>3</sup>Krembil Brain Institute, Toronto, ON, Canada, <sup>4</sup>Department of Neurology, Washington University in St. Louis, St. Louis, MO, USA, <sup>5</sup>Ashgrove Medical Centre, Markham, ON, Canada and <sup>6</sup>Department of Neurosurgery, Toronto Western Hospital, University of Toronto, Toronto, ON, Canada

**Keywords:** dystonia; deep brain stimulation; movement disorders; myoclonus; tremor

*ANO3* encodes anoctamin 3, a Ca<sup>2+</sup>-gated chloride channel highly expressed in the striatum.<sup>1</sup> Although controversial *ANO3* variants have been considered a possible rare cause of primary craniocervical dystonia (DYT-*ANO3* or DYT24). The phenotype for this specific mutation ranges from isolated craniocervical dystonia to laryngeal involvement, tremor, and myoclonus. We describe the clinical and electrophysiological features of a patient with *ANO3* mutation manifesting generalized dystonia, tremor, and myoclonus as well as his response to globus pallidus pars interna (GPi) deep brain stimulation (DBS). A 46-year-old right-handed man presented to our clinic for evaluation of abnormal neck posture. His initial symptoms started at the age of 7 years when his family noticed "bilateral inverted feet." This symptom remained stable until the age of 15 years, when he developed abnormal neck posture associated with postural and kinetic tremors of the upper limbs, progressively worsening over the years prior to his presentation to us. There was no diurnal fluctuation or response to alcohol. Levodopa up to 300 milligrams daily (mg/d) provided minimal subjective gait improvement.

He had no other important comorbidities or surgeries, as well as no alcohol, drug, or smoking history. His family history was remarkable for a brother with childhood-onset mild transient symptoms of "inverted foot" that resolved spontaneously at the age of 5 years. Maternal grandfather had Parkinson's disease.

On examination, the patient had craniocervical dystonia and multidirectional head movements, laryngeal tremor, jerky kinetic tremor of both hands, and bilateral foot dystonia, not improved when walking backward or running (Video).

Neurophysiological studies demonstrated an intermittent postural/action tremor with a mean frequency of 3.5 Hz, and myoclonus (possibly of cortical origin) in the lower limbs (Fig. 1a). A magnetic resonance imaging brain revealed white matter hyperintensities involving the superior cerebellar peduncles (Fig. 1c). Genetic dystonia panel was remarkable for a heterozygous variant in the *ANO3* gene, c.887A > G (Tyr296Cys) (not previously reported in GnomAD. In silico parameters: PolyPhen – probably damaging; Align\_gVGD – CO; SIFT – deleterious;

MutationTaster – disease causing; Conservation - nt moderate, aa moderate; Conclusion: uncertain significance) and a heterozygous pathogenic variant in the Tyrosine Hydroxylase (*TH*) gene, c.1375C > T p.(Gln459). Other family members did not undergo genetic testing.

Considering his *TH* mutation and atypical symptoms, cerebrospinal fluid (CSF) neurotransmitters were examined and revealed a slightly reduced homovanillic acid (HVA) (135 nmol/L, reference: 145–324), normal 5-hydroxyindoleacetic acid (70 nmol/L, reference: 67–140), and normal 3-O-methyldopa (27 nmol/L, reference < 100). He was subsequently retried on levodopa 600 mg/d with no benefit. At the age of 48 years, he underwent bilateral GPi DBS, with a moderate objective and subjective improvement of dystonia, especially of his head, neck, and upper limbs (Video).

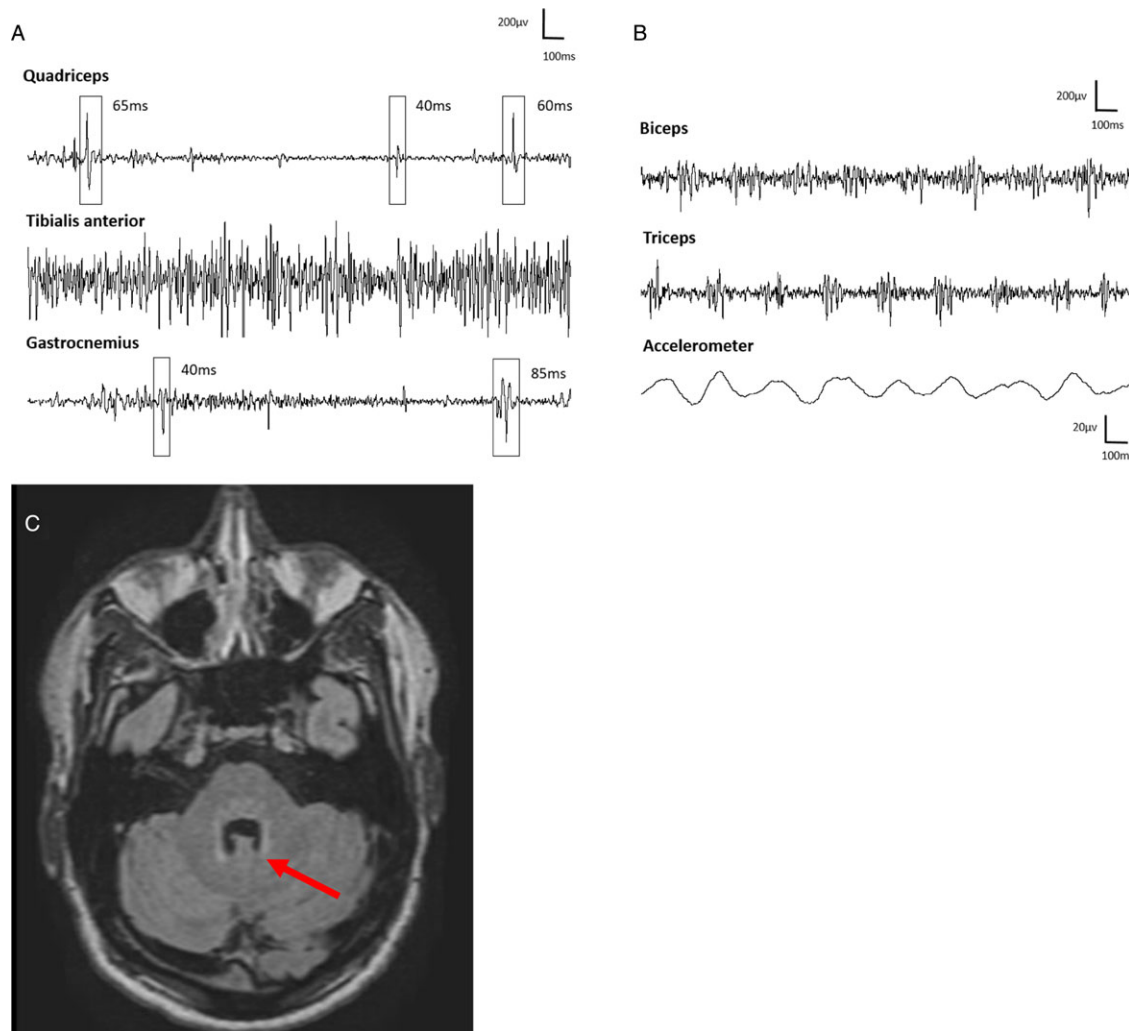
*ANO3* variants are a recently recognized cause of primary dystonia, largely manifesting a spectrum of movements combining craniocervical dystonia with laryngeal involvement and limb tremor.<sup>2,3</sup> Interestingly, superimposed myoclonus, as demonstrated in our patient, has also been described.<sup>4</sup> Most patients develop symptoms during adulthood, however, young-onset has been reported.<sup>3</sup> Our patient presented with bilateral foot dystonia as a child with the later development of craniocervical dystonia, tremor, and myoclonus. To our knowledge, this caudo-rostral progression has not been previously documented with *ANO3* mutations. The phenotypic variability, including varying ages of onset, in this and other genetic dystonias remains largely unexplained. The relationship between *ANO3* variants and dystonia has been a longstanding question in the literature, especially due to the rare occurrence of mutations in this gene and the lack of definitive functional studies. Nevertheless, the most recent MDS Task Force paper on nomenclature of genetic movement disorders has accepted *ANO3* as a confirmed cause of dystonia (OMIM 615034).<sup>5</sup> Our report suggests a potential association with this variant, with a phenotype largely compatible with previously reported cases.

Biallelic mutations in *TH*, encoding for tyrosine hydroxylase, represent a rare cause of dopa-responsive dystonia.<sup>6</sup> Affected

**Corresponding author:** D. G. Di Luca; Email: dilucadaniel@wustl.edu

**Cite this article:** Di Luca DG, Grippe TC, Adams J, Chen R, Fasano A, Lozano A, and Lang AE. (2024) Generalized Dystonia With Tremor and Myoclonus Associated With *ANO3* Variant. *The Canadian Journal of Neurological Sciences* 51: 698–700, <https://doi.org/10.1017/cjn.2023.282>

© The Author(s), 2023. Published by Cambridge University Press on behalf of Canadian Neurological Sciences Federation.



**Figure 1:** Multichannel surface electromyography (EMG) and accelerometer recording. (a) Spontaneous brief contractions, suggestive of myoclonus recorded while performing knee flexion/extension movements with the foot dorsiflexed. (b) Postural tremor recorded from the right arm with arms in the wing position. There were rhythmic, alternating EMG bursts with mean frequency of 3.5 Hz involving mainly the biceps and triceps muscles. (c) Brain MRI demonstrating high signal abnormalities in the superior cerebellar peduncles and dorsal pons.

individuals typically have an early age of onset. The presence of lower limb dystonia with gradual progression to generalized dystonia is a commonly reported clinical presentation. There is often diurnal fluctuation and a remarkable response to levodopa. Additional findings such as low CSF HVA levels can support the diagnosis. Interestingly, white matter hyperintensities involving the superior cerebellar peduncles, among other areas, were described in a severely affected biallelic tyrosine hydroxylase mutation carrier, but to our knowledge, these have not been seen in association with ANO3 mutations. Although a severe phenotype is typical of biallelic mutations and heterozygous mutations are generally thought to be asymptomatic, our group has recently reported a patient with an extremely mild phenotype of levodopa-responsive lower extremity dystonia associated with a heterozygous *TH* mutation.<sup>7</sup>

Treatment of DYT-ANO3 remains symptomatic with oral medications and botulinum toxin injections when appropriate. Globus pallidus pars interna deep brain stimulation has been described in at least five other cases, with partial benefit (including gait), although in one, status dystonicus was not improved.<sup>8</sup> Our patient has undergone a GPi DBS with a considerable

improvement of the upper body symptoms. However, dystonia in his feet took longer to improve, in keeping with the notion that phasic dystonic movements of the upper body tend to respond earlier and better to GPi DBS.

This report further highlights an unusual case of craniocervical dystonia combined with tremor and myoclonus, with a potential association with a poorly recognized ANO3 variant. Perhaps, as more cases are described, childhood-onset generalized dystonia will be recognized as part of the spectrum of this disorder. We also add to the limited literature on the response of DYT-ANO3 to GPi DBS.

**Supplementary material.** The supplementary material for this article can be found at <http://doi.org/10.1017/cjn.2023.282>.

**Funding.** None.

**Competing interests.** None.

**Ethical compliance statement.** We confirm that we have read the Journal's position on issues involved in ethical publication and affirm that this work is consistent with those guidelines.

## References

1. Charlesworth G, Plagnol V, Holmstrom KM, et al. Mutations in ANO3 cause dominant craniocervical dystonia: ion channel implicated in pathogenesis. *Am J Hum Genet.* 2012;91:1041–50.
2. Olschewski L, Jesus S, Kim HJ, et al. Role of ANO3 mutations in dystonia: a large-scale mutational screening study. *Parkinsonism Relat Disord.* 2019;62:196–200.
3. Li S, Wang L, Yang Y, Ma J, Wan X. ANO3 mutations in chinese dystonia: a genetic screening study using next-generation sequencing. *Front Neurol.* 2019;10:1351.
4. Stamelou M, Charlesworth G, Cordivari C, et al. The phenotypic spectrum of DYT24 due to ANO3 mutations. *Mov Disord.* 2014;29:928–34.
5. Lange LM, Gonzalez-Latapi P, Rajalingam R, et al. Nomenclature of genetic movement disorders: recommendations of the international parkinson and movement disorder society task force-an update. *Movement Disorders.* 2022;37:905–35.
6. Wijemanne S, Jankovic J. Dopa-responsive dystonia—clinical and genetic heterogeneity. *Nat Rev Neurol.* 2015;11:414–24.
7. Bally JF, Breen DP, Schaake S, et al. Mild dopa-responsive dystonia in heterozygous tyrosine hydroxylase mutation carrier: evidence of symptomatic enzyme deficiency? *Parkinsonism Relat Disord.* 2020; 71:44–5.
8. Tisch S, Kumar KR. Pallidal deep brain stimulation for monogenic dystonia: the effect of gene on outcome. *Front Neurol.* 2021;11:630391.