

## Simple underlay myringoplasty

M SAKAGAMI, R YUASA\*, Y YUASA\*

### Abstract

**Objective:** To introduce simple underlay myringoplasty which is widely performed in Japan.

**Patients:** 391 ears with perforated eardrum underwent simple underlay myringoplasty from 2000 to 2004, and which were followed up for more than six months after surgery.

**Methods:** After removing the margin of the perforation by a transcanal approach under local anaesthesia, a connective tissue graft was inserted through the perforation and lifted to contact the edge. Fibrin glue was dropped on the contact area. There was no packing in the canal or in the middle-ear cavity. If the perforation remained, re-closure was attempted using the patient's frozen tissue.

**Results:** The rate of closure after the initial attempt was 304/391 (77.7 per cent), and that after re-closure for unsuccessful cases was 70/87 (80.5 per cent). The overall rate was 374/391 (95.7 per cent). There were no serious complications such as sensorineural hearing loss.

**Conclusions:** Simple underlay myringoplasty is a simple and minimally invasive procedure employing fibrin glue and has led to a high closure rate of the eardrum.

**Key words:** Myringoplasty; Chronic Otitis Media; Tympanic Membrane Perforation; Fibrin Tissue Adhesive

### Introduction

To close a tympanic membrane perforation, myringoplasty with a postauricular incision has been routinely performed all over the world for the past four decades and surgeons have chosen a preferred method among underlay, overlay, and inlay (sandwich) techniques. Transcanal techniques have also been attempted to simplify myringoplasty using fat,<sup>1</sup> micropore tape,<sup>2,3</sup> attero-collagen,<sup>4</sup> cellophane sheet<sup>5</sup> and so on. Results were successful for the traumatic eardrum; however, they were not satisfactory for chronic otitis media when compared with the conventional myringoplasty.<sup>5,6</sup>

For transcanal closure of a tympanic perforation in chronic otitis media, Yuasa<sup>7</sup> developed simple underlay myringoplasty with fibrin glue in 1989. Simple underlay myringoplasty has been widely performed in Japan over the last 15 years because of its high success rate of eardrum closure and very low risk of sensorineural hearing loss.<sup>8–10</sup>

The aims of the present study were to introduce simple underlay myringoplasty procedures to European and American doctors and to examine both the rate of closure of tympanic membrane perforations under various pre-operative conditions and the hearing results.

### Subjects and methods

#### Subjects

Five hundred and fifty-four ears with tympanic perforation underwent simple underlay myringoplasty at Sendai Ear Surgicenter between 2000 and 2004. Out of them, 391 ears were followed up more than six months after surgery, and post-operative results of 391 ears were analysed in this study. They were 185 male patients and 206 female patients with a mean age of 45.6 years (range: 4–87 years). The average follow-up period was 23.0 months (6–80 months). Cholesteatoma and adhesive otitis media were excluded. The cause of tympanic perforation was chronic otitis media in 250 (63.9 per cent), trauma in 57 (14.6 per cent), insertion of a tympanic ventilation tube in 62 (15.9 per cent) and paracentesis in 22 (5.6 per cent). The post-operative status of the eardrum was assessed six months after surgery.

Indications for simple underlay myringoplasty were for cases with a simple dry perforation, those without cholesteatoma, those with hearing gain in a paper patch, and those without shadow in the attic on computed tomography (CT).

From the Department of Otolaryngology, Hyogo College of Medicine, Nishinomiya City, Hyogo and the \*Sendai Ear Surgicenter, Shougen, Izumi-ku, Sendai City, Miyagi, Japan.

Partially presented at the 139th Annual Meeting of the American Otological Society, 20–21 May 2006, Chicago, USA.

Accepted for publication: 23 October 2006.

### Surgical procedures

Local anaesthesia was generally applied in simple underlay myringoplasty, except for children under 10 years. The remnant of the eardrum was anaesthetised with a few small cotton balls with anesthetic solution (20 g of lidocaine, 20 g of phenol, 20 g of menthol, and 20 ml of glycerin in 100 ml of solution). About 15 minutes later, the remnant of the eardrum changed to a whitish colour.

The anaesthetised margin of the perforation was cut and removed with a fine pick through an ear speculum to make a vascular bed for grafting. Generally, no skin incision was required in the meatal skin.

Subcutaneous tissue or temporalis fascia harvested from the retroauricular region after local anaesthesia was used for the graft. Subcutaneous connective tissue is preferred to temporalis muscle fascia in simple underlay myringoplasty because thick subcutaneous connective tissue is better at adapting to the vascular bed than a thin fascia graft.

The harvested graft was trimmed to twice the diameter of the perforation. The centre of the graft was then marked with a marker pen. A portion of the remaining graft material was kept in the freezer between  $-18^{\circ}\text{C}$  and  $-20^{\circ}\text{C}$  to be used for repairing any perforation in the post-operative course. The repair procedure was performed in the same way as simple underlay myringoplasty.

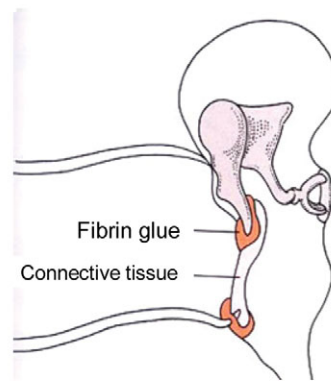
The trimmed graft was stretched in the middle-ear cleft and placed at the centre of the perforation. Then, the stretched graft was lifted to place the marked area at the centre of the perforation and attached to the inner side of the remnant of the eardrum so that the perforation was completely closed by the graft (Figure 1a and b). After checking to ensure graft contact to the margin of the perforation, a few drops of fibrin glue were applied at the contact area. In this method, no packing is necessary in either the middle-ear cleft or the external ear canal.

### Post-operative assessment

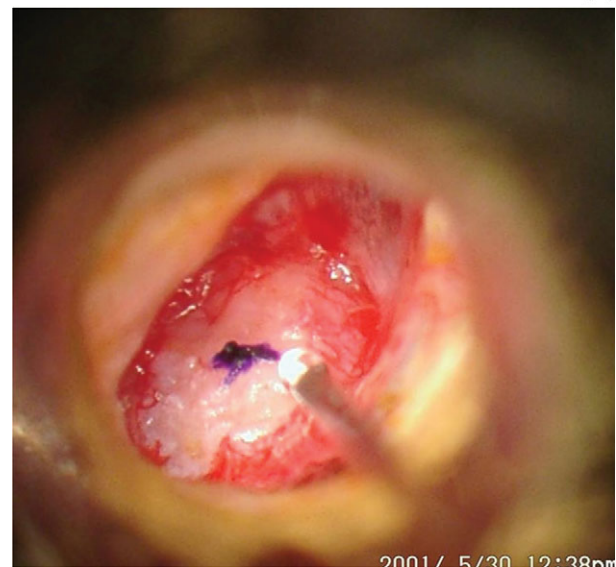Whether the tympanic membrane perforation was closed or not was checked during the post-operative course and finally at six months after surgery. The relationships between the rate of closure and the size of perforation, between the rate of closure and the cause of perforation, and between the rate of closure and the presence of otorrhoea were analysed by the chi-square test. For post-operative hearing, the air–bone gap was assessed at an average of three speech frequencies at least six months after surgery.

### Results

The contact of the graft could be observed just after surgery because there was no packing in the ear canal (Figure 2a). One day after surgery, the graft was stuck to the margin of the perforation (Figure 2b). One month after surgery, new blood vessels had penetrated the surface of the graft and



(a)



(b)

FIG. 1

(a) The graft is underlined and fixed with a few drops of fibrin glue. (b) The mark is placed at the centre of the perforation to ensure contact of the graft to the margin of the perforation.

it was being epithelialised (Figure 2c). Six months after surgery, the eardrum was completely epithelialised (Figure 2d). The rate of closure after the initial attempt was 304/391 (77.7 per cent), and the rate after re-closure for unsuccessful cases was 70/87 (80.5 per cent). The overall rate was 374/391 (95.7 per cent).

For the relationship between the rate of closure and the size of perforation, the failure rate of closure was 11/42 (26.2 per cent) for large-sized perforations (more than three quadrants), 31/115 (27.0 per cent) for middle-sized perforations (between one and two quadrants), and 45/234 (19.2 per cent) for small-sized perforations (less than one quadrant). They did not show significant differences ( $p = 0.2141$ , chi-square test) (Table I).

For the relationship between the rate of closure and frequency of otorrhoea, we were able to examine 373/391 cases because the frequency of otorrhoea remained unclear in the other 18 cases. The failure rate of closure was 61/300 (20.3 per cent) in ears without otorrhoea, 15/54 (27.7 per cent)

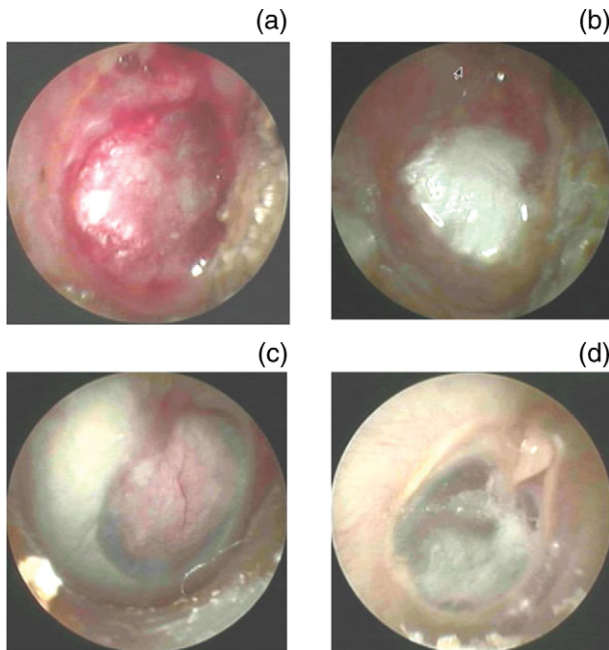


FIG. 2

The condition of the transplanted graft during the post-operative course. (a) Just after completing the procedure; (b) one day after surgery; (c) vascularisation is observed one month after surgery; (d) a thinner graft is observed six months after surgery.

in ears with otorrhoea several times per year, and 6/19 (31.6 per cent) in ears with continuous otorrhoea. They showed no significant difference ( $p = 0.2790$ ) (Table II).

For the relationship between the rate of closure and the cause of perforation, the failure rate of closure was 48/250 (19.2 per cent) in chronic otitis media and 39/141 (27.7 per cent) in traumatic perforation caused by trauma, ventilation tube, and paracentesis. They showed no significant difference ( $p = 0.0535$ ) (Table III).

Of 391 ears, six ears were excluded from hearing assessment because of total hearing loss. The pre-operative air-bone gap (ABG) was  $15.2 \pm 8.3$  dB, and post-operative ABG  $5.1 \pm 8.5$  dB. Pre-operative ABG less than 10 dB was 125/385 (32.5 per cent), that between 10 and 20 dB was 172/385 (44.7 per cent) and that more than 20 dB was 88/385 (22.8 per cent). Post-operative ABG less than 10 dB was 291/385 (75.6 per cent), that between 10 and 20 dB was 82/385 (21.3 per cent), and that more than 20 dB was 12/385 (3.1 per cent). (Figure 3).

TABLE I

FAILURE RATE OF THE INITIAL ATTEMPT TO CLOSE THE EARDRUM FROM THE STANDPOINT OF PERFORATION SIZE

Perforation size	Small	Middle sized	Large
Failure rate %	19.2	27.2	26.2

$p = 0.2141$ , chi-square test

TABLE II

FAILURE RATE OF THE INITIAL ATTEMPT TO CLOSE THE EARDRUM FROM THE STANDPOINT OF OTORRHOEA FREQUENCY

Otorrhoea frequency	None	Sometimes	Frequent
Failure rate %	20.3	27.7	31.6

$p = 0.2790$ , chi-square test

There were no serious complications in this series or in cases of tympanoplasty (ossiculoplasty and simple underlay myringoplasty) in other reports.<sup>6</sup> A few cases showed mild dizziness, nausea, and vomiting which generally disappeared after several hours without requiring treatment.

**Discussion**

There are several reasons why simple underlay myringoplasty has been widely performed in Japan over the past 15 years. First, perforation closure with a paper patch or tape has not been performed for persistent tympanic membrane perforation of chronic otitis media, but has been generally performed in fresh cases of traumatic perforation or after ventilation tube removal.<sup>2-4</sup> On the other hand, simple underlay myringoplasty can be applied to persistent tympanic perforation because the margin of the perforation is cut and freshened to make a reliable vascular bed for grafting at the beginning of the procedure.

Second, simple underlay myringoplasty requires only a short and shallow retroauricular incision to harvest the graft material without a meatal skin incision. It can be performed under local anaesthesia with several small cotton balls with anaesthetic solution at the remnant of the eardrum. The total operation time including anaesthesia is usually less than one hour. Therefore, simple underlay myringoplasty is a so-called 'minimally invasive surgery', and can also be applied in office surgery.

Third, the success rate of closure after the initial attempt was 304/391 (77.7 per cent). However, the overall rate after re-closure for unsuccessful cases with the autologous frozen material was 374/391 (95.7 per cent), which was comparable to that of the conventional methods. The repair with autologous frozen material at the clinic is one of the important parts of simple underlay myringoplasty.

Fourth, there were no serious complications such as sensorineural hearing loss in this series or in other series of tympanoplasty (ossiculoplasty and simple underlay myringoplasty).<sup>6</sup> Therefore, simple underlay

TABLE III

FAILURE RATE OF THE INITIAL ATTEMPT TO CLOSE THE EARDRUM FROM THE STANDPOINT OF THE CAUSE OF THE PERFORATION

Cause of perforation	Infection	Trauma
Failure rate %	19.2	27.7

$p = 0.0535$ , chi-square test

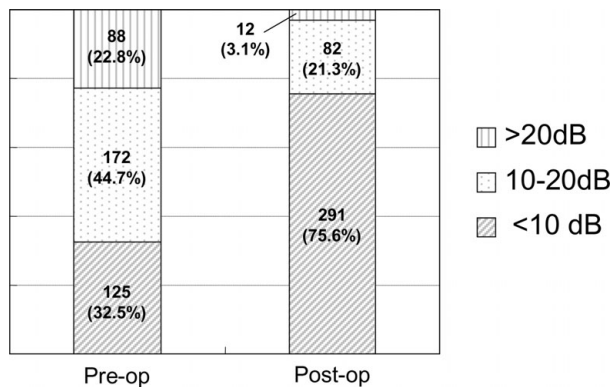


FIG. 3

Comparison of the air–bone gap pre- and post-operation.

myringoplasty was safely introduced to bilateral same-day surgery for bilateral perforated chronic otitis media.<sup>10,11</sup> Simple underlay myringoplasty can also be performed for perforated chronic otitis media with an only hearing ear to prevent hearing deterioration.<sup>12,13</sup>

Fifth, no packing is necessary in either the external ear canal or the tympanic cavity. Therefore, the patient feels an improvement in hearing immediately after the operation, and the condition of the graft can be continuously observed through the post-operative course (Figures 2 a,b,c,d).

On the other hand, there are a few disadvantages of simple underlay myringoplasty. Firstly, fibrin glue is necessary to fix the graft to the freshened margin of the perforation. Fibrin glue is approved for ear surgery in Japan, but not in the USA. It also has a risk of unknown viral infection. Furthermore, fibrin glue is a relatively expensive material and increases the economic burden on both the patients and insurance companies. As a means to solve this problem, autologous fibrin glue can be made and kept before the operation, although this takes time and effort.<sup>14</sup>

- **Simple underlay myringoplasty is widely performed for closure of tympanic membrane perforation in Japan**
- **This procedure is performed by a transcanal approach with local anaesthesia. It includes cutting of the margin of the perforation, placement of the connective tissue graft in the tympanic cavity, lifting the graft and finally securing it with fibrin glue**
- **In this series of 391 cases the rate of closure after the initial attempt was 304/391 (77.7 per cent), and overall rate after re-closure was finally 374/391 (95.7 per cent)**

Secondly, all simple underlay myringoplasty procedures have to be carried out in the ear

speculum, except for harvesting the graft material. Working space is thus limited when compared to conventional tympanoplasty with retroauricular incision. Therefore, it takes time for otosurgeons who are used to the conventional method to perform simple underlay myringoplasty effectively.

Recently, we have applied simple underlay myringoplasty to transcanal tympanoplasty after finishing ossiculoplasty in chronic otitis media. After debridement of the margin of the perforation, a canal skin incision is made at about 5 mm outside the posterior annulus, and posterior canal skin is elevated. When movement of the malleus handle is poor, (1) calcification of the anterior part of the malleus neck is removed or (2) transcanal atticotomy is performed with a small-sized chisel, calcification around the malleus and incus is removed as much as possible, and then the defect of the bony meatus is reconstructed with soft tissue. Finally, a new eardrum is constructed with simple underlay myringoplasty.

## Conclusion

In conclusion, simple underlay myringoplasty is a simple and minimally invasive procedure using fibrin glue, showing a high rate of eardrum closure and very few complications not only for cases with traumatic perforation but also for those with chronic otitis media.

## References

- 1 Camnitz PS, Bost WS. Traumatic perforations of the tympanic membrane: early closure with paper tape patching. *Otolaryngol Head Neck* 1985;**93**:220–3
- 2 Saito H, Kazama Y, Yazawa Y. Simple maneuver for closing traumatic eardrum perforation by micro-pore strip tape patching. *Am J Otolaryngol* 1990;**11**: 427–30
- 3 Ringenberg JC. Closure of tympanic membrane perforations by the use of fat. *Laryngoscope* 1978;**88**: 982–93
- 4 Sakota T, Shibano A, Saitoh Y, Dake Y, Sogo H, Fujimura S *et al.* An office technique without the use of fibrin glue [in Japanese]. *Nihon Jibiinkoka Gakkai Kaiho (Tokyo)* 2000;**103**:836–9
- 5 Amadasum JE. An observational study of the management of traumatic tympanic membrane perforation. *J Laryngol Otol* 2002;**116**:181–4
- 6 Yuasa R, Takasaka T. Persistent perforation after tympanoplasty. In: Alper CM, Bluestone CD, Casselbrant ML, eds. *Advanced Therapy of Otitis Media*. Ontario BC: Decker, 2004;440–6
- 7 Yuasa R, Saijo S, Tomioka Y, Kusakari C, Kakehata S, Katori Y *et al.* Office closure of eardrum perforation with fibrin glue [in Japanese]. *Otolaryngol Head Neck Surg (Tokyo)* 1989;**61**:1117–22
- 8 Yuasa R, Suetake M, Kaneko Y, Kanbayashi J. A new simple myringoplasty with fibrin glue. In: Yanagihara N, Suzuki J, eds. *Transplants and Implants in Otolaryngology*. Amsterdam: Kugler Publications, 1992; 207–10
- 9 Yuasa R. A new underlay myringoplasty with use of fibrin glue as minimally invasive surgery. In: Sanna M, ed. *Cholesteatoma and Mastoid Surgery*. Rome: CIC Internazionale; 1997;854–8

- 10 Sakagami M, Mishiro Y, Tsuzuki , Seo T, Sone M. Bilateral same day surgery for bilateral perforated chronic otitis media. *Auris Nasus Larynx* 2000;**27**:35–8
- 11 Katsura H, Sakagami M, Tsuji K, Muto T, Okunaka M, Mishiro Y *et al.* Reevaluation of bilateral same-day surgery for bilateral perforated chronic otitis media. *Otol Neurotol* 2005;**26**:842–5
- 12 Sakagami M, Muto T, Adachi O, Mishiro Y, Fukazawa K. Surgical management of only hearing ears with positive indications. *J Laryngol Otol* 2006;**120**:972–5
- 13 Sakagami M, Maeda A, Node M, Sone M, Mishiro Y. Long-term observation on hearing change in patients with chronic otitis media. *Auris Nasus Larynx* 2000;**27**: 117–20
- 14 Park MS. Autologous fibrin glue for tympanoplasty. *Am J Otol* 1994;**15**:687–9

Address for correspondence:  
Masafumi Sakagami,  
Department of Otolaryngology,  
Hyogo College of Medicine,  
Mukogawa, Nishinomiya,  
Hyogo 663–8501,  
Japan.

Fax: 81 798 41 8976  
E-mail: msakaga@hyo-med.ac.jp

---

Dr M Sakagami takes responsibility for the integrity of the content of the paper.

Competing interests: None declared

---