

# Treatment Outcomes in 1p19q Co-deleted/Partially Deleted Gliomas

Mairéad G. McNamara, Haiyan Jiang, Mary Jane Lim-Fat, Solmaz Sahebjam, Tim-Rasmus Kiehl, Jason Karamchandani, Claire Coire, Caroline Chung, Barbara-Ann Millar, Normand Laperriere, Warren P. Mason

**ABSTRACT:** *Background:* Radiotherapy with procarbazine, lomustine, and vincristine improves overall survival (OS) in patients with 1p19q co-deleted anaplastic oligodendroglioma/anaplastic oligoastrocytoma. *Methods:* This retrospective analysis investigated outcomes in patients with 1p19q co-deleted/partially deleted oligodendroglioma, oligoastrocytoma, anaplastic oligodendroglioma, or anaplastic oligoastrocytoma. OS and progression-free survival (PFS) were analyzed using the Kaplan-Meier method and prognostic factors using the Cox proportional hazard model. *Results:* A total of 106 patients (between December 1997 and December 2013) were included. Median age was 40 years (19-66), 58 were male (55%), Eastern Cooperative Oncology Group performance status was 0 in 80 patients (75%). 1p19q status was co-deleted in 66 (62%), incompletely co-deleted in 27 (25%), and 1p or 19q loss alone in four (4%) and nine (8%) patients, respectively. Isocitrate dehydrogenase-1 R132H mutation was found in 67 of 85 patients with sufficient material. Upfront treatment was given in 72 (68%) patients and temozolomide alone in 52 (49%). Median time to radiotherapy in 47 patients (44%) was 34.7 months and 41.2 months in 9 patients with co-deleted/incompletely co-deleted anaplastic oligodendroglioma/anaplastic oligoastrocytoma who received upfront temozolomide alone. Median OS was not reached and 5-year OS was 91% for all groups (median follow-up, 5.1 years). On multivariable analysis for all patients, receipt of therapy upfront versus none ( $p = 0.04$ ), PS 1 versus 0 ( $p < 0.001$ ) and 1p19q co-deletion/incomplete deletion versus 1p or 19q loss alone ( $p = 0.005$ ) were prognostic for PFS. Isocitrate dehydrogenase-1 status was not prognostic for PFS. *Conclusions:* With similar survival patterns in low-grade/anaplastic gliomas, molecular characteristics may be more important than histological grade. Longer follow-up and results of prospective trials are needed for definitive guidance on treatment of these patients.

**RÉSUMÉ:** *Résultats d'un traitement appliqué à des gliomes associés à des codélétions 1p/19q et des délétions partielles.* *Contexte:* À l'instar de la procarbazine, de la lomustine et de la vincristine, les traitements de radiothérapie améliorent le taux de survie général des patients atteints d'oligodendrogliomes/oligoastrocytomes anaplasiques associés à des codélétions 1p/19q. *Méthodes:* Cette analyse rétrospective s'est penchée sur les résultats d'un traitement offert à des patients atteints d'oligodendrogliomes/oligoastrocytomes et d'oligodendrogliomes/oligoastrocytomes anaplasiques associés à des codélétions/délétions partielles. La survie générale (overall survival) et la survie sans progression (SSP) ont été analysées au moyen de l'estimateur de Kaplan-Meier et de facteurs pronostiques faisant appel au modèle à risques proportionnels de Cox. *Résultats:* Entre décembre 1997 et décembre 2013, un total de 106 patients ont été inclus dans cette étude. Leur âge médian était de 40 ans (19-66) ; 55% d'entre eux étaient de sexe masculin ( $n = 58$ ). L'échelle de l'Eastern Cooperative Oncology Group était de 0 chez 80 patients (75%). Des codélétions 1p/19q ont été observées chez 66 patients (62%) ; des codélétions incomplètes ont été observées chez 27 d'entre eux (25%) ; enfin, des pertes liées aux chromosomes 1p ou 19q ont été notées chez quatre (4%) et neuf (8%) patients respectivement. On est aussi parvenu à détecter une mutation de l'isocitrate déshydrogénase-1 R132H chez 67 patients sur les 85 qui possédaient assez de matériel génétique. Un traitement initial a été administré à 72 patients (68%), par exemple uniquement de la témozolomide à 52 d'entre eux (49%). Chez 47 patients (44%), la durée médiane de radiothérapie a été de 34,7 mois ; dans le cas de 9 patients atteints d'oligodendrogliomes/oligoastrocytomes anaplasiques associés à des codélétions complètes ou incomplètes à qui l'on n'avait administré qu'un traitement initial à la témozolomide, elle a été de 41,2 mois. Il n'a pas été possible d'obtenir la survie générale moyenne ; toutefois, une survie générale de 5 ans a été de 91% pour tous les groupes (suivi médian : 5,1 ans). Une analyse multivariable de tous les patients a aussi révélé les résultats suivants : administration d'un traitement initial contre aucun traitement ( $p = 0,04$ ) ; échelle de performance 1 contre 0 ( $p < 0,001$ ) ; et codélétion complète/incomplète 1p/19q contre les seules pertes de chromosomes 1p ou 19q ( $p = 0,005$ ). Ces résultats ont été pronostiqués en ce qui regarde la SSP. L'état de l'isocitrate déshydrogénase-1 n'a, quant à lui, pas été pronostiqué en ce qui regarde la SSP. *Conclusions:* Compte tenu des profils de survie similaires en ce qui a trait aux gliomes anaplasiques de bas grade, il se peut que des caractéristiques moléculaires soient plus importantes que le grade histologique. Un suivi à plus long terme ainsi que des études prospectives sont donc nécessaires afin de pouvoir compter sur des orientations définitives concernant le traitement de ces patients.

From the Department of Medical Oncology, Princess Margaret Cancer Centre, Toronto, Canada (MGNM, MJL-F, WPM); Department of Medical Oncology, The Christie NHS Foundation Trust/University of Manchester, Institute of Cancer Sciences, Manchester, UK (MGNM); Department of Biostatistics, Princess Margaret Cancer Centre, Toronto, Canada (HJ); Department of Medical Oncology, Moffitt Cancer Centre, Tampa, Florida (SS); Department of Pathology, University Health Network, Toronto, Canada (T-RK); Department of Pathology, St. Michael's Hospital, Toronto, Canada (JK); Department of Pathology, Trillium Health Centre, Mississauga, Canada (C Coire); Department of Radiation Oncology, Princess Margaret Cancer Centre/University of Toronto, Canada (C Chung, B-AM, NL); Department of Radiation Oncology, MD Anderson Cancer Centre, Houston, Texas (C Chung).

RECEIVED DECEMBER 19, 2015. FINAL REVISIONS SUBMITTED OCTOBER 6, 2016. DATE OF ACCEPTANCE OCTOBER 7, 2016.

Address correspondence to: Mairéad G. McNamara, Department of Medical Oncology, The Christie NHS Foundation Trust/University of Manchester, Institute of Cancer Sciences, Manchester M20 4BX, UK Email: Mairéad.McNamara@christie.nhs.uk

**Keywords:** Gliomas, 1p19q co-deletion, temozolomide, *IDH-1* status

doi:10.1017/cjn.2016.420

Can J Neurol Sci. 2017; 44: 288-294

In gliomas, co-deletions of chromosomes 1p and 19q are associated with tumors with “oligodendroglial” morphology. This co-deletion of chromosome regions 1p36/19q13 in oligodendrogliomas was discovered in 1994 and was subsequently found to derive from an unbalanced translocation at (1;19)(q10;p10).<sup>1</sup> Combined alterations have been observed in up to 70% of oligodendrogliomas and 50% of mixed oligoastrocytomas.<sup>2,3</sup> Besides being a relevant diagnostic marker, 1p19q loss has been validated for its prognostic relevance in anaplastic oligodendroglial tumors and mixed oligoastrocytomas. Although 1p19q co-deletion is also present in astrocytomas and mixed oligoastrocytomas,<sup>2,3</sup> it has been shown to predict increased chemosensitivity in oligodendroglial tumors in particular.<sup>4,5</sup> The 1p19q co-deletion status is also associated with frontal lobe location and the presence of *isocitrate dehydrogenase (IDH)* mutations.<sup>6</sup>

Responses to procarbazine, lomustine, and vincristine (PCV) were first reported in small series of patients with recurrent oligodendroglioma and oligoastrocytoma in 1988<sup>7</sup> and 1992,<sup>8</sup> respectively. These studies led to randomized phase III trials Radiation Therapy Oncology Group (RTOG) 9402<sup>5</sup> and European Organisation for Research and Treatment of Cancer (EORTC) 26951<sup>4</sup> to clarify the role of PCV chemotherapy in anaplastic oligodendroglioma and anaplastic oligoastrocytoma. Long-term results of RTOG 9402 and EORTC 26951 indicated that patients whose tumors harbored a 1p19q co-deletion benefited from early addition of PCV chemotherapy to radiotherapy; a significant improvement in overall survival (OS) was demonstrated compared with early radiotherapy, even with salvage chemotherapy at tumor relapse.<sup>4,5</sup>

Long-term follow up of RTOG 9802 reported that in patients with high-risk grade II gliomas (with less than gross total tumor resection or who were more than 40 years of age), radiotherapy plus PCV also prolonged both progression-free survival (PFS) and OS, compared with radiotherapy alone.<sup>9</sup>

However, there are still unanswered questions regarding whether upfront chemotherapy, omitting/deferring radiotherapy, to avoid or delay the late neurocognitive toxicity of radiotherapy should be the initial therapy for anaplastic oligodendroglial tumors with co-deleted 1p19q, or whether temozolomide can be substituted for PCV chemotherapy, the former being an oral agent with a superior toxicity profile. Additionally, it is unknown whether excluding radiotherapy from initial management of these tumors impacts unfavorably on survival.

The aim of this study was to review retrospectively outcomes in patients treated at a large academic centre with a diagnosis of 1p19q co-deleted/partially deleted oligodendroglioma, oligoastrocytoma, anaplastic oligodendroglioma, or anaplastic oligoastrocytoma and also to examine outcomes in those treated with upfront temozolomide alone.

## MATERIALS AND METHODS

### Patient Population

After receiving institutional research ethics board approval, treatment and follow-up data were retrospectively reviewed

for patients with a diagnosis of 1p19q co-deleted/partially deleted oligodendroglioma, oligoastrocytoma, anaplastic oligodendroglioma, or anaplastic oligoastrocytoma, according to the World Health Organisation (WHO) classification for brain tumors,<sup>10-12</sup> who underwent treatment at a tertiary cancer institution (Princess Margaret Cancer Centre, Toronto, Canada) in the temozolomide treatment era. Patients without 1p/19q co-deletion/partial deletion were not included in this study.

### Treatment

In patients who underwent surgery, partial resection was defined as <90% tumor removal and subtotal resection was defined as <100% but >90% tumor removal. Temozolomide was administered at a dose of 150 to 200 mg/m<sup>2</sup> (days 1-5, 28-day cycle). Radiotherapy was planned to a dose of 59.4 Gy in fractions of 1.8 Gy.

### Molecular Assessments

Molecular analysis for all tumor specimens was performed in one of three specialist neuropathological centres (Trillium Health Centre, Mississauga; St. Michael's Hospital, Toronto; and University Health Network, Toronto). Deletion of 1p and 19q were assessed by polymerase chain reaction at the time of tissue diagnosis (Deoxyribonucleic acid was extracted from the tumor tissue and amplified by polymerase chain reaction using primers specific for microsatellite markers located on chromosomes 1p and 19q to assess allelic loss using loss-of-heterozygosity analysis as described elsewhere)<sup>13-15</sup> or by fluorescence in situ hybridization with locus-specific probes for the regions 1p36.6 and 19q<sup>4</sup> from 2011 onwards. Incomplete deletion was defined as allelic loss on 1p and 19q, but not at all informative loci.

The presence of the most common *IDH-1* mutation (R132H mutation) was assessed by immunohistochemistry as described by Capper et al,<sup>16</sup> and 67 samples with available tissue that were not previously reported were analyzed retrospectively. 0(6)-methylguanine DNA methyltransferase (*MGMT*) promoter methylation status was not available for patients because it was not routinely performed during the period studied.

### Adverse Events

Adverse events were graded according to the National Cancer Institute Common Terminology Criteria for Adverse Events, version 4.03.<sup>17</sup>

### Statistical Methods

Summary statistics were provided for patient demographics, disease, and treatment factors. The estimates of OS and PFS were calculated using the Kaplan-Meier method. The OS was calculated from the date of tissue diagnosis (before beginning therapy) to the date of death from any cause; living patients were censored on the last follow-up date they were known to be alive. The PFS was calculated for all patients from the date of tissue diagnosis (before

beginning therapy) to the date of progression or date of death; patients alive without progression were censored on the date of last follow-up. The survival differences between groups were examined using the log-rank test. Univariable and multivariable analyses were performed using the Cox proportional hazard model. The multivariable model was built using stepwise selection. The selected multivariable model included only variables with  $p < 0.05$  on univariable analysis. Variables included in the univariable analysis were age, gender, Eastern Cooperative Oncology Group performance status (ECOG PS), extent of surgery, presence of previous low-grade glioma, tumor location (frontal lobe versus other), contrast enhancement, 1p19q status, and *IDH1* status. All tests were two-sided with  $\alpha = 0.05$ . Statistical analyses were performed using the SAS software 9.3 and R, version 3.0.0.

## RESULTS

### Patients and Treatment

A total of 106 consecutive patients were included who presented to Princess Margaret Cancer Centre, Toronto, from December 1997 to December 2013 for which 1p19q co-deletion status was available. The median follow-up time for all patients was 5.1 years (range, 0.1-16.3). As of December 2013, there were 64 (60%) PFS events and 94 patients (87%) were still alive.

A summary of patient characteristics for all gliomas is detailed in Table 1 (presence of previous low-grade glioma was defined radiologically in 18 patients and histologically in four patients), tumor characteristics and details of surgery in Table 2, and treatment history in Table 3. As expected, upfront treatment was given in the majority of patients with oligoastrocytoma (88%), anaplastic oligodendroglioma (92%), and anaplastic oligoastrocytoma (100%), but only in 31% of patients with oligodendroglioma.

*IDH1*-R132H immunoreactivity, indicating the presence of a mutation, was reported for 85 (80%) patients with sufficient material available.

The median time to treatment after pathological diagnosis in all patients was 66.5 days. The median time to radiotherapy in all patients to whom it was administered ( $N = 47$  [44%]) was 34.7 months (0.5-159.3). Thirty patients (64%) received radiotherapy at a dose of 59.4 Gy in 33 fractions and 17 (36%) received 54 Gy in 30 fractions. The median time to radiotherapy in months (range) for those patients with a diagnosis of oligodendroglioma and oligoastrocytoma who received radiotherapy was 43.2 months (1.0-96.0) and 43.4 months (1.0-86.6), respectively.

The median time to radiotherapy in nine (25%) patients with a diagnosis of anaplastic oligodendroglioma and anaplastic oligoastrocytoma who were 1p19q co-deleted or who had incomplete co-deletion and received temozolomide alone as up-front treatment was 41.2 months (16.3-93.2). In these nine patients, four had radiotherapy at first progression, three at second progression, and two at third progression. The median follow-up time for these 36 patients was 4.1 years (range, 0.4-16.3).

Different treatments were prescribed for patients at progression, and the choice depended on previous treatment received. Options included radiotherapy, surgery, PCV, temozolomide and retreatment with temozolomide if the intervening period was long ( $> 1$  year), lomustine, etoposide, and investigational therapies. Of the 64 patients (60%) who had progression in this study, 63 proceeded to treatment at first progression (temozolomide alone, 76%, surgery, 8%, concurrent radiotherapy with temozolomide followed by temozolomide alone, 6%, radiotherapy alone, 5%; other, 5%). Forty-five of 46 patients had treatment at second progression (temozolomide alone, 30%; concurrent radiotherapy with temozolomide followed by temozolomide alone, 20%; surgery, 13%; radiotherapy alone, 11%; lomustine, 11%; other, 15%), 25 of 30 at third progression (temozolomide alone, 29%; surgery, 17%; lomustine, 17%; etoposide, 17%; other, 20%), 17 of 20 at fourth progression, nine of 13 at fifth progression, and four of a possible seven at sixth progression. Those not treated with active treatment at time of progression received best supportive care.

### PFS

The Kaplan-Meier plot of PFS in all patients is represented by Figure 1A. Details on median and 2- and 5-year PFS are provided in Table 4 for all groups. There was no significant difference in PFS when stratified by histological group ( $p = 0.6$ ) nor when stratified by 1p19q co-deleted or incomplete 1p19q co-deletion ( $p = 0.59$ ) (thus, 1p19q codeletion/incomplete 1p19q deletion were grouped together for further analysis).

The median PFS for the *IDH1* immunopositive ( $N = 67$ ) and non-*IDH1* immunopositive patients ( $N = 18$ ) was 41.4 months (95% confidence interval [CI], 35.4-56.7 months) and 35.8 months (95% CI, 9.4-54.5 months), respectively. The presence of *IDH1* immunopositivity ( $N = 67$ ) versus no *IDH1* immunopositivity ( $N = 18$ ) was not prognostic for PFS (hazard ratio [HR], 0.71; 95% CI, 0.37-1.34;  $p = 0.28$ ) on univariable analysis.

On univariable analysis for all patients ( $N = 106$ ), only ECOG PS 1 versus 0 (HR, 2.42; 95% CI, 1.39-4.22;  $p = 0.001$ ) and 1p19q status

**Table 1: Summary of patient characteristics for all gliomas**

Patient variable	All patients (N = 106)	Oligodendroglioma (N = 42)	Oligoastrocytoma (N = 8)	Anaplastic oligodendroglioma (N = 47)	Anaplastic oligoastrocytoma (N = 9)
Age at diagnosis, years	40 (19-66)	42 (24-58)	41 (28-66)	40 (19-63)	40 (30-59)
Male	58 (55%)	21 (50%)	6 (75%)	26 (55%)	5 (56%)
ECOG PS					
0	80 (75%)	36 (86%)	6 (75%)	33 (70%)	5 (56%)
1	26 (25%)	6 (14%)	2 (25%)	14 (30%)	4 (44%)
Seizure at presentation	79 (75%)	32 (76%)	7 (88%)	35 (74%)	5 (56%)
Previous low-grade glioma	22 (21%)	8 (19%)	1 (12%)	11 (23%)	2 (22%)

**Table 2: Summary of tumor characteristics and surgery for all gliomas**

	All patients (N = 106) (%)	Oligodendroglioma (N = 42) (%)	Oligoastrocytoma (N = 8) (%)	Anaplastic oligodendroglioma (N = 47) (%)	Anaplastic oligoastrocytoma (N = 9) (%)
Location of tumor: Frontal lobe	62 (58)	25 (60)	5 (62)	29 (62)	3 (33)
Contrast enhancement	50 (47)	10 (24)	2 (25)	33 (70)	5 (56)
Extent of resection					
Biopsy	24 (23)	15 (36)	1 (12)	7 (15)	1 (11)
Partial	73 (69)	24 (57)	5 (62)	36 (77)	8 (89)
Subtotal	9 (8)	3 (7)	2 (25)	4 (9)	0
1p loss alone	4 (4)	0	1 (12)	3 (6)	0
19q loss alone	9 (8)	5 (12)	1 (12)	0	3 (33)
Co-deleted	66 (62)	29 (69)	2 (25)	32 (68)	3 (33)
Incomplete	27 (25)	8 (19)	4 (50)	12 (26)	3 (33)
<i>IDH1</i> immunopositivity					
<i>IDH1</i> immunopositive	67 (63)	26 (62)	1 (12)	36 (77)	4 (45)
No <i>IDH1</i> immunopositivity	18 (17)	4 (10)	3 (38)	8 (17)	3 (33)
Not available	21 (20)	12 (28)	4 (50)	3 (6)	2 (22)

as co-deleted/incomplete deletion versus 1p or 19q loss alone (HR, 0.45; 95% CI, 0.23-0.90;  $p=0.02$ ) were prognostic for PFS. The presence of previous low-grade glioma was not prognostic for PFS on univariable analysis (HR, 1.38; 95% CI, 0.77-2.47;  $p=0.28$ ). On multivariable analysis for all patients, receipt of therapy (radiotherapy alone or in combination with temozolomide followed by temozolomide therapy or temozolomide alone) versus none, upfront, resulted in a 45% reduction in risk of progression (HR, 0.55; 95% CI, 0.32-0.97;  $p=0.04$ ), ECOG PS 1 versus 0 (HR, 2.78; 95% CI, 1.57-4.93;  $p<0.001$ ) and 1p19q status as co-deleted/incomplete deletion versus 1p or 19q loss alone (HR, 0.36; 95% CI, 0.18-0.74;  $p=0.005$ ) were prognostic for PFS.

On multivariable analysis for patients with a diagnosis of oligodendroglioma and anaplastic oligodendroglioma alone ( $N=89$ ), only ECOG PS 1 versus 0 (HR, 2.63; 95% CI, 1.40-4.93;  $p=0.003$ ) and 1p19q status as co-deleted/incomplete deletion versus 1p or 19q loss alone (HR, 0.43; 95% CI, 0.19-0.99;  $p=0.047$ ) were prognostic for PFS.

## OS

The Kaplan-Meier plot of OS in all patients is represented by Figure 1B. Details on 5-year OS for all groups are provided in

Table 4. Median OS was not reached for all groups. The 5-year OS for the oligodendroglioma (90.3% [72.6-96.8]) and anaplastic oligodendroglioma (88.7% [72.2-95.7]) groups were similar, as were the values for the oligoastrocytoma (100% [100]) and anaplastic oligoastrocytoma (100% [100]) groups. Regression-type analysis such as univariable or multivariable analysis on OS was not run because of a low number of events ( $N=12$ ).

## Safety

The most common adverse events reported for patients receiving temozolomide alone as upfront treatment ( $N=52$  [49%]) were thrombocytopenia, fatigue, nausea, and neutropenia, and these were more often grade 1 and 2 events. Two percent of patients had grade 3 thrombocytopenia, fatigue, and neutropenia. There were no reports of grade 3 or 4 cognitive impairment.

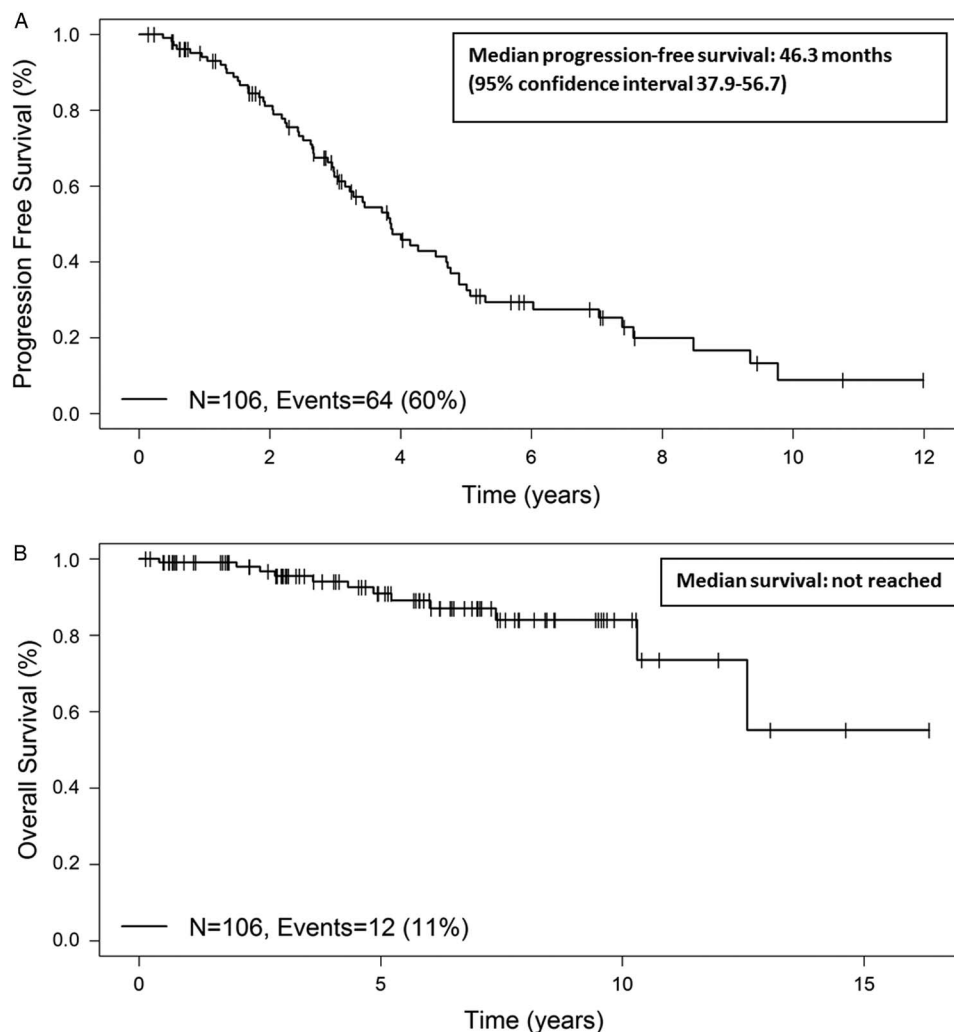
## DISCUSSION

This study retrospectively reviewed outcomes in patients, treated at a large academic centre, with a diagnosis of 1p19q co-deleted/partially deleted oligodendroglioma, oligoastrocytoma, anaplastic oligodendroglioma, or anaplastic oligoastrocytoma. For those

**Table 3: Summary of treatment history for all patients**

	All patients (N = 106)*	Oligodendroglioma (N = 42)	Oligoastrocytoma (N = 8)	Anaplastic oligodendroglioma (N = 47)*	Anaplastic oligoastrocytoma (N = 9)
Upfront temozolomide alone	52 (49%)	9 (21%)	5 (62%)	33 (70%)	5 (56%)
Median number of cycles (range)	12 (1-24)	12 (8-12)	12 (11-18)	12 (5-24)	12 (1-12)
Upfront radiotherapy alone	10 (9)	4 (10)	1 (12)	4 (9)	1 (11)
Upfront radiotherapy concurrent with and adjuvant temozolomide	10 (9)	0 (0)	1 (12)	6 (13)	3 (33)
Upfront observation	34 (32)	29 (69)	1 (12)	4 (9)	(0)

\*Because of rounding, percentages may not equal 100%.



**Figure 1:** (A) Kaplan-Meier plot of progression-free survival in all patients. (B) Kaplan-Meier plot of overall survival in all patients.

36 patients (one death) with a diagnosis of anaplastic oligodendroglioma or anaplastic oligoastrocytoma who had 1p19q co-deleted or incomplete deletion status and who received

temozolomide alone as upfront treatment, the median PFS was 46.3 months and the 5-year OS was 96%. Only 25% of these 36 patients received radiotherapy within a median follow-up of

**Table 4: Median, 2-year, and 5-year PFS and 5-year OS for all groups**

Group	N	Median PFS months (95% CI)	2-year PFS (%) (95% CI)	5-year PFS (%) (95% CI)	5-year OS (%) (95% CI)
All	106	46.3 (37.9-56.7)	81.1 (71.6-87.6)	34.0 (23.5-44.7)	90.9 (81.6-95.6)
Oligodendroglioma	42	46.1 (32.1-58.8)	79.1 (62.5-89)	32.0 (16.7-48.4)	90.3 (72.6-96.8)
Oligoastrocytoma	8	44.7 (26.2-58.8)	100 (100-100)	12.5 (0.7-42.3)	100 (100-100)
AOD	47	45.7 (30.1-63.6)	78.4 (62.5-88.2)	38.4 (22.0-54.5)	88.7 (72.2-95.7)
AOA	9	Not reached	87.5 (38.7-98.1)	65.6 (15.7-90.9)	100 (100-100)
AOD/AOA co-deleted/incomplete (receiving up-front temozolomide alone)	36	46.3 (38.7-90.8)	86.0 (66.8-94.5)	43.0 (21.7-62.6)	96.0 (74.8-99.4)
AOD/AOA co-deleted/incomplete (receiving up-front temozolomide alone)*					
IDHI immunopositive	31	46.3 (38.7-102)	83.7 (62.1-93.6)	48.1 (23.5-69.0)	95.2 (70.7-99.3)
No IDHI immunopositivity	3	Not reached	100 (100-100)	50.0 (0.6-91.0)	100 (100-100)

AOA = anaplastic oligoastrocytoma; AOD = anaplastic oligodendroglioma.

\*IDHI status not available for two of the 36 patients.

4.1 years; thus, this group may reflect a better prognosis set and indicate selection bias associated with a retrospective study. Although inter-study comparisons cannot be made reliably, the median PFS reported for 43 patients (18 deaths) with 1p19q co-deleted status who received radiotherapy and PCV in the EORTC 26951 study<sup>4</sup> was 156.8 months and the 5-year OS was 76.2%.

Although 5-year OS appears more encouraging in this study, it should be cautioned that there were only 12 deaths at the time of analysis and the median follow-up time for all patients in this study was just over 5 years as compared with more than 11 years in EORTC 26951.<sup>4</sup> Thus, mature follow-up of these patients is indicated and thus significant conclusions cannot be drawn. Additionally, an argument can be made that longer PFS and consequent greater time off treatment is more desirable for patients. However, it is important that neurological function and cognition are maintained in a patient group who may live for up to 15 years,<sup>5</sup> and in our study there was no grade 3 or 4 cognitive impairment noted in patients treated with temozolomide alone as upfront therapy after a median of just over 5 years of follow-up.

Long-term data from NOA-04<sup>18</sup> did not support a differential efficacy of primary temozolomide monotherapy or PCV polychemotherapy versus radiotherapy in any of the histological or molecular subgroups of anaplastic glioma, and thus less toxic upfront chemotherapy alone, sparing potential neurological sequelae may be more desirable.

Neurological (cognitive or mood change and peripheral or autonomic neuropathy) adverse effects were among the most frequent severe toxicities after a median of 3 years of follow-up in RTOG 9402,<sup>19</sup> but this may be somewhat attributable to better prospective documentation. It should also be mentioned that radiotherapy technology and application in the present era as opposed to when RTOG 9402,<sup>19</sup> for example, was recruiting patients (1994-2002) will most certainly have improved.

With similar PFS and OS patterns in low-grade and anaplastic gliomas in the current study, molecular characteristics may be more important than histological grade in survival. Indeed, the inclusion of molecular features in a revised WHO classification of brain tumors is under discussion. A recent study has analyzed markers of potential special prognostic interest including *alpha thalassaemia/mental retardation syndrome x-linked (ATRX)*, *IDH* and 1p19q co-deletion in a subset of 100 diffuse gliomas from the NOA-04 trial.<sup>20</sup> Based on these “integrated” diagnoses, loss of *ATRX* expression was close to being mutually exclusive with 1p19q co-deletion, and all but four of 141 patients with loss of *ATRX* expression and diffuse glioma carried either *IDH1* or *IDH2* mutations.<sup>21</sup> These “integrated” diagnoses were reported to have a better association with patient outcome than WHO 2007<sup>21</sup> and support the combined analysis of grade II and III glioma outcomes as performed in our study. This is also supported by a recent publication from The Cancer Genome Atlas Research Network in which it was reported that prognostically significant subtypes of lower grade glioma were captured more accurately by *IDH*, 1p19q, and TP53 status than by histological class.<sup>22</sup>

Limitations of this study are its retrospective nature with potential for inherent biases in patient treatment decisions in a single institution, nonavailability of some data, the inclusion of patients treated over a 16-year period with the corresponding WHO classification reflecting the era of therapy,<sup>10-12</sup> nonassessment of *MGMT* promoter methylation status, and utilization of *IDH-1*

immunohistochemistry, which identifies only approximately 90% of *IDH1* mutations and none of the *IDH2* mutations. In the current study, *IDH1* positivity was not prognostic for PFS and is possibly attributable to the limited sample size.

However, this study reports on outcomes of a relatively large number of patients with 1p19q co-deleted grade II and III gliomas receiving temozolomide alone in days 1 to 5, more routinely used a 28-day schedule as upfront treatment, extending to a recent era, and is a reflection of how the known chemosensitivity of gliomas is influencing how patients are managed at an academic centre, which is a tertiary referral centre, and how the survival results are favorable despite less than optimal follow-up.

In addition, it has been previously reported that *IDH1* mutations and 1p19q co-deletion but not *MGMT* promoter methylation were independent prognostic factors in EORTC study 26951. In 159 cases in that study available for *IDH* analysis, only one *IDH2* mutation was identified.<sup>23</sup>

There are two ongoing randomized trials designed to address the uncertainties in the management of anaplastic oligodendroglioma tumors. In a phase III EORTC/North American intergroup trial (CATNON), patients with non-co-deleted anaplastic gliomas are randomly assigned to one of four treatment arms: radiotherapy, radiotherapy with concurrent temozolomide, radiotherapy followed by temozolomide, and radiotherapy with concurrent and adjuvant temozolomide.<sup>24</sup> In addition, preliminary analysis of the CODEL trial has been presented,<sup>25,26</sup> which is a phase III trial of newly diagnosed anaplastic glioma patients with 1p/19q co-deletions comparing the survival of patients in three different groups: one receiving only radiotherapy (N = 12), another receiving radiotherapy and temozolomide (N = 12), and a third receiving temozolomide alone (N = 12). Patients in the study who received temozolomide only fared worse than the patients in the other two groups, leading an independent medical committee to recommend closing that arm of the study after a median follow-up of 3.4 years. Moving forward, 488 newly diagnosed patients with grade III anaplastic glioma with a 1p/19q co-deletion will be randomized into one arm receiving radiotherapy and the chemotherapy regimen PCV versus another arm of radiotherapy and temozolomide. The adjusted study is expected to be completed by December 2018. Although this trial has faced many obstacles as a consequence of the controversies surrounding the initial management of 1p19q co-deleted tumors, it is hoped that successful completion of this study will furnish definitive guidance on how best to manage these remarkably treatment-sensitive primary brain tumors.

#### ACKNOWLEDGEMENTS AND FUNDING

This research was presented in part at the European Society of Medical Oncology conference, Madrid, September 26-30, 2014, and at the Society for Neuro-Oncology conference, Miami, November 13-16, 2014.

#### DISCLOSURES

The authors do not have anything to disclose.

#### STATEMENT OF AUTHORSHIP

MGMN undertook conception and design, acquisition of data, interpretation of data, and drafting, revising, and final approval of manuscript. HJ undertook statistical analysis and interpretation of data, and drafting, revising and final approval of manuscript. MJL-F

undertook acquisition of data, interpretation of data, and drafting, revising, and final approval of manuscript. SS undertook conception and design, acquisition of data, interpretation of data, and drafting, revising and final approval of manuscript. T-RK undertook molecular analysis, acquisition of data, interpretation of data, and drafting, revising, and final approval of manuscript. JK undertook molecular analysis, acquisition of data, interpretation of data, and drafting, revising, and final approval of manuscript. C Coire undertook molecular analysis, acquisition of data, interpretation of data, and drafting, revising, and final approval of manuscript. C Chung undertook interpretation of data, and drafting, revising, and final approval of manuscript. B-AM undertook interpretation of data, drafting, revising and final approval of manuscript. NL undertook interpretation of data, and drafting, revising, and final approval of manuscript. WPM undertook conception and design, acquisition of data, interpretation of data, and drafting, revising, and final approval of manuscript.

## REFERENCES

- Jenkins RB, Blair H, Ballman KV, et al. A t(1;19)(q10;p10) mediates the combined deletions of 1p and 19q and predicts a better prognosis of patients with oligodendroglioma. *Cancer Res.* 2006;66:9852-61.
- Reifenberger J, Reifenberger G, Liu L, James CD, Wechsler W, Collins VP. Molecular genetic analysis of oligodendroglial tumors shows preferential allelic deletions on 19q and 1p. *Am J Pathol.* 1994;145:1175-90.
- Smith JS, Alderete B, Minn Y, et al. Localization of common deletion regions on 1p and 19q in human gliomas and their association with histological subtype. *Oncogene.* 1999;18:4144-52.
- Van den Bent MJ, Brandes A, Taphoorn MJ, et al. Adjuvant procarbazine, lomustine, and vincristine chemotherapy in newly diagnosed anaplastic oligodendroglioma: long-term follow-up of EORTC brain tumor group study 26951. *J Clin Oncol.* 2013;31:344-50.
- Cairncross G, Wang M, Shaw E, et al. Phase III trial of chemoradiotherapy for anaplastic oligodendroglioma: long-term results of RTOG 9402. *J Clin Oncol.* 2013;31:337-43.
- Alentorn A, Sanson M, Idubai A. Oligodendrogliomas: new insights from the genetics and perspectives. *Curr Opin Oncol.* 2012;24:687-93.
- Cairncross JG, MacDonald DR. Successful chemotherapy for recurrent malignant oligodendroglioma. *Ann Neurol.* 1988;23:360-4.
- Kim L, Hochberg FH, Thornton AF, et al. Procarbazine, lomustine, and vincristine (PCV) chemotherapy for grade III and grade IV oligoastrocytomas. *J Neurosurg.* 1992;85:602-7.
- Buckner JC, Pugh SL, Shaw EG, et al. Phase III study of radiation therapy (RT) with or without procarbazine, CCNU, vincristine (PCV) in low-grade glioma: RTOG 9802 with Alliance, ECOG, and SWOG. *J Clin Oncol.* 2014;32(Suppl 5s:abstr 2000).
- Kleihues P, Burger PC, Scheithauer BW. The new WHO classification of brain tumours. *Brain Pathol.* 1993;3:255-68.
- Kleihues P, Louis DN, Scheithauer BW, et al. The WHO classification of tumors of the nervous system. *J Neuropathol Exp Neurol.* 2002;61:215-25.
- Louis DN, Ohgaki H, Wiestler OD, et al. The 2007 WHO classification of tumours of the central nervous system. *Acta Neuropathol.* 2007;114:97-109.
- Cairncross JG, Ueki K, Zlatescu MC, et al. Specific genetic predictors of chemotherapeutic response and survival in patients with anaplastic oligodendrogliomas. *J Natl Cancer Inst.* 1998;90:1473-9.
- Johnson MD, Vnencak-Jones CL, Toms SA, Moots PM, Weil R. Allelic losses in oligodendroglial and oligodendroglioma-like neoplasms: analysis using microsatellite repeats and polymerase chain reaction. *Arch Pathol Lab Med.* 2003;127:1573-9.
- Felsberg J, Erkwow A, Sabel MC, et al. Oligodendroglial tumors: refinement of candidate regions on chromosome arm 1p and correlation of 1p/19q status with survival. *Brain Pathol.* 2004;14:121-30.
- Capper D, Zentgraf H, Balsl J, Hartmann C, von Deimling A. (2009) Monoclonal antibody specific for IDH1 R132H mutation. *Acta Neuropathol.* 2009;118:599-601.
- Common Terminology Criteria for Adverse Events, version 4.03 (CTCAE). National Cancer Institute Division of Cancer Treatment and Diagnosis. 2010. Available at: [http://evs.nci.nih.gov/ftpl/CTCAE/CTCAE\\_4.03\\_2010-06-14\\_QuickReference\\_8.5x11.pdf](http://evs.nci.nih.gov/ftpl/CTCAE/CTCAE_4.03_2010-06-14_QuickReference_8.5x11.pdf).
- Wick W, Roth P, Wiestler B, et al. Long-term analysis of the NOA-04 randomized phase III trial of sequential radiochemotherapy of anaplastic glioma with PCV or temozolomide. *J Clin Oncol.* 2015;33(Suppl abstr 2001).
- Cairncross G, Berkey B, Shaw E, et al. Phase III trial of chemotherapy plus radiotherapy compared with radiotherapy alone for pure and mixed anaplastic oligodendroglioma: Intergroup Radiation Therapy Oncology Group Trial 9402. *J Clin Oncol.* 2006;24:2707-14.
- Wick W, Hartmann C, Engel C, et al. NOA-04 randomized phase III trial of sequential radiochemotherapy of anaplastic glioma with procarbazine, lomustine, and vincristine or temozolomide. *J Clin Oncol.* 2009;27:5874-80.
- Reuss DE, Sahm F, Schrimpf D, et al. ATRX and IDH1-R132H immunohistochemistry with subsequent copy number analysis and IDH sequencing as a basis for an "integrated" diagnostic approach for adult astrocytoma, oligodendroglioma and glioblastoma. *Acta Neuropathol.* 2015;29:133-46.
- The Cancer Genome Atlas Research Network. Comprehensive, integrative genomic analysis of diffuse lower-grade gliomas. *N Engl J Med.* 2015;372:2481-98.
- van den Bent MJ, Dubbink HJ, Marie Y, et al. IDH1 and IDH2 mutations are prognostic but not predictive for outcome in anaplastic oligodendroglial tumors: a report of the European Organization for Research and Treatment of Cancer Brain Tumor Group. *Clin Cancer Res.* 2010;16:1597-604.
- Phase III Trial of Anaplastic Glioma Without 1p/19q LOH (CATNON). 2016 Available at: <http://clinicaltrials.gov/ct2/show/NCT00626990>.
- Radiation Therapy With Concomitant and Adjuvant Temozolomide Versus Radiation Therapy With Adjuvant PCV Chemotherapy in Patients With Anaplastic Glioma or Low Grade Glioma. 2016. Available at: <http://clinicaltrials.gov/ct2/show/NCT00887146>.
- Jaeckle K, Vogelbaum M, Ballman K, et al. CODEL (Alliance-N0577; EORTC-26081/2208; NRG-1071; NCIC-CEC-2): phase III randomized study of RT vs. RT+TMZ vs. TMZ for newly diagnosed 1p/19q-codeleted anaplastic glioma. Analysis of patients treated on the original protocol design. *Neurology.* 2016: (suppl: abstract PL02.005).