

# A sticky situation: management of spray polyurethane foam insulation in body orifices

Robert J. Sowerby, BSc, MD<sup>\*</sup>; Leigh J. Sowerby, BSc, MD<sup>†</sup>; Chris Vinden, MD<sup>‡</sup>

## ABSTRACT

Spray polyurethane foam insulation is commonly used in the construction industry to fill gaps, seal, and insulate. We present three cases of intentional spray foam insertion in body orifices and discuss the management of such situations in the emergency department. This series includes a case of oral foam insertion used in a suicide attempt by suffocation and two cases of rectal insertion. All of these cases had potential long-term consequences; one was life-threatening. To our knowledge, this is the first published report on the medical management and removal of foam insulation from body orifices. In all three cases, the foam insulation material was successfully removed after allowing the material to harden.

## RÉSUMÉ

L'isolant en mousse de polyuréthane pulvérisée est couramment utilisé dans l'industrie de la construction pour combler les espaces, les calfeutrer et les isoler. Nous présentons trois cas d'insertion intentionnelle de mousse en vaporisateur dans des cavités corporelles, et discutons de la prise en charge de ces situations aux urgences. Cette série comprend un cas d'insertion de mousse par voie orale utilisée dans une tentative de suicide par suffocation, et deux cas d'insertion par voie rectale. Tous ces cas avaient des effets potentiels à long terme, et un cas menaçait la vie du patient. À notre connaissance, ce rapport est le premier publié sur la prise en charge et le retrait de la mousse des cavités corporelles. Dans tous les cas, l'isolant en mousse a pu être retiré après l'avoir laissé durcir.

**Keywords:** foam insulation, foreign body, isocyanates, polyurethane insulation, spray foam

Spray polyurethane foam insulation is commonly used in the construction industry to fill gaps, seal, and insulate. Foam insulation is inexpensive, is readily available at most hardware stores, and has a long shelf life. It also has qualities that may encourage uses other than originally intended. In the following article, we present three cases of intentional spray foam insertion in body orifices and discuss the management of such presentations in the emergency department (ED).

## CASE REPORTS

### Case 1

A middle-aged man presented to the ED 45 minutes after spraying polyurethane foam insulation into his oral cavity and both nares with the intention of suicide by asphyxiation. On arrival, his vital signs were stable, and no respiratory distress was observed. The patient had tacky insulation spattered on his face, hard palate, and teeth. The oral airway was patent, with only traces of foam in the oral cavity and oropharynx. The nasal airway was completely obstructed, and both nostrils were distended with foam. The patient complained of significant discomfort secondary to foam expansion in his nasal cavity. The remainder of the physical examination was unremarkable.

The otolaryngology service was consulted regarding removal of the foam from the oral and nasal cavities. Initial attempts at removing the foam while it was still moist were unsuccessful. However, when removal was

Division of Urology, Department of Surgery, University of Toronto, Toronto, ON; Department of <sup>†</sup>Otolaryngology and <sup>‡</sup>Division of General Surgery, Department of Surgery, University of Western Ontario, London, ON.

**Correspondence to:** Dr. Chris Vinden, Department of Surgery, London Health Sciences Centre-Victoria Hospital, 800 Commissioners Road East, London, ON N6A 5W9; cvinden@sympatico.ca.

Submitted May 17, 2010; Revised September 20, 2010; Accepted October 23, 2010.

This article has been peer reviewed.

© Canadian Association of Emergency Physicians

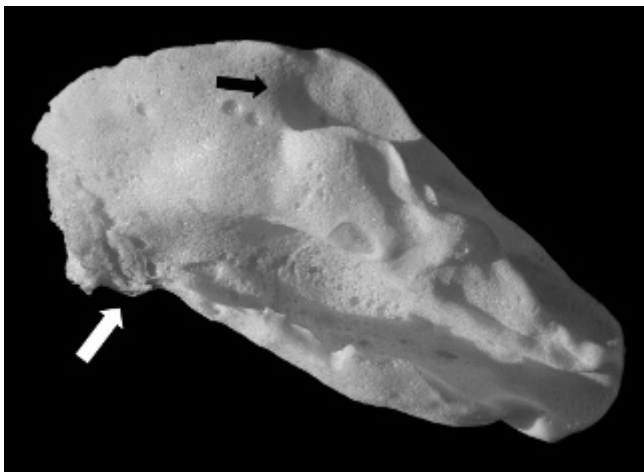
CJEM 2011;13(6):404-408

DOI 10.2310/8000.2011.110291

reattempted approximately 6 hours after insertion, the foam had hardened, and removal was easy. Foam from the oral cavity was removed without difficulty using forceps. The foam was also easily removed en bloc from both nares without lubrication using bayonet forceps after trimming the nasal vibrissae (Figure 1). Flexible fiberoptic nasopharyngoscopy was performed and revealed no supraglottic, glottic, or hypopharyngeal edema, erythema, or foreign material. The nasal mucosa was mildly erythematous, but no residual material was present in the nasal cavity. A chest radiograph was normal. Follow-up assessment 48 hours later revealed resolution of the nasal inflammation. There was no permanent disability, and the patient was referred to the psychiatry service.

### Case 2

A 30-year-old woman presented to the ED 2 hours after spraying foam insulation into her rectum in an attempt to make a homemade sexual toy. On admission, she reported initial abdominal pain and nausea that had subsequently resolved. She had bleeding per rectum, was passing flatus, and had passed some foam prior to coming to hospital. On examination, she had stable vital signs, and her abdomen was soft and diffusely tender, with no distention. A foreign body was palpable on digital rectal examination. Laboratory investigations were unremarkable other than a slightly elevated leukocyte count. An abdominal x-ray series revealed distended bowel loops with no air-fluid levels or free air.

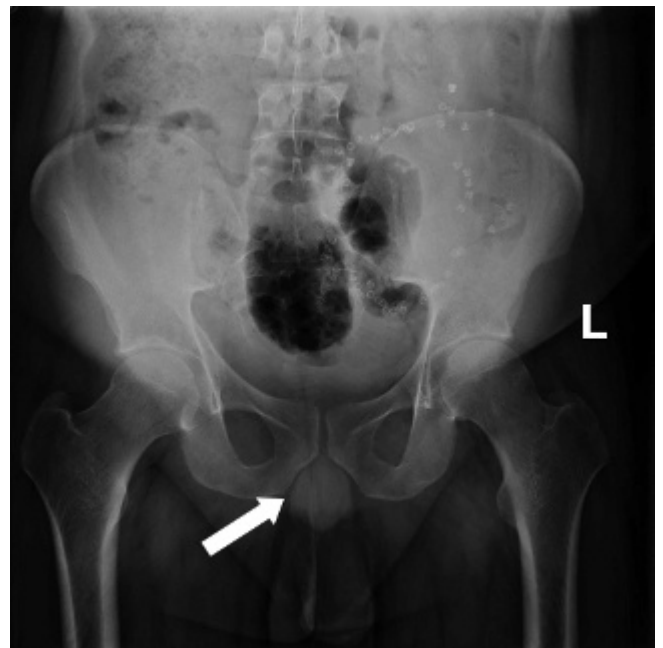


**Figure 1.** Spray foam insulation foreign body removed from the left nasal cavity (*white arrow* = depression from the inferior turbinate; *black arrow* = depression from the middle turbinate).

General Surgery was consulted, and the patient was administered a Fleet enema and one dose of mineral oil by mouth. After 10 hours, the insulation had still not passed, and the patient was taken to the operating room for foreign body removal under general anesthesia. The foam insulation was removed in three pieces using bimanual transvaginal pressure. Flexible sigmoidoscopy was performed and confirmed that there was no remaining foam or evidence of perforation.

### Case 3

A man in his late twenties presented to the ED after injecting a large amount of spray foam insulation into his rectum. He had a past history of several laparotomies for foreign body removal. The time from insertion to presentation was unknown but in the order of hours. On presentation, he complained of abdominal pain, and his vital signs were stable. A firm foreign body was palpable in the rectum. Abdominal radiographs showed a large foreign body extending into the sigmoid colon (Figure 2). Initial attempts in the ED to remove the insulation were unsuccessful and resulted in some minor mucosal trauma and bleeding.

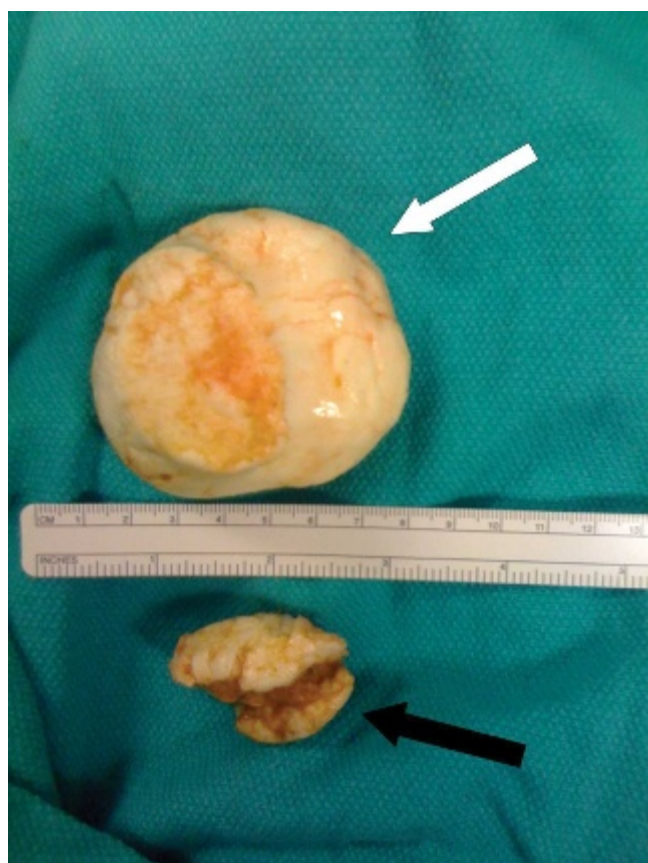

**Figure 2.** Abdominal radiograph demonstrating spray foam insulation foreign body (*white arrow*) extending into the sigmoid colon. Surgical clips are present from previous laparotomies for foreign body removal.

General Surgery was consulted and was able to remove part of the foam insulation with lubrication under procedural sedation and analgesia in the ED (Figure 3). The decision was made to attempt conservative management in the hope of avoiding a laparotomy. Over the next 10 hours, the patient was given a purgative bowel cleansing agent by mouth and numerous enemas. However, he remained unable to pass the foreign body and was taken to the operating room for removal under general anesthesia. The  $17.5 \times 6.0 \times 4.0$  cm foreign body was easily removed via proctoscopy without bleeding or rectal trauma, and no soft tissue was noted to be attached on pathologic examination. The patient recovered uneventfully and was referred to the psychiatry service.

## DISCUSSION

Spray foam insulation is a polyurethane compound primarily used in cavity sealing. It is composed of



**Figure 3.** Spray foam insulation foreign bodies removed from the rectum in the emergency department (*white arrow* = proximal foreign body [note the smooth appearance of the exterior once cured]; *black arrow* = distal foreign body from the region of the anal sphincter).

isocyanate derivatives pressurized in a carrier vapour. The foam cures and hardens within 2 to 12 hours and is known to cure faster in warm environments.<sup>1</sup> The primary concerns with spray foam insulation exposure are isocyanate toxicity and mechanical adherence to the skin.

To our knowledge, this is the first published report on the medical management of foam insulation in body cavities. Recently, a report of suspected pediatric ingestion of di-isocyanate glue was published.<sup>2</sup> This case was uncomplicated and was managed conservatively, without long-term sequelae. The ingestion was not confirmed, and the quantity ingested was suspected to be minimal.

ED management of spray foam insulation foreign bodies without consultation with specialty services should be confined to cases of minor exposure (eg, a small amount in the oral cavity adherent to the palate). Larger amounts of spray foam insulation should be managed by a surgical service, with a low threshold for removal in the operating room.

It is unlikely that prolonged dermal exposure to foam insulation results in absorption of toxic levels of isocyanates, and skin sensitization rarely occurs. When in contact with skin, foam insulation adheres to squamous epithelium. Uncured foam that has come in contact with the skin can be removed with acetone, polyglycol-based skin cleansers, or corn oil.<sup>1</sup> Cured foam can be removed mechanically or will wear off with squamous migration.

Isocyanate exposure to the respiratory epithelium can cause irritation, pulmonary edema, acute lung injury (ALI), and acute respiratory distress syndrome (ARDS).<sup>1,3</sup> In 1984, in Bhopal, India, a leak of isocyanates resulted in one of the world's worst industrial catastrophes, killing over 3,800 people instantly and causing over 20,000 premature deaths.<sup>4</sup> In this tragedy, methylisocyanate, a more potent respiratory irritant compared to other isocyanates, contributed to the majority of lung injury.<sup>3,4</sup> Products made with methylisocyanate should raise clinical suspicion; fortunately, none of the commercially available spray foam insulation products we researched were found to have this type of isocyanate in their formulation.

As a chemical group, isocyanates are the leading cause of occupational asthma. Previous sensitization has been reported to cause bronchospastic reactions even in low-volume exposures and can cause death.<sup>5-7</sup>

During application, the use of appropriate respiratory protection to limit exposure is recommended. Symptoms and signs indicative of respiratory injury may be delayed up to 48 hours, and patients should be closely monitored during this time.<sup>1</sup> Concern for respiratory sequelae should be increased in patients with previous respiratory disease. Patients with asthma should be treated accordingly with standard and supportive therapies. Patients suspected of having ALI or ARDS from irritant gas exposure should be treated in a similar fashion to patients with ALI or ARDS caused by other etiologies. Therapy should focus on maintaining oxygenation with supplementary oxygen, prone position, and ventilation with positive end-expiratory pressure, inverse ratios, and low tidal volumes. Reducing the inspired concentration of oxygen to < 50% as rapidly as possible is also important as such patients have an increased susceptibility to oxygen toxicity.<sup>3</sup> Maintaining airway patency with bronchodilators and suctioning and limiting secretions with corticosteroids are also important management steps. Chemical neutralization is beneficial with some acid-forming irritant gases and should be pursued if expert consultation so advises.<sup>3</sup>

The toxicity of foam insulation itself is low, and ingestion of small amounts is not considered to be harmful apart from irritative effects.<sup>1</sup> Significant exposure may cause organophosphate-like cholinesterase inhibition and a cholinergic toxidrome or acute cholinergic crisis manifesting with symptoms including headache, dizziness, ataxia, muscle twitching, tremors, nausea, abdominal cramping, diarrhea, diaphoresis, myosis, visual blurring, salivation, lacrimation, dyspnea, excessive urination, seizures, or central nervous system depression.<sup>1</sup> Potentially life-threatening symptoms in such situations include bronchorrhea, bronchospasm, and bradyarrhythmias.<sup>8</sup> Management of an acute cholinergic crisis should include decontamination by removal of the toxic agents and poison centre or other expert consultation to facilitate the treatment of pulmonary secretions with antimuscarinic agents such as atropine and the treatment of motor weakness with oximes such as pralidoxime.<sup>8,9</sup> Following resolution of an acute cholinergic crisis, monitoring for delayed respiratory failure, which could indicate an intermediate syndrome, is important.<sup>8</sup>

Myocardial irritability and arrhythmias can occur at excessive exposure levels, and in patients presenting with potential cardiac toxicity, sympathomimetic drugs

should be used with caution.<sup>1</sup> Cyanide poisoning does not occur with exposure to isocyanates, and empiric therapy with cyanide antidotes is not indicated.<sup>3</sup>

Although animal studies have shown that prolonged exposure to high concentrations of spray foam insulation components has caused lung cancer, spray foam insulation is not considered to be carcinogenic in humans with recommended exposure thresholds.<sup>1</sup> A study of a large cohort of people in an isocyanate-exposed employment environment failed to find an increased risk of lung cancer or nonmalignant respiratory diseases.<sup>10</sup>

During application of spray foam insulation, airborne concentrations of isocyanates can be elevated above the permissible exposure thresholds; however, airborne concentrations rapidly decline after application and are virtually undetectable after 45 minutes.<sup>11</sup> Medical staff with repeated isocyanate exposure have developed occupational asthma.<sup>12</sup> At high exposure levels, it may also be possible for medical staff to develop acute toxicity, as can occur in the ED management of organophosphate poisoning.<sup>13</sup> Medical staff in contact with uncured spray foam insulation should use personal protective equipment to minimize exposure, including gowns, gloves, masks, and eye protection.<sup>8</sup>

In the cases we report, we suspect that the foam did not adhere to the oral and nasal cavities because they are lined with columnar epithelium and the foam could not adhere to keratin. It is possible that the mucin produced by the mucous glands creates a barrier preventing contact between spray foam insulation and mucosal epithelium; however, there is no laboratory evidence to support this hypothesis. In the two cases of rectal foam insertion we report, the foam may have been bonded to the epithelium as some minor rectal bleeding was reported in both cases prior to presentation.

From our experience with these cases, we believe that isocyanate foam insulation in the nasal cavity, oral cavity, rectum, or sigmoid colon should be left to cure before any attempts at removal are made. Hardening of the foam and liberal lubrication allow the foreign material to be removed in its entirety. An additional potential concern with spray foam insulation in a closed body cavity is that the foam expands to approximately 130% of its application volume.<sup>1</sup> In this regard, any concerns with airway compromise or bowel perforation should obviously take precedence over attempting to remove the foam en bloc without mucosal damage.

Finally, spray foam insulation from different manufacturers may contain additional chemicals that could present challenges beyond those mentioned in this article. Most manufacturers of foam insulation, such as The Dow Chemical Company, have a 24-hour emergency telephone number where additional information can be obtained.

## **CONCLUSION**

The easy access and common use of spray foam insulation create a potential risk for accidents and misuse. In the cases we presented, mechanical débridement of the insulation was facilitated by allowing the foam to cure before removal was attempted. Management in the ED should include personal protection, monitoring for toxicity, vigilance for asthmatic reactions or ALI, and mechanical débridement with specialist consultation as required.

**Acknowledgement:** Figure 1 photograph by Anthony Branco.

**Competing interests:** None declared.

## **REFERENCES**

1. The Dow Chemical Company. *Material safety data sheet: GREAT STUFF (TM) PRO Window and Door Gum Foam Sealant 20 OZ HC*. Issue Date: Jan 31, 2008. Available at: [http://www.dow.com/PublishedLiterature/dh\\_00f4/0901b803800f4c8a.pdf?filepath=/PublishToInternet/InternetDOWCOM/msds/SDS\\_00073072\\_GSPWDGUN20OZHC\\_CANADA\\_ENGLISH&fromPage=MSDS](http://www.dow.com/PublishedLiterature/dh_00f4/0901b803800f4c8a.pdf?filepath=/PublishToInternet/InternetDOWCOM/msds/SDS_00073072_GSPWDGUN20OZHC_CANADA_ENGLISH&fromPage=MSDS) (accessed July 28, 2009).
2. Goertmoeller SI, Sweeney RM. Unique foreign body ingestions in the pediatric population. *J Emerg Nurs* 2010; 36:178-9, doi:[10.1016/j.jen.2009.11.010](https://doi.org/10.1016/j.jen.2009.11.010).
3. Flomenbaum NE, Goldfrank LR, Hoffman RS, et al, editors. *Goldfrank's toxicologic emergencies*. 8th ed. New York: McGraw-Hill; 2006.
4. Broughton E. The Bhopal disaster and its aftermath: a review. *Environ Health* 2005;4:6, doi:[10.1186/1476-069X-4-6](https://doi.org/10.1186/1476-069X-4-6).
5. Goe SK, Henneberger PK, Reilly MJ, et al. A descriptive study of work aggravated asthma. *Occup Environ Med* 2004; 61:512-7, doi:[10.1136/oem.2003.008177](https://doi.org/10.1136/oem.2003.008177).
6. Lee SM, Koh D. Lessons from an isocyanate tragedy. *Singapore Med J* 2008;49:372-5.
7. Carino M, Aliani M, Licitra C, et al. Death due to asthma at workplace in a diphenylmethane diisocyanate-sensitized subject. *Respiration* 1997;64:111-3, doi:[10.1159/000196653](https://doi.org/10.1159/000196653).
8. Rusyniak DE, Nanagas KA. Organophosphate poisoning. *Semin Neurol* 2004;24:197-204, doi:[10.1055/s-2004-830907](https://doi.org/10.1055/s-2004-830907).
9. Aygun D. Diagnosis in an acute organophosphate poisoning: report of three interesting cases and review of the literature. *Eur J Emerg Med* 2004;11:55-8, doi:[10.1097/00063110-200402000-00012](https://doi.org/10.1097/00063110-200402000-00012).
10. Sorahan T, Nichols L. Mortality and cancer morbidity of production workers in the UK flexible polyurethane foam industry: updated findings, 1958-98. *Occup Environ Med* 2002;59:751-8, doi:[10.1136/oem.59.11.751](https://doi.org/10.1136/oem.59.11.751).
11. Lesage J, Stanley J, Karoly WJ, et al. Airborne methylene diphenyl diisocyanate (MDI) concentrations associated with the application of polyurethane spray foam in residential construction. *J Occup Environ Hyg* 2007;4:145-55, doi:[10.1080/15459620601133779](https://doi.org/10.1080/15459620601133779).
12. Donnelly R, Buick JB, Macmahon J. Occupational asthma after exposure to plaster casts containing methylene diphenyl diisocyanate. *Occup Med* 2003;53:432-4.
13. Geller RJ, Singleton KL, Tarantino ML, et al. Poisoning associated with emergency department treatment of organophosphate toxicity-Georgia, 2000. *JAMA* 2001;285:527-8, doi:[10.1001/jama.285.5.527](https://doi.org/10.1001/jama.285.5.527).