

## Radiology in Focus

### Fungal rhinosinuitis

V. J. LUND, M.S., F.R.C.S., F.R.C.S.ED., G. LLOYD, D.M., F.R.C.R., F.R.C.OPHTH.,  
L. SAVY, B.Sc., M.B., B.S., F.R.C.R., D. HOWARD, F.R.C.S., F.R.C.S.(ED).

#### Abstract

Fungal infections in both their invasive and non-invasive forms can prove difficult to diagnose. The often characteristic appearances on imaging are of great assistance. CT is the primary imaging modality and is probably more accurate than MRI in diagnostic specificity and determining the extent of bone erosion. However this may require a modified scanning technique to adequately demonstrate the typical soft tissue density variations of fungi. MRI should be used to supplement CT when intra-cranial or intra-orbital extension is suspected.

**Key words:** Diagnostic; Rhinitis; Sinusitis; Fungal infection; Imaging

#### Introduction

Fungal infections of the nose and sinuses appear to be increasingly common, though this may relate partly to a lower threshold of clinical suspicion, the use of nasal endoscopy and improved imaging. As it can be extremely difficult to confirm the presence of fungus, both histologically and by culture, the radiological features may be of paramount importance in initiating a careful search for fungal elements.

The classification of fungal rhinosinuitis (Table I) into invasive and non-invasive relies primarily upon the presence or absence of fungal hyphae within the mucosa, and not to the presence of bone erosion, which can be found in non-invasive forms.

#### Material and methods

From a cohort of 45 patients with fungal rhinosinuitis, imaging was available for a retrospective analysis in 34 cases. This review is based upon the results of this analysis, together with a review of the relevant literature.

TABLE I  
FUNGAL RHINOSINUITIS – CLASSIFICATION

Non-invasive (n)	Invasive (n)	
Fungal ball (mycetoma)	10	Acute fulminant 2
Allergic fungal infection	18	Chronic 3
		immunocompetent
		immunocompromised
		Sclerosing 1
		Granulomatous <sup>a</sup>

<sup>a</sup>De Shazo *et al.* 1997.<sup>9</sup>

#### Plain X-rays

Although plain X-rays may show opacification, their lack of sensitivity and specificity in the demonstration of both the pathology and the anatomy renders them of little practical use in the diagnosis of this condition.

#### CT

CT should be performed in direct coronal and axial planes and photographed at both bony and soft tissue windows, which necessitates the use of a soft tissue algorithm for

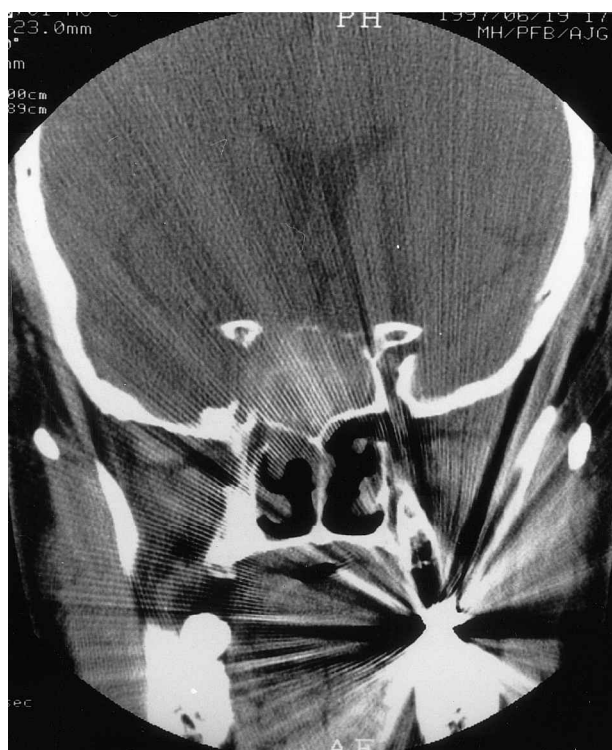
TABLE II  
IMAGING PROTOCOL

CT – direct coronal and axial  
bone protocol – window widths ~ 2000 HU\*  
centred – 250/–200  
soft tissue protocol – window widths 300–350 HU\*  
centred + 30

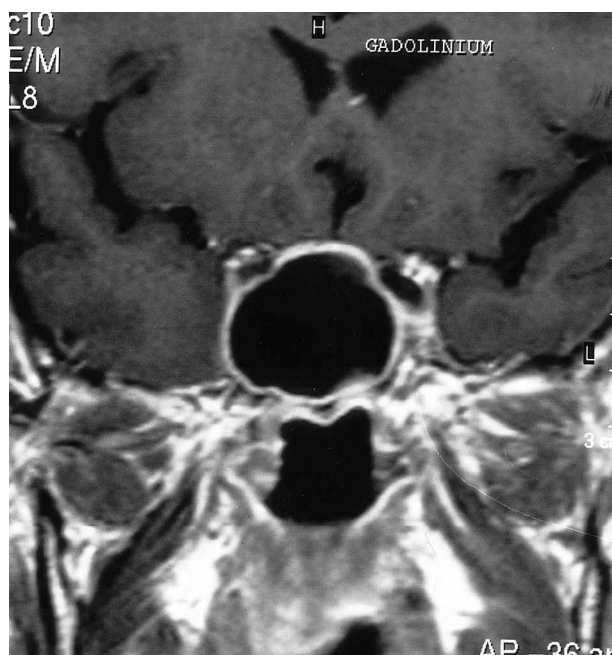
add contrast enhancement or proceed to MRI when intracranial or intraorbital extension suspected

MRI – 3 planar (axial, coronal, sagittal)  
T<sub>1</sub> –/+ gadolinium sequences  
T<sub>2</sub> sequences

\*depending on scanner.



(a)



(b)

FIG. 1

(a) Coronal CT and (b) MRI (T<sub>1</sub>-weighted sequence) showing fungal ball filling the sphenoid sinus.

image acquisition, rather than the bony algorithm used for routine sinus imaging (Table II). This will optimally show the extent of the disease, together with the characteristic high density which is frequently caused by the fungal material in the central part of the sinus. Dystrophic calcification has been reported within the fungal mass, but other relatively high atomic number elements, such as manganese, calcium and iron, are also known to be present,<sup>1,2</sup> which may all contribute to the typical high density.

**Fungal ball** With a fungal ball a single sinus is affected, either the maxillary sinus or occasionally the concha bullosa, isolated ethmoidal cell or sphenoid sinuses (Figures 1a, 2). Of our 10 cases, six occurred in the maxilla, two in the posterior ethmoids and two in the sphenoid. Sinus opacification may be partial (7/10) or complete (3/10). In the latter situation there may be associated expansion of the sinus, and although there may be thinning of the adjacent bone there may also be sclerosis, possibly owing to the secondary bacterial infection that can occur.<sup>3</sup> High density within the sinus was present in eight of the 10 cases.

**Allergic** In allergic fungal sinusitis the opacification may be unilateral (2/18) or bilateral (16/18), though sometimes with a predominant side. In the majority of cases (83 per cent) there is mixed density, produced by the polypoid material combined with the fungal secretion (Figure 3a). There is often expansion of the sinuses, which can be considerable, encroaching upon the orbits or intracranial cavity<sup>4</sup> (Figures 3a, 4). Anterior bowing of the maxillary wall (Figure 5a) and deviation of the septum is also seen when the disease primarily affects one side. Bone erosion was present in 72 per cent of our cases and has been estimated to be present in up to 80 per cent of cases.<sup>5</sup> No one sinus is more frequently affected than the other but, using a sinus staging system,<sup>6</sup> the score ranged from 4 to 24, with a mean of 17.5.

**Chronic invasive** The distinction between non-invasive allergic fungal sinusitis and chronic invasive infection can be very difficult to make radiologically, as similar imaging features may be seen in both. However, as the invasive process proceeds there is usually greater extension into surrounding structures, such as the orbit or anterior and middle cranial fossae, and in particular the cavernous sinus (Figure 6). In addition there may be adjacent dural inflammation. Thus the mixed high-density signal and bone erosion are a feature of both conditions, but were present in our three cases of chronic invasive infection. Sinus scores ranged from 17 to 24, with a mean of 21.

**Acute fulminant invasive** In acute fulminant fungal infections the process is extremely rapid and associated with massive tissue necrosis and skull base erosion

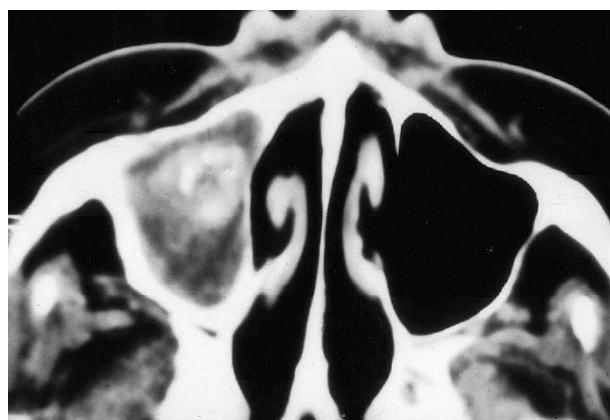
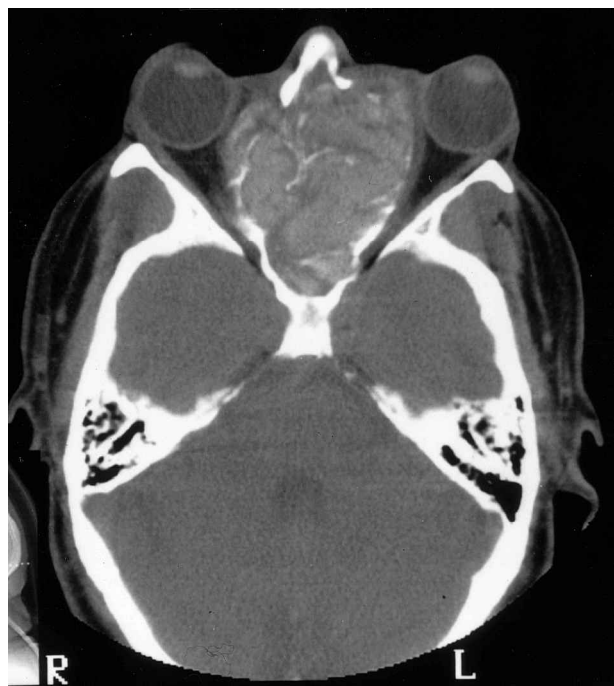
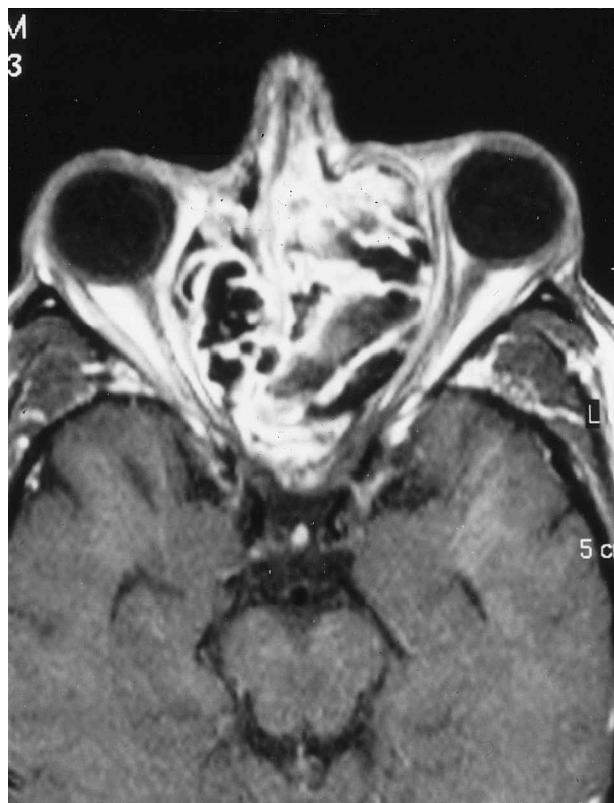

FIG. 2

Axial CT scan showing typical appearances of fungal ball in maxillary sinus.



(a)



(b)

FIG. 3

(a) Axial CT and (b) axial MRI ( $T_1$ -weighted sequence with gadolinium DPTA) showing fungal material expanding the ethmoidal sinuses bilaterally in allergic fungal disease.

(Figure 7). But for the time course, the appearances are more in keeping with a malignant neoplasm, and the usual mixed high density of fungal material is not present.

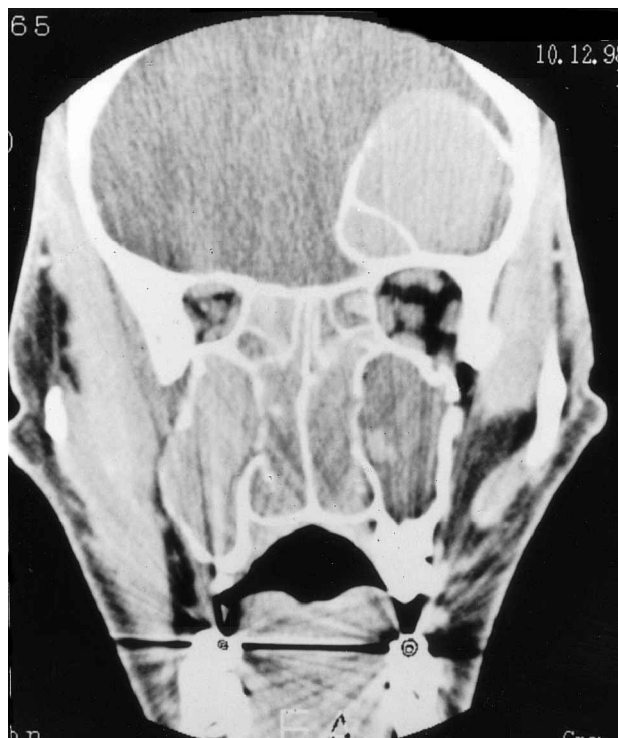

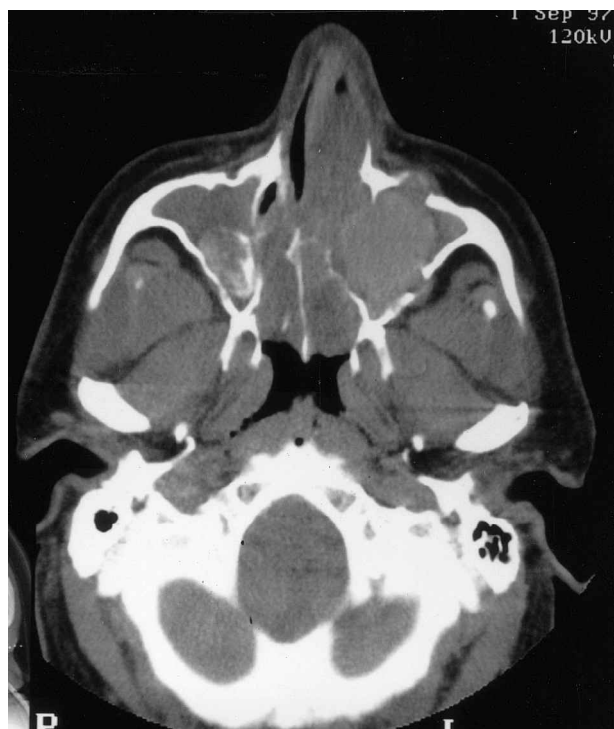
FIG. 4

Coronal CT scan showing extensive expansion of the frontal sinus together with involvement of all other sinuses in allergic fungal disease.

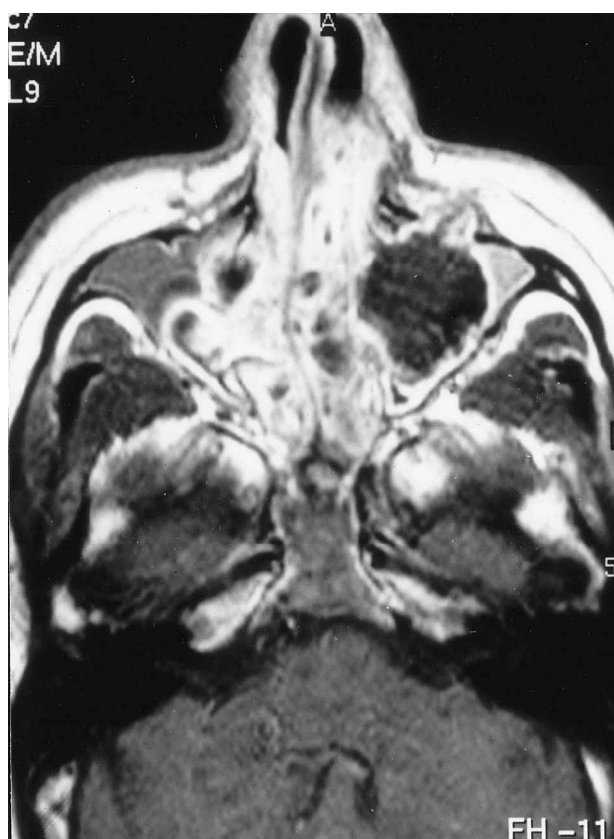
*Sclerosing invasive* In the rare form of invasive sclerosing infection a fibrotic midline space-occupying mass is seen, usually involving both orbits, again with extension into the intracranial cavity (Figure 8). As the process is one of fibrosis, fungal hyphae are few in number and the characteristic high density is again absent.

#### Magnetic resonance imaging

Three-plane  $T_1$ -weighted imaging with and without enhancement using an intravenous paramagnetic agent (gadolinium chelate) and a single axial  $T_2$ -weighted sequence offer the most information concerning intracranial extension of disease, but MRI should not be regarded as the primary imaging modality in fungal infection. The relaxation times of tissue are related to the percentage of free water, the amount of proteinaceous secretion and the presence of paramagnetic or ferromagnetic material.<sup>7</sup> Thus fungal sinusitis may result in either low, intermediate or high signal on  $T_1$  or  $T_2$ -weighted images, depending on the proportion of various chemical constituents. Fungal material may be very low in signal intensity on  $T_1$ -weighted sequences (Figures 1b, 3b, 5b) and can produce a signal void on  $T_2$ -weighted sequences.<sup>2</sup> This may give rise to an apparently 'empty' sinus with a rim of inflammatory mucosa. This mucosa often has an irregular appearance or 'fuzzy edge', characteristic of fungal infection. As a consequence it is always advisable to perform CT before proceeding to MRI, which will give further information on intracranial and intraorbital extension. The situation may be further clarified by the subtraction of  $T_1$ -weighted images done with and without gadolinium,<sup>8</sup> though this will also highlight any adjacent dural inflammation which may be seen in the chronic invasive form of the disease, as well as normal mucosal enhancement. Indeed, thickened mucosa usually enhances more intensely than the fungal material adjacent to it.



(a)



(b)

FIG. 5

(a) Axial CT and (b) axial MRT (T<sub>1</sub>-weighted sequence with gadolinium DPTA) showing erosion of the anterior wall of the maxillary sinus in allergic fungal disease.

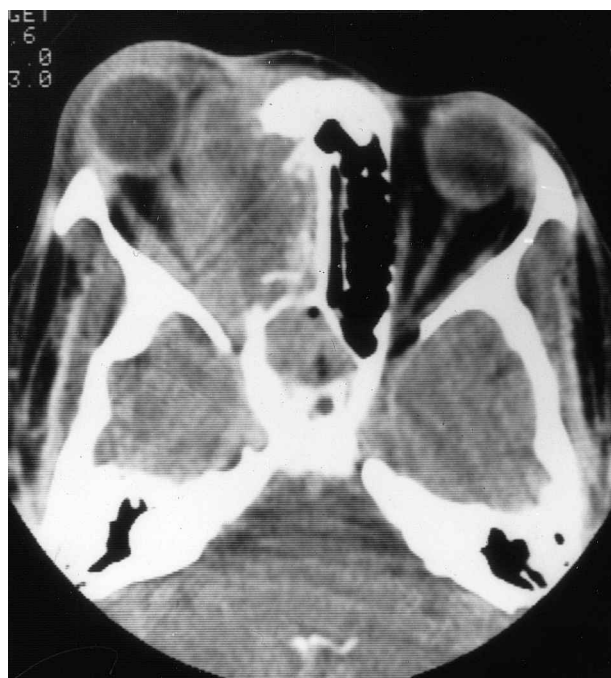

FIG. 6

Axial CT scan showing extensive unilateral orbital, ethmoid and sphenoid sinus involvement in chronic invasive fungal rhinosinusitis (with thanks to A.D. Cheesmen).

**Differential diagnosis**

This appearance must be distinguished from the dense areas occasionally seen within inverted papilloma, and almost always within chondrosarcoma, by the pattern of

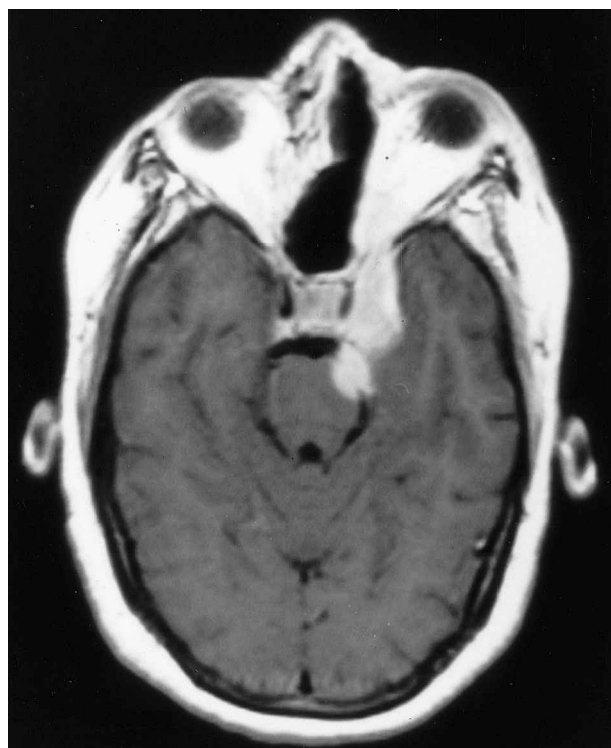

FIG. 7

Axial MRI (T<sub>1</sub>-weighted sequence with gadolinium DPTA) showing invasion of the orbital apex, cavernous sinus and middle cranial fossa despite previous radical surgery in acute fulminant fungal infection.

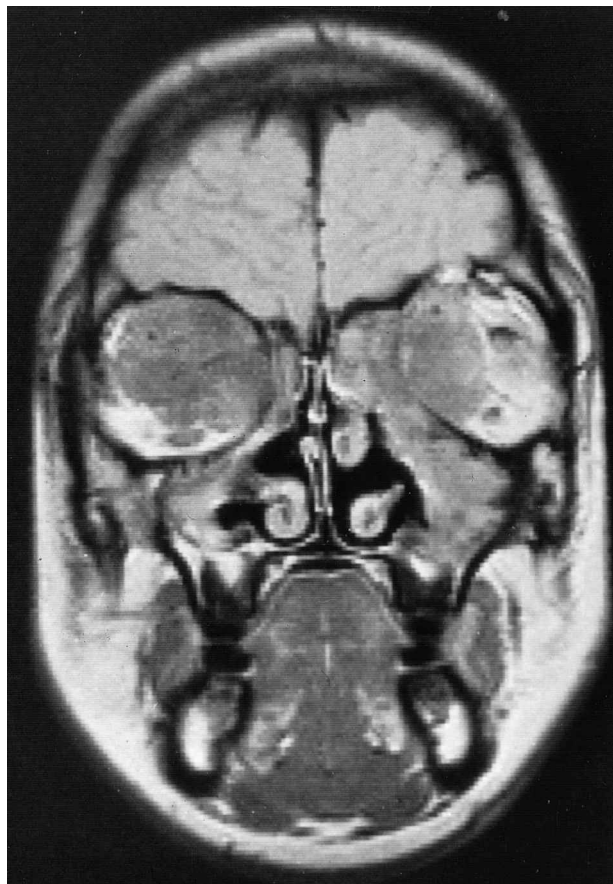


FIG. 8

Coronal MRI (proton density image) showing bilateral orbital involvement in invasive sclerosing fungal infection (with thanks to A. D. Cheesman).

distribution of disease within the sinuses and by the shape of the high-density regions. In chondrosarcoma the calcification within the mass is stippled and multifocal and the density of the calcification higher than that generally found in fungal infection. Its distinction is much more difficult on MRI.

### Conclusions

CT is the most practical primary imaging modality for suspected fungal disease of the sinuses and is probably more accurate than MRI in terms of diagnostic specificity and in defining the extent of bone erosion.

A different scanning technique than is used for routine sinus CT is required to demonstrate the typical soft tissue density variations of fungi adequately.

MRI should be used to supplement CT to visualize intracranial or intraorbital disease extension more clearly, if this is suspected clinically or on CT.

### References

- 1 Stammberger H, Jakse R, Beaufort F. Aspergillosis of the paranasal sinuses: X-ray diagnosis, histopathology, and clinical aspects. *Ann Otol Rhinol Laryngol* 1984;**93**:251–6
- 2 Zinreich S, Kennedy DW, Malat J, *et al.* Fungal sinusitis: diagnosis with CT and MR imaging. *Radiology* 1988;**169**:439–44
- 3 Som PM, Curtin, HD. Chronic inflammatory sinonasal diseases including fungal infections: the role of imaging. *Radiol Clin North Am* 1993;**31**:33–44
- 4 Mukherji SK, Figueroa RE, Ginsberg LE, Zeifer BA, Marple BF, Alley JG, *et al.* Allergic fungal sinusitis: CT findings. *Radiology* 1998;**207**:417–22
- 5 Bent JP, Kuhn FA. The diagnosis of allergic fungal sinusitis. *Otolaryngeol Head Neck Surg* 1994;**111**:580–8
- 6 Lund VJ, Mackay IS. Staging in rhinosinusitis. *Rhinology* 1993;**31**:183–4
- 7 Som PM, Dillon WP, Fullerton, GD, *et al.* Chronically obstructed sinonasal secretions: observations on T<sub>1</sub> and T<sub>2</sub> shortening. *Radiology* 1989;**172**:515–20
- 8 Lund VJ, Lloyd GAS, Howard DJ, Cheesman AD, Phelps PD. Enhanced magnetic resonance imaging and subtraction techniques in the postoperative evaluation of craniofacial resection for sinonasal malignancy. *Laryngoscope* 1996;**106**:553–8
- 9 DeShazo RD, Chapin K, Swain RE. Fungal sinusitis. *N Engl J Med* 1997;**337**:254–9

Address for correspondence:

Professor VJ Lund,  
Institute of Laryngology & Otology,  
University College London,  
330 Gray's Inn Road,  
London WC1X 8DA,  
UK.

Fax: 0171-833 9480