



Letter to the Editor: New Observation

Oculomotor Findings in Spinocerebellar Ataxia 27B: A Case Series

Guillemette Clément^{1,2} , Salomé Puisieux^{1,2}, Catherine Ashton³, David Pellerin^{3,4} , Matt C. Danzi⁵, Céline Bonnet^{2,6}, Virginie Roth⁶, Marion Wandzel⁶, Armand Hocquel¹, Carine Pourié², Natacha Dreumont², Laetitia Lambert⁷, Henry Houlden⁴, Stephan Zuchner⁵, Bernard Brais^{3,8}, Imen Ben Rejeb⁷, Solène Frismand^{1,2} and Mathilde Renaud^{1,2,9}

¹Service de Neurologie, Centre hospitalier Régional Universitaire de Nancy, Nancy, France, ²INSERM-U1256 NGERE, Université de Lorraine, Nancy, France, ³Department of Neurology and Neurosurgery, Montreal Neurological Hospital and Institute, McGill University, Montreal, QC, Canada, ⁴Department of Neuromuscular Diseases, UCL Queen Square Institute of Neurology and The National Hospital for Neurology and Neurosurgery, University College London, London, UK, ⁵Dr. John T. Macdonald Foundation Department of Human Genetics and John P. Hussman Institute for Human Genomics, University of Miami, Miami, FL, USA, ⁶Laboratoire de génétique, Centre Hospitalier Régional Universitaire de Nancy, Nancy, France, ⁷Service d'ORL et chirurgie cervico-faciale, CHRU de Nancy Hôpitaux de Brabois, Vandœuvre-lès-Nancy, France, ⁸Department of Human Genetics, McGill University, Montreal, QC, Canada and ⁹Service de Génétique Clinique, Centre Hospitalier Régional Universitaire de Nancy, Nancy, France

Keywords: *FGF14*; oculomotor disorders; gait disorders; cerebellar ataxia; SCA27B

Spinocerebellar ataxia 27B (SCA27B) is a recently described cause of autosomal dominant cerebellar ataxia caused by a (GAA)_n(TTC)_n repeat expansion in intron 1 of the fibroblast growth factor 14 (*FGF14*) gene.¹ The disease is clinically characterised by an adult-onset, slowly progressive pancerebellar syndrome that is frequently associated with: episodic symptoms; visual disturbances, such as diplopia; and cerebellar oculomotor signs.^{2,3} It is a common cause of previously unsolved late-onset cerebellar ataxia, with a frequency ranging from 10% to 61% in various ethnically diverse cohorts.^{1,2,4}

Visual disturbances and cerebellar oculomotor signs are common in spinocerebellar ataxia (SCA).⁵ Oculomotor disorders also appear to be common in SCA27B, with a prevalence as high as 95% in some series.^{2,3,6,7}

Here, we describe the oculomotor abnormalities detected on neurological examination of five patients with SCA27B after a standardised, recorded examination. The video of the oculomotor examination was independently reviewed by two neurologists with expertise in movement disorders. The study was filed and accepted on the clinicaltrials.gov platform with the trial registration number NCT05884086 (30/05/2023).

Four French patients, aged 79, 86, 61 and 78 years, and one French-Canadian patient, aged 61 years, were included in this series (Table S1). The age of onset of the disease ranged between 40 and 76 years, with a median duration of 10 years at the time of examination. All had an autosomal dominant family history of cerebellar ataxia. The median size of the GAA repeat expansion was 485 (range, 334–550). Four patients displayed progressive cerebellar ataxia, while one patient still only exhibited episodic ataxia (patient 3). The total score on the Scale for the Assessment and Rating of Ataxia for the four patients with progressive cerebellar ataxia ranged from 4.5/40 to 23/40. In three patients, cerebellar symptoms worsened with

alcohol intake and exercise; symptoms worsened with alcohol in one patient and with exercise alone in one patient.

The visual symptoms reported by the patients were mainly episodic diplopia (4/5), episodic visual blurring (3/5) and oscillopsia (3/5). Table S2 describes all the oculomotor anomalies found in the five patients. Cerebellar oculomotor anomalies on interictal clinical examination comprised abnormalities in eye pursuit. It was slow in all five patients and saccadic in four patients. When examining oculomotor saccades, only one patient had no saccade abnormalities. Two patients had isolated hypometric vertical saccades, and two had more severe saccade impairments with increased latencies, slow velocity and hypometria and, for one patient, a curved trajectory during vertical saccades with jerky oscillations at the end of the upward movement. Nystagmus was present in all patients. Two patients presented with downbeat nystagmus (DBN) and horizontal gaze-evoked nystagmus (GEN) (Video S1). Two patients had a combination of upbeat nystagmus, rebound nystagmus and horizontal-rotatory GEN. The score on the Scale for Ocular Motor Deficits in Ataxia for the 5 patients ranged from 4 to 9 out of 26, with the majority of scores for “jerk nystagmus” and “saccades” (Table S3). Oculomotor abnormalities were recorded in patient 3 during an attack of paroxysmal ataxia. The ocular pursuit was slow and saccadic. The patient displayed horizontal-rotatory nystagmus on lateral gaze, upbeat nystagmus on upward gaze and rebound nystagmus. Horizontal saccades were slow but not dysmetric, whereas vertical saccades were hypometric. Primary fixation was interrupted by saccadic intrusions.

The clinical oculomotor examination of patient 3, who was close to an episode, revealed abnormalities. At a distance from any episode, we were able to re-examine this patient, who no longer

Corresponding author: Guillemette Clément; Email: g.clement2@chru-nancy.fr

Guillemette Clément, Salomé Puisieux, Solène Frismand and Mathilde Renaud contributed equally to this work.

Cite this article: Clément G, Puisieux S, Ashton C, Pellerin D, Danzi MC, Bonnet C, Roth V, Wandzel M, Hocquel A, Pourié C, Dreumont N, Lambert L, Houlden H, Zuchner S, Brais B, Rejeb IB, Frismand S, and Renaud M. Oculomotor Findings in Spinocerebellar Ataxia 27B: A Case Series. *The Canadian Journal of Neurological Sciences*, <https://doi.org/10.1017/cjn.2024.355>

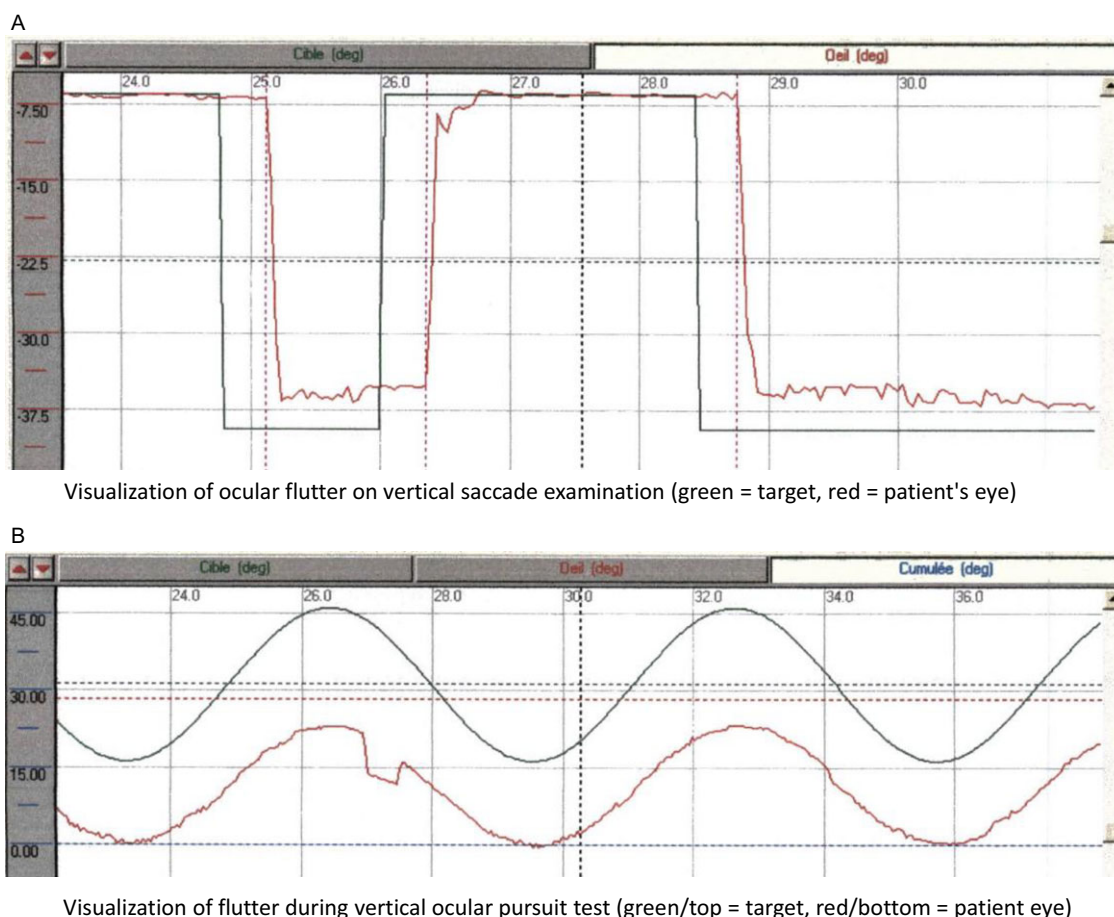


Figure 1. Graphic illustration of patient 3's vestibulonystagmography between episodes. (A) Visualization of ocular flutter on vertical saccade examination. (B) Visualization of flutter during vertical ocular pursuit test.

showed any visible manifestations. A vestibulonystagmography (VNG) examination could be carried out during this second evaluation, at a distance from an episode of ataxia.

Examination with VNG goggles showed flutter in all four gaze directions. Flutter can be visualized in both the vertical saccade test (Figure 1A) and the vertical pursuit test (Figure 1B). On the rotary chair test, there was a clear reduction in the vestibulo-ocular reflex gain in both clockwise and anticlockwise direction of the rotation.

Visual and cerebellar oculomotor abnormalities are among the most frequent manifestations of SCAs, with an estimated prevalence of 90% in SCA27B.² Our results support the previous findings from Pellerin et al., who highlighted a strong association between SCA27B and DBN and showed that SCA27B was a frequent genetic cause of DBN syndromes, accounting for almost 50% of previously idiopathic cases.³

Oculomotor assessment is important in SCA27B as it may show many possible oculomotor abnormalities beyond DBN. These may be present as early as the episodic stage, guiding the clinician towards this diagnosis. A complete oculomotor examination is therefore recommended in clinical practice to guide the molecular analysis of SCA27B. In fact, this ataxia seems to be very common among cerebellar ataxias.^{1,6,8} Although the diagnosis of certainty

obviously remains genetic, signs particularly favourable to the diagnosis will guide the genetic prescription.

It is likely that these various disorders reflect early damage to the cerebellum, particularly the cerebellar flocculus and paraflocculus, in the course of SCA27B.³

Cerebellar oculomotor disorders are common among cerebellar ataxia. Among other episodic ataxias, type 1 episodic ataxia (EA1) is linked to a pathogenic variant in the *KCNA1* gene and type 2 episodic ataxia (EA2) to a pathogenic variant in *CACNA1A*. Both ataxias begin in childhood and are characterised by episodes of ataxia. DBN is described in EA2 as in SCA27B, but oculomotor disturbances are usually absent in EA1.^{9,10}

About SCAs, impaired pursuit and saccadic dysmetria are observed in many SCAs (SCA 1, 2, 3, 6, 7 and 17) and may precede the first symptoms of ataxia.⁵ Sixty percent of patients with SCAs have nystagmus. Gaze-evoked nystagmus is the most commonly observed. In our cohort, gaze-evoked nystagmus was even more frequent and was found in all our patients. DBN was found in only two out of five patients (40%), a lower frequency than in the cohort of Méreaux et al., which found DBN in 63.6% of their patients.⁸

There are a number of therapeutic avenues for cerebellar ataxia, some of which are currently the subject of more in-depth research.

According to Ashton et al., a partial improvement was observed in the symptoms of SCA27B patients treated with acetazolamide.⁴ Another treatment considered in SCA27B is 4-aminopyridine, which reduced the frequency and/or severity of ataxic symptoms in a previous small series of patients with SCA27B.² Placebo-controlled video-oculography data of four *FGF14* patients previously enrolled in a 4-AP randomised double-blind trial showed a significant decrease in slow phase velocity of DBN with 4-AP, but not placebo.³

Visual symptoms and cerebellar oculomotor abnormalities are some of the key features of SCA27B. Proper assessment and treatment are major challenges in the management of SCA27B patients. Given the numerous oculomotor abnormalities found in SCA27B, further studies by videonystagmography should be performed to document these findings more precisely and on a larger scale.

Supplementary material. The supplementary material for this article can be found at <https://doi.org/10.1017/cjn.2024.355>.

Author contributions. G.C., S.P., C.A., S.F. and M.R. did study conception and design. Material preparation, data collection and analysis were performed by G.C., S.P., C.A., S.F. and M.R. The first draft of the manuscript was written by G.C. and D.P., and all authors commented on previous versions of the manuscript. IBR interpreted the VNG. All authors read and approved the final manuscript.

Funding statement. None.

Competing interests. Authors have no disclosures.

References

1. Pellerin D, Danzi MC, Wilke C et al. Deep intronic FGF14 GAA repeat expansion in late-onset cerebellar ataxia. *N Engl J Med*. 2023;388:128–141.
2. Wilke C, Pellerin D, Mengel D et al. GAA-FGF14 ataxia (SCA27B): phenotypic profile, natural history progression and 4-aminopyridine treatment response. *Brain*. 2023;146:4144–4157.
3. Pellerin D, Heindl F, Wilke C et al. GAA-FGF14 disease: defining its frequency, molecular basis, and 4-aminopyridine response in a large downbeat nystagmus cohort. *EBioMedicine*. 2024;102:105076.
4. Ashton C, Indelicato E, Pellerin D et al. Spinocerebellar ataxia 27B: episodic symptoms and acetazolamide response in 34 patients. *Brain Commun*. 2023;5(5):fcad239.
5. Peng Y, Tu Q, Han Y, Wan C, Gao L. Visual oculomotor abnormalities and vestibulo-ocular reflex dynamics in polyglutamine spinocerebellar ataxias (Review). *Exp Ther Med*. 2023;26(1):358.
6. Clément G, Puisieux S, Pellerin D, Brais B, Bonnet C, Renaud M. Spinocerebellar ataxia 27B (SCA27B), a frequent late-onset cerebellar ataxia. *Rev Neurol (Paris)*. 2024;180:410–416.
7. Loperigolo D. Oculomotor features in SCA27B patients. *Clin Neurophysiol*. 2024;158:56–58.
8. Méreaux JL, Davoine CS, Pellerin D et al. Clinical and genetic keys to cerebellar ataxia due to FGF14 GAA expansions. *EBioMedicine*. 2024;99:104931.
9. Jen J, Kim GW, Baloh RW. Clinical spectrum of episodic ataxia type 2. *Neurology*. 2004;62:17–22.
10. Graves TD, Griggs RC, Bundy BN et al. Episodic ataxia type 1: natural history and effect on quality of life. *Cerebellum* 2023;22(4):578–586. doi: [10.1007/s12311-021-01360-6](https://doi.org/10.1007/s12311-021-01360-6).