



Experience of left ventricular outflow tract arrhythmia ablation in paediatric patients using limited fluoroscopy and three-dimensional mapping technique

Original Article

Cite this article: Ballı Ş, Kanlıoğlu P, and Akgun G (2024) Experience of left ventricular outflow tract arrhythmia ablation in paediatric patients using limited fluoroscopy and three-dimensional mapping technique. *Cardiology in the Young* 34: 1026–1031. doi: [10.1017/S1047951123003955](https://doi.org/10.1017/S1047951123003955)

Received: 24 August 2023
Revised: 30 October 2023
Accepted: 10 November 2023
First published online: 1 December 2023

Keywords:

Left ventricular outflow tract arrhythmia; ablation; three-dimensional mapping

Corresponding author:

Ş. Ballı; Email: drsevketballi@hotmail.com

Şevket Ballı¹ , Pinar Kanlıoğlu¹ and Gokmen Akgun² 

¹Department of Pediatric Cardiology, Dr. Siyami Ersek Thoracic and Cardiovascular Surgery Training & Research Hospital, University of Health Sciences, Istanbul, Turkey and ²Department of Pediatric Cardiology, Kocaeli City Hospital, Kocaeli, Turkey

Abstract

Objective: The left ventricular outflow tract is an important source of ventricular arrhythmias. Up to one-third of all idiopathic ventricular arrhythmias in patients with structurally normal hearts may arise from this region. We would like to share the results of our left ventricular outflow tract ablation using three-dimensional mapping and limited fluoroscopy. **Materials and Methods:** This is a single-centre retrospective cohort study. Forty-six consecutive patients who underwent left ventricular outflow tract ablation procedures between January 2015 and June 2023 were included in the study. The EnSite Precision System (Abbott, St. Paul, MN, USA) was used to facilitate mapping and to reduce or eliminate the need for fluoroscopy. **Results:** The study group comprised 29 males and 17 females, with a mean age of 13.4 ± 4.5 years. The most common location for arrhythmias was the left coronary cusp (n : 21). Other locations, in sequence, included the junction of the right and left coronary commissure (n : 10), right coronary cusp (n : 10), left ventricular outflow tract endocardium (n:4), aorto-mitral junction (n : 1), and great cardiac vein (n : 1). Nine of these patients had previously undergone unsuccessful right ventricular outflow tract ablation at another centre. Cryoablation was performed in three patients, irrigated radiofrequency ablation in three patients, and conventional radiofrequency ablation in the remaining patients. The acute success rate was 100%, and no recurrences were observed. The mean follow-up period was 49.6 ± 24.4 months. All patients were asymptomatic and were being followed without antiarrhythmic medication. **Conclusion:** Although left ventricular outflow tract ablations pose a risk for coronary artery and heart valve complications, they can be performed successfully and safely with the guidance of three-dimensional mapping.

The left ventricular outflow tract is a common source of ventricular arrhythmias in patients with structurally normal hearts.^{1,2} While idiopathic ventricular arrhythmia generally carries a favourable prognosis, there exists a small risk of sudden cardiac death or left ventricular dysfunction.^{3,4} Catheter ablation is an effective therapy for these arrhythmias, but careful consideration of potential risks is essential. Three-dimensional mapping is widely used for left ventricular outflow tract ablation in adults, but research in children is limited. This study aims to present outcomes of left ventricular outflow tract ablation using three-dimensional mapping and limited fluoroscopy.

Material and method

Patient population

This retrospective cohort study was conducted at a single centre. A total of 47 consecutive patients who underwent ablation procedures between January 2015 and June 2023 were included in the study. Ethical approval was obtained from the local ethics committee, and written informed consent was obtained from all patients prior to the procedure. Clinical and periprocedural data were collected from electronic medical records and the electrophysiology laboratory database.

The inclusion criteria for the study defined idiopathic left ventricular arrhythmia as the presence of ventricular tachycardia or premature ventricular complexes in the absence of structural heart disease or identifiable predisposing causes. Prior to the ablation procedure, all patients underwent a comprehensive evaluation, including a physical examination, 12-lead electrocardiography, 24-hour Holter monitoring, exercise testing, and transthoracic echocardiogram to assess left ventricular function. Additionally, a thorough family history of sudden death was obtained. Patients with congenital or structural heart disease were excluded

from the study. Antiarrhythmic medication was discontinued at least five half-lives prior to the electrophysiologic study.

The indications for ablation in children with idiopathic left ventricular arrhythmia included symptomatic ventricular tachycardia episodes, a high burden of ventricular arrhythmia associated with ventricular dysfunction, failure of antiarrhythmic medication, and exercise-induced or unsuppressed ventricular arrhythmia. To facilitate the procedure and minimise or eliminate the need for fluoroscopy, the EnSite Precision System (Abbot, St Paul, MN, USA) was utilised for mapping purposes.

Electrocardiographic analysis

All patients included in the study exhibited ventricular arrhythmias with an inferior axis. Prior to the ablation procedure, various electrocardiographic parameters were evaluated, including the R wave transition in precordial leads, V2S/V3R ratio, V2 transition ratio, DIII/DIIR ratio, aVL/avR Q ratio, and maximum deflection index. The assessment of these findings was based on previous studies.^{5,6}

Three-dimensional mapping system

This system integrates magnetic cardiac geometry creation technology with an impedance-based platform, resulting in a dual technology system.^{7,8} The EnSite Precision mapping system (St Jude/Abbott Medical, St Paul, MN, USA) incorporates features like AutoMap and TurboMap. AutoMap continuously records multiple simultaneous points from multiple electrodes for anatomy, voltage, and activation sequence mapping. TurboMap, on the other hand, enables the replay of any tachycardia occurring during the initial mapping at a speed ten times faster than normal, facilitating the creation of activation maps without the need for manual remapping. SparkleMap complements this by providing a video representation of the activation overlaid on the voltage map on the three-dimensional geometry model. Additionally, colour-coded fractionation maps, which automatically annotate fractionated electrograms, are useful in identifying ablation targets. Another important feature is AutoMark, which uses real-time contact force recordings to provide colour-coded lesion formation designations.

Electrophysiologic study

The procedure was primarily conducted under local anaesthesia, with conscious sedation administered to patients who were unable to tolerate it. The coronary sinus catheter was advanced into the great cardiac vein until the proximal electrode pair recorded an earlier ventricular activation than the most distal electrode pair during ventricular arrhythmias. Intravenous heparin was administered to maintain an activated clotting time of > 300 s during left ventricular outflow tract procedures. In cases where clinical arrhythmias did not occur spontaneously, programmed stimulation was performed. The standard protocol involved ventricular stimulation at two basic drive cycle lengths with up to two extrastimuli, with a minimum coupling interval of 230 ms. If ventricular arrhythmia was not inducible at baseline, intravenous isoproterenol infusion (2–5 µg/min) was administered to provoke clinical arrhythmias.

The EnSite Precision mapping system was routinely utilised for mapping purposes. Activation mapping, based on activation time in bipolar electrograms and qS complex in unipolar electrogram from the distal electrode, was the primary mapping strategy employed. In cases of ventricular tachycardia originating from the

outflow tract, mapping of the right ventricular outflow tract was typically performed initially. If early local activation was not found in the right ventricular outflow tract, a retrograde approach was used to map the left ventricular outflow tract. In cases where an adequate number of premature ventricular contractions and ventricular tachycardia could not be induced, pace mapping was performed. The pace mapping score provided by the electro-anatomic mapping system was evaluated as significantly meaningful with a value of 95%. Prior to catheter ablation within the aortic sinus cusps, selective angiography of the coronary artery and aorta was performed to accurately define the location of the ablation catheter, prevent arterial injury, and delineate coronary sinus ostia in the aortic sinus cusps. Coronary angiography was performed as necessary to visualise any changes in the position of the ablation catheter during the procedure. Continuous fluoroscopy was employed during energy application to detect any catheter dislodgement. Electrocardiogram data, including ST or T wave changes, were monitored throughout the procedure. In the event of catheter dislodgement and/or electrocardiogram changes, radiofrequency application was immediately terminated. Radiofrequency ablation was avoided within a five mm proximity to the coronary artery. The endpoint of the catheter ablation was the elimination and non-inducibility of ventricular tachycardia or premature ventricular complexes during an isoproterenol infusion and burst pacing from the right ventricle. Following catheter ablation within the aortic sinus cusps, repeat coronary angiography was performed to ensure no evidence of injury to the coronary arteries. The patient was monitored for at least 30 minutes to ensure no recurrence of arrhythmias.

Ablation

Radiofrequency energy was applied using the RF Mariner 4 mm catheter (Medtronic, Inc., Minneapolis, USA). In cases where radiofrequency ablation was unsuccessful, an irrigated ablation catheter was utilised. Radiofrequency energy was initiated at 25 W and increased to 35 W over a period of 30–60 s at the level of the aortic cusps. During ablation, a 15% impedance drop was targeted. If ventricular tachycardia or premature ventricular complexes were still present 10 s after the start of ablation, the application was stopped. Cryoablation (Freezor Cryocath, Medtronic, Inc., Minneapolis, USA) was employed in locations near the conduction system and coronary artery, with a target temperature of –75°C for a duration of 240 s.

Statistical analysis

Statistical analysis was performed using SPSS 22.0 (IBM Corporation, Armonk, New York, United States). Quantitative data were expressed as mean ± standard deviation or median range (minimum–maximum) values. Categorical values were presented as n (number) and % (percentage).

Results

The study included a total of 47 patients, consisting of 29 males and 18 females, with a mean age of 13.4 ± 4.5 years. The clinical data of the patients are presented in Table 1. The majority of patients were symptomatic, with palpitations being the most common symptom reported. All patients exhibited high-grade ventricular arrhythmias, including nonsustained ventricular tachycardia (n : 9), sustained ventricular tachycardia (n : 4), and isolated premature ventricular complexes. Two patients experienced sustained

Table 1. Electrocardiographic findings.

	LCC (n:21)	RCC (n:10)	LCC-RCC (n:10)	LVOT endocardial (n:4)	AMC (n:1)	Epicardial (n:1)
PVC, %	36.2 ± 13.6	35.6 ± 11.7	32.8 ± 9.8	34.3 ± 9.4	28	26
Sustained VT, n	2	1	1	1		
Nonsustained VT, n	3	1	1	1		
Cardiomyopathy, n	3	2	2			
V1 transition, n	2			0	1	
V2 transition, n	19	1	6	3		1
V3 transition, n	0	9	4	1		
V4 transition, n	0					
V2 transition ratio	0.91 ± 0.28	0.43 ± 0.4	0.55 ± 0.15	0.53 ± 0.07	0.48	0.54
V2S/V3R ratio	1.29 ± 0.22	1.32 ± 0.33	1.31 ± 0.22	1.33 ± 0.11	1.35	1.28
DIII/DII R ratio	1.22 ± 0.22	0.92 ± 0.18	1.1 ± 0.19	1.21 ± 0.22	1.1	1.75
aVL/aVR Q ratio	1.32 ± 0.32	1.40 ± 0.42	1.36 ± 0.41	1.41 ± 0.12	1.38	1.72
MDI, %	53.31 ± 5.72	52.4 ± 10.33	54.23 ± 4.82	53.21 ± 12.61	0.52	0.62

AMC = aorto-mitral continuity; LCC = left coronary cusp; LVOT = left ventricular outflow tract; MDI = maximum deflection index, n = number; PVC = premature ventricular contraction; RCC = right coronary cusp.

ventricular tachycardia during exercise testing, while no arrhythmias were detected during Holter monitoring in the two patients with sustained ventricular tachycardia. Eight patients were asymptomatic, and their arrhythmias were discovered incidentally during routine testing. The mean burden of premature ventricular complexes in the 24-hour Holter electrocardiogram was $35.9 \pm 13.2\%$. Among the patients, 22 were receiving antiarrhythmic treatment, with 17 beta blockers, three flecainide, and two sotalol. Left ventricular dysfunction was detected in seven patients, all of whom were male.

Electrocardiography findings

All ventricular arrhythmias exhibited an inferior axis, and a transition zone was observed at or before V3. Deep Q waves were present in leads aVR and aVL. During clinical ventricular arrhythmias, two patients demonstrated a right bundle branch block morphology, while the remaining patients exhibited a left bundle branch block morphology with an early transition at V2–V3. Detailed information regarding R wave transition in precordial leads, V1–V2 R wave duration, V2S/V3R ratio, V2 transition ratio, DIII/DII R ratio, aVL/aVR S ratio, R wave duration index, and maximum deflection index can be found in Table 2.

Ablation findings

Due to the absence or non-inducibility of arrhythmia in two patients, the procedure could not be performed on them. Sustained ventricular tachycardia was induced in two patients, while nonsustained ventricular tachycardia was induced in four patients.

All procedures began with mapping of the right ventricular outflow tract. If mapping or ablation in this area failed, mapping of the left ventricular outflow tract was performed. Cryoablation was performed in three patients due to the proximity to the coronary artery orifices and conduction tissue, while radiofrequency ablation was performed in all other patients. Activation mapping was utilised in all procedures, and pace mapping was used in eight cases. Among the patients who underwent pace mapping, the mean percentage of compatibility was 96% (range: 94.1–100).

The most common ablation site was the left coronary cusp (n : 21), followed by the junction of the right and left coronary commissure (n : 10), the right coronary cusp (n : 10), the endocardium of the left ventricular outflow tract (n:4), the aorto-mitral junction (n : 1), and the great cardiac vein (n : 1) (Figs. 1, 2). In cases where right ventricular outflow tract ablation had previously been unsuccessful at another centre, we successfully performed ablation in the right coronary cusp in six out of nine patients and in the junction of the right coronary cusp and left coronary cusp in three patients.

The mean time for clinical disappearance of ventricular arrhythmia was 5.5 ± 3 s, with a mean power of 48.4 W. On bipolar recording, the earliest ventricular activation preceding the QRS onset was 38.6 ± 13.2 ms during ventricular arrhythmia. The mean number of radiofrequency pulses used was 4.9 ± 4.7 (range: 1–16). Further details about the procedure can be found in Table 2.

No complications occurred during the ablation procedures. There were no observed ST-T segment or T wave changes during mapping and ablations. Aortic valve damage and wall motion abnormalities were not observed in any of the patients following the procedure.

Table 2. Patient characteristics and procedural data.

Age (year)	13.4 ± 4.5
Gender (M/F)	29/18
Weight (kg)	48.3 ± 16.2 (22–83)
Procedure time (minute)	169.5 ± 49.7
Fluoroscopy time (minute)	6.9 ± 5.3
Number of total lesion	5.3 ± 2.8
Total lesion duration (ms)	175.3 ± 96.3
Earliest ventricular activation (ms)	48.4 ± 22.14
Arrhythmia disappearance time (ms)	2.6 ± 1.4
Catheter type RFA, n	41
Irrigated RFA, n	3
Cryoablation, n	3

RFA = radiofrequency ablation catheter; ms = millisecond; n = number.

Follow-up

Follow-up was conducted through either inpatient or outpatient visits, or through phone communication without a pre-scheduled follow-up period. The mean duration of follow-up was 49.6 ± 24.4 months. None of the patients required antiarrhythmic drug therapy. Aspirin was administered for a duration of three months. No patients experienced any recurrence of arrhythmia during the 48-hour Holter monitoring following the procedure. Transthoracic echocardiography was performed immediately before discharge and at three and six months post-ablation for all patients. At the end of the six-month period, all six patients had their systolic function restored to normal.

Discussion

Ventricular arrhythmias can present with symptoms such as palpitations, chest tightness, and shortness of breath, although they can also be asymptomatic. Treating these arrhythmias is crucial due to the associated risks of tachycardia-induced cardiomyopathy and sudden death.⁹ The likelihood of developing cardiomyopathy increases with a higher burden of ventricular arrhythmias. Ablation plays a significant role in achieving a curative treatment approach. It is worth noting that this study represents the largest number of cases conducted among paediatric patients in this field, to the best of our knowledge.

During the ablation procedure in the aortic cusp, it is important to consider the spatial configurations of the left ventricular outflow tract and right ventricular outflow tract, as well as the proximity of the coronary arteries to the ablation zone. While the right ventricular outflow tract is composed entirely of myocardial tissue, the left ventricular outflow tract contains both fibrous and myocardial tissue. The conduction tissue passing beneath the fibrous structure is critically important during the ablation procedure. Although the right coronary cusp and left coronary cusp contain myocardial tissue, the non-coronary cusp consists mostly of fibrous tissue and is not typically significant as an arrhythmia focus.¹⁰ When ablation in the right ventricular outflow tract is unsuccessful, it is crucial to consider the right coronary cusp and the junction

of the right coronary cusp and left coronary cusp as alternative locations. In our case series, out of the nine patients who had unsuccessful ablations in the right ventricular outflow tract at other centres, we achieved successful ablation in the right coronary cusp in six patients and at the junction of the right coronary cusp and left coronary cusp in three patients.

In line with previous studies, our findings support the notion that the left coronary cusp region is the most frequently identified site for arrhythmia localisation.¹¹ Conversely, the non-coronary cusp is an uncommon origin site for ventricular arrhythmias, as it is not directly connected to the ventricular myocardium, except for the peri-His area. Although there have been rare reported cases of ventricular arrhythmias originating from the non-coronary cusp,¹² none of the patients in our study exhibited arrhythmias originating from the non-coronary cusp.

The use of cryoablation is an important alternative in locations near the left ventricular outflow tract because of the proximity to the conduction system and coronary artery orifice. Cryoablation helps mitigate the risk of atrioventricular block and coronary damage.¹³ In our study, we utilised cryoablation in three patients, with two near the left coronary cusp and one near the conduction system. Previous studies have avoided ablation within a five mm range of the coronary arteries due to the risk of coronary damage. However, with the wider adoption of cryoablation, we believe this concern can be effectively addressed.

The left ventricular summit, located between the great cardiac vein, left anterior descending artery, and circumflex artery, plays a significant role in generating epicardial arrhythmias.¹⁴ Ablation procedures targeting this region can be challenging due to the dense presence of adipose tissue. In our case, when an early activation area could not be identified in the endocardial left ventricular outflow tract and coronary cusps, we successfully performed cryoablation by accessing the summit area through the great cardiac vein. Cryoablation is considered a safer alternative to radiofrequency ablation due to its lower risk of thrombosis and perforation.

There is increasing research about the link between frequent ventricular premature beats and the development of cardiomyopathy. In our study, we observed cardiomyopathy in seven patients. Treating the underlying rhythm disorder can potentially restore cardiac function. We found that in patients who developed cardiomyopathy, cardiac function returned to normal within a maximum of six months. Asymptomatic patients develop cardiac dysfunction due to delayed diagnosis. Studies have demonstrated that ablation therapy is more effective than antiarrhythmic therapy in achieving earlier normalisation of cardiac function.⁹

A detailed pre-procedural electrocardiogram evaluation is important in predicting the location of an arrhythmia. Parameters such as R wave transition in precordial leads, V1-V2 R wave duration, V2S/V3R ratio, V2 transition ratio, DIII/DIIR ratio, aVL/aVR Q ratio, and maximum deflection index are often utilised for this purpose.^{15,16} However, individual differences in cardiac rotation can impact these ratios and measurements. Other factors that influence the predictive accuracy of algorithms include lead positions, aorta deformities, chest wall thickness (e.g. obesity, chest wall deformity), ventricular hypertrophy, and preferential conduction.¹⁷ Yoshida et al. showed that a V2S/V3R cut-off value of ≤ 1.5 predicted left ventricular outflow tract origin with 89% sensitivity and 94% specificity.¹⁸ We recommend the Yoshida formula due to its ease of calculation and usability. All of our cases, except one, were consistent with this formula. In one case, with a

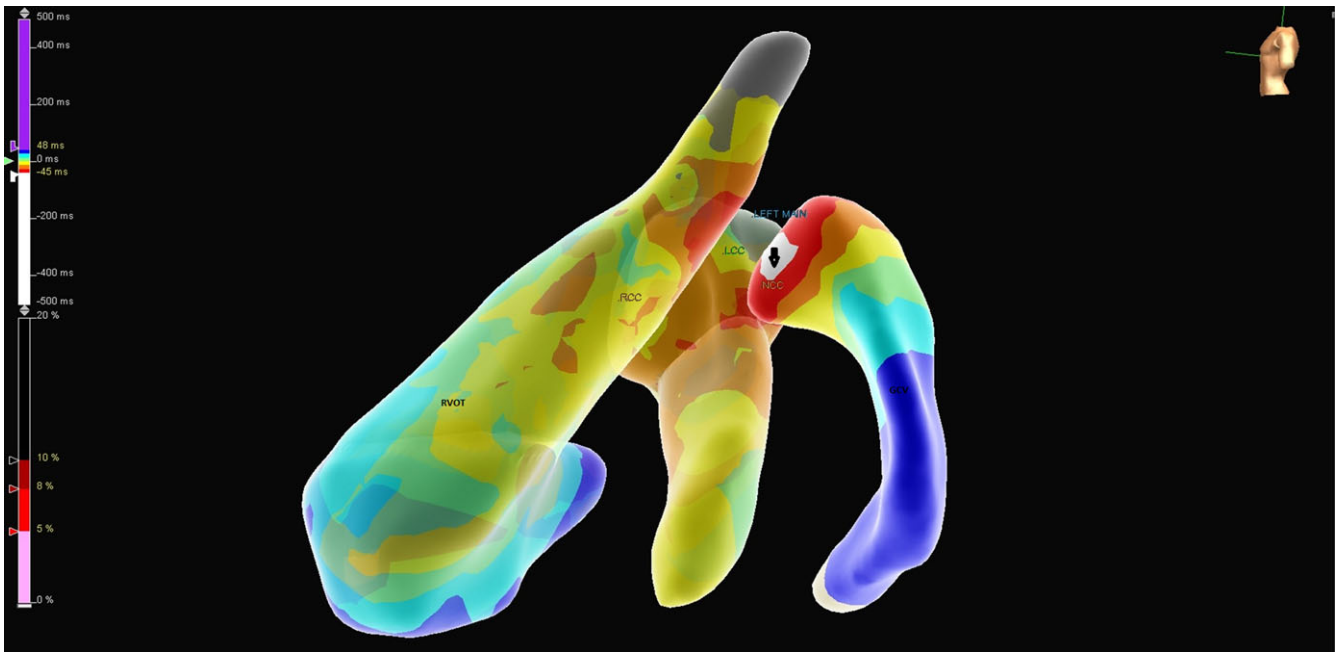


Figure 1. LCC, RCC, GCV, and RVOT are displayed in the 3D mapping. An early activation zone was detected in the branches of the great cardiac vein system during the mapping process. The black arrow indicates the white area where early activation occurs. (NCC = noncoronary cusp, LCC = left coronary cusp, RCC = right coronary cusp, GCV = great cardiac vein).

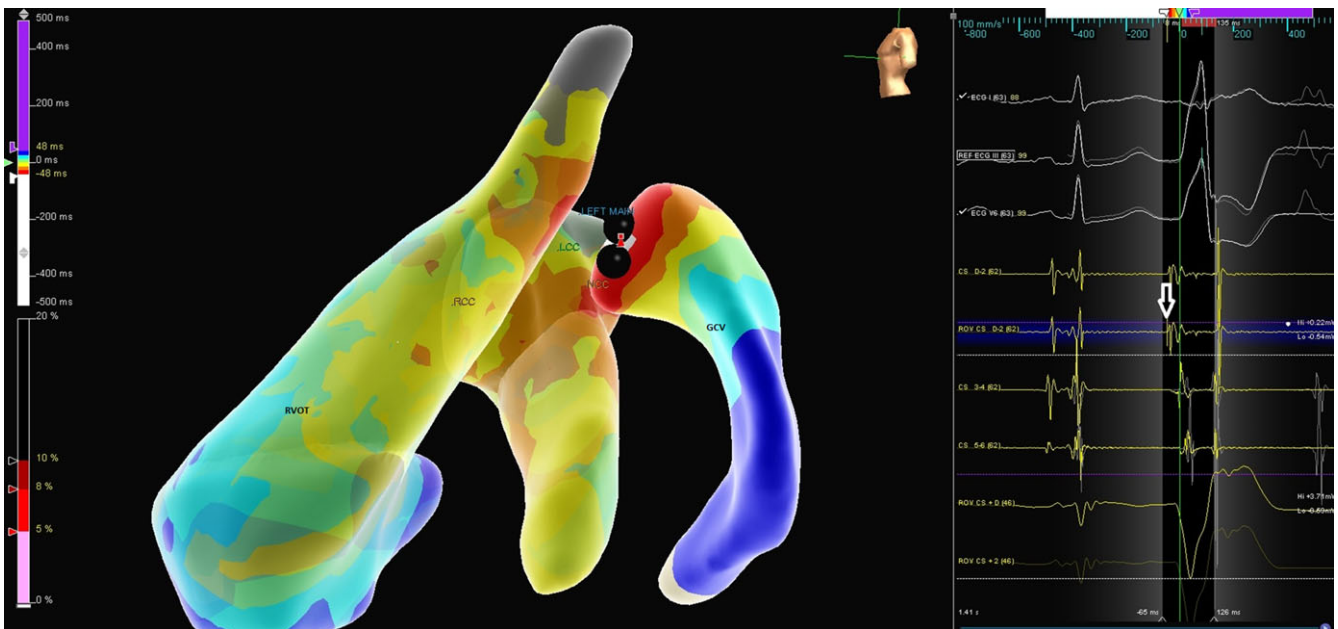


Figure 2. In the three-dimensional mapping, the lesions created with cryoablation catheters are visualised as black-coloured. The white arrow indicates the electrogram displaying early activation.

V3 transition ratio of 1.6, the origin was identified as the left ventricular outflow tract.

Conclusion

While left ventricular outflow tract ablations carry a potential risk of coronary artery and heart valve complications, they can be performed safely and successfully with the aid of three-dimensional mapping guidance.

Study limitation

This retrospective cohort study was conducted at a single centre, and it is important to consider that the results may be influenced by the patient population, as we primarily serve as a tertiary referral centre. Notably, intracardiac echocardiography was not utilised in this study. To ensure accurate measurements, it is crucial to assess the distance in two orthogonal views and preferably use a separate angiography catheter introduced from a contralateral access to clearly define the left main ostium. Alternatively, intracardiac

echocardiography can be used to evaluate the catheter position relative to the coronary artery ostia. Although it provides continuous monitoring of catheter position, it should be noted that this approach significantly increases the procedural cost.

Acknowledgements. None.

Financial support. This research received no specific grant from any funding agency, commercial, or not-for-profit sectors.

References

1. Lerman BB, Stein KM, Markowitz SM. Mechanisms of idiopathic left ventricular tachycardia. *J Cardiovasc Electrophysiol* 1997; 8: 571–583.
2. Callans DJ, Menz V, Schwartzman D, et al. Repetitive monomorphic tachycardia from the left ventricular outflow tract: electrocardiographic patterns consistent with a left ventricular site of origin. *J Am Coll Cardiol* 1997; 29: 1023–1027.
3. Cronin EM, Bogun FM, Maury P, et al. HRS/EHRA/APHRS/LAHRS expert consensus statement on catheter ablation. *Heart Rhythm* 2020; 17: e2–e154.
4. Pfammatter JP, Paul T. Idiopathic ventricular tachycardia in infancy and childhood: a multicenter study on clinical profile and outcome: working group on dysrhythmias and electrophysiology of the association for european pediatric cardiology. *J Am Coll Cardiol* 1999; 33: 2067–2072.
5. Nguyen MB, Ceresnak SR, Janson CM, et al. A multicenter review of ablation in the aortic cusps in young people. *Pacing Clin Electrophysiol* 2017; 40: 798–802.
6. Yamada T, Kumar V, Yoshida N, et al. Eccentric activation patterns in the left ventricular outflow tract during idiopathic ventricular arrhythmias originating from the left ventricular summit: a pitfall for predicting the sites of ventricular arrhythmia origins. *Circ Arrhythm Electrophysiol* 2019; 12: e007419.
7. Borlich M, Sommer P. Cardiac mapping systems: rhythmia, topera, enSite precision, and carto. *Card Electrophysiol Clin* 2019; 11: 4497–458.
8. Hsu JC, Darden D, Glover BM, et al. Performance and acute procedural outcomes of the enSite precisionTM cardiac mapping system for electrophysiology mapping and ablation procedures: results from the enSite precisionTM observational study. *J Interv Card Electrophysiol* 2022; 65: 141–151.
9. Tovia Oholi, Brodie MD, Yoav Michowitz MD, et al. Left ventricular outflow tract arrhythmias: clinical characteristics and site of origin. *Imaj* 2016; 18: 114–118.
10. Ouyang F, Fotuhi P, Ho SY, et al. Repetitive monomorphic ventricular tachycardia originating from the aortic sinus cusp: electrocardiographic characterization for guiding catheter ablation. *J Am Coll Cardiol* 2002; 39: 500–508.
11. Yamada T, McElderry HT, Doppalapudi H, et al. Idiopathic ventricular arrhythmias originating from the aortic root prevalence, electrocardiographic and electrophysiologic characteristics, and results of radiofrequency catheter ablation. *J Am Coll Cardiol* 2008; 52: 139–147.
12. Ioannidis P, Christoforatu E, Zografos T, et al. Ventricular ectopy from the non-coronary cusp: pathophysiological and anatomical considerations. *Indian Pacing Electrophysiol J* 2021; 21: 245–247.
13. Ergul Y, Ozgur S, Şahin GT, et al. Aortic cusp ablation for premature ventricular contractions and ventricular tachycardia in children: a 5-year single-center experience. *J Interv Card Electrophysiol* 2021; 61: 283–292.
14. Santangeli P, Lin D, Marchlinski FE. Catheter ablation of ventricular arrhythmias arising from the left ventricular summit. *Card Electrophysiol Clin* 2016; 8: 99–107.
15. Lin CY, Chung FP, Lin YJ, et al. Radiofrequency catheter ablation of ventricular arrhythmias originating from the continuum between the aortic sinus of Valsalva and the left ventricular summit: electrocardiographic characteristics and correlative anatomy. *Heart Rhythm* 2016; 13: 111–121.
16. Yamada T, McElderry HT, Doppalapudi H, et al. Idiopathic ventricular arrhythmias originating from the left ventricular summit anatomic concepts relevant to ablation. *Circ Arrhythm Electrophysiol* 2010; 3: 616–623.
17. Yoshida N, Inden Y, Uchikawa T, et al. Novel transitional zone index allows more accurate differentiation between idiopathic right ventricular outflow tract and aortic sinus cusp ventricular arrhythmias. *Heart Rhythm* 2011; 8: 349–356.
18. Yoshida N, Yamada T, McElderry HT, et al. A novel electrocardiographic criterion for differentiating a left from right ventricular outflow tract tachycardia origin: the V2S/V3R index. *J Cardiovasc Electr* 2014; 25: 747–753.