




Jessica W. Wong<sup>1</sup> , Erin Bock<sup>1</sup>, Wooi Seng Kee<sup>2</sup>, Aleisha J. Anderson<sup>3</sup>, Darshan Kothari<sup>2</sup> and Adrian J. Tarca<sup>2</sup>

## Brief Report

**Cite this article:** Wong JW, Bock E, Kee WS, Anderson AJ, Kothari D, and Tarca AJ (2023) Myopericarditis following COVID-19 vaccination in adolescent triplets. *Cardiology in the Young* 33: 2379–2383. doi: [10.1017/S1047951123001105](https://doi.org/10.1017/S1047951123001105)

Received: 16 April 2022  
Revised: 2 March 2023  
Accepted: 19 April 2023  
First published online: 8 May 2023

**Keywords:**

SARS-CoV-2; myocarditis; pericarditis; vaccine; COVID-19; BNT162b2

**Corresponding author:** Dr J. W. Wong, Emergency Department, Perth Children's Hospital, 15 Hospital Avenue, Perth, Western Australia 6009, Australia.  
E-mail: [jessicawinsee.wong@health.wa.gov.au](mailto:jessicawinsee.wong@health.wa.gov.au)

<sup>1</sup>Emergency Department, Perth Children's Hospital, Perth, Australia; <sup>2</sup>Department of Cardiology, Children's Cardiac Centre, Perth Children's Hospital, Perth, Australia and <sup>3</sup>Department of Infectious Diseases, Perth Children's Hospital, Perth, Australia

**Abstract**

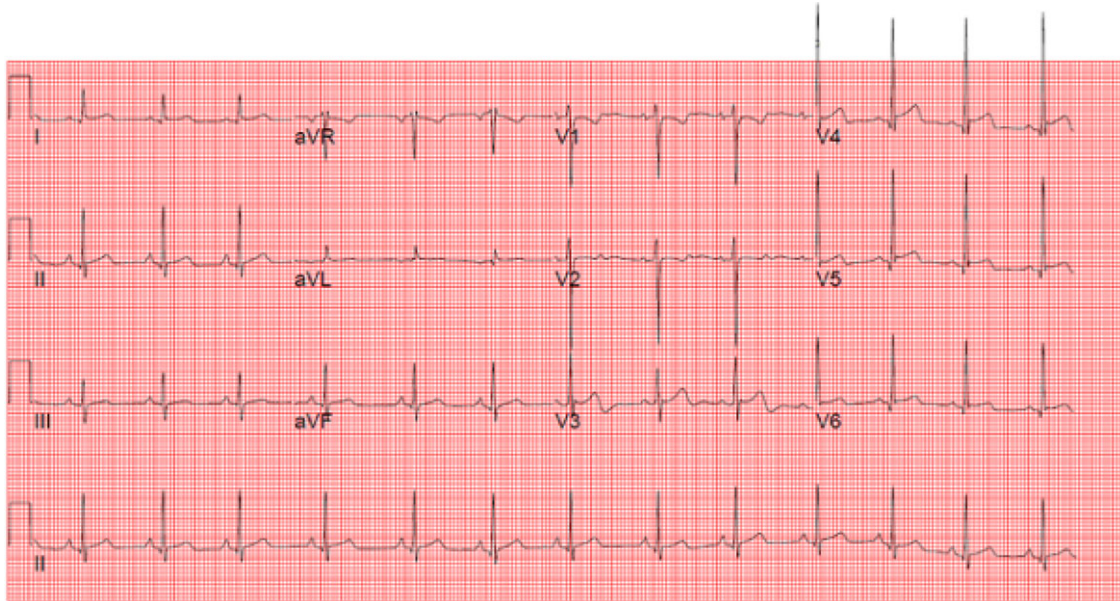
Multiple studies have reported myocarditis and pericarditis after the Pfizer-BioNTech coronavirus disease 2019 messenger ribonucleic acid vaccine. We describe male adolescent triplets who presented with myopericarditis within one week following vaccine administration.

In Australia, the Pfizer-BioNTech coronavirus disease 2019 mRNA vaccine (Pfizer vaccine) has been approved for prevention of COVID-19 for children aged five years or older, with real world effectiveness preventing hospitalisation of 94%.<sup>1</sup> Safety, immunogenicity, and efficacy have been demonstrated in a phase 2–3 trial for the 5- to 11-year-old cohort.<sup>2</sup> Pfizer vaccine-associated myopericarditis is a rare adverse event, with the highest rates observed in young males following the second dose.<sup>3,4,5</sup> There have been previous cases of familial clusters of acute idiopathic pericarditis and one previous report of vaccine-associated myocarditis in siblings.<sup>3,6</sup> We report a case of monochorionic triamniotic triplets with vaccine-associated myopericarditis.

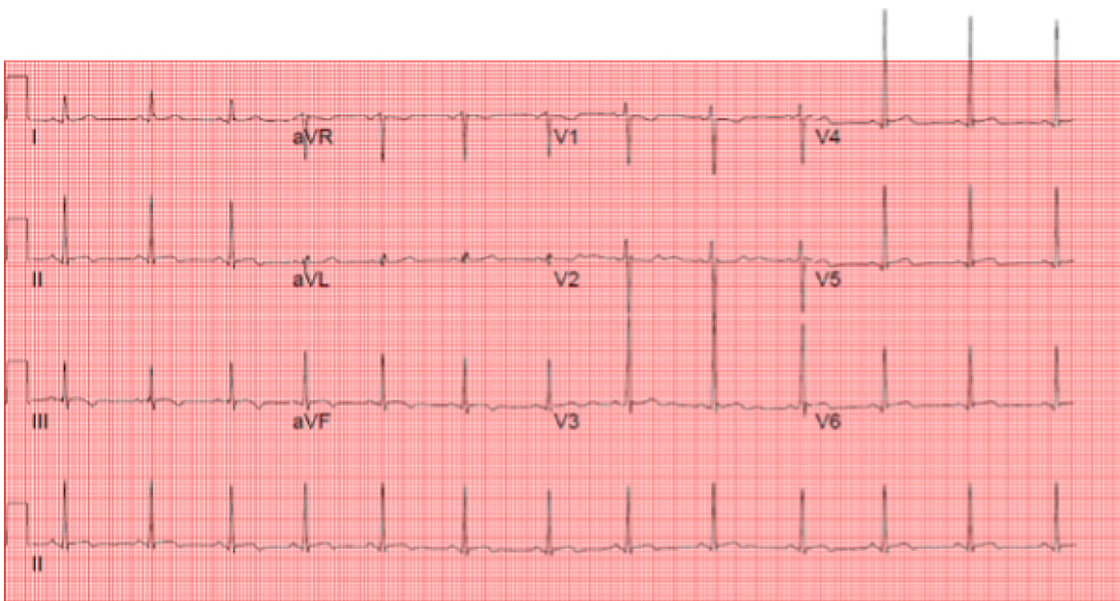
Thirteen-year-old male triplets developed left-sided chest pain after receiving the Pfizer vaccination. For Triplet 1, this occurred on day three following dose one. For Triplets 2 and 3, this occurred following the second dose of Pfizer, on day four and day five post-vaccine respectively. Triplets 1 and 3 reported fever on day one post-vaccination, whereas Triplet 2 had only localised injection site pain. In all cases, the chest pain was left-sided and radiated down the left arm. Triplet 1 had pain exacerbated by movement, whereas Triplets 2 and 3 had pain exacerbated by lying flat. All three triplets had a history of prematurity and mild asthma, not requiring preventer therapy. They had no personal history of COVID-19 infection and had no prior, or recurrent, episodes of chest pain, and no other reported adverse events following immunisation. There was no history of congenital cardiac disease, acute pericarditis, or autoimmune disease in immediate family members. Family history of myocarditis was denied at the time of admission; however, during outpatient follow-up, it was revealed that the triplets' maternal great aunt had an episode of non-vaccine-associated myocarditis, with concerns about a related cardiomyopathy.

All triplets were haemodynamically stable with normal cardiovascular examination on presentation to the tertiary paediatric emergency department. Initial electrocardiogram findings showed normal sinus rhythm and borderline ST-segment elevation in Triplet 1, normal sinus rhythm in Triplet 2, and normal sinus rhythm with occasional atrial ectopic beats in Triplet 3 (Fig 1, Figs 2 and 3 online). Laboratory tests for all triplets showed significantly elevated cardiac enzymes. Triplets 1 and 3 also had mildly elevated C-reactive protein. Echocardiograms revealed normal heart structure, dimensions, and function in all triplets; however, Triplet 1 had a mildly dilated left ventricular apex which had resolved on repeat echocardiogram post-discharge. Demographic and clinical comparative characteristics are shown in Table 1.

All triplets were admitted to the cardiology unit for cardiac monitoring and received regular ibuprofen, naproxen, or paracetamol. Triplet 1 and 2's troponins peaked at 2490 ng/L and 4530 ng/L, respectively, with chest pain resolving by day six. Triplet 3 had a Holter monitor revealing predominant sinus rhythm, with isolated periods of sinus arrhythmia, atrial ectopic beats (16% of total beats), and isolated occasional premature ventricular contractions, with no supraventricular tachycardia or ventricular tachycardia. He was discharged on day six post-vaccine with minimal chest pain. At outpatient cardiology reviews, all triplets' electrocardiograms and echocardiograms remained normal, with down-trending troponin levels.



**Figure 1.** Triplet 1 ECG showing sinus rhythm and mild ST elevation.



**Figure 2.** Triplet 2 ECG showing normal sinus rhythm.

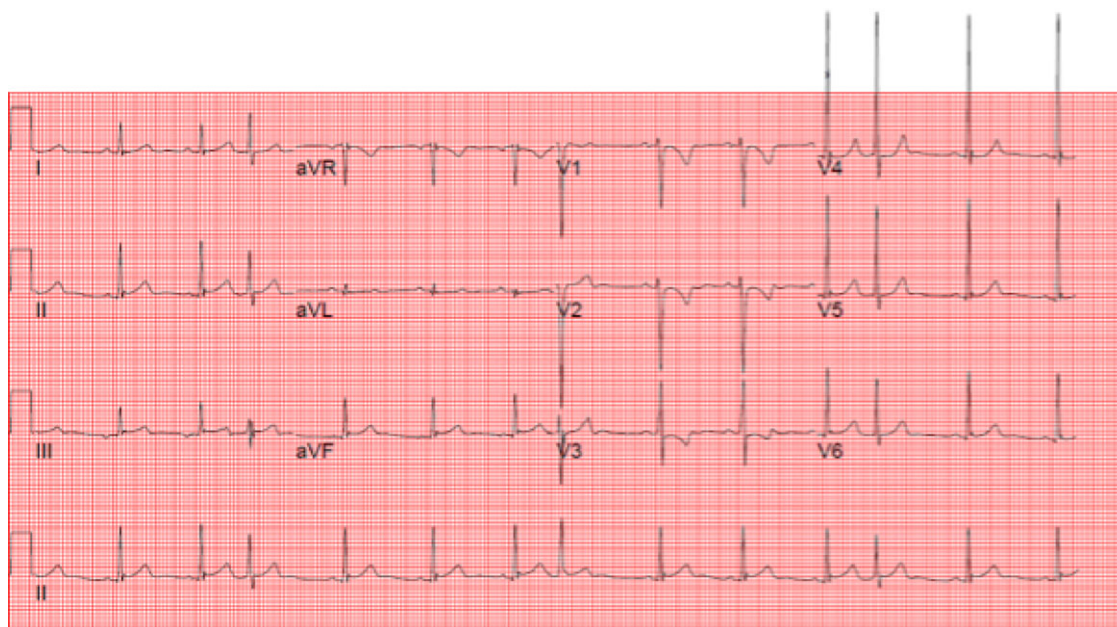
All triplets meet the Brighton Collaboration case definition for probable myocarditis<sup>7</sup>, noting that cardiac MRI is not routinely performed for myocarditis in children at this centre. They were referred to the hospital's specialist immunisation clinic for discussion regarding causality and guidance on future COVID-19 vaccines. The clinic's recommendation to the triplets was to avoid all further mRNA vaccines (notably this means Triplet 1 has only received a single COVID-19 vaccination as no alternative vaccine

is currently licensed for use in patients aged under eighteen). HLA typing and DNA for extract to store have been requested; pending at the time of writing.

### Discussion

This case series describes the first case of myopericarditis secondary to Pfizer vaccination occurring in triplets, which may suggest





**Figure 3.** Triplet 3 ECG showing normal sinus rhythm and atrial ectopic beats.

familial risk and a possible genetic association to the underlying pathophysiology.

Pfizer vaccine-associated myocarditis has been recognised as a rare complication, most commonly in adolescents and young adults following dose two, with a male predominance.<sup>3,4,5</sup> As of 2 January, 2022, the Australian Therapeutic Goods Association vaccine weekly data reported 415 cases of likely myocarditis, from approximately 27.3 million administered doses of Pfizer vaccine.<sup>4</sup> Both active and passive surveillance of adverse events following immunisation occurs in Australia, with public health notification mandatory in many jurisdictions, including where these cases occurred. In adolescent males (12–17 years), myocarditis occurred most commonly following the second dose at 12 cases per 100,000 Pfizer doses.<sup>4</sup> Recent review of the United States Vaccine Adverse Event Reporting System data reports myocarditis cases as highest after the second vaccination dose in adolescent males (70.7 per million doses of Pfizer for those 12–15 years and 105.9 per million for those 16–17 years).<sup>5</sup> The majority of cases are reported to be benign and self-limiting.

Paediatric myocarditis is most commonly caused by viral infections, including SARS-CoV-2, although uncommon aetiologies include toxins, drug hypersensitivity, and autoimmune disorders.<sup>8</sup> During the pandemic, the emergence of myopericarditis has been seen in the context of the multisystem inflammatory syndrome in children.<sup>9</sup> The pathogenesis of this may be explained by innate, adaptive, or auto-immune responses.<sup>8</sup> Although well recognised,<sup>9</sup> the mechanisms of post-vaccination myopericarditis are not fully understood. Proposed mechanisms include immune responses, molecular mimicry of autoantigens and spike proteins, and dysregulated cytokine expression and immune pathways.<sup>2</sup> Initial trials of mRNA vaccines generated a high immune response in the paediatric group which may mimic the multisystem inflammatory syndrome in children and associated myocarditis. Alternatively,

the mRNA vaccine may induce a non-specific innate inflammatory response or immune cross reactivity between the viral spike protein and cardiac protein.<sup>10</sup> Root-Berstein et al suggested that mRNA vaccines may precipitate cytokine activation of pre-existing autoreactive immune cells leading to an inflammatory state.<sup>11</sup> This process may contribute to the pathogenesis of myocarditis. Recent data suggest that the overall risk of myocarditis following SARS-CoV-2 infection is greater than the risk of Pfizer vaccine-associated myocarditis (35 compared with 2 excess myocarditis events per million people, respectively); however, this varies by age, gender, and dose number.<sup>12</sup>

Data regarding the risk of recurrence with subsequent COVID-19 vaccine doses are currently limited. The current advice in Australia is to defer further doses of mRNA vaccines; a similar approach has also been observed in other jurisdictions. Individual risk–benefit discussions should be conducted with patient and family. Further understanding of the potential familial risk may assist in these discussions.

A genetic link of myocarditis in the context of dilated cardiomyopathy has been hypothesised due to a familial aggregation, weak association with HLA-DR4, abnormal expression of HLA class II and adhesion molecules, and presence of autoantibodies.<sup>13</sup> Meder et al revealed a close association between chromosome 6p21 and susceptibility to inflammatory processes in dilated cardiomyopathy, which supports a genetic link.<sup>14</sup> Genetic susceptibility to myocarditis has also been proposed as arising from changes in myocardial structural proteins and/or genetically determined dysregulated immune responses.<sup>15,16</sup> This case series suggests genetic factors may play a role in the pathogenesis of vaccine-associated myopericarditis. Further observational and controlled studies are required to fully explore this assertion. The long-term impact of both COVID-19 and vaccine-associated myopericarditis requires further study.

**Table 1.** Characteristics of myopericarditis following COVID-19 vaccination in adolescent triplets.

Case	Triplet 1	Triplet 2	Triplet 3
<b>Demographics</b>			
<b>Age</b>	13	13	13
<b>Sex</b>	Male	Male	Male
<b>History of cardiac conditions</b>	None	None	None
<b>Presentation</b>			
<b>Symptoms after 1<sup>st</sup>/2<sup>nd</sup> vaccination</b>	First	Second	Second
<b>Time from vaccine to chest pain (days)</b>	3	4	5
<b>Time from vaccine to emergency presentation (days)</b>	4	4	5
<b>Symptoms</b>	Left-sided chest pain radiating down left arm, worse with movement.	Left-sided chest pain radiating down left arm, worse on lying flat. Diaphoresis.	Left-sided chest pain radiating to left shoulder and arm, worse on lying flat.
<b>Length of hospitalisation (days)</b>	3	3	2
<b>Blood tests (normal range)</b>			
<b>CRP level, mg/L (&lt; 5.0 mg/L)</b>	10	–	17
<b>ESR level, mm/h (&lt; 15 mm/h)</b>	13	–	17
<b>Troponin level at presentation, ng/L (&lt; 26 ng/L)</b>	587	2140	583
<b>Troponin level at peak, ng/L (&lt; 26 ng/L)</b>	2490	4530	583
<b>Imaging</b>			
<b>Electrocardiogram findings</b>	ST segment elevation	Normal sinus rhythm	Premature atrial complexes
<b>Chest X-ray findings</b>	–	Normal	Normal
<b>Echocardiogram findings – inpatient</b>	Normal cardiac structure and function. LV apex appears mildly dilated. Normal LV EDD z-score and basal dimension. Normal LV wall thickness. No evidence of pericardial effusion.	Normal cardiac dimensions, structure, and function, with no pericardial effusion	Normal cardiac dimensions, structure, and function, with no pericardial effusion
<b>Echocardiogram findings – outpatient follow-up (interval between studies)</b>	Normal left ventricular wall thickness, dimension, and function. No pericardial effusion. (1 week follow-up.)	Normal left ventricular size, wall thickness, and systolic function. No pericardial effusion, (3 week follow-up.)	Normal left ventricular wall thickness, dimension and function. (3 week follow-up.)
<b>Holter monitor findings</b>			Predominant sinus rhythm, with isolated periods of sinus arrhythmia, atrial ectopic beats (16% of total beats), and isolated occasional premature ventricular contractions, with no supraventricular tachycardia or ventricular tachycardia.

**Acknowledgements.** None.

**Author contributions.** All authors contributed to the conception of this work. Wong JW and Kee WS contributed to the acquisition of data. All authors critically appraised the work, contributing to the intellectual content and approved the final version prior to submission. All authors agree to be accountable for all aspects of the work in ensuring that questions related to the accuracy or integrity of any part of the work are appropriately investigated and resolved.

**Financial support.** This research received no specific grant from any funding agency, commercial, or not-for-profit sectors.

**Conflicts of interest.** None.

## References

- Olson SM, Newhams MM, Halasa NB, et al. Effectiveness of BNT162b2 vaccine against critical Covid-19 in adolescents. *New Engl J Med* 2022; 386: 713–723. DOI: [10.1056/NEJMoa2117995](https://doi.org/10.1056/NEJMoa2117995).
- Walter EB, Talaat KR, Sabharwal C, et al. Evaluation of the BNT162b2 Covid-19 vaccine in children 5 to 11 years of age. *New Engl J Med* 2022; 386: 35–46. DOI: [10.1056/NEJMoa2116298](https://doi.org/10.1056/NEJMoa2116298).

3. Bozkurt B, Kamat I, Hotez PJ. Myocarditis with COVID-19 mRNA vaccines. *Circulation* 2021; 144: 471–484. DOI: [10.1161/CIRCULATIONAHA.121.056135](https://doi.org/10.1161/CIRCULATIONAHA.121.056135).
4. COVID-19 Vaccine Weekly Safety Report 6 January 2022 [Internet]. Australian Government; c2022, [updated 2022; cited 2022 Feb 16]. Available from. <https://www.tga.gov.au/periodic/covid-19-vaccine-weekly-safety-report-06-01-2022>,
5. Oster ME, Shay DK, Su JR, et al. Myocarditis Cases Reported After mRNA-Based COVID-19 Vaccination in the US From December 2020 to August 2021. *JAMA* 2022; 2021: 331–340. DOI: [10.1001/jama.2021.24110](https://doi.org/10.1001/jama.2021.24110).
6. Moosmann J, Gentles T, Occlershaw C, Mitchelson B. COVID vaccine-associated myocarditis in adolescent siblings: does it run in the family? *Nato Adv Sci Inst Se* 2022; 10: 611. DOI: [10.3390/vaccines10040611](https://doi.org/10.3390/vaccines10040611).
7. Tejtel SK, Munoz FM, Al-Ammouri I, et al. Myocarditis and pericarditis: case definition and guidelines for data collection, analysis, and presentation of immunization safety data. *Vaccine* 2022; 40: 1499–1511. DOI: [10.1016/j.vaccine.2021.11.074](https://doi.org/10.1016/j.vaccine.2021.11.074).
8. Law YM, Lal AK, Chen S, et al. Diagnosis and management in myocarditis in children. A scientific statement from the American heart association. *Circulation* 2021; 144(6): e123–e135. DOI: [10.1161/CIR.0000000000001001](https://doi.org/10.1161/CIR.0000000000001001).
9. Su JR, McNeil MM, Welsh KJ, et al. Myopericarditis after vaccination, vaccine adverse event reporting system (VAERS), 1990-2018. *Vaccine* 2021; 39: 839–845. DOI: [10.1016/j.vaccine.2020.12.046](https://doi.org/10.1016/j.vaccine.2020.12.046).
10. Segal Y, Shoenfeld Y. Vaccine-induced autoimmunity: the role of molecular mimicry an immune cross-reaction. *Cell Mol Immunol* 2018; 15: 586–594. DOI: [10.1038/cmi.2017.151](https://doi.org/10.1038/cmi.2017.151).
11. Root-Berstein R, Fairweather D. Unresolved issues in theories of autoimmune disease varying myocarditis as a framework. *J Theor Biol* 2015; 375: 101–123. DOI: [10.1016/j.jtbi.2014.11.022](https://doi.org/10.1016/j.jtbi.2014.11.022).
12. Patone M, Mei XW, Handunnetthi L, Dixon S, et al. Risk of myocarditis after sequential doses of COVID-19 vaccine and SARS-CoV-2 infection by age and sex. *Circulation* 2022; 146: 743–754. DOI: [10.1161/CIRCULATIONAHA.122.059970](https://doi.org/10.1161/CIRCULATIONAHA.122.059970).
13. Caforio AL, Mahon NJ, Tona F, et al. Circulating cardiac autoantibodies in dilated cardiomyopathy and myocarditis: pathogenetic and clinical significance. *Eur J Heart Fail* 2002; 4: 411–417. DOI: [10.1016/s1388-9842\(02\)00010-7](https://doi.org/10.1016/s1388-9842(02)00010-7).
14. Meder B, Rühle F, Weis T, et al. A genome-wide association study identifies 6p21 as novel risk locus for dilated cardiomyopathy. *Eur Heart J* 2014; 35: 1069–1077. DOI: [10.1093/eurheartj/eh251](https://doi.org/10.1093/eurheartj/eh251).
15. Campuzano O, Fernández-Falgueras A, Sarquella-Brugada G, et al. A genetically vulnerable myocardium may predispose to myocarditis. *J. Am. Coll. Cardiol* 2015; 66: 2913–2914. DOI: [10.1016/j.jacc.2015.10.049](https://doi.org/10.1016/j.jacc.2015.10.049).
16. Baggio C, Gagno G, Porcari A, et al. Myocarditis: which role for genetics? *Curr. Cardiol. Rep* 2021; 23(6): 58. DOI: [10.1007/s11886-021-01492-5](https://doi.org/10.1007/s11886-021-01492-5).