



# Ductal stenting for retraining the left ventricle in patients with transposition of great arteries with intact ventricular septum: a single-centre experience

## Original Article

**Cite this article:** Banerji N, Parikh R, Parmar T, Champaneri B, Pota A, Pathak N, Mishra A, Gajjar T, Surti J, Gangwani A, and Patel K (2024) Ductal stenting for retraining the left ventricle in patients with transposition of great arteries with intact ventricular septum: a single-centre experience. *Cardiology in the Young* **34**: 2382–2387. doi: [10.1017/S1047951124025964](https://doi.org/10.1017/S1047951124025964)

Received: 27 July 2023

Revised: 17 May 2024

Accepted: 29 July 2024

First published online: 17 October 2024




### Keywords:

Arterial switch operation; ductal stenting; intact ventricular septum; transposition of the great arteries

### Corresponding author:

Bhavik Champaneri;

Email: [champaneribhavik7@unmicrc.org](mailto:champaneribhavik7@unmicrc.org)

Nayan Banerji<sup>1</sup>, Rujuta Parikh<sup>2</sup>, Tarun Parmar<sup>1</sup>, Bhavik Champaneri<sup>1</sup> , Abhay Pota<sup>1</sup> , Nihar Pathak<sup>2</sup>, Amit Mishra<sup>3</sup> , Trushar Gajjar<sup>3</sup>, Jigar Surti<sup>4</sup>, Amit Gangwani<sup>2</sup> and Krutika Patel<sup>5</sup>

<sup>1</sup>Department of Pediatric Cardiology, UN Mehta Institute of Cardiology and Research Centre, Ahmedabad, Gujarat, India; <sup>2</sup>Department of Cardiology, UN Mehta Institute of Cardiology and Research Centre, Ahmedabad, Gujarat, India; <sup>3</sup>Department of Cardio Vascular Thoracic Surgery, UN Mehta Institute of Cardiology and Research Centre, Ahmedabad, Gujarat, India; <sup>4</sup>Department of Cardiac Anaesthesia, UN Mehta Institute of Cardiology and Research Centre, Ahmedabad, Gujarat, India and <sup>5</sup>Department of Research, UN Mehta Institute of Cardiology and Research Centre, Ahmedabad, Gujarat, India

### Abstract

**Introduction** Ductal stenting in late presenters with transposition of great arteries with intact ventricular septum retrains the left ventricle before arterial switch operation. However, the experience is limited for its efficacy and safety. This study aims to highlight the efficacy and safety of ductal stenting for retraining the left ventricle. **Methods:** Eight children with transposition of great arteries-intact ventricular septum and regressed left ventricle underwent ductal stenting. Serial echocardiographic measurements of left ventricle shape, mass, volume, free wall thickness, and function were done, and arterial switch operation was performed once the left ventricle was adequately prepared. Post-operative outcome in terms of duration of mechanical ventilation, ICU stay, and improvement in left ventricle function were monitored. **Results:** The procedure was successful in all patients. Babies were divided into two groups on basis of age at ductal stenting (group 1 age less than 90 days and group 2 age more than 90 days) and were evaluated for the degree of left ventricle retraining as evidenced by echocardiographic parameters and post-operative variables. The left ventricle posterior wall thickness and mass index after ductal stenting increased significantly in both the groups. Postoperatively, one baby of group two expired after seven days due to severe left ventricle dysfunction. Rest babies had an uneventful post-operative ICU stay with no statistical difference in the duration of invasive mechanical ventilation or ICU stay. On six-month follow-up, all surviving babies were doing well with normal left ventricle function. **Conclusion:** Ductal stenting is a good alternative measure as compared to surgical procedures for left ventricle retraining in transposition of great arteries with regressed left ventricle.

### Introduction

Arterial switch operation is the preferred surgical option in children with transposition of the great arteries: with intact ventricular septum. The risk of arterial switch operation is increased in these subset of patients who present late due to the inability of the left ventricle to support the systemic afterload following surgery, and this significantly affects early survival. Conventionally, left ventricle regression is assumed after three weeks of age.<sup>1</sup> The ideal surgical options for patients presenting late with transposition of the great arteries with intact ventricular septum and regressed left ventricle is still unclear. Late primary switch, rapid two-stage switch<sup>2,3</sup> and atrial switch operations (e.g., Senning's/Mustard) are some of the options.

Transcatheter stenting of the patent ductus arteriosus has emerged as a nonsurgical alternative option to retrain the left ventricle in this subset of patients. This procedure has the advantage since it provides pressure and volume overload to the regressed left ventricle.<sup>4–6</sup> It is also less invasive, thereby making it an alternative option in comparison to the conventional surgical procedures like Pulmonary artery banding with Blalock-Taussig shunt.

We studied the efficacy and safety of ductal stenting in retraining of the regressed left ventricle in patients with transposition of the great arteries-intact ventricular septum. Herein, we describe our experience of eight patients who underwent ductal stenting followed by an arterial switch operation.

## Materials and methods

### Study setting

This was a single-centre, retrospective study in a tertiary referral centre in Western India investigating all consecutive patients with transposition of the great arteries-intact ventricular septum with regressed left ventricle who underwent ductal stenting for left ventricle retraining from January 2017 to June 2023.

Infants included in this study had presented beyond three weeks of age with a regressed left ventricle on the echocardiogram. Stenting of the ductus arteriosus was done for left ventricle retraining. Follow-up echocardiograms were done, and arterial switch operation was performed after left ventricle was prepared. Written informed consent was obtained from all patients and/ or relatives enrolled in the study. The study was approved by institutional ethics committee.

### Echocardiographic evaluation

All babies with transposition of the great arteries-intact ventricular septum were evaluated by transthoracic echocardiography before undergoing ductal stenting as well as before arterial switch operation to assess the degree of left ventricle retraining. Left ventricle indices which were taken into consideration included left ventricle end-diastolic diameter in the parasternal long-axis view, left ventricle end-diastolic dimensions and ejection fraction measured on M mode. The left ventricle posterior wall thickness was measured at end-diastole at the mid-cavity level. Left ventricle mass was derived using the dimensions obtained from the parasternal long-axis view in end diastole where left ventricle mass =  $0.8 [1.04 \times (\text{LVID} + \text{IVSd} + \text{PWd})^3 - \text{LVID}^3] + 0.6 \text{ g}$ , where LVID is the left ventricle internal diameter in diastole, IVSd is the interventricular septal thickness in diastole, PWd is the left ventricle posterior wall thickness in diastole,<sup>7</sup> 1.04 is the specific gravity of the myocardium, and 0.8 is the correction factor. Left ventricle mass was also indexed to body surface area using the Mosteller formula.<sup>8</sup>

The left ventricle geometry was subjectively classified as “satisfactory,” “D-shape,” and “ellipsoid” to describe the degree of regression of the left ventricle, based on the position of the interventricular septum in end systole (Figure 1).<sup>9</sup>

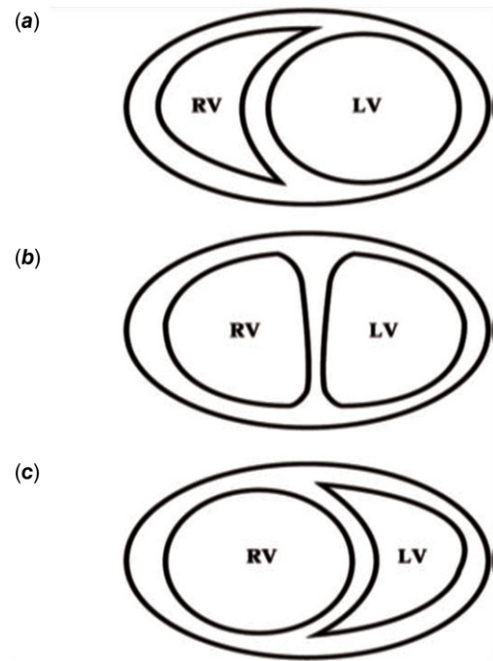
Patients were taken up for transcatheter stenting of the duct for retraining of the left ventricle if they fulfilled at least two of the following criteria: (1) an indexed left ventricle mass of less than  $35 \text{ g/m}^2$ , (2) left ventricle posterior wall thickness during diastole of less than 3.5 mm, or (3) an unfavourable left ventricle geometry.<sup>9</sup>

Left ventricle was considered retrained when it fulfilled the following criteria: (1) an indexed left ventricle mass greater than  $35 \text{ g/m}^2$ , (2) left ventricle posterior wall thickness during diastole of more than 3.5 mm, and (3) visually favourable left ventricle geometry.

The size of the atrial septal defect was also determined by echocardiography. The largest diameter of the atrial septal defect in all views was recorded.

### The procedure

Aspirin  $5 \text{ mg/kg}$  loading dose was given 12 hours prior to procedure. Transvenous controlled anaesthesia without mechanical ventilation was used in all the patients. A 5 Fr introducer short sheath was introduced into the femoral artery. Heparinization was done with single dose of 100 units/kg (keeping an activated clotting

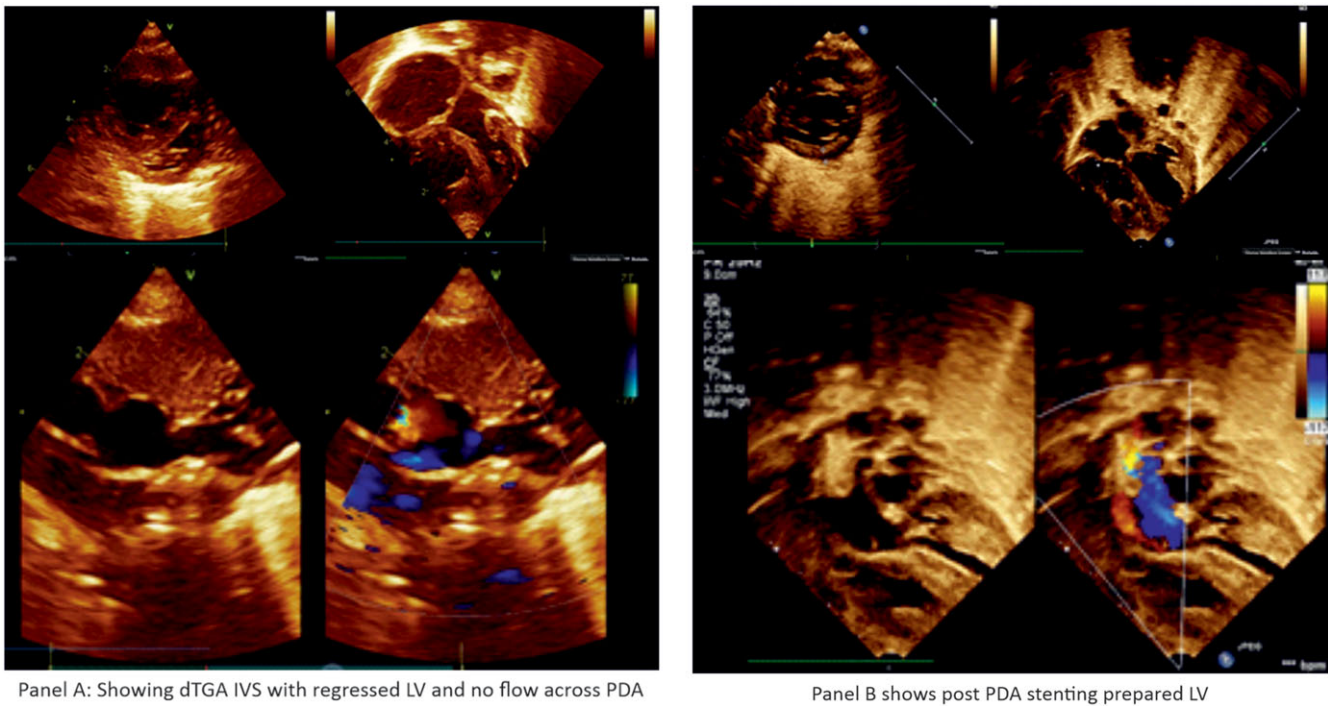


**Figure 1.** Left ventricular (LV) geometry was assessed on parasternal short-axis view and categorised according to deviation of the intraventricular septum (IVS) as (a) “satisfactory” if the IVS bulged to the right. (b) “D-shape” if the IVS was central. (c) “Ellipsoid” if the IVS bulged to the left (RV = right ventricle).

time  $>200 \text{ s}$ ). A check angiogram was performed as a roadmap to identify the position and the course of the patent ductus arteriosus. A 0.014-inch balance middleweight guidewire was advanced through a 5 Fr IMA guiding catheter (Medtronic, Inc.) and negotiated through the ductus arteriosus and parked deep in the main pulmonary artery. Repeat check angiograms were performed through the guiding catheter with the coronary wire straightening the PDA to assess the aortic and pulmonary ends of the duct, and measurements were made. A coronary stent (bare metal) with diameter of 4 mm (for babies  $<3.5 \text{ kg}$ ) or 4.5 mm (for babies  $>3.5 \text{ kg}$ ) with adequate length to cover the entire duct was deployed. An angiogram was performed to confirm the position of the stent as well as to profile the branch pulmonary arteries after stent placement and before removing the coronary wire. If there was no ductal patency, the ductal ampulla was probed with a 0.014-inch Pilot 50 guidewire to gain entry into the Pulmonary Artery through the ductus arteriosus, and then stenting of the duct was performed. Continuous heparin infusion of  $15\text{--}20 \text{ U/kg/hour}$  was started following the procedure for a duration of 24 hours. Aspirin  $5 \text{ mg/kg}$  once a day and Clopidogrel  $0.5 \text{ mg/kg}$  twice a day were continued till the left ventricle was prepared.

### Follow-up after patent ductus arteriosus stenting

The infants were monitored in the intensive care unit (ICU) for features of pulmonary overcirculation and heart failure for 48 hours after the procedure. Heparin infusion was continued for 24 hours, and aspirin ( $5 \text{ mg/kg/day}$ ) was started immediately after the procedure. Echocardiographic left ventricle assessment was repeated at 72-hour intervals. Once the left ventricle was found to be prepared by echocardiography, arterial switch operation was performed after discontinuing antiplatelet drugs (Figure 2).



**Figure 2.** Panel (a) dTGA IVS with regressed LV and no flow across PDA. Panel (b) post PDA stenting prepared LV.

### Arterial switch operation: surgical procedure and stent removal

Arterial switch operation was proceeded in usual fashion with transaction of the aorta and harvesting of coronary buttons. While the main pulmonary artery was being transacted, selective antegrade cerebral perfusion was maintained by clamping the aorta distal to the left subclavian artery with reduced flows. The ductal stent was removed, and the ductus was divided between ligatures. Cardiopulmonary bypass time and aortic cross clamp time were noted.

### Post-operative course

Each infant's course in the post-operative ICU was monitored for duration of mechanical ventilation, duration of intensive care unit stay, the need for extracorporeal life support, mortality, and serial echocardiographic assessment of left ventricle function.

### Statistical analysis

All statistical studies were carried out using SPSS v 26.0 (IBM® SPSS Statistics®, Chicago, IL, USA). Categorical data are described as number with frequency and continuous data as median with interquartile range or mean with standard deviation, as appropriate. Categorical data were compared using the chi-square test and Student's *t*-test; quantitative variables were compared using an analysis of variance. Group differences associated with a *p* value <0.05 were considered statistically significant.

### Results

There were eight consecutive babies who presented during a span of five years (January 2017 to June 2023) with a diagnosis of transposition of great arteries with intact interventricular septum

who presented late and had evidence of regressed left ventricle on echocardiogram. All these babies underwent ductal stenting for retraining the left ventricle. These babies were divided into two groups depending on the age at ductal stenting group 1 ( $n = 5$ ) – age less than 90 days and group 2 ( $n = 3$ ) – age more than 90 days and were evaluated for the degree of successful left ventricle retraining as evidenced by echocardiographic parameters as well as by the post-operative variables.

Table 1 shows the baseline characteristics of the two groups. Of the eight babies, six were male, and all of them had unrestrictive interatrial communication (mean size:  $6.5 \pm 1.9$  mm); hence, none of them needed balloon atrial septostomy. Baseline weight and length of the babies were fairly similar with no statistical difference. The mean age of ductal stenting in these patients was  $96.5 \pm 56.8$  days. There was a significant difference in the age of ductal stenting among the two groups ( $61 \pm 18.1$  days as compared to  $155.6 \pm 47$  days). There was an increase in oxygen saturation post ductal stenting as compared to baseline ( $89.2 \pm 3$  vs.  $74.6 \pm 7.3$  percent); however, there was no statistical significance among the two groups. The duration of retraining the left ventricle was also not statistically significant ( $11.6 \pm 3.2$  vs.  $22 \pm 19.4$  days) with a mean duration of  $15.5 \pm 12$  days, although the second group required longer duration to retrain. However, the age at arterial switch operation differed significantly among the two groups ( $72.6 \pm 17.5$  vs.  $177.6 \pm 58.6$  days). The mean cardiopulmonary bypass time ( $196.1$  minutes) and aortic cross clamp time ( $108.4$  minutes) were fairly similar between the two groups.

Post ductal stenting, all babies except one baby had uneventful course while waiting for arterial switch operation. One baby developed features of pulmonary oedema with respiratory distress on next day of procedure, for which he was mechanically ventilated and inotropic support was started. After eight days, left ventricle was retrained and underwent successful arterial switch operation on the 10<sup>th</sup> day of ductal stenting.

**Table 1.** Baseline characteristics of patients

Variables	Total <i>n</i> = 8 (% or mean ± SD)	Group 1 <i>n</i> = 5(% or mean ± SD)	Group 2 <i>n</i> = 3(% or mean ± SD)	P value
Male	6(75)	3(60)	3(100)	0.67
Female	2(25)	2(40)	0	
Size of ASD (mm)	5.6 ± 2.3	4.6 ± 1.8	7.3 ± 2.3	0.11
Age at ductal stenting (days)	96.5 ± 56.8 (43–190)	61 ± 18.1 (43–86)	155.6 ± 47.0 (102–190)	<b>0.006*</b>
Height at ductal stenting (cm)	48.3 ± 6.3	45.6 ± 5.8	52.6 ± 5.0	0.13
Weight at ductal stenting (kg)	3.9 ± 1.3	3.2 ± 0.2	5.0 ± 1.7	0.05
SpO <sub>2</sub> before stenting (%)	76.1 ± 6.2	74.6 ± 7.3	78.6 ± 3.0	0.41
SpO <sub>2</sub> after stenting (%)	89.8 ± 3.2	89.2 ± 3.0	90.6 ± 4.1	0.59
Duration of LV retraining (days)	15.5 ± 12 (7–44)	11.6 ± 3.2 (7–15)	22.0 ± 19.4 (7–44)	0.26
Age at ASO (days)	112.0 ± 64.1 (53–234)	72.6 ± 17.5 (53–93)	177.6 ± 58.6 (117–234)	<b>0.008*</b>
Weight at ASO (kg)	4.4 ± 1.4	3.6 ± 0.3	5.5 ± 1.6	<b>0.03*</b>
Duration of invasive ventilation (days)	7.13 ± 3.5	5.6 ± 2.6	9.6 ± 3.7	0.12
Duration of total ICU stay (days)	14.1 ± 6.1 (7–25)	13.2 ± 4.7 (7–19)	15.6 ± 9.0 (7–25)	0.63
Cardiopulmonary bypass time (mins)	196.1 ± 12.6	188.0 ± 6.5	202.3 ± 16.6	0.12
Cross clamp time (mins)	108.4 ± 10.2 (98–119)	109.8 ± 13.0 (98–128)	106.0 ± 3.0 (103–109)	0.65

ASD = atrial septal defect, ASO = Arterial switch operation, \**p* value <0.05 shows statistically significant.

**Table 2.** Comparison of echocardiographic parameters before and after ductal stenting

Variables	Total <i>n</i> = 8 (mean ± SD)		Group 1 <i>n</i> = 5 (mean ± SD)		Group 2 <i>n</i> = 3 (mean ± SD)		<i>p</i> value
	Pre	Post	Pre	Post	Pre	Post	
LVEF (%)	57.6 ± 3.5	58 ± 6.4	58.2 ± 2.1	59.6 ± 4.6	56.7 ± 5.8	55.3 ± 9.3	0.91
IVS (mm)	4.2 ± 0.3	4.6 ± 0.3	4.1 ± 0.2	4.5 ± 0.2	4.5 ± 0.4	4.8 ± 0.4	0.13
PWD (mm)	3.1 ± 0.4	4.4 ± 0.3	3.1 ± 0.4	4.24 ± 0.3	3.1 ± 0.4	4.6 ± 0.3	0.79
LV mass (g)	10.7 ± 0.9	15.3 ± 2.9	10.5 ± 0.9	15.7 ± 3.7	11.0 ± 1.2	14.6 ± 1.2	<b>0.04*</b>
LV mass index (g/m <sup>2</sup> )	19.2 ± 1.9	63.3 ± 22.8	19.7 ± 2.3	62.6 ± 29.7	25.8 ± 3.1	64.3 ± 7.8	<b>0.04*</b>

LVEF = left ventricle ejection fraction, IVS = interventricular septum, PWD = posterior wall diameter, LV = left ventricular, \**p* value <0.05 shows statistically significant.

Table 2 shows the change in echocardiographic variables pre and post ductal stenting, respectively, between the two groups. There was a statistically significant change in the left ventricle mass and index of the left ventricle after ductal stenting in both the groups.

Table 3 shows the comparison of hemodynamic parameters pre and post ductal stenting between the two groups. There was an increase in pulmonary arterial pressure post ductal stenting; however, it was not statistically significant. But there was a statistically significant reduction in the systolic aortic pressures following ductal stenting in both the groups.

At baseline, six had ellipsoid and two had D-shaped left ventricle geometry. Post ductal stenting before ASO, six had satisfactory and two had D-shaped left ventricle geometry. Post operatively, one baby from group one expired after seven days due to severe left ventricle dysfunction. Ductal stenting was done for that baby at the age of 190 days and required left ventricle retraining for 44 days. Arterial switch operation was done at 234 days, and the baby required extracorporeal life support for seven

days post operatively, but could not be weaned off extracorporeal life support and ultimately succumbed due to severe left ventricle dysfunction. However, the other babies had an uneventful post-operative ICU stay with no statistical difference in the duration of invasive mechanical ventilation (5.6 ± 2.6 vs. 9.6 ± 3.7 days) or total duration of ICU stay (13.2 ± 4.7 vs. 15.6 ± 9 days). Two babies developed moderate left ventricle dysfunction post arterial switch operation. They were managed conservatively with longer ventilatory support and medications and improved during ICU stay. All babies except one had favourable outcomes and were discharged post arterial switch operation in hemodynamically stable condition. On follow-up after six months, all surviving babies were doing well with normal left ventricle function.

## Discussion

The ideal management of a patient presenting with transposition of great arteries with intact ventricular septum beyond the initial few weeks of life is controversial because the risk of arterial switch

**Table 3.** Comparison of haemodynamic parameters pre and post ductal stenting

Variables	Total <i>n</i> = 8 (mean ± SD)		Group 1 <i>n</i> = 5 (mean ± SD)		Group 2 <i>n</i> = 3 (mean ± SD)		<i>p</i> value
	Pre	Post	Pre	Post	Pre	Post	
Systolic PA pressure	47.6 ± 8.9	61.3 ± 7.5	50.4 ± 9.1	64.0 ± 7.4	43.0 ± 7.5	56.7 ± 6.1	0.97
Diastolic PA pressure	24.5 ± 6.7	15.9 ± 6.4	17.8 ± 7.6	26.8 ± 7.8	12.7 ± 1.5	20.67 ± 1.2	0.52
Mean PA pressure	25.8 ± 7.6	34.5 ± 7.2	28.8 ± 8.2	37.2 ± 8.1	20.7 ± 2.1	30.0 ± 1.7	0.36
Aortic systolic pressure	101.9 ± 14.7	87.4 ± 12.3	96.6 ± 16.4	85.8 ± 14.6	110.7 ± 6.0	90.0 ± 9.2	<b>0.02*</b>
Aortic diastolic pressure	58.0 ± 14.2	43.5 ± 11.4	52.8 ± 14.9	38.2 ± 11.2	66.7 ± 9.0	52.3 ± 4.0	0.97
Aortic mean pressure	74.4 ± 13.6	57.1 ± 10.4	68.0 ± 13.3	54.2 ± 12.4	85.0 ± 5.3	62.0 ± 3.6	0.14

PA = pulmonary artery, \**p* value <0.05 shows statistically significant.

operation is significantly increased beyond three weeks of age due to regression of left ventricle.<sup>10,11</sup> Primary arterial switch operation with extracorporeal life support, left ventricle retraining, and atrial switch operations are some of the available alternatives.<sup>12–15</sup> Although primary arterial switch is possible in these babies who present late, post-operative morbidities like low cardiac output state, prolonged invasive and non-invasive ventilation, and the need for extracorporeal life support precludes it from being the standard treatment which can be adopted universally by all centres. The rapid two-stage arterial switch was thought to be an effective alternative solution to patients who presented late for surgery.<sup>16,17</sup> The time interval between the stages in rapid two-stage arterial switch operation is characterised by prolonged ventilatory support, severe acidosis, low cardiac output state, extended inotropic support, and prolonged duration of hospitalisation.<sup>4</sup> In many developing nations where diagnosis of congenital heart disease occurs fairly late and 95% of infants remain untreated, increased resource utilisation makes the two-stage approach less viable due to economic constraints.<sup>18</sup> Unfortunately, low- and middle-income countries often face the challenges in managing these late presenters due to limited resources in terms of funds, infrastructure, and manpower.

Ductal stenting provides pressure and volume overload to the left ventricle and thus appears to be a 'physiological' way for retraining the left ventricle. It was first described by Sivakumar et al and has been sparingly reported.<sup>19</sup> Our study extends the utility of the procedure and provide data in support of the procedure in late presenters with transposition of great arteries. In our study, although the pulmonary arterial pressure increased following ductal stenting, however, it was not found to be statistically significant. The adequacy of left ventricle for ASO has been conventionally judged by echocardiographic measurements of left ventricle mass index, left ventricle posterior wall thickness, and interventricular septal thickness in diastole as well as left ventricle geometry as described by Leong et al.<sup>9</sup> It avoids the distortion of branch PAs and would reduce the neo-aortic regurgitation seen with two-stage surgical retraining.<sup>2,3</sup> Further, an occluded patent ductus arteriosus in the early infancy might also be recanalised, as reported by Kothari et al.<sup>5</sup> The procedure was successful in all of our patients, and we did not encounter stent thrombosis as reported by Mumtaz et al<sup>20</sup> and Alwi et al.<sup>21</sup> It is important to recognise that large atrial septal defect might reduce the efficacy of the procedure since large atrial septal defect would reduce the left ventricle preload. An early left ventricle regression with large atrial septal defect has been documented previously.<sup>8</sup> The course of children with ductal stenting was reasonably smooth without

worsening of failure, needing intubation, or other clinical events. These patients were on continuous heparin infusion for 24 hours and aspirin following ductal stenting.

Thus, patent ductus arteriosus stent is a cost-effective procedure for left ventricle retraining that might obviate the need for extracorporeal life support in late presenters undergoing arterial switch operation and should be utilised more often.

#### Limitations

It was a single-centre retrospective observational study with relatively limited sample size. Also, the duration of retraining the left ventricle was not uniform in all the patients.

#### Conclusion

Ductal stenting is a safe and effective option for left ventricle retraining in late presenters with transposition of great arteries and intact ventricular septum. In the low- and middle-income countries that lack infrastructure for ventricular assist devices and extracorporeal membrane oxygenator support, ductal stenting to retrain the left ventricle followed by arterial switch operation could well be one of the preferred options in this subset of the patients.

**Supplementary material.** The supplementary material for this article can be found at <https://doi.org/10.1017/S1047951124025964>.

**Acknowledgement.** I thank Dr Shyam Sunder Kothari for guiding in the preparation of manuscript.

**Financial support.** The author(s) received no financial support for the research, authorship, and/or publication of this article.

**Competing interests.** The author(s) declared the following potential conflicts of interest with respect to the research, authorship, and/or publication of this article.

**Ethical standard.** The authors assert that all procedures contributing to this work comply with the ethical standards, and the study has been approved by the institutional committees (U. N. Mehta Institute of Cardiology and Research Centre).

#### References

- Nicholas TK, Blackstone EH, Doty DB, Hanley FL, Karp RB. Kirklín/Baratt-Boyes Cardiac Surgery. Churchill Livingstone, Philadelphia, 2003, pp. 1438–1507.

2. Kramer HH, Scheewe J, Fischer G, et al. Long term follow-up of left ventricular performance and size of the great arteries before and after one- and two-stage arterial switch operation of simple transposition, of left ventricular performance and size of the great arteries before and after one- and two-stage arterial switch operation of simple transposition. *Eur J Cardiothorac Surg* 2003; 24: 898–905.
3. Sharma R, Bhan A, Choudhary SK, et al. Ten-year experience with the arterial switch operation, experience with the arterial switch operation. *Indian Heart J* 2002; 54: 681–00.
4. Wernovsky G, Giglia TM, Jonas RA, Mone SM, Colan SD, Wessel DL. Course in the intensive care unit after preparatory pulmonary artery banding and aortopulmonary shunt placement for transposition of the great arteries with low left ventricular pressure. *Circulation* 1992; 86: 133–139.
5. Kothari SS, Ramakrishnan S, Senguttuvan NB, Gupta SK, Bisoi AK. Ductal recanalization and stenting of late presenters with TGA intact ventricular septum. *Ann Pediatr Cardiol* 2011; 4: 135–138.
6. Soo KW, Leong MC, Khalid F. Recanalisation of the closed ductus arteriosus in a critically ill infant with transposition of the great arteries. *Cardiol Young* 2016; 26: 371–374.
7. Lang RM, Badano LP, Mor-Avi V, et al. Recommendation for cardiac chamber quantification by echocardiography in adults: an update from the American Society of Echocardiography and the European Association of Cardiovascular Imaging. *Eur Heart J Cardiovasc Imaging* 2015; 16: 233–270.
8. Gopalakrishnan A, Sasidharan B, Krishnamoorthy KM, et al. Left ventricular regression after balloon atrial septostomy in d-transposition of the great arteries. *Eur J Cardiothorac Surg* 2016; 50: 1096–1101.
9. Leong MC, Ahmed Alhassan AA, Sivalingam S, Alwi M. Ductal stenting to retrain the involuted left ventricle in d-transposition of the great arteries. *Ann Thorac Surg* 2019; 108: 813–819.
10. Nicholas TK, Blackstone EH, Hanley FL, Kirklin JK. Complete transposition of the great arteries. In *Kirklin/Baratt-Boyes Cardiac Surgery*, 4th. Churchill Livingstone, Philadelphia, 2012: pp1855–1930.
11. Ma K, Hua Z, Yang K, et al. Arterial switch for transposed great vessels with intact ventricular septum beyond one month of age. *Ann Thorac Surg* 2014; 97: 189–195.
12. Bisoi AK, Ahmed T, Malankar DP, et al. Midterm outcome of primary arterial switch operation beyond six weeks of life in children with transposition of great arteries and intact ventricular septum. *World J Pediatr Congenit Heart Surg* 2014; 5: 219–225.
13. Kang N, de Leval MR, Elliott M, et al. Extending the boundaries of the primary arterial switch operation in patients with transposition of the great arteries and intact ventricular septum. *Circulation* 2004; 110: 123–127.
14. Nathan M. Late arterial switch operation for transposition with intact septum. *World J Pediatr Congenit Heart Surg* 2014; 5:226–228.
15. Cain MT, Cao I, Ghanayem YS, et al. Transposition of the great arteries—outcomes and time interval of early neonatal repair. *World J Pediatr Congenit Heart Surg* 2014; 5: 214–247.
16. Yacoub MH, Radley-Smith R, Maclaurin R. Two-stage operation for anatomical correction of transposition of the great arteries with intact interventricular septum. *Lancet* 1977; 1: 1275–1278.
17. Jonas RA, Giglia T, Sanders SP, et al. Rapid, two-stage arterial switch for transposition of the great arteries and intact ventricular septum beyond the neonatal period. *Circulation* 1989; 80: 203–208.
18. Iyer KS, Sharma R, Kumar K, et al. Serial echocardiography for decision making in rapid two-stage arterial switch operation. *Ann Thorac Surg* 1995; 60: 658–664.
19. Sivakumar K, Francis E, Krishnan P, et al. Ductal stenting retrains the left ventricle in transposition of great arteries with intact ventricular septum. *J Thorac Cardiovasc Surg* 2006; 132: 1081–1086.
20. Mumtaz ZA, Sivakumar K. Acute intraprocedural thrombosis during an arterial ductal stenting successfully managed by eptifibatide. *Cardiol Young* 2022; 32: 665–667.
21. Alwi M. Stenting the ductus arteriosus: case selection, technique and possible complications. *Ann Pediatr Cardiol* 2008; 1: 38–45.