

Research Article

Cite this article: de Paula FR, Picelli AM, Perles L, André MR, Viana LA (2022). A 50-year-old redescription: molecular and morphometric characterization of *Hepatozoon carinicauda* Pessôa and Cavalheiro, 1969 in the brown-banded water snake *Helicops angulatus* (Linnaeus, 1758). *Parasitology* **149**, 1468–1478. <https://doi.org/10.1017/S0031182022000919>

Received: 16 December 2021

Revised: 1 June 2022

Accepted: 22 June 2022

First published online: 3 August 2022

Key words:




Haemogregarines; molecular description; neotropical snakes; taxonomy; 18S rRNA

Author for correspondence:

Fabiane R. de Paula,

E-mail: fabianerp.ap@gmail.com

A 50-year-old redescription: molecular and morphometric characterization of *Hepatozoon carinicauda* Pessôa and Cavalheiro, 1969 in the brown-banded water snake *Helicops angulatus* (Linnaeus, 1758)

Fabiane R. de Paula^{1,2} , Amanda M. Picelli^{3,4} , Lívia Perles⁵, Marcos R. André⁵ and Lúcio A. Viana^{1,2} 

¹Programa de Pós-Graduação em Biodiversidade Tropical, Universidade Federal do Amapá (UNIFAP), Macapá, AP, Brazil; ²Laboratório de Estudos Morfofisiológicos e Parasitários, Departamento de Ciências Biológicas e da Saúde, UNIFAP, Macapá, AP, Brazil; ³Fundação Oswaldo Cruz – Fiocruz Rondônia, Porto Velho, RO, Brazil; ⁴Programa de Pós-Graduação em Biologia Experimental, Universidade Federal de Rondônia, Porto Velho, RO, Brazil and ⁵Laboratório de Imunoparasitologia, Departamento de Patologia, Reprodução e Saúde Única, Faculdade de Ciências Agrárias e Veterinárias, Universidade Estadual Paulista (FCAV/UNESP), Jaboticabal, SP, Brazil

Abstract

The combined use of molecular and microscopic techniques has become an increasingly common and efficient practice for the taxonomic and evolutionary understanding of single-celled parasites such as haemogregarines. Based on this integrative approach, we characterized *Hepatozoon* found in *Helicops angulatus* snakes from the Eastern Amazonia, Brazil. The gamonts observed caused cell hypertrophy and were extremely elongated and, in some cases, piriform (mean dimensions: $25.3 \pm 1.9 \times 8.6 \pm 1.3 \mu\text{m}$). These morphological features correspond to *Hepatozoon carinicauda*, described 50 years ago in the snake *Helicops carinicaudus* in the southeast region of Brazil. Phylogenetic and genetic divergence analyses, performed with the sequence obtained from the amplification of a 590 bp fragment of the 18S rRNA gene, revealed that *Hepatozoon* in *He. angulatus* differed from the other lineages retrieved from GenBank, and was clustered singly in both the phylogenetic tree and the haplotype network. The integration of these data allowed the identification of *H. carinicauda* in a new aquatic host, and increased the knowledge of its geographical distribution. Therefore, the present study included the first redescription of a *Hepatozoon* species in a snake from the Brazilian Amazon.

Introduction

Haemogregarines of the genus *Hepatozoon* Miller, 1908 (Apicomplexa, Hepatozoidae) comprise a ubiquitous group of intraerythrocytic parasites that are remarkably diverse among snakes (Smith, 1996; Úngari *et al.*, 2018). For many years, species nomination in this taxon was based on classical taxonomic methods, using morphological and morphometric data (Morrison, 2009). However, such features alone do not provide a robust diagnosis for single-celled organisms such as *Hepatozoon*, whose paucity of morphological traits make them especially prone to cryptic species (Perkins *et al.*, 2011; Zechmeisterová *et al.*, 2021). In this regard, the use of molecular markers, especially the 18S ribosomal nuclear gene (Hrazdilová *et al.*, 2021), was a decisive milestone for the taxonomy of these parasites, allowing access to genetic diversity and a better understanding of their phylogenetic relationships (Harris *et al.*, 2011; O'Dwyer *et al.*, 2013; Hrazdilová *et al.*, 2021).

Descriptions of *Hepatozoon* in snakes have been reported in literature for more than a century (Smith, 1996), yet genetic data for this group are restricted to the last 15 years (Sloboda *et al.*, 2007). In Brazil, even with the high taxonomic richness recorded (ca. 40 spp.) in snakes (Pessôa *et al.*, 1974; Smith, 1996; Úngari *et al.*, 2018, 2021), only the sequences of 5 species were available to date: *Hepatozoon cevapii* O'Dwyer *et al.*, 2013 reported in *Crotalus durissus* Linnaeus, 1758 (O'Dwyer *et al.*, 2013) and *Thamnodynastes lanei* Bailey *et al.*, 2005 (De Paula *et al.*, 2021); *Hepatozoon cuestensis* O'Dwyer *et al.*, 2013 and *Hepatozoon massardii* O'Dwyer *et al.*, 2013 described in *C. durissus* (O'Dwyer *et al.*, 2013; Úngari *et al.*, 2018); *Hepatozoon musa* Borges-Nojosa *et al.*, 2017 from *Philodryas nattereri* (Steindachner, 1870) (Borges-Nojosa *et al.*, 2017), *C. durissus* and *Epicrates crassus* Cope, 1862 (Úngari *et al.*, 2018); and *Hepatozoon quagliattus* Úngari *et al.*, 2021 in *Dipsas mikanii* (Schlegel, 1837) (Úngari *et al.*, 2021).

Helicops Wagler, 1830 (Colubridae, Dipsadinae) is a genus of neotropical snakes widely distributed in South America and comprises 19 described species, of which 15 can be found in Brazil, some of them are endemic to the country (Costa and Bérnils, 2018; Nogueira *et al.*, 2019; Schoneberg and Kohler, 2021). These snakes are strictly aquatic, with nocturnal habits, and feed mainly on fish and anurans (Aguilar and Di-Bernardo, 2004; Ávila *et al.*, 2006;

Carvalho *et al.*, 2017). They can be viviparous or oviparous, with the exception of *Helicops angulatus* (Linnaeus, 1758) that possesses both reproductive modes (Braz *et al.*, 2016). In terms of the occurrence of haemoparasites, 2 species of hepatozoids have been reported in these snakes (Pessôa and Cavalheiro, 1969a, 1969b): *Hepatozoon modesta* Pessôa and Cavalheiro, 1969 from *Helicops modestus* Gunther, 1861 and *Hepatozoon carinicauda* Pessôa and Cavalheiro, 1969 in *Helicops carinicaudus* (Wied-Neuwied, 1824).

Therefore, the present study aimed to investigate the presence of haemoparasites in the brown-banded water snake *He. angulatus*. As a result, through the use of an integrative taxonomy approach (morphology, morphometry and molecular data), *H. carinicauda*, a species named more than 50 years ago, was rediscovered and redescribed.

Materials and methods

Blood sampling and parasite morphological identification

Blood samples from 3 individuals of *He. angulatus* were collected via venepuncture of the tail (Sykes and Klaphake, 2008). The snakes were manually captured in 2 flooding areas in the municipal region of Macapá, in the state of Amapá, Brazil (0°01'04.29"S, 51°05'11.17"W; 0°00'40.7"N, 51°05'49.5"W) (Fig. 1). A portion of this blood was used to make blood smears, which were fixed with absolute methanol for 3 min and stained with Giemsa 10% for 30 min, while the rest of the sample was preserved in 96% ethanol (Hull and Camin, 1960; Telford *et al.*, 2001). The slides were examined under a light microscope at $\times 400$ and $\times 1000$ magnification and the parasite forms were recorded with a 5.1 MP digital camera attached to the biological microscope DI – 136T. The images and measurements of the parasites were processed using Image View® software. Morphometric characterization was given in micrometres (μm) and variables such as the length, width and area of the parasite and erythrocytes were presented as mean, range and standard deviation. Parasitaemia was estimated by counting the number of parasites visualized in 2000 erythrocytes, in 20 fields of 100 examined erythrocytes (Godfrey *et al.*, 1987).

DNA extraction, amplification and sequencing

Total DNA was extracted from a sample using the DNeasy Blood & Tissue Kit (QIAGEN, Valencia, CA, USA), according to the manufacturer's instructions. The detection of the parasite DNA by polymerase chain reaction (PCR) was performed using the Hep300 and Hep900 primers, which amplified a fragment of 590 base pairs (bp) of the 18S rRNA gene for sequencing and phylogenetic analysis (Ujvari *et al.*, 2004). The PCR consisted of a pre-PCR step at 94°C for 3 min, followed by 45 cycles of 94°C for 45 s, 1 cycle at 56°C for 1 min, an extension at 72°C for 40 s and a final extension at 72°C for 10 min. The amplicon was purified following the manufacturer's protocol using Wizard® SV Gel and the PCR Clean-Up System. PCR products were sequenced using the BigDye™ Terminator v.3.1 Cycle Sequencing Ready Reaction Kit (Applied Biosystems, Foster City, CA, USA) and the ABI 3100 Genetic Analyser (Applied Biosystems) (Sanger *et al.*, 1977).

Phylogenetic analyses

The amplified sequence was edited and the consensus sequence was built using the BioEdit software package, v7.2.5 (Hall, 1999). The identity, query coverage and E-values were assessed by the BLASTn tool (using default parameters), available in the NCBI GenBank database (Altschul *et al.*, 1990). The obtained sequence was aligned with other sequences retrieved from

GenBank using MAFFT software, version 7 (Katoh *et al.*, 2019). Sequences used for phylogenetic inferences were selected from the BLAST results and other studies performed in Brazil and other countries. First, the 'best of fit' model was selected by the IQ-TREE software package (Trifinopoulos *et al.*, 2016), under the Akaike information criterion (Darriba *et al.*, 2012). A Bayesian inference analysis was performed with MrBayes 3.1.2. (Ronquist and Huelsenbeck, 2003). Markov chain Monte Carlo simulations were run for 10^6 generations with a sampling frequency of every 100 generations and a burn-in of 25% using the CIPRES Science Gateway (Miller *et al.*, 2010). The number of generations was selected based on the value of the average standard deviation of split frequencies (<0.02 , MrBayes version 3.2 Manual) (Ronquist *et al.*, 2011). Maximum likelihood (ML) tree inference was performed with the IQ-TREE software package (Trifinopoulos *et al.*, 2016). Phylogenetic tree edition and rooting (outgroup) were performed using the Treegraph 2.0 beta software.

Genetic diversity of *Hepatozoon* spp.

Nineteen sequences retrieved from GenBank (MN833641, MF435047, MF435048, KX880079, MF497763, MF497764, MF497765, MF497766, MF497767, KC342524, MF497769, MF497770, KC342526, MW241134, MW241135, KC342525, MF322538, MF322539, MW591599) and aligned using the MAFFT software package (version 7) (Katoh *et al.*, 2019), resulting in an alignment of 461 bp, were used to evaluate the genetic diversity of the 18S rRNA gene from *Hepatozoon* spp. detected in the snake in the present study and in reptiles from previous studies in Brazil (O'Dwyer *et al.*, 2013; Borges-Nojosa *et al.*, 2017; Bouer *et al.*, 2017; Úngari *et al.*, 2018, 2021; Picelli *et al.*, 2020). Nucleotide diversity (π), haplotype diversity (H_d), number of haplotypes (h), total number of mutations (Eta) and average number of nucleotide differences (k), using DnaSP v5 software (Librado and Rozas, 2009), were calculated. Additionally, a haplotype network was constructed using Median Joining Network parameters (Bandelt *et al.*, 1999) using PopArt software (<http://popart.otago.ac.nz>). Finally, an even-distance matrix among sequences detected in reptiles in Brazil was estimated using the Mega-X software package version 10.1.8 (Kumar *et al.*, 2018).

Results

Microscopic analysis

All 3 *He. angulatus* snakes were positive for *Hepatozoon* parasites, with an average parasitaemia of 7/2000 erythrocytes in the blood (0.37%; ± 4.51), ranging from 3 to 12 parasites among the specimens. Gamonts (Fig. 2a–f) observed in the peripheral blood of the 3 snakes had extremely wide and elongated bodies, which induced deformities in the host cells, and had large eccentric nuclei. These characteristics agreed with *H. carinicauda*, a species previously described in the snake *He. carinicaudus* (Pessôa and Cavalheiro, 1969b). Details of the morphometric and morphological traits are shown in Table 1 and in the species redescription section below.

Molecular and phylogenetic analyses

The 18S rRNA sequence detected in *He. angulatus* exhibited 100% of query coverage, 98.47% of identity and 0.0 of E-value with *Hepatozoon* spp. detected in *Amblyomma fimbriatum* Koch, 1844 from *Varanus panoptes* Storr, 1980, sampled in Australia (EU430234; Vilcins *et al.*, 2009), and 98.14% of identity with *Hepatozoon ophisauri* (Tartakovskii, 1913) from Iran, detected in the lizard *Pseudopus apodus* (Pallas, 1775)

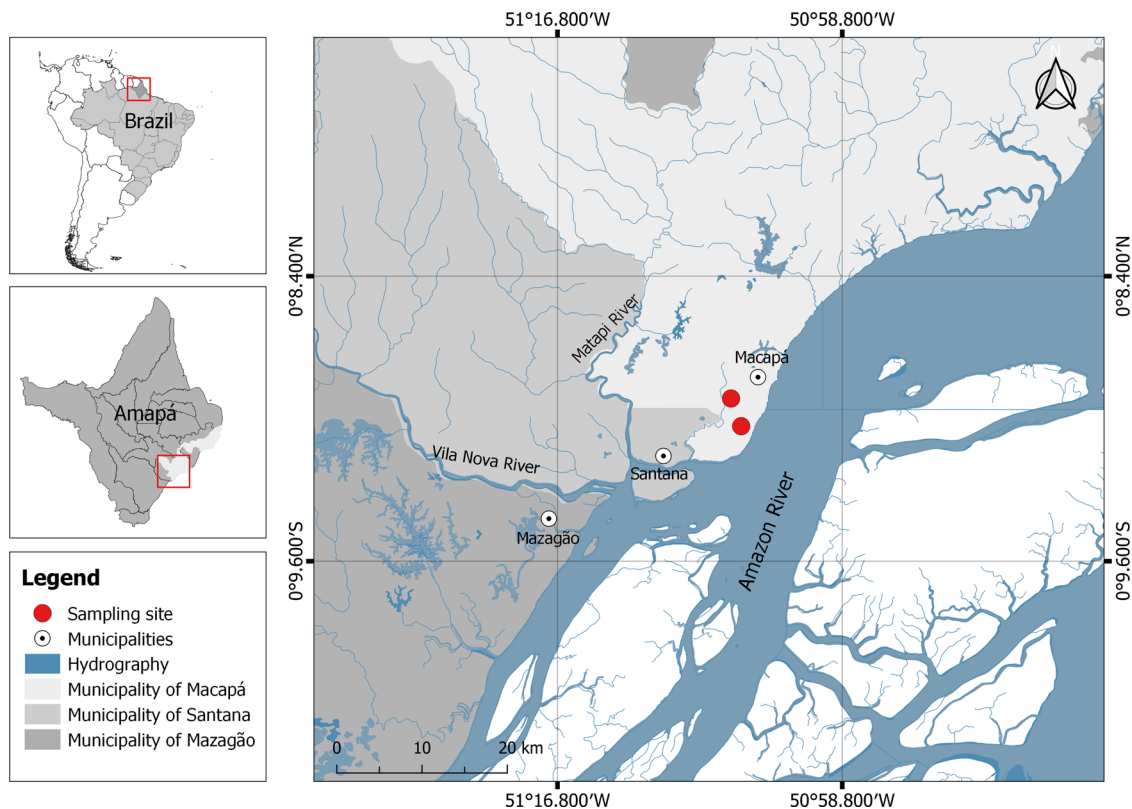


Fig. 1. Map of the study area, Macapá, Amapá, Brazil, containing the location of the analysed samples, indicated by red circles.

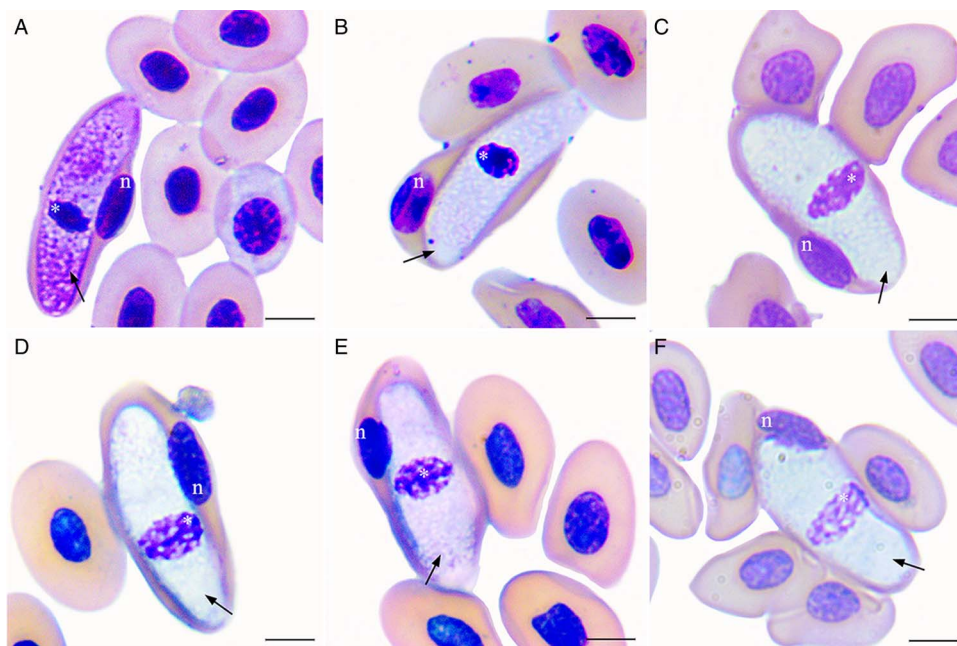


Fig. 2. Gamonts of *Hepatozoon carinicauda* infecting erythrocytes of the aquatic snakes *Helicops angulatus* from the Eastern Amazonia, Brazil (a–f). Arrows indicate parasites; asterisks (*) indicate gamont nuclei; and 'n' indicates host cell nucleus. Micrographs are from Giemsa-stained thin blood films. Scale bar = 10 μ m.

(MN723845; Zechmeisterová *et al.*, 2021). The sequence also exhibited 99% of query coverage, 98.63% of identity and 0.0 of E-value with *Hepatozoon* spp. detected in *Amblyomma varanense* (Supino, 1897) from the King cobra *Ophiophagus hannah* (Cantor, 1836) from Thailand (JQ670908; Sumrandee *et al.*, 2015).

Phylogenetic analysis of a 615 bp alignment using evolutionary model GTR (general-time reversible model) + F + I + G4 showed 87% bootstrap in the maximum likelihood (ML) tree (Fig. 3) and 91% posterior probability in the Bayesian tree

(Supplementary material). The topology of both trees was similar. The newly generated sequence formed a new branch, inserted into a large clade composed of *Hepatozoon* strains isolated from herpetofauna and mites from South America. Sequences previously detected in snakes (*H. cevapii*, *H. massardii*, *H. musa* and *H. cuestensis*) from Brazil were inserted (O'Dwyer *et al.*, 2013; Borges-Nojosa *et al.*, 2017), and *H. cevapii* and *H. massardii* were positioned in a different clade (Fig. 3). The sequences of *H. cuestensis* and *H. musa* shared the same ancestor with the

Table 1. Comparative morphometry of *Hepatozoon carinicauda* gamonts and their host cells between this study, Pessôa and Cavalheiro (1969b) and Telford (2009)

Snake host/study		<i>Helicops carinicauda</i> /Pessôa and Cavalheiro (1969b)	<i>Helicops carinicauda</i> /Telford (2009)
Characteristic	<i>Helicops angulatus</i> /this study		
<i>Hepatozoon carinicauda</i>			
Number of gamonts	48		
Length	25.32 ± 1.85 (21.54–29.41)	23–30	25–26
Width	8.62 ± 1.27 (6.84–11.79)	3–13	10–13
Area	174.14 ± 17.20 (144.33–227.99)		250–338
Nucleus length	5.23 ± 1.61 (3.33–12.04)	3–5	2.8–4.1
Nucleus width	6.89 ± 1.24 (4.54–9.77)		4.5–8.3
Nucleus area	30.21 ± 14.19 (14.95–84.4)		
Infected erythrocyte			
Number of infected erythrocytes	48		
Length	27.28 ± 1.98 (22.63–32.4)	30–35	
Width	11.81 ± 1.63 (8.97–16.05)		
Area	250.78 ± 34.21 (202.11–357.3)		
Nucleus length	8.33 ± 0.94 (6.25–10.2)		
Nucleus width	3.86 ± 1.04 (2.78–7.66)		
Nucleus area	24.59 ± 4.25 (18.68–36.58)		
Uninfected erythrocyte			
Number of uninfected erythrocytes	30		
Length	16.92 ± 0.94 (14.64–18.77)		
Width	10.54 ± 0.99 (8.85–12.07)		
Area	142.07 ± 15.21 (113.89–169.49)		
Nucleus length	6.91 ± 0.54 (5.99–7.87)		
Nucleus width	4.36 ± 0.38 (3.68–5.31)		
Nucleus area	24.61 ± 2.67 (19.32–31.8)		

Measurements are in micrometres and presented as mean ± standard deviation (s.d.) and/or intervals (minimum and maximum values).

sequence detected in the present study (Fig. 3). Furthermore, the sequences of *Hepatozoon* spp. (EU430234) and *H. ophisauri* (MN723845) that presented >98% of identity with our sequence were clustered in other clades.

The distance matrix showed that the divergence (*P* value) between the *Hepatozoon* 18S rRNA sequences obtained herein and in reptiles from previous studies carried out in Brazil varied from 1.86 to 6.5% (Table 2). The *Hepatozoon ameivae* (Carini and Rudolph, 1912) sequence obtained from the lizard *Ameiva ameiva* (Linnaeus, 1758) (Picelli *et al.*, 2020) was the closest, with a distance of 1.86% (Table 2). Among the *Hepatozoon* sequences obtained from snakes in Brazil, the closest were those from *H. musa*, which had a divergence from 1.88 to 2.2%, followed by *H. cuestasensis*, which had a divergence from 2.1 to 2.3%, *H. massardii*, with a distance of 2.5%, and *H. cevapii*, which had a divergence of distance ranging from 2.3 to 2.7% (Table 2). The sequences of *H. quagliattus* were the most distant of all, with a genetic distance from 6.2 to 6.7% (Table 2).

Genetic diversity

The analysis of nucleotide polymorphisms of the 18S rRNA sequences isolated in reptiles in Brazil revealed 10 different haplotypes (Fig. 4), with 54 variable sites, with haplotype diversity (Hd) = 0.9 and a nucleotide diversity (Pi) = 0.02724. As a result, most *Hepatozoon* species from Brazilian reptiles were represented by individual haplotypes, with the exception of the *Hepatozoon*

caimani (Carini, 1909) and *H. musa* species, both of which had 2 haplotypes. Nucleotide sequence genealogy shows that the sequence of *H. carinicauda* originated from median vectors, which represent hypothetical haplotypes generated by the software to connect the other haplotypes, but which were not contemplated in the present study. The comparison between *H. carinicauda* and its closest sequence, *H. ameivae*, demonstrates the presence of 3 median vectors with 10 mutational events between them. These results corroborate the phylogenetic tree, and 5 groups were found: (i) one comprising *H. cuestasensis*, *H. musa* and *H. ameivae*; (ii) another group composed of *H. carinicauda*; (iii) a third composed of *H. massardii* and *H. cevapii*; (iv) a fourth composed of *H. quagliattus*; and (v) a fifth composed of haplotypes of *H. caimani* (Fig. 4).

Phylogenetic position and genetic divergence showed that the novel sequence obtained in this study is a distinct species of *Hepatozoon*. Therefore, based on these data, the morphological and morphometric similarities, and the congeneric host (*Helicops*), we believe that the parasite found herein belongs to the previously described species *H. carinicauda*.

Species redescription

Taxonomic summary

Phylum: Apicomplexa Levine, 1970

Class: Coccidia Leuckart, 1879

Order: Eucoccidiorida Léger and Duboscq, 1910

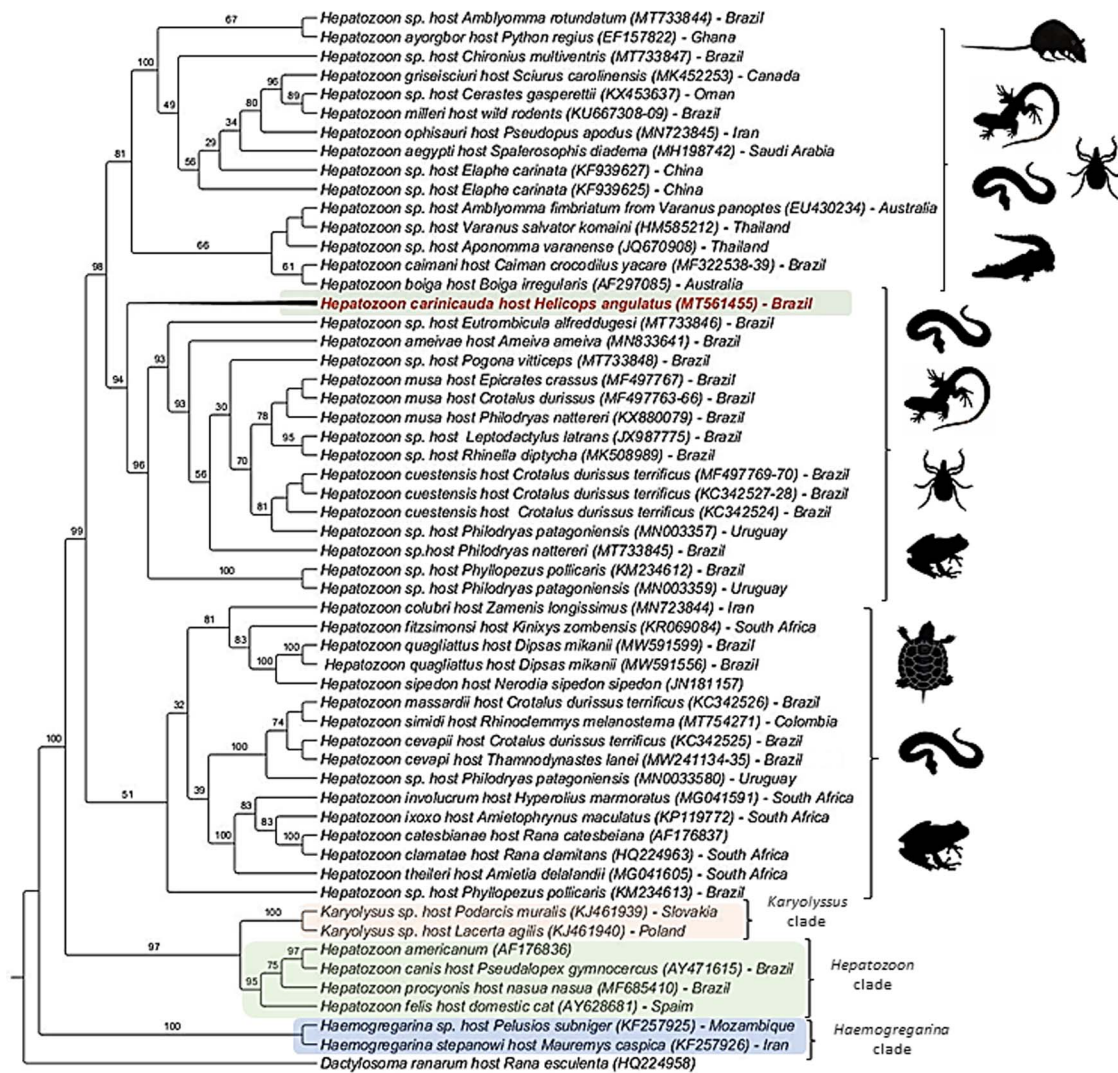


Fig. 3. Phylogenetic tree based on an alignment of 615 bp fragment of *Hepatozoon* spp. 18S rRNA sequences, using ML method and GTR evolutionary model. Numbers beside nodes correspond to bootstrap. Accession numbers are indicated in the sequences. The sequence of *Hepatozoon carinicauda* detected in the present study is highlighted in bold red.

Suborder: Adeleorina Léger, 1911

Family: Hepatozoidae Wenyon, 1926

Genus: *Hepatozoon* Miller, 1908

Hepatozoon carinicauda Pessôa and Cavalheiro, 1969

Type host: *Helicops carinicaudus* (Wied-Neuwied, 1824) (Serpentes: Colubridae), Wied's Keelback, Cobra-D'água-Preta.

Other hosts: *Helicops angulatus* (Linnaeus, 1758) (Serpentes: Colubridae), *Brown-banded water snake*, Cobra-D'água – current study.

Vector: Unknown.

Type locality: Votuporanga, São Paulo state, Brazil (Pessôa and Cavalheiro, 1969b).

Other localities: Urban flooding area (0°01'04.29"S, 51°05'11.17"W; 0°00'40.7"N, 51°05'49.5"W), municipal region of Macapá, state of Amapá, Brazil (present study).

Prevalence: One of *He. carinicaudus* (Pessôa and Cavalheiro, 1969b); and all 3 specimens of *He. angulatus* (this study).

Site of infection: Gamonts in blood erythrocytes (see Pessôa and Cavalheiro, 1969b; current study); meronts observed in liver, intestine and lungs (Pessôa and Cavalheiro, 1969b).

Parasitaemia (this study): Mean of 7 parasites/2000 blood erythrocytes (0.37%; ±4.51), ranging from 3 to 12 parasites.

Type material: Six blood slides (hapantotypes) from *He. angulatus* were deposited at the Institute for Scientific and

Technological Research of the State of Amapá (IEPA), Amapá, Brazil (no IEPA0001, IEPA0002, IEPA0003, IEPA0004, IEPA0005, IEPA0006).

DNA sequences: The 18S ribosomal gene sequence (590 bp) was deposited in GenBank® (accession number MT561455).

Redescription

This haemogregarine was described by Pessôa and Cavalheiro (1969b) in the colubrid snake *He. carinicaudus* from the southeast region of Brazil. In the original description, large gamonts were reported infecting erythrocytes and meronts, with an abundant number of merozoites in the liver, intestine and lung smears. Those authors also made an attempt at vectorial incrimination and recorded the development of sporulated oocysts in the body cavity of the leech *Haementeria lutzi* Pinto, 1920. In the present study, intraerythrocytic gamonts were the forms of *H. carinicauda* investigated in the peripheral blood of a new vertebrate host, the brown-banded water snake *He. angulatus* from the Eastern Amazonia, Brazil (Fig. 2a–f).

Diagnosis: Gamonts (Fig. 2a–f; Table 1) – extremely elongated, slightly curved and sometimes pyriform; both ends rounded; basophilic cytoplasm with granules; parasitophorous vacuole not evident. Wide and elliptical nucleus; eccentric and slightly oriented towards one end; position usually marked by the

Table 2. Divergence scores among the different *Hepatozoon* spp. detected in reptiles from Brazil

	1	2	3	4	5	6	7	8	9	10	11	12	13	14	15	16	17	18	19	20
1 <i>H. carinicauda</i> (MT561455)																				
2 <i>H. ameivae</i> (MN833641)	0.0186																			
3 <i>H. musa</i> (MF497763)	0.0198	0.0108																		
4 <i>H. musa</i> (MF497764)	0.0203	0.0111	0.0000																	
5 <i>H. musa</i> (MF497767)	0.0200	0.0109	0.0000	0.0000																
6 <i>H. musa</i> (MF497765)	0.0196	0.0107	0.0000	0.0000	0.0000															
7 <i>H. musa</i> (MF497766)	0.0188	0.0113	0.0000	0.0000	0.0000	0.0000														
8 <i>H. cuestensis</i> (MF497769)	0.0230	0.0142	0.0073	0.0075	0.0073	0.0072	0.0056													
9 <i>H. cuestensis</i> (MF497770)	0.0236	0.0145	0.0074	0.0075	0.0074	0.0073	0.0056	0.0000												
10 <i>H. cuestensis</i> (KC342524)	0.0217	0.0138	0.0062	0.0063	0.0062	0.0061	0.0061	0.0000	0.0000											
11 <i>H. caimani</i> (MF435048)	0.0204	0.0255	0.0234	0.0240	0.0236	0.0232	0.0245	0.0266	0.0273	0.0277										
12 <i>H. musa</i> (KX880079)	0.0220	0.0128	0.0019	0.0019	0.0019	0.0019	0.0020	0.0096	0.097	0.0087	0.0257									
13 <i>H. massardii</i> (KC342526)	0.0257	0.0316	0.0331	0.0337	0.0330	0.0323	0.0325	0.0298	0.0303	0.0296	0.0297	0.0369								
14 <i>H. cevapii</i> (KC342525)	0.0237	0.0296	0.0310	0.0316	0.0309	0.0303	0.0305	0.0278	0.0283	0.0277	0.0277	0.0347	0.0020							
15 <i>H. cevapii</i> (MW241134)	0.0272	0.0306	0.0324	0.0333	0.0327	0.0321	0.0320	0.0319	0.0327	0.0277	0.0290	0.0350	0.0020	0.0000						
16 <i>H. cevapii</i> (MW241135)	0.0271	0.0305	0.0324	0.0333	0.0327	0.0321	0.0320	0.0319	0.0327	0.0277	0.0289	0.0349	0.0020	0.0000	0.0000					
17 <i>H. caimani</i> (MF322538)	0.0288	0.0342	0.0309	0.0296	0.0290	0.0288	0.0246	0.0273	0.0276	0.0286	0.0072	0.0341	0.0307	0.0286	0.0378	0.0378				
18 <i>H. caimani</i> (MF435047)	0.0347	0.0347	0.0360	0.0370	0.0364	0.0357	0.0321	0.0392	0.0401	0.0360	0.0225	0.0390	0.0400	0.0380	0.0399	0.0399	0.0306			
19 <i>H. quagliattus</i> (MW591599)	0.0627	0.0610	0.0629	0.0647	0.0635	0.0642	0.0678	0.0674	0.0691	0.0632	0.0628	0.0661	0.0692	0.0672	0.0646	0.0644	0.0719	0.0745		
20 <i>H. quagliattus</i> (MW591556)	0.0654	0.0636	0.0643	0.0654	0.0642	0.0649	0.0678	0.0675	0.0691	0.0632	0.0655	0.0691	0.0692	0.0672	0.0671	0.0671	0.0656	0.0768	0.0000	

The pairwise distance matrix was estimated using the Mega-X software version 10.1.8.

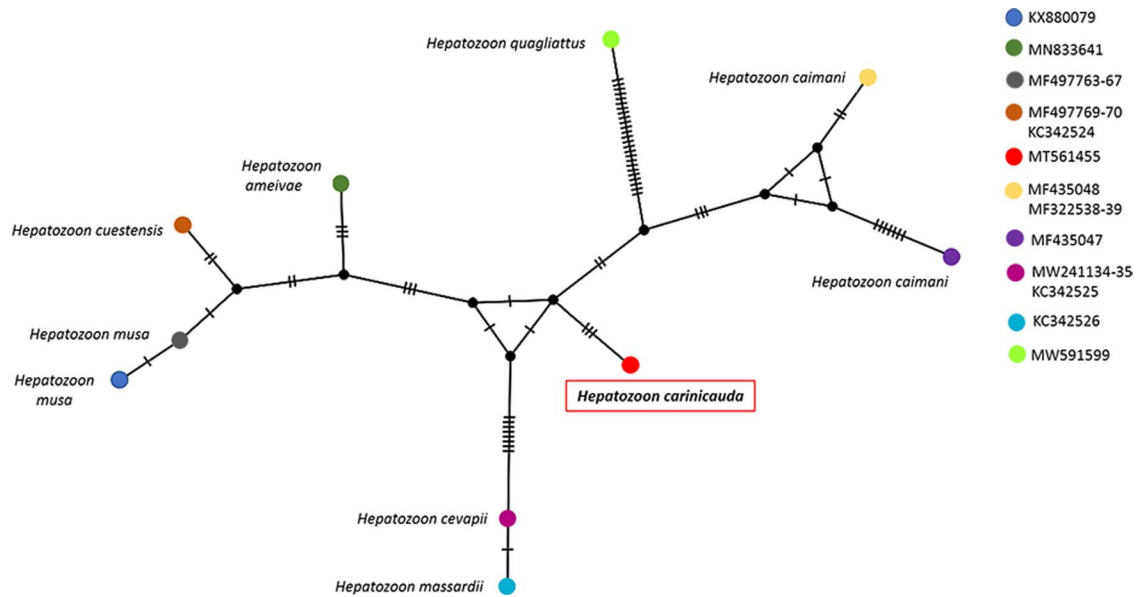


Fig. 4. Median Joining Network of 18S rRNA *Hepatozoon* sequences (461 bp) detected in snakes from Brazil in the present study and in previous studies. While the lines between haplotypes represent mutational steps, the black circles indicate median vectors (hypothetical haplotypes generated by the software to connect all the haplotypes).

enlargement of the body of the parasite; with condensed dark-stained chromatin filaments or more dispersed chromatin. Body dimensions: $25.3 \pm 1.9 \times 8.6 \pm 1.3 \mu\text{m}$; and area $174.1 \pm 17.2 \mu\text{m}^2$. Nucleus dimensions: $5.2 \pm 1.6 \times 6.9 \pm 1.2 \mu\text{m}$; and area $30.2 \pm 14.1 \mu\text{m}^2$. The cytopathological effects caused by parasites on their host cells were remarkable when compared with non-parasitized erythrocytes. The infected erythrocytes were hypertrophied ($27.3 \pm 2.0 \mu\text{m}$ vs $16.9 \pm 0.9 \mu\text{m}$) with gamonts occupying almost the entire area ($250.8 \pm 34.2 \mu\text{m}^2$) of these cells. The parasitized erythrocyte nucleus was flattened and displaced laterally to the host cell margin [$8.3 \pm 0.9 \times 3.9 \pm 1.0 \mu\text{m}$ vs $6.9 \pm 0.5 \times 4.4 \pm 0.4 \mu\text{m}$ (Table 1)], which was generally irregular (Fig. 2e–f).

Remarks: *Hepatozoon carinicauda* gamonts observed in the blood of *He. angulatus* were slightly smaller than those described in the type host, *He. carinicaudus* (Pessôa and Cavalheiro, 1969b) ($29.4\text{--}21.5 \times 11.8\text{--}6.8 \mu\text{m}$ vs $30\text{--}23 \times 13\text{--}5 \mu\text{m}$, respectively). When compared to *H. modesta* (Pessôa and Cavalheiro, 1969a), another species described in *Helicops* snakes, *H. carinicauda* is larger ($15\text{--}13 \times 3\text{--}2 \mu\text{m}$ vs $29.4\text{--}21.5 \times 11.8\text{--}6.8 \mu\text{m}$, respectively). Moreover, unlike *H. carinicauda*, there is nothing unique about the morphology of *H. modesta*, and it is considered a ‘hepatozoic’ type – a former term used for parasites that did not deform or displace the host cell nucleus (Pessôa and Cavalheiro, 1969a). Morphometric and morphological differences can also be found among *H. carinicauda* and phylogenetically close haemogregarine species infecting lizards and snakes, such as *H. ameivae*, *H. cuestensis* and *H. musa*. Gamonts of *H. ameivae*, in addition to being smaller ($14.28 \times 4.50 \mu\text{m}$), possess the outstanding feature of overlapping the host cell nucleus (Picelli et al., 2020), a trait not observed in *H. carinicauda*. *Hepatozoon cuestensis* forms have arched ends, uniform cytoplasm and are smaller in size ($17.07 \times 3.6 \mu\text{m}$) (O’Dwyer et al., 2013). Finally, *H. musa* has both curved ends and bodies which, although elongated ($18.9 \times 3.8 \mu\text{m}$), are smaller than *H. carinicauda* (Borges-Nojosa et al., 2017).

Discussion

Taken together, our genetic, morphological and morphometric data allowed us to redescribe *H. carinicauda* in a new snake host, *He. angulatus*, and to place this parasite species in a current

phylogenetic context. This was mainly possible because *H. carinicauda* has very distinct and unique morphological and morphometric characteristics (i.e. large dimensions that considerably deform the erythrocytes). Other studies that employed integrative taxonomy started from the same assumption, such as *H. ameivae* in the lizard *A. ameiva*, whose gamonts overlap the host cell nucleus (Picelli et al., 2020), and the redescription of *H. ophisauri* in the lizard *P. apodus*, which has unusual pink inclusions, and *Hepatozoon colubri* (Borner, 1901) in the snake *Zamenis longissimus* (Laurenti, 1768), which presents a degeneration zone in the cytoplasm, and connection to the nucleus of the host cell (Zechmeisterová et al., 2021).

Hepatozoon carinicauda was first observed 52 years ago infecting another *Helicops* snake, the Wied’s Keelback *He. carinicaudus*. This host species and *He. angulatus* shared the main ecological features associated with this snake genus, namely inhabiting freshwater environments, having nocturnal habits and feeding mainly on fish and frogs (Aguiar and Di-Bernardo, 2004; Ávila et al., 2006; Carvalho et al., 2017). Nevertheless, in addition to having specific differentiations, these species exhibit distinct geographic distribution patterns. Although there are no data on the sympatric occurrence of these host species, the distribution of both species suggests an area of sympatry in the state of Bahia, northeast of Brazil (Freitas, 2003; Costa and Bérnils, 2018). In fact, studies have shown that *He. carinicaudus* is endemic to the coastal Atlantic Forest at low elevations, restricted to the southeast and south regions of the country (Yuki and Lema, 2005; Nogueira et al., 2019). In contrast, *He. angulatus* represents a cryptic species complex, which is most widespread in northern South America (Nogueira et al., 2019; Murphy et al., 2020), with records in the Brazilian biomes of the Amazonia, the Chiquitano dry forest, the Cerrado, the Caatinga and the northern portion of the Atlantic Forest (Nogueira et al., 2019; Murphy et al., 2020). Generally, the sharing of parasites by different host species can be explained by the understanding that there is a low specificity to the vertebrate host among the haemogregarines (Maia et al., 2012; De Paula et al., 2021). However, we cannot fully assume that this is the case here, due to the evolutionary and ecological history of the hosts. The presence of *H. carinicauda* in these snakes would be through a vector and/or an intermediate host

related to both, given the similarity of the ecological niche they use (Poulin and Morand, 2004; Morand, 2015). It is also noteworthy that since these snakes are congeneric hosts, the parasite may have been inherited by these species through a common ancestor during the speciation process (Poulin and Morand, 2004; Hay *et al.*, 2020). In this sense, it would be useful to investigate other *Helicops* species, as well as other aquatic snake taxa, to test these hypotheses.

With respect to morphological aspects, we observed that *H. carinicauda* gamonts found in *He. angulatus*, although slightly smaller, remain within the dimensions of the species (Pessôa and Cavalheiro, 1969b). In the original description, Pessôa and Cavalheiro (1969b) measured gamonts twice, with an interval of 1 month between each measurement, and noticed an increase in the size of the parasitic forms. Nonetheless, Telford (2009) calculated the measurements of *H. carinicauda* from the original description photos, finding that larger parasites, identified during the second smear examination, had smaller dimensions ($26\text{--}25 \times 13\text{--}10\ \mu\text{m}$) than those presented by Pessôa and Cavalheiro (1969b). Despite the fact that both measures were consistent with one another, the author concluded that the original measurements of *H. carinicauda* were unsuitable. In fact, as in other older haemoprotozoan descriptions, not all the traits in *H. carinicauda* and the host cells were evaluated, with some discrepancies between the first and second measurements (Pessôa and Cavalheiro, 1969b). For example, the parasite nuclei were considered in the first analysis only, whereas the infected erythrocytes were assessed in the second examination only, where just length was recorded. Therefore, we believe that these methodological inconsistencies are likely to have led to the morphological differences between our study and that of Pessôa and Cavalheiro (1969b).

To our knowledge, this is the first molecular characterization of a haemogregarine species isolated from a *Helicops* snake. It should be noted that *Hepatozoon* spp. DNA was recently detected in a tick (*Amblyomma rotundatum* Koch, 1844) collected from a *He. carinicaudus* snake (Fonseca *et al.*, 2020). However, in this study, infection in snakes was not confirmed, and so it was not clear whether the tick acts as a vector of *Hepatozoon* for this aquatic snake host. Furthermore, as the authors did not perform morphological characterization or molecular sequencing, it was not possible to compare this parasite with *H. carinicauda* found herein. Furthermore, it is important to emphasize that available molecular data for *Hepatozoon* infecting snakes remain scarce in all countries within the Amazonian domain. So far, there has been only 1 molecular characterization in the entire region, *H. cevapii* in *T. lanei* (De Paula *et al.*, 2021), a parasite previously described in *C. durissus* in the southeast of Brazil (O'Dwyer *et al.*, 2013).

The 18S rRNA nuclear marker is very popular, and it is used almost exclusively, in phylogenetic analyses of haemogregarines (Hrazdilová *et al.*, 2021). It has proven useful for molecular screening of *Hepatozoon* and species descriptions in snakes (O'Dwyer *et al.*, 2013; Borges-Nojosa *et al.*, 2017; Ūngari *et al.*, 2018, 2021), including in our study. Yet, in recent years the need for the improvement and employment of other genetic markers capable of responding more clearly to the phylogenetic relationships of the group has been discussed (Abdel-Baki *et al.*, 2014; Maia *et al.*, 2016; Cook *et al.*, 2018; Guti rrez-Liberato *et al.*, 2021; Hrazdilov  *et al.*, 2021). In the recent differentiation of *Hepatozoon catesbiana*e (Stebbins, 1903), *Hepatozoon clamatae* (Stebbins, 1905) and a third *Hepatozoon* genotype infecting frogs, the 18S rRNA marker identified low molecular divergence, and was found to be inadequate for the differentiation of these species (L veill  *et al.*, 2021). Hrazdilov  *et al.* (2021) argue that the solution to the taxonomic puzzle of historical roots requires combinations of nuclear and mitochondrial markers. This

approach may resolve deeper issues permeating the phylogenetic position of *Hepatozoon* lineages *vis- -vis* other haemogregarines, such as the problematic proposal of a new genus ('*Bartazoon*') for hepatozoids of non-carnivorous vertebrates (reptiles, amphibians, bats, rodents and marsupials) (Karadjian *et al.*, 2015; Maia *et al.*, 2016; Hrazdilov  *et al.*, 2021). In the present work, there were attempts to analyse long fragments of the 18S gene of *H. carinicauda*, which could contribute to a more robust database. However, the stored genetic material samples degrade, making DNA extraction and subsequent sequencing impossible.

Overall, the phylogeny recovered in our study maintained the known paraphyletic pattern for *Hepatozoon* (Maia *et al.*, 2012; Karadjian *et al.*, 2015), where sequences obtained from amphibians, reptiles, rodents and mites tend to fall within the same major clade (Zechmeisterov  *et al.*, 2021). In this respect, most likely due to the amount of sequences analysed here, our phylogeny reveals clearer relationships with regard to the positioning of *Hepatozoon* lineages in the herpetofauna, resulting in 3 well-structured clades. Furthermore, the phylogenetic relationships in our study were quite similar to those obtained by Ūngari *et al.* (2021) and Zechmeisterov  *et al.* (2021), but diverged from the positioning of some lineages in the study by Guti rrez-Liberato *et al.* (2021). In this case, our phylogenetic tree reveals that *Hepatozoon simidi* Guti rrez-Liberato *et al.*, 2021 is most closely related to *H. massardii* and *H. cevapii*, 2 sequences that were absent in the analyses performed by Guti rrez-Liberato *et al.* (2021).

In terms of the phylogenetic positioning of *H. carinicauda*, this new lineage appears as a sister taxon to a clade composed of *Hepatozoon* sequences from anurans, lizards, snakes and a trombiculid mite, from different locations in South America. Interestingly, *H. carinicauda* was placed as isolated and distant from the other sequences obtained in aquatic hosts. *Hepatozoon sipedon* Smith *et al.*, 1994 from the aquatic snake, *Nerodia sipedon* (Linnaeus, 1758) (JN181157; Barta *et al.*, 2012), and *H. simidi* from the Colombian wood turtle, *Rhinoclemmys melanosterna* (Gray, 1861) (MT754271; Guti rrez-Liberato *et al.*, 2021) possess closer proximity and are inserted into a large clade. Haplotypes of *H. caimani* (MF435048–MF322539; Bouer *et al.*, 2017) from caimans are clustered in another clade, distantly related to other aquatic haemogregarine lineages, including *H. carinicauda*. Therefore, *Hepatozoon* lineages isolated from hosts associated with aquatic environments are paraphyletic, with at least 3 evolutionary origins.

It is assumed that for *Hepatozoon*, as for many other groups of heteroxenous parasites (Vot pka *et al.*, 2017), evolutionary history can be better told through vectors (Barta *et al.*, 2012), and that the unique position of *H. carinicauda* in the phylogeny may reflect this relationship. Unfortunately, the vectors of *H. carinicauda* are still to be confirmed. Pess a and Cavalheiro (1969b) carried out an experimental transmission of *H. carinicauda* to *H. lutzi* leeches, by haematophagy on an infected *He. carinicaudus* snake, and observed the formation of sporulated oocysts after 40 days. However, as the authors did not provide information about whether snakes and/or possible paratenic hosts were fed leeches containing developed oocysts, and were later examined for infection, it cannot be concluded whether these invertebrates are vectors or not. Furthermore, there is no proof to date that leeches are involved in the transmission of *Hepatozoon* (Telford, 2009). Indeed, in aquatic vertebrates, the recognized vectors for these haemoparasites are mosquitoes, such as: *Culex pipiens* Linnaeus, 1758 and *Culex territans* Walker, 1856 which can transmit *H. sipedon* to *Lithobates pipiens* (Schreber, 1782), a paratenic host subsequently preyed upon by *N. sipedon* (Smith *et al.*, 1994); *Culex fatigans* Wiedemann, 1828, in which the complete sporogony of *H. caimani* was observed after haematophagy in infected caimans (Lainson *et al.*, 2003); and *Culex* mosquitoes belonging

to the subgenus *Melanoconion*, mainly *Culex theobaldi* (Lutz, 1904), have also been reported as natural vectors for *H. caimani* (Viana et al., 2010). We therefore emphasize the importance of conducting studies with vectors, especially in the natural environment, to explore the relationships that may exist between *Hepatozoon* from terrestrial and aquatic hosts, as well as to elucidate the life cycles of these parasites, a research field that remains underexplored.

The evolutionary relationships obtained from the phylogenetic tree and haplotype network were similar. The trend of isolation of *H. carinicauda* is repeated and the haplotypes from reptiles remain evenly distributed, as they are in the clades of the phylogenetic tree, an organization pattern already observed in haplotypes of distinct *Hepatozoon* species, such as the wild cat *Felis silvestris* (Schreber, 1775) and domestic cats from South Africa (Hodzic et al., 2017; Harris et al., 2019). In the network, the *H. carinicauda* haplotype is located in a central position, which suggests that it is an ancestral haplotype, in comparison with more external haplotypes which represent species that have diverged more recently (Flanley et al., 2018). However, as the relationships in the network have only recently been studied, they can be unstable and can change as more sequences are incorporated. Furthermore, many mutational events are visualized throughout the network, enabling the visualization of 5 haplogroups. The presence of median vectors indicate that these are *Hepatozoon* species that have not been sampled yet, so more reptilian hepatozoid sequences need to be analysed in haplotype networks to better understand the relationships among these groups.

In summary, our study presented the first redescription, with the addition of molecular data, of a *Hepatozoon* species infecting snakes in the Brazilian Amazonia. We also provide the first genetic record of haemogregarines in neotropical aquatic snakes and expand knowledge of the geographic distribution of *H. carinicauda* in Brazil. Furthermore, our phylogenetic results showed that sequences isolated from aquatic hosts are not monophyletic, which may indicate a lower evolutionary relationship between these parasites and the environment used by their vertebrate hosts. Finally, we stress that there is a need for more studies, especially involving vector aspects, as there is still a large gap in knowledge about the taxonomy, natural history and evolution of parasites in wild hosts, especially in the Amazonia region.

Supplementary material. The supplementary material for this article can be found at <https://doi.org/10.1017/S0031182022000919>.

Data availability. All sequences used here are available at GenBank.

Acknowledgements. We would like to acknowledge Brazilian CAPES (the Coordination for the Improvement of Higher Education Personnel) for the Masters Scholarship to F. P. R.; the Postgraduate Development Program (PDPG – Amazônia Legal/CAPES) and the One Health in Areas of Urban and Peri-Urban Streams Project of Porto Velho (SUIg_PVH/UNIR/CAPES) for the Postdoctoral Fellowship to A. M. P.; FAPESP (Process#2019/15150-4) for the PhD Fellowship to L. P.; and Adriane C. Ramires for editing the figures. We are also grateful to CNPq (the National Council for Scientific and Technological Development) for the Productivity Grant awarded to M. R. A. (CNPq Process #302420/2017-7).

Author contributions. F. R. P. and L. A. V. conceived and designed the study. F. R. P. performed the fieldwork and the microscopic analysis. L. P. and M. R. A. performed the molecular analysis. A. M. P. and F. R. P. processed the data, interpreted the results and worked on the manuscript. All authors took part in the preparation, revised and approved the final version of the manuscript.

Financial support. This study was financed in part by CAPES (Finance Code 001), and was also supported by the Brazilian National Council for Scientific and Technological Development (CNPq Universal 429.132/2016-6 to LAV).

Conflict of interest. None.

Ethical standards. All procedures performed in this study involving animals were approved by the ethics committee on animal use from UNIFAP (protocol number 02/2020), and snake sampling and access to the genetic data were authorized by the Brazilian Ministry of the Environment (SISBIO number 74153 and SISGEN AB23235, respectively).

References

- Abdel-Baki AA, Al-Quraishy S and Zhang J (2014) Redescription of *Haemogregarina garnhami* (Apicomplexa: Adeleorina) from the blood of *Psammophis schokari* (Serpentes: Colubridae) as *Hepatozoon garnhami* n. comb. based on molecular, morphometric and morphologic characters. *Acta Parasitologica* **59**, 294–300.
- Aguiar LFS and Di-Bernardo M (2004) Diet and feeding behavior of *Helicops infrataeniatus* (Serpentes: Colubridae: Xenodontinae) in southern Brazil. *Studies on Neotropical Fauna and Environment* **39**, 7–14.
- Altschul SE, Gish W, Miller W, Myers EW and Lipman DJ (1990) Basic local alignment search tool. *Journal of Molecular Biology* **215**, 403–410.
- Ávila RW, Ferreira VL and Arruda JA (2006) Natural history of the South American water snake *Helicops leopardinus* (Colubridae: Hydropsini) in the Pantanal, central Brazil. *Journal of Herpetology* **40**, 274–279.
- Bandelt H, Forster P and Rohl A (1999) Median-joining networks for inferring intraspecific phylogenies. *Molecular Biology and Evolution* **16**, 37–48.
- Barta JR, Ogedengbe JD, Martin DS and Smith TG (2012) Phylogenetic position of the adeleorinid coccidia (Myxozoa, Apicomplexa, Coccidia, Eucoccidiorida, Adeleorina) inferred using 18S rRNA sequences. *Journal of Eukaryotic Microbiology* **59**, 171–180.
- Borges-Nojosa DM, Borges-Leite MJ, Maia JP, Zanchi-Silva D, da Rocha BR and Harris DJ (2017) A new species of *Hepatozoon* Miller, 1908 (Apicomplexa: Adeleorina) from the snake *Philodryas nattereri* Steindachner (Squamata: Dipsadidae) in northeastern Brazil. *Systematic Parasitology* **94**, 65–72.
- Bouer A, André MR, Gonçalves LR, Luzzi MDC, Oliveira JPD, Rodrigues AC, Varani AM, Miranda VFO, Perles L, Werther K and Machado RZ (2017) *Hepatozoon caimani* in *Caiman crocodilus yacare* (Crocodylia Alligatoridae) from North Pantanal, Brazil. *Brazilian Journal of Veterinary Parasitology* **26**, 352–358.
- Braz HB, Scartozzoni RR and Almeida-Santos SM (2016) Reproductive modes of the South American water snakes: a study system for the evolution of viviparity in squamate reptiles. *Zoologischer Anzeiger* **263**, 33–44.
- Carvalho TC, De Assis Montag LF and Dos Santos-Costa MC (2017) Diet composition and foraging habitat use by three species of water snakes, *Helicops* Wagler 1830 (Serpentes: Dipsadidae) in eastern Brazilian Amazonia. *Journal of Herpetology* **51**, 215–222.
- Cook CA, Netherlands EC, Smit NJ and Van As J (2018) Two new species of *Hepatozoon* (Apicomplexa; Hepatozoidae) parasitising species of *Philothamnus* (Ophidia: Colubridae) from South Africa. *Folia Parasitologica* **65**, 004.
- Costa HC and Bérnills RS (2018) Répteis do Brasil e suas Unidades Federativas: Lista de espécies. *Herpetologia Brasileira* **7**, 11–57.
- Darriba D, Taboada GL, Doallo R and Posada D (2012) jModelTest 2: more models, new heuristics and parallel computing. *Nature Methods* **9**, 772.
- De Paula FR, Picelli AM, Silva MRL, Correa JKC and Viana LA (2021) *Hepatozoon cevapii* (Apicomplexa: Hepatozoidae) in the *Thamnodynastes lanei* snake (Colubridae, Tachymenini) from the Eastern Amazon, Brazil. *Parasitology Research* **120**, 2981–2987.
- Flanley CM, Ramalho-Ortigao M, Coutinho-Abreu IV, Mukbel R, Hanafi HA, El-Hossary SS, Fawaz EY, Hoel DF, Bray AW, Stayback G, Shoue DA, Kamhawi S, Karakus M, Jaouadi K, Yaghoob-Ershadi MR, Krüger A, Amro A, Kenawy MA, Dokhan MR, Warburg A, Hamarsheh O and McDowell MA (2018) Population genetics analysis of *Phlebotomus papatasi* sand flies from Egypt and Jordan based on mitochondrial cytochrome b haplotypes. *Parasites & Vectors* **11**, 214.
- Fonseca MS, Bahiense TC, Silva AAB, Onofrio VC, Barral TD, Souza BMP, Lira-da-Silva RM, Biondi I, Meyer R and Portela RW (2020) Ticks and associated pathogens from rescued wild animals in rainforest fragments of northeastern Brazil. *Frontiers in Veterinary Science* **7**, 177.
- Freitas MA (2003) *Serpentes brasileiras. Malha de Sapó Publicações e Consultoria Ambiental*. Brasil: Lauro de Freitas.

- Godfrey RD Jr, Fedynich AM and Pence DB (1987) Quantification of haematozoa in blood smears. *Journal of Wildlife Diseases* **23**, 558–565.
- Gutiérrez-Liberato GA, Lotta-Arévalo IA, Rodríguez-Almonacid CC, Vargas-Ramírez M and Matta NE (2021) Molecular and morphological description of the first *Hepatozoon* (Apicomplexa: Hepatozoidae) species infecting a neotropical turtle, with an approach to its phylogenetic relationships. *Parasitology* **148**, 747–759.
- Hall TA (1999) BioEdit: a user-friendly biological sequence alignment editor and analysis program for Windows 95/98/NT. *Nucleic Acids Symposium Series* **41**, 95–98.
- Harris DJ, Maia JP and Perera A (2011) Molecular characterization of *Hepatozoon* species in reptiles from the Seychelles. *Journal of Parasitology* **97**, 106–111.
- Harris DJ, Santos J, Rampedi KM, Halajian A and Xavier R (2019) Genetic diversity of *Hepatozoon* (Apicomplexa) from domestic cats in South Africa, with a global reassessment of *Hepatozoon felis* diversity. *Journal of the South African Veterinary Association* **90**, 1–6.
- Hay ME, Poulin R and Jorge F (2020) Macroevolutionary dynamics of parasite diversification: a reality check. *Journal of Evolutionary Biology* **33**, 1758–1769.
- Hodzic A, Alic A, Prasovic S, Otranto D, Baneth G and Duscher GG (2017) *Hepatozoon silvestris* sp. nov.: morphological and molecular characterization of a new species of *Hepatozoon* (Adeleorina: Hepatozoidae) from the European wild cat (*Felis silvestris silvestris*). *Parasitology* **144**, 650–661.
- Hrazdilová K, Cervená B, Blanvillain C, Foronda P and Modrý D (2021) Quest for the type species of the genus *Hepatozoon* – phylogenetic position of hemogregarines of rats and consequences for taxonomy. *Systematics and Biodiversity* **19**, 1–10. doi:10.1080/14772000.2021.1903616.
- Hull RW and Camin JH (1960) Haemogregarines in snakes: the incidence and identity of the erythrocytic stages. *Journal of Parasitology* **46**, 515–523.
- Karadjian G, Chavatte JM and Landau I (2015) Systematic revision of the adeleid haemogregarines, with creation of *Bartazoon* ng, reassignment of *Hepatozoon argantis* Garnham, 1954 to *Hemolivia*, and molecular data on *Hemolivia stellata*. *Parasite* **22**, 31.
- Katoh K, Rozewicki J and Yamada KD (2019) MAFFT online service: multiple sequence alignment, interactive, sequence choice and visualization. *Briefings in Bioinformatics* **20**, 1160–1166.
- Kumar S, Stecher G, Li M, Knyaz C and Tamura K (2018) MEGA X: molecular evolutionary genetics analysis across computing platforms. *Molecular Biology and Evolution* **35**, 1547–1549.
- Lainson R, Paperna I and Naiff RD (2003) Development of *Hepatozoon caimani* (Carini, 1909) Pessôa, De Biasi & De Souza, 1972 in the caiman *Caiman c. crocodilus*, the frog *Rana catesbeiana* and the mosquito *Culex fatigans*. *Memórias do Instituto Oswaldo Cruz* **98**, 103–113.
- Léveillé AN, Zeldenrust EG and Barta JR (2021) Multilocus genotyping of sympatric *Hepatozoon* species infecting the blood of Ontario ranid frogs reinforces species differentiation and identifies an unnamed *Hepatozoon* species. *Journal of Parasitology* **107**, 246–261.
- Librado P and Rozas J (2009) DnaSP v5: a software for comprehensive analysis of DNA polymorphism data. *Bioinformatics* **25**, 1451–1452.
- Maia JP, Perera A and Harris DJ (2012) Molecular survey and microscopic examination of *Hepatozoon* Miller, 1908 (Apicomplexa: Adeleorina) in lacertid lizards from the western Mediterranean. *Folia Parasitologica* **59**, 241–248.
- Maia JP, Carranza S and Harris DJ (2016) Comments on the systematic revision of adeleid haemogregarines: are more data needed? *Journal of Parasitology* **102**, 549–552.
- Miller MA, Pfeiffer W and Schwartz T (2010) Creating the CIPRES Science Gateway for inference of large phylogenetic trees. *Gateway Computing Environments Workshop (GCE)* **14**, 1–8. doi:10.1109/GCE.2010.5676129.
- Morand S (2015) (macro-) Evolutionary ecology of parasite diversity: from determinants of parasite species richness to host diversification. *International Journal Parasitology Parasites and Wildlife* **4**, 80–87.
- Morrison DA (2009) Evolution of the Apicomplexa: where are we now? *Trends in Parasitology* **25**, 375–382.
- Murphy JC, Muñoz-Mérida A, Auguste RJ, Lasso-Alcala O, Rivas GA and Jowers MJ (2020) Evidence for cryptic diversity in the Neotropical water snake, *Helicops angulatus* (Linnaeus, 1758) (Dipsadidae, Hydrophini), with comments on its ecology, facultative reproductive mode, and conservation. *Amphibian & Reptile Conservation* **14**, 138–155.
- Nogueira CC, Argôlo AJS, Arzamendia V, Azevedo JA, Barbo FE, Bérniz RS, Bolochio BE, Borges-Martins M, Brasil-Godinho M, Braz H, Buononato MA, Cisneros-Heredia DE, Colli GR, Costa HC, Franco FL, Giraud A, Gonzalez RC, Guedes T, Hoogmoed MS, Marques OAV, Montingelli GG, Passos P, Prudente ALC, Rivas GA, Sanchez PM, Serrano FC, Silva NJ, Strüssmann C, Vieira-Alencar JPS, Zaher H, Sawaya RJ and Martins M (2019) Atlas of Brazilian snakes: verified point-locality maps to mitigate the Wallacean shortfall in a megadiverse snake fauna. *South American Journal of Herpetology* **14**, 1–274.
- O'Dwyer LH, Moço TC, Paduan KS, Spennassatto C, Silva RJ and Ribolla PEM (2013) Descriptions of three new species of *Hepatozoon* (Apicomplexa, Hepatozoidae) from rattlesnakes (*Crotalus durissus terrificus*) based on molecular, morphometric and morphologic characters. *Experimental Parasitology* **135**, 200–207.
- Perkins SL, Martinsen ES and Falk BG (2011) Do molecules matter more than morphology? Promises and pitfalls in parasites. *Parasitology* **138**, 1664–1674.
- Pessôa SB and Cavalheiro J (1969a) Notas sobre hemogregarinas de serpentes brasileiras – VII. *Revista Brasileira de Biologia* **29**, 351–354.
- Pessôa SB and Cavalheiro J (1969b) Notas sobre hemogregarinas de serpentes Brasileiras. IX. Sobre a hemogregarina da *Helicops carinicauda* (Wied). *Revista Goiana de Medicina* **15**, 161–168.
- Pessôa SB, De Biasi P and Puerto G (1974) Nota sobre a frequência de hemoparasitas em serpentes do Brasil. *Memórias do Instituto Butantan* **38**, 69–118.
- Picelli AM, Da Silva MRL, Ramires AC, Da Silva TRR, Pessoa FAC, Viana LA and Kaefer IL (2020) Redescription of *Hepatozoon ameivae* (Carini and Rudolph, 1912) from the lizard *Ameiva ameiva* (Linnaeus, 1758). *Parasitology Research* **119**, 2659–2666.
- Poulin R and Morand S (2004) *Parasite Biodiversity*. Washington: Smithsonian Institution Press.
- Ronquist F and Huelsenbeck JP (2003) MrBayes 3: Bayesian phylogenetic inference under mixed models. *Bioinformatics* **19**, 1572–1574.
- Ronquist F, Huelsenbeck JP and Teslenko M (2011) MrBayes 3.2 Manual: tutorials and model summaries. Available at http://mrbayes.sourceforge.net/mb3.2_manual.pdf.
- Sanger F, Nicklen S and Coulson AR (1977) DNA sequencing with chain-terminating inhibitors. *Proceedings of the National Academy of Sciences* **74**, 5463–5467.
- Schoneberg Y and Kohler G (2021) Distribution and identification of the species in the genus *Helicops* Wagler, 1830 (Serpentes, Colubridae, Xenodontinae). *Arpha Preprints* **10**, e69234. doi:10.3897/arpha.preprints.e67869.
- Sloboda M, Kamler M, Bulantová J, Votýpka J and Modrý D (2007) A new species of *Hepatozoon* (Apicomplexa: Adeleorina) from *Python regius* (Serpentes: Pythonidae) and its experimental transmission by a mosquito vector. *Journal of Parasitology* **93**, 1189–1198.
- Smith TG (1996) The genus *Hepatozoon* (Apicomplexa: Adeleina). *Journal of Parasitology* **82**, 565–585.
- Smith TG, Desser SS and Martin DS (1994) The development of *Hepatozoon sipedon* sp. nov. (Apicomplexa: Adeleina: Hepatozoidae) in its natural host, the northern water snake (*Nerodia sipedon sipedon*), in the culicine vectors *Culex pipiens* and *C. territans*, and in an intermediate host, the northern leopard frog (*Rana pipiens*). *Parasitology Research* **80**, 559–568.
- Sumrandee C, Baimai V, Trinachartvanit W and Ahantirig A (2015) *Hepatozoon* and *Theileria* species detected in ticks collected from mammals and snakes in Thailand. *Ticks and Tick-Borne Diseases* **6**, 309–315.
- Sykes JM IV and Klaphake E (2008) Reptile hematology. *Veterinary Clinics: Exotic Animal* **11**, 481–500.
- Telford SR Jr (2009) *Hemoparasites of the Reptilia: Color Atlas and Text*. Boca Raton: CRC Press.
- Telford SR Jr, Wozniak EJ and Butler JF (2001) Haemogregarine specificity in two communities of Florida snakes, with descriptions of six new species of *Hepatozoon* (Apicomplexa: Hepatozoidae) and a possible species of *Haemogregarina* (Apicomplexa: Haemogregarinidae). *Journal of Parasitology* **87**, 890–905.
- Trifinopoulos J, Nguyen LT, Von Haeseler A and Minh BQ (2016) W-IQ-TREE: a fast-online phylogenetic tool for maximum likelihood analysis. *Nucleic Acids Research* **44**, 232–235.
- Ujvari B, Madsen T and Olsson M (2004) High prevalence of *Hepatozoon* spp. (Apicomplexa, Hepatozoidae) infection in water pythons (*Liasis fuscus*) from tropical Australia. *Journal of Parasitology* **90**, 670–672.
- Úngari LP, Santos AL, O'Dwyer LH, Da Silva MR, Santos TC, Da Cunha MJ and Cury MC (2018) Molecular characterization and identification of *Hepatozoon* species Miller, 1908 (Apicomplexa: Adeleina: Hepatozoidae) in captive snakes from Brazil. *Parasitology Research* **117**, 3857–3865.

- Úngari LP, Netherlands EC, De Alcantara EP, Emmerich E and Da Silva RJ (2021) Description of a new species *Hepatozoon quagliattus* sp. nov. (Apicomplexa: Adeleorina: Hepatozoidae), infecting the sleep snake, *Dipsas mikanii* (Squamata: Colubridae: Dipsadinae) from Goiás State, Brazil. *Acta Parasitologica* **66**, 871–880.
- Viana LA, Soares P, Paiva F and Lourenço-de-Oliveira R (2010) Caiman-biting mosquitoes and the natural vectors of *Hepatozoon caimani* in Brazil. *Journal of Medical Entomology* **47**, 670–676.
- Vilcins IME, Ujvari B, Old JM and Deane E (2009) Molecular and morphological description of a *Hepatozoon* species in reptiles and their ticks in the Northern Territory Australia. *Journal of Parasitology* **95**, 434–442.
- Votýpka J, Modrý D, Oborník M, Slapeta J and Lukes J (2017) Apicomplexa. In Archibald JM, Simpson GB and Slamovits CH (eds), *Handbook of the Protists*. Boston: EUA, pp. 1–58.
- Yuki RN and Lema T (2005) Análise comparativa entre as cobras d'água meridionais (*Helicops carinicaudus* (wied, 1825) e *Helicops infrataeniatus* Jan, 1865), com a descrição do crânio e hemipênis (Serpentes: Colubridae: Xenodontinae). *Comunicações do Museu de Ciências e Tecnologia da PUCRS. Série Zoologia* **18**, 85–128.
- Zechmeisterová K, Javanbakht H, Kvicerová J and Siroký P (2021) Against growing synonymy: identification pitfalls of *Hepatozoon* and *Schellackia* demonstrated on North Iranian reptiles. *European Journal of Protistology* **79**, 125780. doi:10.1016/j.ejop.2021.125780.