

## View from Beneath: Pathology in Focus

### Kikuchi's necrotising lymphadenitis

JAMES W. FAIRLEY, F.R.C.S.,\* SIMON CROSS, M.R.C.Path.,\*\* JOHN D. SHAW, F.R.C.S.,\* GARRY W. GLOVER, F.R.C.S.,‡ MICHAEL H. BENNETT, F.R.C.Path.†

#### Abstract

Three cases of Kikuchi's necrotizing lymphadenitis without granulocytic infiltration presented to the ENT department as cervical lymphadenopathy with neutropaenia. Differential diagnosis from malignant lymphoma was difficult both clinically and histopathologically. Two recovered spontaneously without treatment within three months, one improved initially but was lost to follow-up after one month.

#### Introduction

The management of lumps in the neck is part of ENT practice. In order to make the correct diagnosis it is important to remember the rare possibilities. The first case of Kikuchi's necrotizing lymphadenitis in Britain was described by Gleeson *et al.*, in 1985. There have been no further reports in the ENT literature since then. We report three further cases of Kikuchi's necrotizing lymphadenitis, presenting to the ENT department and mimicking lymphoma both clinically and histopathologically.

#### Case reports

##### Case 1

A 26-year-old white woman with a past history of severe asthma presented in January 1990 with a six week history of a progressively enlarging, mildly painful, left neck swelling. For the last two weeks she had complained of a generalized itchy rash. She had been scratched by her cat, but this was three weeks after the swelling commenced.

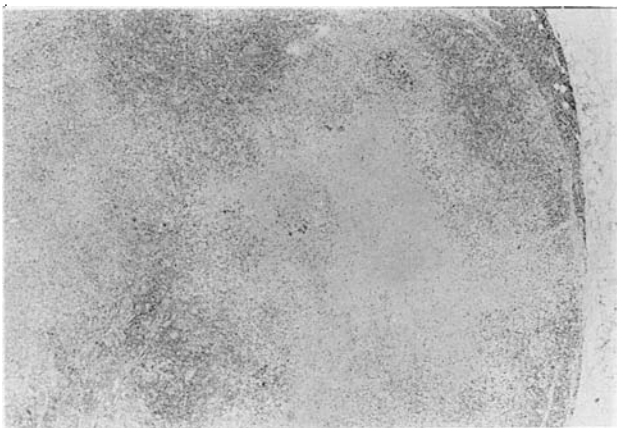

FIG. 1

Case 1. Low power view of lymph node showing focal areas of necrosis (Haematoxylin and eosin  $\times 25$ )

Examination showed a large tender smooth swelling under the upper border of the left sternomastoid muscle, with multiple smaller tender lymph nodes in the posterior triangle and supraclavicular fossa. The left tonsil was enlarged. The inguinal lymph nodes were tender and slightly enlarged. There was no hepatosplenomegaly. There was a punctate erythematous rash with scanty patchy distribution all over the body.

Investigations were as follows:

Chest X-ray—normal. Hb 12.8 g/dl, ESR 19 mm/hr, WBC  $3.4 \times 10^9/l$ —neutrophils  $1.5 \times 10^9/l$  (absolute neutropaenia), lymphocytes  $1.3 \times 10^9/l$ , monocytes  $0.5 \times 10^9/l$ , platelets  $265 \times 10^9/l$ . Coagulation studies normal. Urea and electrolytes, serum calcium and phosphate normal. Aspartate transaminase 68 (normal range 7–40 U/l), alanine transaminase 84 (NR7–45 U/l). Alkaline phosphatase and gamma glutamyl transferase were normal. Serological tests for infectious mononucleosis (Epstein Barr virus IgM), toxoplasmosis (latex test), and brucellosis (agglutination test) were negative. An HIV antibody test (EIA) was negative. On paired sera taken two

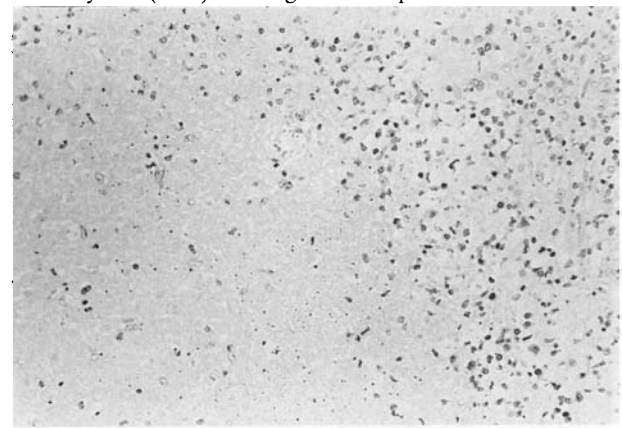


FIG. 2

Case 1. Higher power view of the edge of a necrotic area showing absence of granulocytic cells (Haematoxylin and eosin  $\times 160$ )

\*ENT Department, Royal Hallamshire Hospital, Sheffield S10 2JF.

†Honorary Consultant Pathologist, Mount Vernon Hospital, Middlesex.

‡ENT Department, Mount Vernan Hospital, Middlesex.

\*\*Department of Histopathology, Royal Hallamshire Hospital, Sheffield S10 2JF.

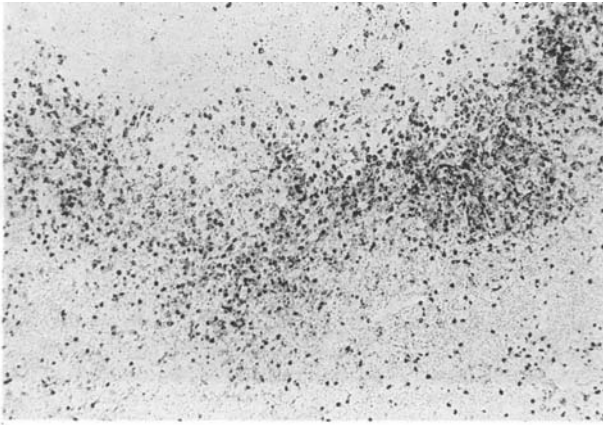


FIG. 3

Case 1. The edge of an area of necrosis showing numerous histiocytes stained with Mac 387 antibody (immunoperoxidase  $\times 63$ )

weeks apart there were no significant rises in antibody titres to measles virus, mumps virus S, mumps virus V, adenovirus, mycoplasma pneumoniae, influenza A, influenza B, respiratory syncytial virus, psittacosis, coxsackie virus burnettii, herpes virus hominis, varicella zoster, cytomegalovirus, rubella and parvovirus. Total serum IgG was 15.9 g/l, IgA 3.1 g/l, IgM 1.2 g/l. Autoimmune screening for antinuclear factor and anti-mitochondrial antibodies was negative.

She underwent examination of the post-nasal space, laryngoscopy, pharyngoscopy and cervical oesophagoscopy. No mucosal abnormality was seen, the left tonsil was slightly enlarged. A blind biopsy was taken from the nasopharynx and the left tonsil was removed.

Histology of both nasopharynx and tonsil revealed normal reactive lymphoid tissue with no evidence of malignancy nor any specific infection.

Computerized tomographic scan of the neck (unenhanced because of her asthma) showed enlarged lymph nodes in the left posterior triangle and supraclavicular fossa and a diffuse mass, deep to sternomastoid, extending from the level of the hyoid to 2 cm above the angle of the mandible, separate from the parotid. There was no parapharyngeal or nasopharyngeal lesion.

She then underwent excision biopsy of a lymph node from the left posterior triangle.

Histology showed a lymph node measuring 15  $\times$  14  $\times$  5 mm. Macroscopically the cut surface had a homogeneous pale yellow appearance. Paraffin sections showed a lymph node with gross distortion of the normal architecture and focal areas of necrosis (Fig. 1). The central part of these necrotic areas contained eosinophilic fibrinoid material and much nuclear

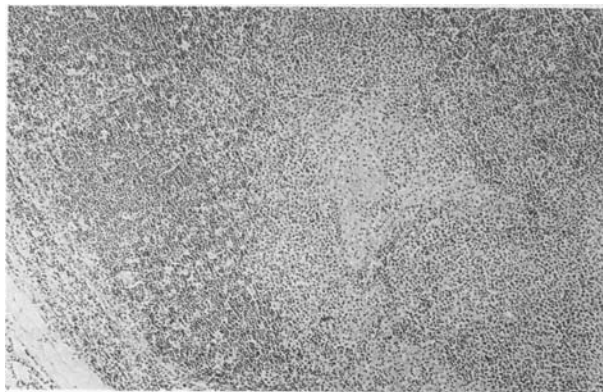


FIG. 4

Case 2. Paracortical region with a central focus of necrosis (Haematoxylin and eosin  $\times 80$ )

debris (Fig. 2). No significant infiltration by granulocytes was seen and no Reed-Sternberg cells were identified. Gram, Giemsa, Warthin-Starry, methenamine silver, periodic acid-Schiff, Ziehl-Neelsen, Wade-Fite and methylene blue stains were performed and samples were examined by electron microscopy but no organisms were identified. Immunocytochemical staining with Mac 387 antibody (Dakopatts, Copenhagen, Denmark) confirmed the presence of numerous histiocytes around the periphery of the areas of necrosis (Fig. 3). The microscopic appearances were those of Kikuchi's necrotizing lymphadenitis without granulocytic infiltration (Pileri *et al.*, 1982; Ali and Horton, 1985; Dorfman and Berry, 1988).

Six months later she remains clinically well with a minor degree of cervical lymphadenopathy.

Case 2

A 38-year-old white woman presented in July 1985 with a three week history of a painful swelling in the right side of her neck. This had failed to respond to repeated courses of antibiotics. She was feeling generally tired and had episodic sweating. There was no sore throat or otalgia and no preceding illness. In the past she had bilateral mastoidectomies and attended annually for aural toilet.

Examination showed a large tender mass under the upper part of the sternomastoid muscle with some smaller lymph nodes palpable along the deep cervical chain. There were no other palpable nodes and ENT examination was otherwise normal with healthy mastoid cavities.

Investigations were as follows: Hb 11.7 g/dl, ESR 29 mm/hr, WBC  $2.2 \times 10^9/l$ , Neutrophils 45 per cent (absolute neutropenia). The following investigations were normal: Chest X-ray, Urinalysis, creatinine clearance, 24 hour urinary protein, liver function tests including gamma glutamyl transferase, plasma proteins, calcium, phosphorus, uric acid, glucose, Hepatitis B surface antigen, Paul Bunnell, serum iron, blood culture, auto-antibodies to smooth muscle mitochondria and antinuclear factor.

Tru-cut biopsy showed a core of vascular and fatty connective tissue, heavily infiltrated by small dark cells. This was thought suggestive of lymphoma but inadequate for proper diagnosis. She therefore underwent excision biopsy of a cervical lymph node, which showed focal necrosis and partial destruction of architecture, but reactive follicles present. Paracortical regions showed marked expansion with multiple foci of incomplete haemorrhagic necrosis (Fig. 4) and numerous histiocyte-like cells but no polymorphs (Fig. 5). There was some lymphocytic periadenitis but no frank arteritis. These features were considered consistent with Kikuchi's necrotizing lymphadenitis.

Following an initial worsening of her general condition, with

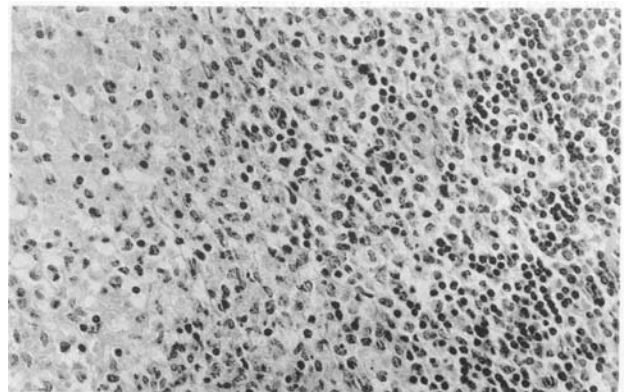


FIG. 5

Case 2. Edge of necrotic area showing plentiful histiocytes but an absence of neutrophils (Haematoxylin and eosin  $\times 350$ )

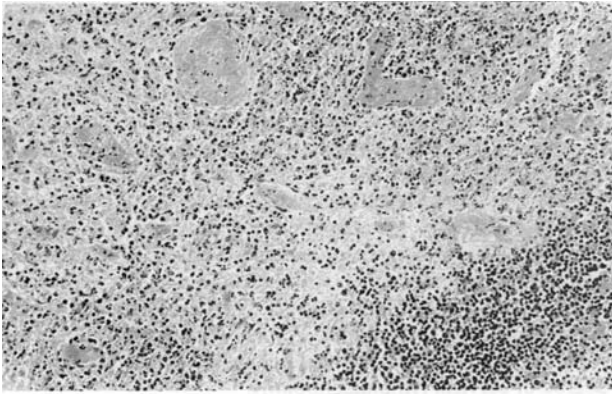


FIG. 6

Case 3. Area of necrosis with fibrin thrombi within the vessels (Haematoxylin and eosin  $\times 160$ )

the development of a polyarthritides and blotchy skin rash, she recovered spontaneously without further treatment. The neck swelling settled over the next two months and she remains well five years later.

### Case 3

A 27-year-old vegetarian Indian woman presented in December 1984 with a two week history of sore throat and left neck swelling. This had failed to respond to penicillin prescribed by her general practitioner. She felt generally unwell with night sweats. There was no recent history of exposure to tuberculosis.

On examination she was febrile, 38.5°C. There was a matted mass of lymph nodes under the upper third of the left sternomastoid, with some smaller nodes in the supraclavicular fossa. The remainder of the ENT examination was normal. The tip of the spleen was just palpable, but there was no hepatomegaly and no other lymphadenopathy.

Haemoglobin was 8.9 g/dl with iron deficiency picture and normal electrophoresis pattern. WBC  $5.9 \times 10^9/l$ , granulocytes 63 per cent platelets  $191 \times 10^9/l$ , ESR 70 mm/hr. Chest X-ray—normal. Mantoux test—negative at 1:10,000 and 1:1,000. Toxoplasma dye test, brucellosis direct agglutination and complement fixation tests—negative.

A tru-cut biopsy revealed non-specific inflammation, no granulomata or tubercle bacilli, but was inadequate to exclude lymphoma.

Over the following two weeks she persisted with a swinging pyrexia, worse in the evenings reaching peaks of 39.5°C. There was no response to a five day course of intravenous cephalexin. She was transfused two units of blood for her anaemia. ESR increased to 102 mm/hr, WBC fell to  $4.3 \times 10^9/l$ .

An incisional biopsy of the mass of lymph nodes taken two weeks after initial presentation revealed a necrotizing lymphadenitis, showing extensive areas of incomplete necrosis with intravascular fibrin thrombi, pyknotic nuclear debris and numerous histiocytes but no polymorphs (Figs. 6 & 7). She improved over the next week, without further treatment, and was discharged but failed to attend follow-up appointments. Enquiries showed that the family had moved away.

### Discussion

Kikuchi's necrotizing lymphadenitis is a rare cause of cervical lymph node enlargement, mainly affecting young women. It was first described by Kikuchi in Japan in 1972; Fujimoto *et al.*, reported a similar condition later the same year. Reports were confined to Japanese patients until 1982 when 27 cases were discovered retrospectively in the lymph node registry at Kiel, West Germany (Pileri *et al.*, 1982). The first and only case

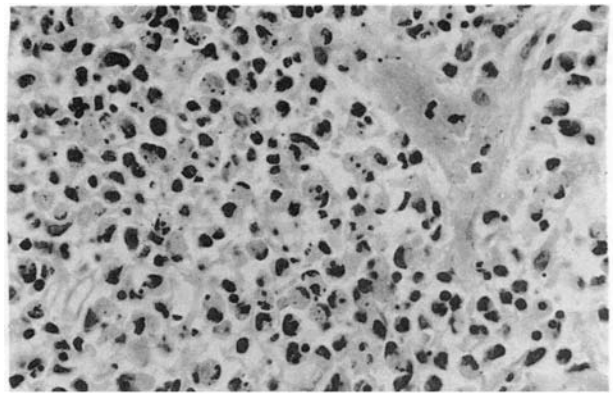


FIG. 7

Case 3. High power view of area of necrosis showing nuclear debris and pyknotic nuclei but an absence of neutrophils. (Haematoxylin and eosin  $\times 500$ )

reported in the English ENT literature was by Gleeson *et al.* (1985), since when there have been developments in knowledge of the pathology (Facchetti *et al.* 1989) and cases have been described from all over the world (Dorfman and Berry, 1988). Kikuchi's remains little known in ENT practice, and is likely to be misinterpreted both clinically and pathologically as malignant lymphoma (Dorfman and Berry, 1988) unless the possibility is remembered. This was the case in all three of our patients; clinically the diagnosis of lymphoma was considered most likely, and there was considerable concern and uncertainty about the histological appearances. The main differential diagnosis of Kikuchi's necrotizing lymphadenitis is non-Hodgkin's lymphoma, but also includes Hodgkin's disease, toxoplasmosis, infectious mononucleosis, cat scratch disease, systemic lupus erythematosus and acquired immunodeficiency syndrome (AIDS). The characteristic pathological changes in Kikuchi's lymphadenitis are well demonstrated in our cases. Most striking is the paracortical necrosis, with complete absence of granulocytes (Ali and Horton, 1985). This may be associated with a peripheral blood neutropaenia, which was most marked in our cases 1 and 2. Case 3 was also striking for the relatively low white blood count in the presence of a swinging pyrexia. This provides a useful clue to the diagnosis. The cause of Kikuchi's disease remains unknown. From its clinical behaviour it may well be a reaction to a viral infection. An alternative explanation, favoured by Dorfman and Berry (1988) is that it is a 'form fruste' of systemic lupus erythematosus. This is based on the fact that both occur most commonly in young women, and two of 108 cases submitted to him for further pathological consultation subsequently went on to develop SLE. Treatment of Kikuchi's disease is supportive, since the underlying cause is unknown and the majority of patients will recover spontaneously. Follow-up should continue for several years, as some cases may relapse or develop SLE.

### Acknowledgements

We thank Pat Hird for performing the immunocytochemical stains and Mick Eaton for his photographic assistance with case 1.

### References

- Ali, M. H., Horton, L. W. L. (1985) Necrotizing lymphadenitis without granulocytic infiltration. *Journal of Clinical Pathology*, **38**: 1252–1257.
- Dorfman, R. F., Berry, G. J. (1988) Kikuchi's necrotizing lymphadenitis: An analysis of 108 cases with emphasis on differential diagnosis. *Seminars in Diagnostic Pathology*, **5**(4): 329–345.
- Facchetti, F., De Wolf-Peters, C., Van den Oord, J. J., De Vos,

- R., Desmet, V. J. (1989) Plasmacytoid monocytes (so-called plasmacytoid T-cells) in Kikuchi's lymphadenitis. *American Journal of Clinical Pathology*, **92**: 42–50.
- Fujimoto, Y., Kojima, Y., Yamaguchi, K. (1972) Cervical subacute necrotizing lymphadenitis. *Naika*, **30**: 920–927.
- Gleeson, M. J., Siodlak, M. Z., Barbatis, C., Salama, N. Y. (1985) Kikuchi's—a new cause of cervical lymphadenopathy. *Journal of Laryngology and Otology*, **99**: 935–939.
- Kikuchi, M. (1972) Lymphadenitis showing focal reticulum cell hyperplasia with nuclear debris and phagocytosis. *Nippon Ketsueki Gakkai Zasshi*, **35**: 379–380.
- Pileri, S., Kikuchi, M., Helbron, D., Lennert, K. (1982) Histiocytic necrotizing lymphadenitis without granulocytic infiltration. *Virchows Archiv A*, **395**: 257–271.

Address for correspondence:  
Mr Fairley,  
ENT Department,  
Royal Hallamshire Hospital,  
Sheffield S10 2JF.  
Fax No. (0742) 725962

**Key words:** Lymphadenitis; lymph nodes; Kikuchi's disease

