

## Clinical Records

# Conductive deafness in aglossia

KOICHIRO HIGASHI, MASATAKA EDO

### Abstract

Aglossia is a rare anomaly often accompanied with several congenital defects including varying degrees of limb deficiency, micrognathia and oral synechiae. We report on a girl with aglossia and persistent anterior buccopharyngeal membrane. Other anomalies observed on the patient were oesophageal atresia, hypoplastic epiglottis, ptosis of the left eyelid, and conductive deafness which is probably an additional symptom of this syndrome group.

**Key words:** Hearing loss, conductive; Abnormalities, multiple

### Introduction

Aglossia is a rare condition with about 60 cases having been reported in the literature. Most of them are accompanied with limb defects (Weingarten *et al.*, 1993). We report on a girl who has conductive deafness along with aglossia and oral synechiae. Until now deafness has not been regarded as a symptom of these syndrome groups.

### Case report

The female infant was the result of a full-term uncomplicated pregnancy with an Apgar score of 8 at one minute. The mother and the father were 29 and 36 years old respectively. Soon after birth, severe micrognathia was recognized. The child developed increasing dyspnoea. Attempts at intubation and insertion of a nasogastric tube failed, and tracheotomy and gastrotomy were

performed. She was diagnosed as having congenital oesophageal atresia (Gross C type) for which she was operated on at three months of age. Clinical examination showed low set ears, severe micrognathia, aglossia, hypoplastic epiglottis, ptosis of the left eyelid, and very slight syndactyly of bilateral second, third and fourth toes.

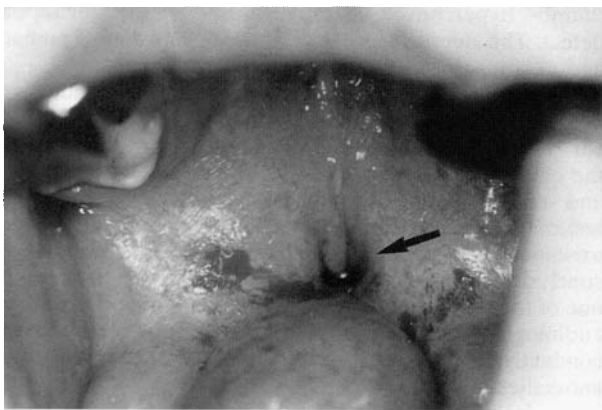


FIG. 1

Photograph of oral cavity. Only small hall was seen instead of fauces (arrow).

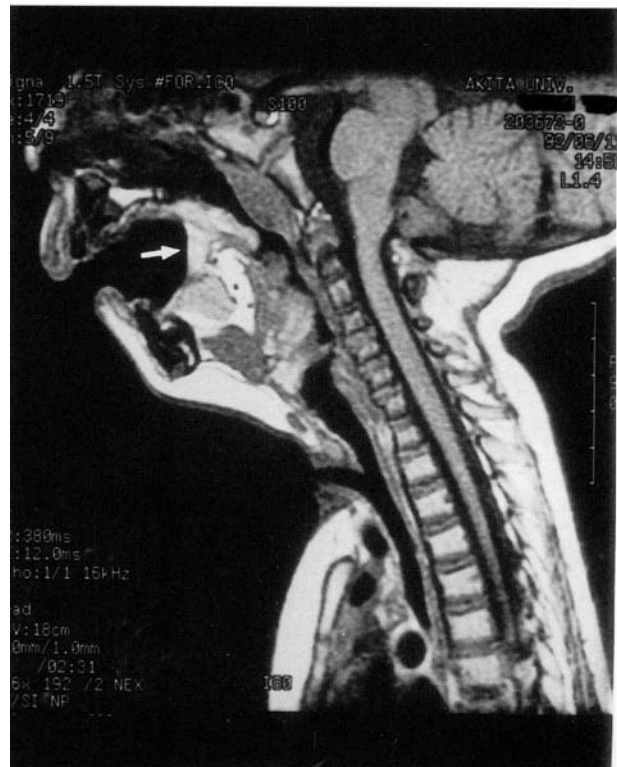


FIG. 2

Sagittal MRI showing the thick partition between the oral cavity and the mesopharynx (arrow).

From the Department of Otolaryngology, Akita University, Akita, Japan.  
Accepted for publication: 13 August 1996.

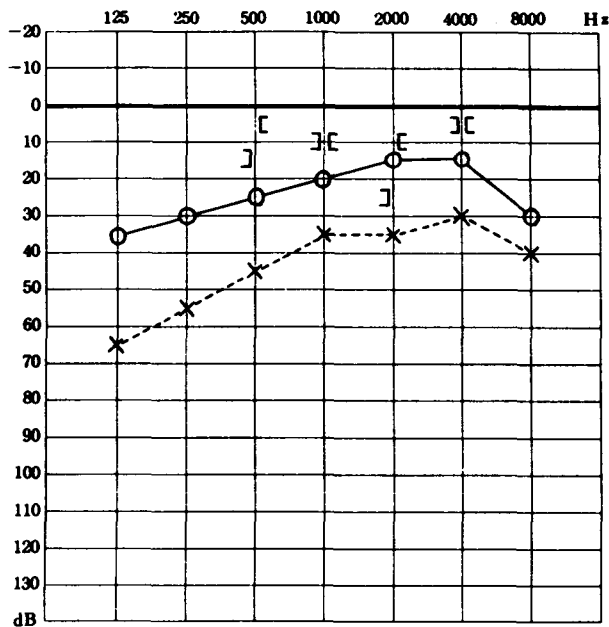


FIG. 3  
Pure tone audiogram.

Oral cavity and mesopharynx were partitioned by a thick membrane with a small hole of about 5 mm in diameter at the centre of it (Figures 1 and 2). On otological examination, the malleus handles and lateral processes were somewhat short or stumpy in shape.

The early development was disturbed by repeated infections of the respiratory tract, but at six years of age psychomotor development was within normal limits. Audiometry revealed bilateral conductive deafness (Figure 3). Tympanometry showed type A tympanogram bilaterally, but with a bifid peak in the left ear. Computed tomography (CT) scan of the temporal bones revealed anomalous ossicles (Figure 4).

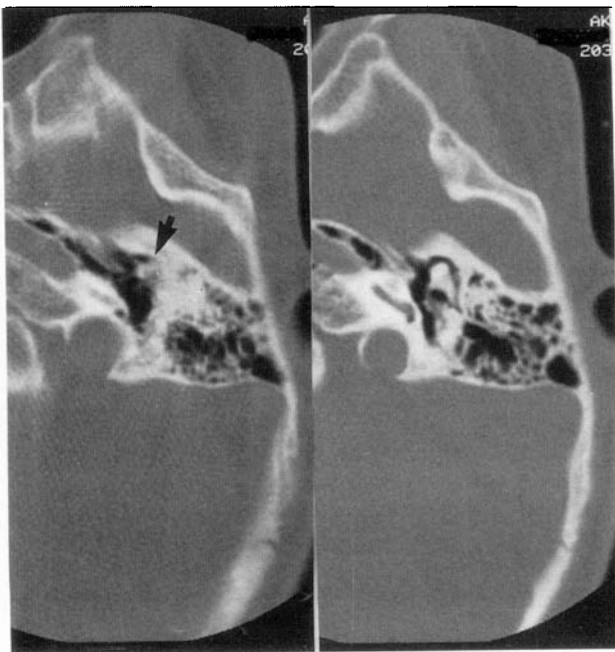


FIG. 4

CT scan of right temporal bone (successive two slices) showing somewhat malformed ossicles (arrow) and narrow epitympanum.

TABLE I  
OROMANDIBULAR AND LIMB HYPOGENESIS SYNDROMES

Type I	A) Hypoglossia
	B) Aglossia
Type II	A) Hypoglossia-hypodactylia
	B) Hypoglossia-hypomelia (Peromelia)
	C) Hypoglossia-hypodactylomelia
Type III	A) Glossopalatine ankylosis (ankyloglossum superius syndrome)
	B) With hypoglossia
	C) With hypoglossia-hypodactylia
	D) With hypoglossia-hypomelia
	E) With hypoglossia-hypodactylomelia
Type IV	A) Intraoral bands and fusion
	B) With hypoglossia
	C) With hypoglossia-hypodactylia
	D) With hypoglossia-hypomelia
	E) With hypoglossia-hypodactylomelia
Type V	A) The Hanhart syndrome
	B) Charlie M syndrome
	C) Pierre Robin syndrome
	D) Moebius syndrome
	E) Amniotic band syndrome

**Discussion**

Aglossia is a rare anomaly often accompanied with several congenital defects including varying degrees of limb deficiency, micrognathia and oral synechia. Definition of syndromes with aglossia is confusing. They are considered as one group of anomalies (Spivack and Bennett, 1968). Hall (1971) divided these syndromes of oromandibular and limb hypogenesis, into five types. Hanhart syndrome which includes hypomelia and severely hypoplastic mandible, Charlie M syndrome, Pierre Robin syndrome, Moebius syndrome and amniotic band syndrome are also included in his classification (Table I). Our patient corresponds to type IVB, intraoral bands and fusion with hypoglossia. The intraoral membrane observed in our patient attaches to the floor of the mouth and extends to the hard palate. It is a remnant of the anterior buccopharyngeal membrane (Gartlan *et al.*, 1993).

There are few reports about deafness in this group of syndromes. Chandra Sekhar *et al.* (1987) described a case of Hanhart syndrome with conductive deafness. The audiogram showed bilateral severe conductive deafness with air-bone gaps of over 50 dB. Jorgenson (1983) reported a female infant with micrognathia, small tongue fused to palate, hypoplastic terminal phalanges of both thumbs, hyperconvex fingernails, and a ventricular septal defect. The stenotic ear canals, low-set, cup-shaped pinnae and deafness in the patient seemed unique.

In the present case, slight to moderate conductive hearing loss was recognized, which is greater in the left ear. The anomalous ossicles are inferred from CT scan of the ears. Because suppression of development of the first and second branchial arches are observed in these anomalies with aglossia, it is reasonable to suppose the existence of ossicular anomalies. This case causes us to conclude the high probability that conductive deafness is one of the symptoms of this syndrome complex. Therefore, audiological examination is important in determining conductive deafness in patients with these kinds of anomalies.

**References**

Chandra Sekhar, H. K., Sachs, M., Silverl, V. C. (1987) Hanhart's syndrome with special reference to temporal bone findings. *Annals of Otolaryngology and Rhinology* 96: 309-314.

- Gartlan, M. G., Davies, J., Smith, R. J. H. (1993) Congenital oral synechia. *Annals of Otolaryngology, Rhinology and Laryngology* **96**: 309–314.
- Hall, B. D. (1971) Aglossia-adactylia. *Birth Defects: Original Article Series* **7(7)**: 233–236.
- Jorgenson, R. J. (1983) Syndrome identification case report 97: Tongue fusion, micrognathia and digital defects. *Journal of Clinical Dysmorphology* **1**: 8–9.
- Spivack, F., Bennett, J. E. (1968) Glossopalatine ankylosis. *Plastic and Reconstructive Surgery* **42**: 129–136.
- Weingarten, R. T., Walner, D. L., Holinger, D. L. (1993) Tongue hypoplasia in a newborn. *International Journal of Pediatric Otorhinolaryngology* **25**: 235–241.

Address for correspondence:  
Dr K. Higashi,  
Department of Otolaryngology,  
Akita University,  
Hondo 1-1-1,  
Akita, Japan.