

An update on sarcocystosis in one-humped camels (*Camelus dromedarius*)

Muhammad A. Saeed¹, Jane L. Vaughan² and Abdul Jabbar¹

¹Department of Veterinary Biosciences, Faculty of Veterinary and Agricultural Sciences, The University of Melbourne, Werribee, Victoria 3030, Australia and ²Cria Genesis, PO Box 406, Ocean Grove, Victoria 3226, Australia

Review Article

Cite this article: Saeed MA, Vaughan JL, Jabbar A (2018). An update on sarcocystosis in one-humped camels (*Camelus dromedarius*). *Parasitology* **145**, 1367–1377. <https://doi.org/10.1017/S0031182018000239>

Received: 30 December 2017
Revised: 29 January 2018
Accepted: 30 January 2018
First published online: 5 June 2018

Key words:

Camelus dromedarius; dromedary camels; *Sarcocystis*; Sarcocystosis

Author for correspondence: Abdul Jabbar,
E-mail: jabbara@unimelb.edu.au

Abstract

Sarcocystis spp. are intracellular coccidian parasites which infect domestic and wild animals and birds, resulting in considerable economic losses in production animals, and public health concerns worldwide. *Sarcocystis* spp. have an indirect life cycle where wild and/or domestic canine species primarily serve as definitive hosts and several domestic and wild animals (such as camels) act as intermediate hosts. In Northern Africa, the Middle East, Central Asia and China, camel meat is preferred due to cultural and religious traditions as well as its lower cholesterol/fat content than other red meat. However, camel meat quality could be downgraded by the presence of sarcocysts. To date, two *Sarcocystis* spp. have been reported from camels, including *Sarcocystis ippeni* (forms microscopic sarcocysts) and *Sarcocystis cameli* (forms both macroscopic and microscopic sarcocysts). Sarcocystosis is usually asymptomatic, though significant pathogenic effects have also been reported in camels. Despite the high occurrence of sarcocystosis in camels, little is known about various aspects of the disease in these animals. This paper provides a comprehensive review of the existing knowledge on the taxonomy, pathogenesis, epidemiology and diagnosis of *Sarcocystis* spp. infecting camels and it also highlights areas for further research that could enhance our understanding about sarcocystosis in camels.

Introduction

Sarcocystis is an intracellular protozoan parasite that was first reported in 1843 (Miescher, 1843). To date, more than 200 species have been recognized in this genus that infects a wide array of domestic and wild animals, resulting in considerable health and production losses in farmed animals worldwide (Tenter, 1995; Dubey, 2015). *Sarcocystis* spp. complete their life cycles in two hosts, i.e. a definitive (predator) and an intermediate (prey) host and they have higher host-specificity for their intermediate hosts than definitive hosts (Fayer, 2004). *Sarcocystis hominis*, *Sarcocystis heydorni* and *Sarcocystis suihominis* are known to infect humans where cattle (*S. hominis* and *S. heydorni*) and pigs (*Sarcocystis suihominis*) serve as their intermediate hosts (Poulsen and Stensvold, 2014; Dubey, 2015). *Sarcocystis nesbitti* has also been reported to infect humans (as intermediate host) following the ingestion of food/water contaminated with reptile excreta as snakes appear to be the potential definitive hosts (AbuBakar *et al.* 2013; Lau *et al.* 2014). The development of asexual stages of *Sarcocystis* spp. occur in intermediate hosts, including mammals (e.g., herbivorous animals such as camels, sheep and cattle; primates including humans), birds and poikilothermic animals where sarcocysts appear mainly in striated muscles of the diaphragm, heart, oesophagus and skeletal muscles (Hidron *et al.* 2010; Dubey *et al.* 2015a) and less frequently in the central nervous system and smooth muscle of the intestine (Fayer, 2004; Miller *et al.* 2009; Dubey *et al.* 2015a). Definitive hosts (e.g. canids, felids, marsupials and primates) acquire the infection by ingesting intermediate host tissue infected with mature sarcocysts, then following a phase of sexual reproduction in the definitive host, oocysts/sporocysts are excreted into the environment *via* feces which can then be ingested by appropriate intermediate hosts.

The dromedary or one-humped camel (*Camelus dromedarius*) is widely distributed in the hot, arid areas of the Middle East, Africa, South Asia and Central Australia and Canary Islands of Spain while the Bactrian or two-humped camel (*Camelus bactrianus*) is found in China, Canary Islands of Spain, India, Kazakhstan, Mongolia and Russia (Kalmykistan) and (Faye, 2014; Kadim *et al.* 2014). The total camel population is estimated over 28 million worldwide (FAOSTAT, 2016). Camels are adapted to adverse climatic and harsh environmental conditions such as high temperatures, intense solar radiation, water scarcity and poorly digestible vegetation which can adversely affect the performance of other meat-producing animals (Kadim *et al.* 2008; Faye, 2014), thereby making camels suitable for commercial meat and milk production in a wide range of agroclimatic zones. The annual worldwide camel meat and milk productions have been recorded as 532 198 and 2 696 337 tonnes, respectively (FAOSTAT, 2016). Camel meat is preferred in some countries due to its lower fat and cholesterol contents compared with beef, lamb and ostrich meat and other perceived health benefits (Kadim *et al.* 2008, 2014). Thus, camel meat potentially holds a high value for local as well as international meat markets due to the camel's production ability in harsh environments and the increasing demand for camel meat. However, the presence of sarcocysts in camel meat

could potentially downgrade its quality for human consumption as camels serve as an intermediate host for at least two *Sarcocystis* spp. and the infection is common in the dromedary camel throughout its distribution globally (Mandour *et al.* 2011; Hamidinejat *et al.* 2013; Omer *et al.* 2017). Infected camels generally exhibit subclinical infections, although *Sarcocystis* spp. can induce significant pathology or even mortality in these animals (Valinezhad *et al.* 2008; Omer *et al.* 2017). However, little is known about various aspects of sarcocystosis in camels, including its molecular biology, pathology, molecular epidemiology, life cycle, economic impact and public health significance.

This paper provides an update on the taxonomy, epidemiology, pathogenesis and diagnosis of *Sarcocystis* spp. that infect camels. Furthermore, it highlights areas for future research that could enhance our knowledge on sarcocystosis in camels. The word camel(s) refers to the dromedary or one-humped camel(s) throughout this paper, unless otherwise mentioned as the Bactrian camel.

Taxonomy of *Sarcocystis* spp. in camels

There has been considerable confusion regarding the nomenclature of *Sarcocystis* spp. in camels, and at least six different names have been used for *Sarcocystis* spp. in camels, including *Sarcocystis cameli*, *Sarcocystis ippeni*, *Sarcocystis camelicanis*, *Sarcocystis camelocanis*, *Sarcocystis miescheri* and *Sarcocystis meischeri*.

Mason (1910) first time described sarcocysts in camels from Egypt as white lines (12 × 1 mm) in striated muscles with either thick or thin walls. Although the wall thickness of these sarcocysts was different, Mason (1910) thought that these cysts belonged to the one species of *Sarcocystis*, *S. cameli*. Subsequently, based on their morphological features, thick- and thin-walled sarcocysts in camels were renamed as *S. cameli* (Dubey *et al.* 1989) and *S. ippeni* (Odening, 1997), respectively. Other studies also confirmed the presence of both types of sarcocysts in camels from Saudi Arabia (Fatani *et al.* 1996) and Sudan (Ishag *et al.* 2006). Ishag *et al.* (2006) observed two different sizes of *Sarcocystis* sporocysts excreted in feces of dogs experimentally fed with camel meat. The smaller (13.2–13.6 × 6.5–9.5 μm) sporocysts with a longer patent period (55–57 days) were considered as *S. cameli* whereas the larger (16.0 × 9.9–11.5 μm) sporocysts with a shorter patent period (37–45 days) were named as *S. camelocanis* (Ishag *et al.* 2006). Subsequently, the name *S. camelicanis* was introduced for sporocysts excreted in dog feces, fed with camel meat without providing any further detail (Abdel-Ghaffar *et al.* 2009). *Sarcocystis miescheri* was reported as a new *Sarcocystis* sp. in camels, based on oocyst features excreted by dogs fed with sarcocyst-infected camel meat (Mandour *et al.* 2011), and the same name was used and misspelled as *S. meischeri* in a subsequent study (Abd-Elmalek *et al.* 2015).

Overall these studies indicate that the taxonomy of *Sarcocystis* spp. of camels remains debatable, primarily due to the unavailability of type specimens and inadequate structural descriptions. Dubey *et al.* (2015b) reviewed the literature on *Sarcocystis* spp. infecting camels, and based on their morphological features, proposed that *S. cameli* and *S. ippeni* were the only two valid species that affect camels worldwide. However, in our review, we have used the original names of *Sarcocystis* spp. as used by various authors (Tables 1 and 2) for clarity.

Structure of sarcocysts found in camels

Both macroscopic and microscopic sarcocysts have been reported in camels, though the latter is more common (Table 1).

Macroscopic sarcocysts appear as small (1.5–5.0 × 0.2–0.4 mm), white structures embedded in various muscle tissues of camels (Dubey *et al.* 2017). However, microscopic sarcocysts vary in size depending on the type of tissue in which they are present (Table 1). Furthermore, the shape of microscopic sarcocysts could also vary (round/spherical, elongated, ellipsoid, spindle-shaped, spiral etc.). For instance, cysts from cardiac muscle (154 × 62 μm) and skeletal muscle of the shoulder (108.9 × 52.2 μm) were smaller than those (248.7 × 96.7 μm) observed in oesophageal striated or smooth muscle (Woldemeskel and Gumi, 2001).

Generally, each sarcocyst is surrounded by a primary cyst wall, containing numerous villar protrusions into the cyst ground substance. The ground substance divides the cyst cavity into multiple compartments within which merozoites and merozoites/bradyzoites are packed. Generally, merozoites are located at the periphery while bradyzoites occupy the interior of each cyst (Abdel Ghaffar *et al.* 1979; Al-Quraishy *et al.* 2004; Mandour *et al.* 2011). The size and shape of bradyzoites vary depending on the location within camel tissues. For instance, elongated/banana-shaped (12–18 × 3–6 μm) and spherical (15–16 × 12–14 μm) bradyzoites have been observed in muscle of heart, diaphragm and oesophagus, respectively (Rahbari *et al.* 1981; Mandour *et al.* 2011). The nucleus in banana-shaped bradyzoites is located either centrally or towards the blunt end (Fatani *et al.* 1996; Ishag *et al.* 2006; Latif and Khamas, 2007; Mandour *et al.* 2011).

The morphology of the primary cyst wall of microcysts is used as the most important criterion to classify *Sarcocystis* spp. (Abdel-Ghaffar *et al.* 2009; Dubey *et al.* 2015a, b). Two distinct types of primary cyst walls have been reported in camels (one with finger-like and other with cone-like villar protrusions). Various authors have used different names to describe these two types of the cyst (see Table 1). For clarity, we have designated them as Variety A and Variety B cyst walls.

Variety A (*S. cameli*) cyst walls

The microscopic cysts of *S. cameli* have smooth walls, with variable length (e.g., 130–180) and width (60–110 μm). Abdel-Ghaffar *et al.* (1979) first described the ultrastructure of microscopic sarcocysts collected from camels in Egypt and found that the electron-dense cyst wall had finger-like villar protrusions (1.2–1.6 × 0.5 μm) which harboured knob-like elevations at their surfaces. Each villar protrusion was characterized by the presence of internal fibrillar elements (microtubules). Elongated bradyzoites measured 8–12 × 2.5–3.8 μm in size (Abdel Ghaffar *et al.* 1979). Subsequent studies found that each villar protrusion contained about 16–18 knob-like structures (Abdel-Ghaffar *et al.* 2009). Similar sarcocyst wall structure was reported in other studies from Iran (Motamedi *et al.* 2011), Jordan (Latif and Khamas, 2007) and Saudi Arabia (Al-Quraishy *et al.* 2004), although they used different names for the parasite (see Table 1).

Dubey *et al.* (2015b) described similar sarcocyst wall structure in camels and named it as *S. cameli*. Sarcocysts of this species had thin walls, with no visible projections. The cyst wall had finger-like villar protrusions (3.0 × 0.5 μm), with rows of knob-like projections that appeared to be interconnected, and bradyzoites (14–15 × 3–4 μm) in the centre. Dubey *et al.* (2015a) named this cyst type as 'type 9j' and proposed dogs as a potential definitive host for *S. cameli* (Dubey *et al.* 2015b).

The first ultrastructure of macroscopic sarcocysts from camels in Iraq was recently described by Dubey *et al.* (2017). They observed a thin cyst wall with 'type 9j' or finger-like villar protrusions (2.5 μm) and named the parasite as *S. cameli*.

Table 1. Morphology of *Sarcocystis* spp. in dromedary camels.

Species of <i>Sarcocystis</i> ^a	Cyst type	Cyst wall type (LM)	Cyst wall thickness (μm)	Sporocyst size (μm)	Bradyzoite / merozoite length (μm)	TEM (wall type/villar protrusion shape)	Reference(s)
<i>S. cameli</i>	Mac	NA	0.5–1.0	1500–5000 × 200–400	12–14	Thin/finger	Dubey <i>et al.</i> (2017)
		NA	NA	6000–15 000	NA	NA	Kuraev (1981) ^b
	Mic	Thin	< 2	205 × 73	14–15 × 3–4	NA/finger	Dubey <i>et al.</i> (2015b)
		NA	NA	260 × 75	NA	NA	Motamedi <i>et al.</i> (2011)
		Thick	1–2	33.3–388.8 × 22.2–33.3	NA	NA	Hilali and Mohamed (1980)
	Thick	1–3	73–155 × 23–29.5	NA	NA	Ishag <i>et al.</i> (2006)	
<i>S. ippeni</i>		Thin	< 2	110–120 × 50–100	12–13.5 × 2–3	NA/conical	Dubey <i>et al.</i> (2015b)
<i>S. meischeri</i>		Thick	NA	179–2500 × 70–112.5	30–32 × 7.5–14.2	Thick/finger, conical	Abd-Elmalek <i>et al.</i> (2015)
<i>S. miescheri</i>		Thick	1.7–2.1	229–2000 × 77.8–137.8	21.6–32.9 × 7.8–17.8	Thick/villi (finger), spine (conical?)	Mandour <i>et al.</i> (2011)
<i>S. camelicanis</i>		NA	NA	120–170 × 50–100	NA	Thick/finger	Abdel-Ghaffar <i>et al.</i> (2009)
<i>S. camelocanis</i>		Thin	0.5	72.5–264 × 9.9–29.5	NA	NA	Ishag <i>et al.</i> (2006)
<i>Sarcocystis</i> spp.		NA	1–2	85–325 × 35–85	15.5 × 0.9	NA	Omer <i>et al.</i> (2017)
		NA	NA	75 × 260	3.0 × 7.0	NA	Eslampanah <i>et al.</i> (2016)
		NA	1.07	84 × 19	19 × 4.9	NA	Vounba (2010)
		NA	0.69	57 × 16	NA	NA	
		NA	NA	179–2500 × 70–112.5	NA	NA	Hamidinejat <i>et al.</i> (2013)
		NA	NA	NA	NA	NA	Hosseini <i>et al.</i> (2010)
		Thin	NA	NA	NA	NA	Valinezhad <i>et al.</i> (2008)
		Thick, thin	1.75, 0.8	NA	NA	NA	Latif and Khamas (2007)
		NA	NA	NA	NA	NA	Shekarforoush <i>et al.</i> (2006)
		Thin	0.6–1.2	240 × 120	10.5 × 3.0	NA	Al-Quraishy <i>et al.</i> (2004)
		NA	NA	NA	NA	NA	Fukuyo <i>et al.</i> (2002) ^b
		Thin	NA	108.9–248.7 × 52.2–96.7	NA	NA	Woldemeskel and Gumi (2001)
		Thick, thin	2–3, 0.5–1.0	73–155 × 23–29.5, 72.5–264 × 9.9–29.5	10–16 × 3–4	NA	Manal <i>et al.</i> (2001)
		NA	NA	NA	NA	NA	Latif <i>et al.</i> (1999)
		Thick, thin	1.5–2, 0.75–1	170–194 × 117.5–188, 141–400 × 70.5–188	14.0–17.0 × 3.0–5.0	NA	Fatani <i>et al.</i> (1996)
		Thick, thin	2–2.5, NA	NA	NA	NA	Borrow <i>et al.</i> (1989)
		NA	NA	NA	NA	NA	Kirmse and Mohanbabu (1986)
		NA	NA	NA	NA	NA	Hussein and Warrag (1985)
		NA	NA	NA	12–18 × 3–6, 15–16 × 12–14	NA	Rahbari <i>et al.</i> (1981)
		NA	NA	120–150 × 50–80	2.5–4.0 × 10.0–12.0	Thin/conical	Entzeroth <i>et al.</i> (1980)
	NA	NA	130–180 × 60–110	8–12 × 2.5–3.8	NA	Abdel Ghaffar <i>et al.</i> (1979)	
	Mac	NA	NA	800 × 300	NA	NA	Rao <i>et al.</i> (1997)

LM, light microscopy; Mac, macroscopic; Mic, microscopic; NA, not available/applicable; TEM, transmission electron microscopy.

^aThe name used by the authors.

^bThe study did not mention the type (dromedary/Bactrian) of camels used or used both types of camels and did not correlate the result with any of the two types.

Variety B (*S. ippeni*) cyst walls

Entzeroth *et al.* (1980) described the second type of microscopic sarcocysts from camels in Egypt harbouring a cyst wall with cone-like villar protrusions (0.5–1.4 μm) and bradyzoites (2.5–4.0 × 10.0–12.0 μm) with cristae. Dubey *et al.* (2015b) observed similar

cyst walls in camels from Egypt and named it as *S. ippeni*. Sarcocysts of *S. ippeni* are characterized by thick (2.3–3.0 μm) cyst walls containing conical villar protrusions, harbouring electron dense knobs. Each villar protrusion harbours smooth,

Table 2. Studies aimed at assessing the prevalence of *Sarcocystis* spp. in dromedary camels.

Species of <i>Sarcocystis</i> ^a	Geographical location	Tissue(s) examined	Diagnostic method(s) used	Proportion	Percent prevalence ^b	Reference
<i>S. cameli</i>	Egypt	E	His	2/2	NA	Dubey <i>et al.</i> (2015a, b)
		D, E	Mc, His	41/112	37	Hilali and Mohamed (1980)
	Iran	D, E, Sm	Pd	NA	NA	Motamedi <i>et al.</i> (2011)
	Iraq	E	NA	2/2	NA	Dubey <i>et al.</i> (2017)
<i>S. ippeni</i>	Kazakhstan	D, E, H, Sm, T	NA	84/266	32	Kuraev (1981) ^c
		E	His	2/2	NA	Dubey <i>et al.</i> (2015a, b)
		D, E, H, Sm, T	Td	116/180	64	Abdel-Ghaffar <i>et al.</i> (2009)
		E, Sm, T	Mc	108/195	56	Abd-Elmalek <i>et al.</i> (2015)
<i>S. miescheri</i>	E	Mc	66/156	42	Mandour <i>et al.</i> (2011)	
<i>Sarcocystis</i> spp.	Afghanistan	E	His, Mc	118/192	61	Kirmse and Mohanbabu (1986)
	Chad	D, H, Sm, T	His, Pd	19/30	63	Vounba (2010)
	Egypt	H	His	34/42	81	El-Etreby (1970)
		NA	His	3/13	23	Entzeroth <i>et al.</i> (1980)
	Ethiopia	D, E, H, T	His	NA/44	NA	Abdel Ghaffar <i>et al.</i> (1979)
		D, E, H, Sm	His	55/121	45	Woldemeskel and Gumi (2001)
	India	E, T	His	NA/246	15	Kumar <i>et al.</i> (2016)
		Sm	Ge, His	1/1	100	Rao <i>et al.</i> (1997)
	Iraq	D, E, H, Sm	Pd	33/36	92	Latif <i>et al.</i> (1999)
	Iran	D, E, H, Sm	Mc	NA/50	NA	Eslampanah <i>et al.</i> (2016)
		D, E, H, Sm	Pd	67/130	52	Hamidinejat <i>et al.</i> (2013)
		D, E, T	Pd,	61/100	61	Hosseini <i>et al.</i> (2010)
		D, E, H, Sm, T	His	209/250	84	Valinezhad <i>et al.</i> (2008)
		D, E, H, Sm, T	Mc	209/400	52	Shekarforoush <i>et al.</i> (2006)
		D, E, H	Mc	NA/39	53	Rahbari <i>et al.</i> (1981)
		Jordan	D, E, H	Pd	6/97	6
			His	2/97	2	
		D, E, H, Sm	Mc	24/110	22	Latif and Khamas (2007)
	Mauritania	D, H, Sm, T	His, Pd	28/58	48	Vounba (2010)
	Mongolia	D, H, T	Mc	5/5	100	Fukuyo <i>et al.</i> (2002) ^c
	Saudi Arabia	D, E, H, Sm, T	Pd	50/50	50	Omer <i>et al.</i> (2017)
		D, E, H, Sm, T	His	22/80	28	
		D, E, Sm, T	Td	399/624	64	Al-Quraishy <i>et al.</i> (2004)
		D, E, H	Td, His	91/103	88	Fatani <i>et al.</i> (1996)
	Somalia	D, E, H	Td, His	165/200	82	Borrow <i>et al.</i> (1989)
	Sudan	Br, H, L, Sm	His	2/2	NA	Manal <i>et al.</i> (2001)
		D, E, H, Sm	Pd	81/100	81	Hussein and Warrag (1985)

^aThe name used by the authors.

^bDecimal points were rounded off; Br, brain.

^cThe study did not mention the type (dromedary/Bactrian) of camels used or used both types of camels and did not correlate the result with any of the two types; D, diaphragm; E, oesophagus; H, heart; His, histology; Mc, muscle compress/squash/squeeze; NA, not available; Pd, pepsin digestion; Sm, skeletal muscle; T, tongue; Td, trypsin digestion

criss-crossed microtubules without any granules/dense areas and bradyzoites measure 12.0–13.5 × 2.0–3.0 μm in size (Dubey *et al.* 2015b).

Therefore, it appears *S. cameli* can form both macroscopic and microscopic sarcocysts in camels. Cysts possess a cyst wall characterized by finger-like villar protrusions with knob-like projections on each villar protrusion. *Sarcocystis ippeni* forms microscopic

sarcocysts characterized by conical villar protrusions harbouring electron dense knobs.

Life cycle of *Sarcocystis* spp.

To establish the definitive host(s) of *Sarcocystis* spp. that infect camels, various authors have conducted experimental infection

studies by feeding dogs and cats with *Sarcocystis*-infected camel meat (see Table 3). To date, only sporocysts have been found in feces of dogs, suggesting that dogs are the potential definitive host for *Sarcocystis* spp. that infect camels. Although the complete life cycle of *Sarcocystis* spp. of camels remains to be explored, a general life cycle of *Sarcocystis* spp. is illustrated in Fig. 1.

A definitive host such as a dog becomes infected following the ingestion of sarcocysts contained in infected camel tissue. The prepatent period could vary from 7 to 15 days (see Table 3). Following cyst rupture in the posterior third of the small intestine, bradyzoites are released into the lumen, penetrate the lamina propria and undergo various sexual developmental stages (Hilali *et al.* 1982). Micro- and macrogametes are differentiated by 2–3 days post-infection (dpi) and are spherical to ovoid, although microgametes are fewer in number and may contain up to 30 nuclei. A zygote is formed following the fusion of a macro- and microgamete and may be observed 5 dpi having a dense cell wall and relatively a large nucleus (Hilali *et al.* 1982; Abdel-Ghaffar *et al.* 2009). Each zygote develops into an oocyst which contains two completely sporulated sporocysts and appears in the lamina propria by 8 dpi (Hilali *et al.* 1982). Each sporocyst contains four sporozoites and a residual body (Hilali *et al.* 1992; Ishag, 2003; Ishag *et al.* 2006; Abdel-Ghaffar *et al.* 2009). The sizes of sporocysts observed in various experimental infection studies in dogs are presented in Table 3. Individual sporocysts or sporulated oocysts are released in the feces of the definitive host, which may then contaminate camel food and water and can readily infect them.

Camels may acquire a *Sarcocystis* infection by ingesting food/water or their own feces contaminated with sporulated oocysts or sporocysts shed by a definitive host such as a dog. Each sporocyst releases four sporozoites in the digestive tract of camels which penetrate the gut wall and enter endothelial cells of blood vessels (Abdel-Ghaffar *et al.* 2009; Dubey *et al.* 2015a). Following a few generations of asexual reproduction (i.e. schizogony), a huge number of merozoites are produced which migrate in the blood and finally develop into sarcocysts in myocytes. Each sarcocyst contains millions of infective bradyzoites which are protected from host cell defense mechanisms by a parasitophorous vacuole, made from the host cell plasma membrane (Abdel-Ghaffar *et al.* 2009).

Given that both *S. cameli* and *S. ippeni* can form microcysts in camels and the nomenclature of these species was unclear at the time when these studies were conducted, it is not possible to relate the type of sarcocyst or *Sarcocystis* sp. with the dog as their definitive host. Nevertheless, the current evidence suggests that the dog is the potential definitive host for at least one of the *Sarcocystis* spp. in camels.

Pathogenesis of sarcocystosis in camels

Despite the high prevalence (discussed in the following section) of *Sarcocystis* in camels, there is a paucity of information on the pathogenesis of sarcocystosis in these animals. Several factors, including the immune status of the host, the number of oocysts/sporocysts ingested, and *Sarcocystis* spp. involved, determine the number and distribution of sarcocysts in an intermediate host (Wernery *et al.* 2014; Dubey *et al.* 2015a). However, these factors have been mainly unexplored for *Sarcocystis* spp. in camels. Thick- (1–3 μm) and thin- (0.5 μm) walled sarcocysts have been observed in muscles of infected camels (Ishag *et al.* 2006), indicating that multiple *Sarcocystis* spp. or more than one parasitic forms could exist in the same camel host.

Microscopic sarcocysts, the most common form reported in camels, appear in different tissues of the host such as diaphragm, oesophagus and skeletal muscles (e.g. limb muscle, masseter

muscle), heart, tongue, etc. (Table 2). Although the disease is usually asymptomatic or subclinical in camels (Hamidinejat *et al.* 2013; Omer *et al.* 2017), significant pathology has been ascribed to microscopic sarcocystosis. For instance, following the ingestion of *Sarcocystis* sporocysts, camels can develop pyrexia, anorexia and restlessness and may exhibit anaemia, low packed cell volume and decreased albumin, globulin, haemoglobin and serum protein concentrations (Fatani *et al.* 1996). Haemorrhages may be observed in the omentum, mesenteric lymph nodes, urinary bladder, myocardium, brain, lungs and skeletal muscles (Fatani *et al.* 1996; Manal *et al.* 2001). Initial inflammatory changes induce necrosis and degeneration in musculoskeletal tissues which may ultimately lead to healing with fibrosis and scarring (Valinezhad *et al.* 2008). Mostly, the affected tissues may exhibit no degenerative or inflammatory changes in host tissues. However, in some of the infected tissues, degenerated sarcocysts could be associated with necrosis and an inflammatory response between muscle fibres which is characterized by infiltration of polymorphonuclear cells, lymphocytes, macrophages, eosinophils and fibroblasts (Manal *et al.* 2001; Valinezhad *et al.* 2008).

Overall these studies indicate that sarcocystosis could be associated with significant pathology, with mild or no clinical symptoms in infected camels. However, this is worth mentioning that the sample size in almost all previous studies was very small (Table 3) that warrants further studies with large sample size with proper experimental controls to better understand the pathogenesis of *Sarcocystis* spp. in camels. Future studies are required to comprehensively understand the pathogenesis of sarcocystosis and its impact on the cardiac/musculoskeletal functioning and productivity of camels, economic importance and animal welfare. Furthermore, pathogenesis associated with macroscopic sarcocysts need to be examined in camels.

Epidemiology of sarcocystosis in camels

The prevalence of sarcocystosis in camels has been reported from different regions of the world, including the Middle East, Africa and Asia (Table 2). Natural infections with *Sarcocystis* spp. in camels are usually asymptomatic (Hosseini *et al.* 2010; Mandour *et al.* 2011; Hamidinejat *et al.* 2013; Abd-Elmalek *et al.* 2015; Omer *et al.* 2017), despite the presence of significant histopathology in affected tissues (Valinezhad *et al.* 2008). The prevalence of sarcocystosis in camels has been estimated in Afghanistan (61%), Iran (52–84%), Egypt (23–64%), Jordan (22%), Kazakhstan (32%), Saudi Arabia (28–88%), Somalia (82%) and Sudan (81%) (Table 2). Furthermore, infection rates may vary considerably among different organs examined (Supplementary Table S1). In general, the probability of detecting a sarcocyst increases when more than one organ is examined (Woldemeskel and Gumi, 2001). However, the prevalence of sarcocystosis may vary in different studies depending on the differences in diagnostic methods used, sampling location, animal age, type of organs/tissue(s) analysed and the number of samples studied. Thus, these factors should carefully be evaluated when comparing the prevalence data from different studies.

Herd management practices, including sanitary conditions and the presence of dogs, play a crucial role in the epidemiology of *Sarcocystis* in camels as the infection depends on the frequency of contact between camels and dogs (or their excreta). For instance, sarcocystosis has been reported more frequently in areas where camels are reared in the presence of pastoral dogs (Woldemeskel and Gumi, 2001; Valinezhad *et al.* 2008). Similar findings have been reported for the presence of higher *Sarcocystis* infection rates in llamas (another camelid) kept with pastoral dogs and under poor sanitary conditions (Romero *et al.* 2017; Saeed *et al.* 2018). Likewise, road-side slaughter and

Table 3. Experimental studies on *Sarcocystis* spp. infecting dromedary camels.

Species of <i>Sarcocystis</i> ^a	Geographical location	Experimental animal ^b	No. of animals infected	Infective tissue/material used	Infective dose	Prepatent period (days)	Sporocyst size (μm)	Reference
<i>S. cameli</i>	Egypt	Dog	3	Camel meat	250–500 g	10–11	12–14 × 8.9–11.3	Hilali et al. (1992)
	Egypt	Dog	14	Camel meat	500 g	NA	12 × 9	Hilali et al. (1982)
	Egypt	Dog	3	Camel meat	250 g	10–14	12 × 9	Hilali and Mohamed (1980)
	Kazakhstan	Dog	3	Camel meat	300 g	8–10	14 × 11	Kuraev (1981)
	Saudi Arabia	Camel	2	Sporocysts	25 × 10 ⁴ , 75 × 10 ⁴	NA	NA	Fatani et al. (1996)
	Saudi Arabia	Dog	2	Camel meat	500 g	7	10.7–14.3 × 8.3–10.7	Hilali et al. (1995)
	Sudan	Camel	3	Sporocysts	1 × 10 ⁴	NA	NA	Ishag et al. (2006)
Dog		6	Camel meat	400 g	9–13	13.2–13.6 × 6.5–9.5		
<i>S. camelicanis</i>	Egypt	Dog	13	Camel meat	NA	11	13.7–15.6 × 7.8–10.7	Abdel-Ghaffar et al. (2009)
	Sudan	Camel	3	Sporocysts	1 × 10 ² , 10 ⁵ , 10 ⁶	NA	NA	Ishag (2003)
		Dog	6	Camel meat	400 g	9–13	16.0 × 9.9–11.5	Ishag et al. (2006)
		Camel	3	Sporocysts	1 × 10 ⁴	NA	NA	
<i>S. miescheri</i>	Egypt	Dog	2	Camel meat	NA	13–15	8.7–14.4 × 8.5–11.6	Mandour et al. (2011)
<i>Sarcocystis</i> spp.	Saudi Arabia	Dog	2	Camel meat	500 g	9–10	10.7–14.3 × 8.3–10.7	Fatani et al. (1996)
	Sudan	Camel	2	Sporocysts	1 × 10 ⁶	NA	NA	Manal et al. (2001)

NA, not available/applicable.

^aThe name used by the authors.

^bCats were also used as an experimental animal in some studies although they were found refractory to experimental infection.

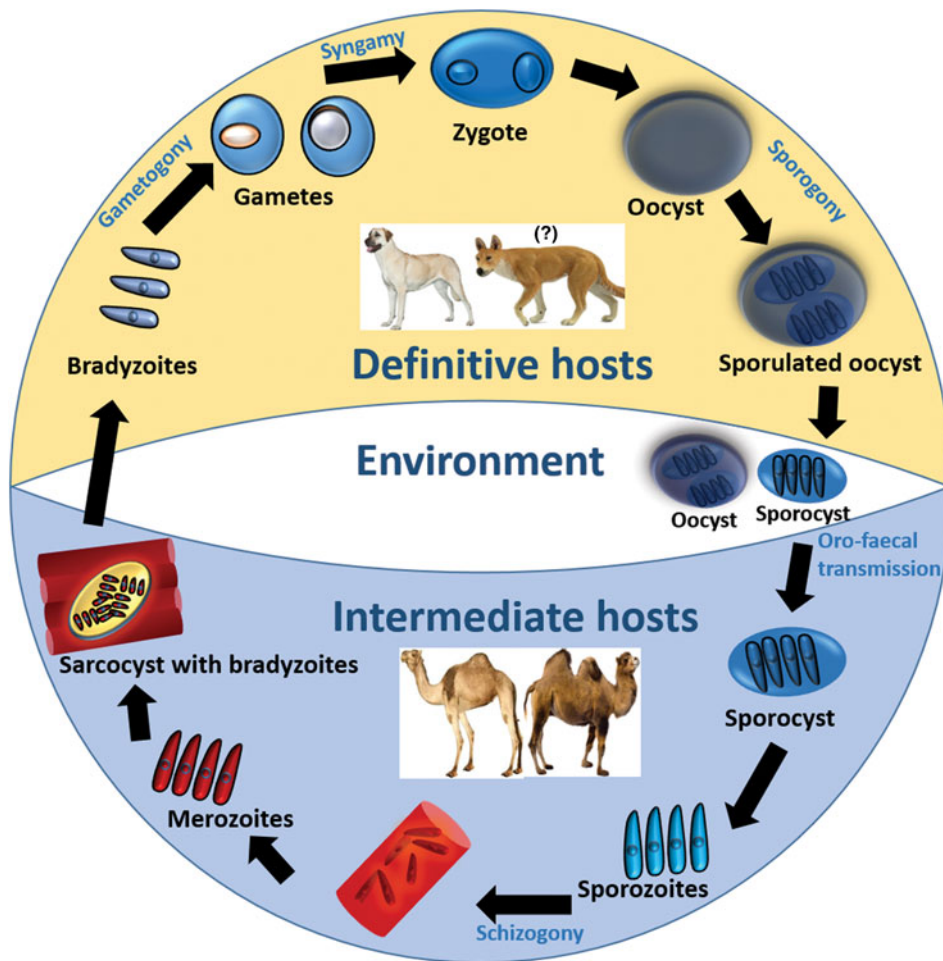


Fig. 1. Life cycle of *Sarcocystis* spp. in camels.

disposal of camel carcasses in the wild are common practices in developing countries and facilitates easy access of dogs and wild carnivores to infected tissues. This increases the likelihood of shedding sporocysts in feces of these animals which could contaminate camel feed and water (Woldemeskel and Gumi, 2001).

Longevity in camels has been found to be associated with *Sarcocystis* infections as older animals have had a long time to be exposed to oocysts/sporocysts in infected pastures. For example, a higher prevalence of sarcocystosis was observed in adult (e.g. 8–12 years) camels than young (e.g. < 2 years) ones from different parts of the world (Fatani *et al.* 1996; Latif *et al.* 1999; Al-Quraishy *et al.* 2004; Shekarforoush *et al.* 2006; Hamidinejat *et al.* 2013; Omer *et al.* 2017). No significant variation was observed in infection rates between male and female camels in many studies (Woldemeskel and Gumi, 2001; Shekarforoush *et al.* 2006; Valinezhad *et al.* 2008; Hamidinejat *et al.* 2013), however, a higher prevalence was recently reported in female camels (Omer *et al.* 2017). This may have been due to a difference in age rather than sex, as all males used in this study were 2–4 years younger than females (Omer *et al.* 2017). Studies in other camelids, such as alpacas and llamas, have shown that females are more susceptible to *Sarcocystis* infections, possibly due to their lower immunity during gestation and around parturition (Romero *et al.* 2017; Saeed *et al.* 2018). However, further investigations are required to test this hypothesis in camels.

Diagnosis of sarcocystosis in camels

Diagnosis of acute sarcocystosis in camels is challenging due to the lack of a commercial standard diagnostic test, asymptomatic or generalized nature of the disease and the presence of hidden

(microscopic) sarcocysts. Virtually all camels, regardless of clinical involvement, have been reported with some microscopic sarcocysts in muscles during meat inspection (Table 2). However, a variety of conventional methods, including muscle squash, muscle squeeze, pepsin digestion, trypsin digestion and histopathological examination have been used for the diagnosis of microscopic sarcocysts in camels. The muscle squash method involves a firm crushing of small pieces of meat between two glass slides and the muscle squeeze method uses a metal instrument to crush and squeeze muscle tissue to obtain the fluid for microscopic examination (Latif *et al.* 1999; Latif and Khamas, 2007; Mandour *et al.* 2011). Enzymatic digestion of muscle using pepsin or trypsin enzymes or histological examination of tissues are other commonly used methods to study microscopic sarcocysts in camels (Valinezhad *et al.* 2008; Abdel-Ghaffar *et al.* 2009; Hamidinejat *et al.* 2013; Omer *et al.* 2017). It is important to consider that some of these methods could produce superior results to others. For instance, pepsin or trypsin digestion methods were found to be more sensitive than muscle squash/squeeze or histological diagnostic methods (Borrow *et al.* 1989; Latif *et al.* 1999; Omer *et al.* 2017). This could be due to the use of larger pieces of muscle during enzymatic digestion steps allowing the release of a larger number of bradyzoites for microscopic examination.

The molecular diagnosis could be another useful method for the detection of *Sarcocystis* spp.; however, there is a paucity of information on the molecular diagnosis of *Sarcocystis* spp. in camels. The first molecular identification of *S. cameli* was undertaken for microscopic sarcocysts in camels from Iran where the 18S rRNA gene fragment was amplified from bradyzoite DNA using conventional polymerase chain reaction (PCR) followed

by sequencing (GenBank: GU074011.1) and restriction fragment length polymorphism (RFLP) analyses (Motamedi *et al.* 2011; Eslampanah *et al.* 2016). The RFLP method was more cost-effective than DNA sequencing or electron microscopic procedures. Recently, the 18S rRNA fragment was amplified from microscopic sarcocysts in camels, although no phylogenetic analyses were provided (Omer *et al.* 2017). This indicates that extensive studies are required to bridge the knowledge gap on molecular profiling of *Sarcocystis* spp. which could provide a foundation to develop a molecular test for the diagnosis of these parasites in camels.

Molecular detection of sarcocysts is invaluable in identifying *Sarcocystis* spp.; however, this holds little value as an early diagnostic method in camels since the DNA is extracted from a developed cyst at necropsy. Studies are required to develop a molecular test for the detection of *Sarcocystis* spp. from blood, and this could be an invaluable diagnostic tool for early diagnosis of sarcocystosis in camels.

Control of sarcocystosis in camels

Anticoccidial drugs have been trialled to treat intestinal stages of *Sarcocystis* spp. during acute infections not only in camels and other intermediate hosts but also in their definitive hosts. For example, camels treated with amprolium were protected from the severe form of experimental sarcocystosis (Ishag *et al.* 2006). The prophylactic use of salinomycin protected sheep from experimental infections with *Sarcocystis* sp. (Leek and Fayer, 1983). Similarly, halofuginone reduced the severity or prevented disease in sheep and goats infected with *Sarcocystis* spp. (Dubey *et al.* 2015a). Given that it is not possible to diagnose acute sarcocystosis under field conditions and these drugs only affect intestinal stages of the parasite, chemotherapy holds little or no value in treating muscular sarcocystosis in camels. Furthermore, some antiparasitic drugs (such as salinomycin) may be highly toxic to camels, causing weakness, limb incoordination and even mortality (Anderson, 2008).

Immunisation against *Sarcocystis* spp. could be another solution to protect camels and other intermediate hosts from sarcocystosis; however, no commercial vaccines are available thus far. Immunisation studies in cattle, sheep, goats and pigs indicate that animals inoculated with small numbers of sporocysts exhibited protective immunity against a subsequent challenge with *Sarcocystis* spp. (Fayer and Dubey, 1984; Ford, 1985; Abdel-Baki *et al.* 2009). Thus, the development of a vaccine against *Sarcocystis* spp. in camels and other domestic animals is practicable. However, a thorough understanding of the immune mechanisms underlying host–pathogen interactions is crucial for the development of a successful vaccine against *Sarcocystis* spp. and this aspect has been completely overlooked in camels. Given that no vaccine is available against sarcocystosis and chemotherapy might not be effective, preventative measures provide the only practical solution to protect camels against *Sarcocystis* spp.

In camels, the main method of *Sarcocystis* transmission appears to be an environment contaminated with dog/carnivore feces facilitating the fecal–oral route. Therefore, the disruption of this cycle is essential to break the life cycle and control sarcocystosis in camels. The following steps could be undertaken to potentially disrupt the *Sarcocystis* life cycle in camels: (a) camel feed/water and bedding storage areas should be kept free from dogs and wild carnivores and their excreta; (b) dogs should not be fed with uncooked/untreated camel meat as it may contain sarcocysts; freezing or boiling could significantly reduce or eliminate sarcocysts in camelid meat (Godoy *et al.* 2007; Saeed *et al.* 2018); and (c) any camel tissues, including carcasses and placental/fetal

material, should be buried or incinerated to prevent ingestion by definitive hosts such as dogs and wild carnivores (d) abattoirs and slaughtering plots should be kept free from stray dogs.

Conclusions and future directions

Sarcocystosis is a parasitic disease of camels. Camels serve as an intermediate host for at least two morphologically distinct *Sarcocystis* spp., *S. cameli* and *S. ippeni*. Both *Sarcocystis* spp. can form microscopic sarcocysts which appear in diaphragmatic, oesophageal, cardiac and skeletal muscles; however, *S. cameli* can also produce macroscopic sarcocysts. Sarcocystosis usually remains asymptomatic, although significant pathologies have been observed in affected camels. Animal age, the presence of pastoral dogs and poor sanitary conditions are the main predisposing factors for sarcocystosis in camels. Several conventional methods, including muscle squash/squeeze, pepsin/trypsin digestion and histopathological examination are used for the diagnosis of *Sarcocystis* spp. in camels, however, no methods are available for an early diagnosis of *Sarcocystis* spp. Furthermore, prevention is the only pragmatic approach to control sarcocystosis in camels as there is no effective treatment once an animal is infected.

This article provides an in-depth analysis of the existing knowledge on sarcocystosis in camels; however, several aspects of sarcocystosis in camels require further investigations. For instance, sarcocystosis has not been well-studied in the Bactrian (two-humped) camel, although one study reported *Sarcocystis* in Bactrian camels from Kazakhstan (Kuraev, 1981). Similarly, little is known about sarcocystosis in camels from other regions of Asia (e.g., China, India and Pakistan) and Africa (e.g., Somalia) which represents the highest population of dromedary camels in the world. Furthermore, the prevalence data on macroscopic sarcocysts and the susceptibility of different breeds of camels are scarce. Further studies are required to improve our understanding of the impact of sarcocystosis on camel health and reproductive performance, meat production and productivity, predisposition to other diseases and associated economic losses.

The taxonomy of *Sarcocystis* spp. infecting camels is primarily based on the morphological characterization of the cyst wall of sarcocysts and no molecular methods have been used in this regard. The cyst walls of *S. cameli* and *S. ippeni* are characterized by finger-like and conical villar protrusions, respectively. Morphological features of sarcocysts may be affected by factors such as the age of cyst, the location of cyst within the host, and the tissue processing/fixation methods; therefore, the description of a new *Sarcocystis* sp. using morphological characters (e.g. the structure of cyst wall) only, could be insufficient and may create confusion during species identification processes. For instance, various shapes of villar protrusions (conical, finger-like and stubby) were observed within the same sarcocyst (Dubey *et al.* 2015b) (see Fig. 5 in this paper). Furthermore, the ‘thick or thin’ cyst wall character also varied in different studies (Table 1), although various authors described a similar shape of villar protrusions (Al-Quraishy *et al.* 2004; Abdel-Ghaffar *et al.* 2009; Mandour *et al.* 2011; Abd-Elmalek *et al.* 2015; Dubey *et al.* 2015b, 2017). This likely explains why there are at least six different names for *Sarcocystis* spp. that infect camels. For instance, Dubey *et al.* (2015b), characterized and named only thin-walled *Sarcocystis* spp. and did not include any thick-walled sarcocysts from camels which may point towards the existence of more than two *Sarcocystis* spp. and leave taxonomic classification as subject to change based on the availability of more information. Another limitation of these studies is the use of small number and old (stored for decades) cyst samples to describe new species of *Sarcocystis* in camels (Dubey *et al.* 2015b, 2017). Thus, it is essential to utilize molecular characterization besides morphological

criteria, with large numbers of fresh samples, including both thick- and thin-walled sarcocysts for more authentic and robust taxonomy of *Sarcocystis* spp. that infect camels.

Based on experimental infection studies, dogs are known as definitive hosts for *Sarcocystis* spp. that infect camels (Abdel-Ghaffar *et al.* 2009). However, sarcocystosis has also been reported from camels in Ethiopia in the absence of dogs (Woldemeskel and Gumi, 2001), suggesting that other carnivores (e.g. wild canids) could also serve as the potential definitive host for these parasites and warrants for further studies. Little is known about the developmental stages (e.g. merozoites, bradyzoites, microgametes, microgametes, etc.) of *Sarcocystis* spp. in both camels and dogs. Experimental infection studies are required to improve our understanding of the developmental stages of *Sarcocystis* spp. in camels as well as their definitive host(s) for designing effective control strategies.

The lack of standard diagnostic tests is another major hindrance to fully understand the disease biology of *Sarcocystis* spp. in camels. Since microscopic sarcocysts (the most common form reported) are hidden within muscles of the camel, sensitive diagnostic tools are required to detect *Sarcocystis* preferably from body fluids (e.g. blood) for an early diagnosis of *Sarcocystis* in these animals. Serological methods have been developed for the determination of anti-*Sarcocystis* antibodies in sera of other camelid hosts such as alpacas and llamas (Viscarra *et al.* 2003; More *et al.* 2008; Romero *et al.* 2017). A high inter-species cross-reactivity was observed among different *Sarcocystis* spp. of ruminants in these studies, highlighting the possibility of developing a similar serological test for the diagnosis of sarcocystosis in camels. Likewise, a range of molecular methods has been developed for the evaluation of genetic diversity as well as the diagnosis of *Sarcocystis* spp. in other animals (Stojecki *et al.* 2012). For instance, a semi-nested PCR has been developed to detect *Sarcocystis* DNA, allowing the detection of as low as 100 bradyzoites per mL of llama blood (Martin *et al.* 2016). Experimental infection studies in cattle have shown that *Sarcocystis* merozoites can be detected in buffy coat preparations from infected animals as early as the third week of infection (Dubey *et al.* 2015a). Although this method holds little value for the routine diagnosis of *Sarcocystis* spp. in animals due to the short time merozoites circulate in the blood soon after initial infection, this highlights the possibility of detecting *Sarcocystis* DNA from camel blood with regular PCR. However, none of these methods has been trialled for early diagnosis of sarcocystosis in camels.

As mentioned earlier, the only known species with zoonotic potential include *S. hominis*, *S. heydorni* and *S. sui hominis* (Poulsen and Stensvold, 2014; Dubey, 2015). Despite a high prevalence of *Sarcocystis* spp. in camels, their zoonotic potential and public health significance have not been evaluated. It has been suggested that the consumption of uncooked meat infected with *Sarcocystis* could cause gastrointestinal and respiratory problems in humans (Leguía, 1991; Poulsen and Stensvold, 2014). Similarly, camelid meat infected with *Sarcocystis* spp. can produce a pronounced pathology in dogs and toxicity in rabbits (Leguía, 1991; Godoy *et al.* 2007; Vilca *et al.* 2013). However, the impact of *Sarcocystis*-infected camel meat on human or animal (i.e., dog) health remains an untouched area of study. Physical and chemical methods have been utilized to treat infected camelid meat to neutralize the toxicity and the viability of sarcocysts. For instance, boiling (100 °C for 10 min), baking (105 °C for 65 min), and frying methods were used to decontaminate llama meat infected with *Sarcocystis* and fed to young dogs (Godoy *et al.* 2007; Vilca *et al.* 2013). The puppies that ate treated meat did not excrete any sporocysts in their feces unlike those who received untreated meat. These results indicate that boiling, baking and freezing could be applied to neutralize the viability of

sarcocysts. Similar studies are required in camels to assess the effectiveness of these methods to decontaminate camel meat infected with *Sarcocystis* spp.

Our knowledge on sarcocystosis in camels is limited and further studies are required to understand the epidemiology and disease biology of *Sarcocystis* spp. and their impact on camel health, immunity, reproduction and productivity. The development of validated serological and molecular diagnostic tools for the early detection of *Sarcocystis* spp. from body fluids (e.g. blood) in camels would be a breakthrough in parasitology research. Molecular characterization of *Sarcocystis* spp. infecting camels could assist in developing an early diagnostic test, describing a more authentic taxonomy and determining phylogenetic relationships of these parasites with *Sarcocystis* spp. from other camelid hosts as well as other coccidian protozoa.

Supplementary material. The supplementary material for this article can be found at <https://doi.org/10.1017/S0031182018000239>.

Acknowledgements. We are grateful to Professor Ian Beveridge for the translation of articles in French language. We are thankful to Miss Sahar T. Shairani for her technical assistance.

Financial support. This research received no specific grant from any funding agency, commercial or not-for-profit sectors.

References

- Abdel-Baki AA, Allam G, Sakran T and El-Malah EM (2009) Lambs infected with UV-attenuated sporocysts of *Sarcocystis ovis* produced abnormal sarcocysts and induced protective immunity against a challenge infection. *The Korean Journal of Parasitology* **47**, 131–138.
- Abdel Ghaffar F, Entzeroth R, Chobotar B and Scholtyssek E (1979) Ultrastructural studies of *Sarcocystis* sp. from the camel (*Camelus dromedarius*) in Egypt. *Tropenmedizin und Parasitologie* **30**, 434–438.
- Abdel-Ghaffar F, Mehlhorn H, Bashtar AR, Al-Rasheid KAS, Sakran T and El-Fayoumi H (2009) Life cycle of *Sarcocystis camelicanis* infecting the camel (*Camelus dromedarius*) and the dog (*Canis familiaris*), light and electron microscopic study. *Parasitology Research* **106**, 189–195.
- Abd-Elmalek B, Abed G and Mandour A (2015) Study on *Sarcocystis* sp. by light and electron microscopy in camel muscles at Assiut governorate. *Journal of Veterinary Science and Technology* **6**. doi: 10.4172/2157-7579.1000266.
- AbuBakar S, Teoh BT, Sam SS, Chang LY, Johari J, Hooi PS, Lakhbeer-Singh HK, Italiano CM, Omar SFS and Wong KT (2013) Outbreak of human infection with *Sarcocystis nesbitti*, Malaysia, 2012. *Emerging Infectious Diseases* **19**, 1989–1991.
- Al-Ani FK and Amr Z (2017) *Sarcocystis* spp prevalence in camel meat in Jordan. *Journal of Dairy & Veterinary Sciences* **4**, 1–3.
- Al-Quraishy S, Bashtar A, Al-Rasheid K and Abdel-Ghaffar F (2004) Prevalence and ultrastructure of *Sarcocystis* species infecting camels (*Camelus dromedaries*) slaughtered in Riyadh city, Saudi Arabia. *Saudi Journal of Biological Sciences* **11**, 135–141.
- Anderson DE (2008) Ionophores: salinomycin toxicity in camelids. In Fowles ME (ed.). *Zoo and Wild Animal Medicine* (6th edn). Amsterdam, Netherlands: Elsevier, pp. 50–54.
- Borrow HA, Mohammed HA and Di Sacco B (1989) *Sarcocystis* in Somali camels. *Parassitologia* **31**, 133–136.
- Dubey J, Calero-Bernal R, Rosenthal B, Speer C and Fayer R (2015a) *Sarcocystosis of Animals and Humans*, 2nd edn. Florida, USA: CRC Press.
- Dubey JP (2015) Foodborne and waterborne zoonotic sarcocystosis. *Food and Waterborne Parasitology* **1**, 2–11.
- Dubey JP, Speer C and Fayer R (1989) *Sarcocystosis of Animals and Man*. Florida, USA: CRC Press.
- Dubey JP, Hilali M, Van Wilpe E, Calero-Bernal R, Verma SK and Abbas IE (2015b) A review of sarcocystosis in camels and redescription of *Sarcocystis cameli* and *Sarcocystis ippeni* sarcocysts from the one-humped camel (*Camelus dromedarius*). *Parasitology* **142**, 1481–1492.
- Dubey JP, A'Aji NN, Mowery JD, Verma SK and Calero-Bernal R (2017) Identification of macroscopic sarcocysts of *Sarcocystis cameli* from one-

- humped camels? (*Camelus dromedarius*) in Iraq. *Journal of Parasitology* **103**, 168–169.
- El-Etreby M (1970) Myocardial sarcosporidiosis in the camel. *Pathologia Veterinaria* **7**, 7–11.
- Entzeroth R, Ghaffar FA, Chobotar B and Scholtzsek E (1980) Fine structural study of *Sarcocystis* sp. from Egyptian camels (*Camelus dromedarius*). *Acta Veterinaria Academiae Scientiarum Hungaricae* **29**, 335–339.
- Eslampanah M, Motamedi GR, Dalimi A, Noori A, Habibi GR, Aghaeepour K and Niroumand M (2016) Study of camel and goat *Sarcocystis* by electron microscopic and PCR-RFLP. *Veterinary Researches Biological Products (Pajouhesh-Va-Sazandegi)* **29**, 77–84.
- FAOSTAT (2016) Food and Agriculture Organization of the United Nations. Available at <http://www.fao.org/faostat/en/#data/QL>.
- Fatani A, Elsebaie A and Hilali M (1996) Clinical and haematobiochemical changes in camels (*Camelus dromedarius*) experimentally inoculated with *Sarcocystis cameli*. *Journal of Camel Practice and Research* **3**, 11–15.
- Faye B (2014) The camel today: assets and potentials. *Anthropozoologica* **49**, 167–176.
- Fayer R (2004) *Sarcocystis* spp. in human infections. *Clinical Microbiology Reviews* **17**, 894–902.
- Fayer R and Dubey J (1984) Protective immunity against clinical sarcocystosis in cattle. *Veterinary Parasitology* **15**, 187–201.
- Ford G (1985) Immunity of sheep to homologous challenge with dog-borne *Sarcocystis* species following varying levels of prior exposure. *International Journal for Parasitology* **15**, 629–634.
- Fukuyo M, Battsetseg G and Byambaa B (2002) Prevalence of *Sarcocystis* infection in meat-producing animals in Mongolia. *Southeast Asian Journal of Tropical Medicine and Public Health* **33**, 490–495.
- Godoy Z, Vilca L, Gonzáles Z, Leyva V and Sam T (2007) Saneamiento y detoxificación de carne de llama (*Lama glama*) infectada con *Sarcocystis aucheniae* mediante cocción, horneado, fritura y congelado. *Revista de Investigaciones Veterinarias del Perú* **18**, 51–56.
- Hamidinejat H, Hekmatimoghaddam S, Jafari H, Sazmand A, Haddad Molayan P, Derakhshan L and Mirabdollahi S (2013) Prevalence and distribution patterns of *Sarcocystis* in camels (*Camelus dromedarius*) in Yazd province, Iran. *Journal of Parasitic Diseases* **37**, 163–165.
- Hidron A, Vogenthaler N, Santos-Preciado JI, Rodríguez-Morales AJ, Franco-Paredes C and Rassi A (2010) Cardiac involvement with parasitic infections. *Clinical Microbiology Reviews* **23**, 324–349.
- Hilali M and Mohamed A (1980) The dog (*Canis familiaris*) as the final host of *Sarcocystis cameli* (Mason, 1910). *Tropenmedizin und Parasitologie* **31**, 213–214.
- Hilali M, Imam E and Hassan A (1982) The endogenous stages of *Sarcocystis cameli* (Mason, 1910). *Veterinary Parasitology* **11**, 127–129.
- Hilali M, Nassar AM and Elghaysh A (1992) Camel (*Camelus dromedarius*) and sheep (*Ovis aries*) meat as a source of dog infection with some coccidian parasites. *Veterinary Parasitology* **43**, 37–43.
- Hilali M, Fatani A and Al-Atiya S (1995) Isolation of tissue cysts of *Toxoplasma*, *Isospora*, *Hammondia* and *Sarcocystis* from camel (*Camelus dromedarius*) meat in Saudi Arabia. *Veterinary Parasitology* **58**, 353–356.
- Hosseini S, Ataie A, Rahimi E and Jafarian M (2010) Prevalence of sarcocystosis in camel in Najafabad slaughterhouse. *Journal of Veterinary Pathobiology* **1**, 41–47.
- Hussein HS and Warrag M (1985) Prevalence of *Sarcocystis* in food animals in the Sudan. *Tropical Animal Health and Production* **17**, 100–101.
- Ishag MY (2003) *Studies on Toxoplasma and Sarcocystis from Camels (Camelus dromedaries) in the Sudan*. Thesis, University of Khartoum, Sudan.
- Ishag MY, Majid A and Magzoub A (2006) Isolation of a new *Sarcocystis* species from Sudanese camels (*Camelus dromedarius*). *International Journal of Tropical Medicine* **1**, 167–169.
- Kadim I, Mahgoub O and Purchas R (2008) A review of the growth, and of the carcass and meat quality characteristics of the one-humped camel (*Camelus dromedaries*). *Meat Science* **80**, 555–569.
- Kadim I, Mahgoub O and Mbaga M (2014) Potential of camel meat as a non-traditional high quality source of protein for human consumption. *Animal Frontiers* **4**, 13–17.
- Kirmse P and Mohanbabu B (1986) *Sarcocystis* sp. in the one-humped camel (*Camelus dromedarius*) from Afghanistan. *British Veterinary Journal* **142**, 73–74.
- Kumar M, Vyas I, Dadhich H, Rani S, Mathur M, Sharma S, Saini K and Kumar S (2016) Occurrence and pathology of upper gastrointestinal parasites in camel (*Camelus dromedaries*). *Veterinary Practitioner* **17**, 176–177.
- Kuraev G (1981) Sarcocystosis of camels in Kazakhstan (in Russian). *Veterinaria* **7**, 41–42.
- Latif B and Khamas W (2007) Light and ultrastructural morphology of sarcocystosis in one-humped camels (*Camelus dromedarius*) in Northern Jordan. *Journal of Camel Practice and Research* **14**, 45–48.
- Latif BMA, Al-Delemi JK, Mohammed BS, Al-Bayati SM and Al-Amiry AM (1999) Prevalence of *Sarcocystis* spp. in meat-producing animals in Iraq. *Veterinary Parasitology* **84**, 85–90.
- Lau YL, Chang PY, Tan CT, Fong MY, Mahmud R and Wong KT (2014) *Sarcocystis nesbitti* infection in human skeletal muscle: possible transmission from snakes. *The American Journal of Tropical Medicine and Hygiene* **90**, 361–364.
- Leek RG and Fayer R (1983) Experimental *Sarcocystis oivicanis* infection in lambs: Salinomycin chemoprophylaxis and protective immunity. *The Journal of Parasitology* **69**, 271–276.
- Leguia G (1991) The epidemiology and economic impact of llama parasites. *Parasitology Today* **7**, 54–56.
- Manal YI, El Amin E and Osman A (2001) Camels experimentally infected with *Sarcocystis*. *The Sudan Journal of Veterinary Research* **17**, 27–33.
- Mandour A, Rabie S, Mohammed N and Hussein N (2011) On the presence of *Sarcocystis miescheri* sp. nov. in camels of Qena governorate. *Egyptian Academic Journal of Biological Sciences* **3**, 1–7.
- Martin M, Franco CD, Romero S, Carletti T, Schnittger L and Florin-Christensen M (2016) Molecular detection of *Sarcocystis aucheniae* in the blood of llamas from Argentina. *Revista Argentina de Microbiología* **48**, 200–205.
- Mason FE (1910) Sarcocysts in the camel in Egypt. *Journal of Comparative Pathology and Therapeutics* **23**, 168–176.
- Miescher F (1843) Über eigenthümliche Schläuche in den Muskeln einer Hausmaus. *Verhandlungen der Naturforschenden Gesellschaft in Basel* **5**, 198–202.
- Miller M, Barr B, Nordhausen R, James E, Magargal S, Murray M, Conrad P, Toy-Choutka S, Jessup D and Grigg M (2009) Ultrastructural and molecular confirmation of the development of *Sarcocystis neurona* tissue cysts in the central nervous system of southern sea otters (*Enhydra lutris nereis*). *International Journal for Parasitology* **39**, 1363–1372.
- More G, Pardini L, Basso W, Marin R, Bacigalupe D, Auad G, Venturini L and Venturini MC (2008) Seroprevalence of *Neospora caninum*, *Toxoplasma gondii* and *Sarcocystis* sp. in llamas (*Lama glama*) from Jujuy, Argentina. *Veterinary Parasitology* **155**, 158–160.
- Motamedi GR, Dalimi A, Nouri A and Aghaeipour K (2011) Ultrastructural and molecular characterization of *Sarcocystis* isolated from camels? (*Camelus dromedarius*) in Iran. *Parasitology Research* **108**, 949–954.
- Odening K (1997) Die *Sarcocystis*-Infektion: Wechselbeziehungen zwischen freilebenden Wildtieren, Haustieren und Zootieren. *Zoologische Garten* **67**, 317–340.
- Omer SA, Alzurairi AA and Mohammed OB (2017) Prevalence and molecular detection of *Sarcocystis* spp. infection in the dromedary camel (*Camelus dromedarius*) in Riyadh city, Saudi Arabia. *Biomedical Research India* **28**, 4962–4965.
- Poulsen CS and Stensvold CR (2014) Current status of epidemiology and diagnosis of human sarcocystosis. *Journal of Clinical Microbiology* **52**, 3524–3530.
- Rahbari S, Bazargani T and Rak H (1981) Sarcocystosis in the camel in Iran. *Journal of Faculty of Veterinary Medicine University of Tehran* **37**, 1–10.
- Rao GR, Sharma R and Shah H (1997) Occurrence of sarcocystis in the camel (*Camelus dromedarius*) in India. *Indian Veterinary Journal* **74**, 426.
- Romero S, Carletti T, Franco CD, Moré G, Schnittger L and Florin-Christensen M (2017) Seropositivity to *Sarcocystis* infection of llamas correlates with breeding practices. *Veterinary Parasitology* **10**, 65–70.
- Saeed MA, Rashid MH, Vaughan J and Jabbar A (2018) Sarcocystosis in South American camelids: The state of play revisited. *Parasites and Vectors* (in press).
- Shekarforoush SS, Shakerian A and Hasanpoor MM (2006) Prevalence of *Sarcocystis* in slaughtered one-humped camels (*Camelus dromedarius*) in Iran. *Tropical Animal Health and Production* **38**, 301–303.
- Stojecki K, Karamon J, Sroka J and Cenczek T (2012) Molecular diagnostics of *Sarcocystis* spp. infections. *Polish Journal of Veterinary Sciences* **15**, 589–596.
- Tenter AM (1995) Current research on *Sarcocystis* species of domestic animals. *International Journal for Parasitology* **25**, 1311–1330.

- Valinezhad A, Oryan A and Ahmadi N** (2008) *Sarcocystis* and its complications in camels (*Camelus dromedarius*) of Eastern provinces of Iran. *Korean Journal of Parasitology* **46**, 229–234.
- Vilca M, Durán J, Ramos D and Lucas J** (2013) Saneamiento y eliminación de la toxicidad de carne de alpaca (*Vicugna pacos*) con sarcocistiosis mediante ahumado y curado. *Revista de Investigaciones Veterinarias del Perú* **24**, 537–543.
- Viscarra R, Rushton J, González A and López T** (2003) Validation of a serological test for sarcocystiosis in llamas found in the Bolivian High Andes. In *Las memorias del 10 Symposium Internacional de Epidemiología y Economía Veterinaria. Viña del mar, Chile*, vol. **17**.
- Vounba P** (2010) *Etude de la prévalence de la sarcosporidiose musculaire du Dromadaire (Camelus dromedarius) aux abattoirs de N'djamena (Tchad) et de Nouakchott (Mauritanie)*. Thèse pour obtenir le grade de Docteur Vétérinaire (Diplôme D'état), Faculté de Médecine, de Pharmacie et d'Odonto-Stomatologie de Dakar, Dakar (Senegal), 100 p.
- Wernery U, Kinne J and Schuster RK** (2014) *Camelid Infectious Disorders*. Paris, France: OIE (World Organisation for Animal Health) Press.
- Woldemeskel M and Gumi B** (2001) Prevalence of sarcocysts in one-humped camels (*Camelus dromedarius*) from southern Ethiopia. *Journal of Veterinary Medicine* **48**, 223–226.