

Original Article

Cite this article: Chi SH, Mok YE, Kang J, Gim J-A, and Lee M-S. (2025) Network hub changes in the pars opercularis indicate impaired inhibition in tic disorder patients. *Acta Neuropsychiatrica*. 37(e6), 1–6. doi: [10.1017/neu.2024.53](https://doi.org/10.1017/neu.2024.53)

Received: 18 April 2024
Revised: 4 October 2024
Accepted: 14 October 2024

Keywords:

Tic disorders; tourette Syndrome; magnetic resonance imaging; brain; brain mapping

Corresponding author:

Moon-Soo Lee; Email: npboard@korea.ac.kr

Network hub changes in the pars opercularis indicate impaired inhibition in tic disorder patients

SuHyuk Chi¹ , Young Eun Mok¹, June Kang², Jeong-An Gim³ and Moon-Soo Lee¹ 

¹Department of Psychiatry, Korea University Guro Hospital, Seoul, Korea; ²Department of Brain and Cognitive Engineering, Korea University, Seoul, Korea and ³Department of Medical Science, Soonchunhyang University, Asan-si, Chungcheongnam-do, Korea

Abstract

Objective: This study aimed to utilise graph theory to explore the functional brain networks in individuals with tic disorders and to investigate resting-state functional connectivity changes in critical brain regions associated with tic disorders. **Methods:** Participants comprised individuals with tic disorders and age-matched healthy controls, ranging from 6 to 18 years old, all recruited from Korea University Guro Hospital. We ensured a medication-naïve cohort by excluding participants exposed to psychotropic medications for at least three weeks prior to the study. Data included structural and resting-state functional MRI scans, analysed with the CONN-fMRI Functional Connectivity toolbox v20b. The analysis included 22 patients (18 males, 4 females) and 26 controls (14 males, 12 females). **Results:** Significantly increased global efficiency was observed in the left inferior frontal gyrus pars opercularis among tic disorder patients compared to controls. Furthermore, this region displayed enhanced resting-state functional connectivity with its right counterpart in patients versus controls. **Conclusion:** The inferior frontal gyrus pars opercularis, known for its inhibitory role, may reflect adaptive functional adjustments in response to tic symptoms. Increased hubness of the inferior frontal gyrus pars opercularis possibly represents functional adjustments in response to tic symptoms. The identified brain region with increased efficiency and connectivity presents a promising avenue for further research into tic expression and control mechanisms.

Significant outcomes

- The left inferior frontal gyrus pars opercularis of tic disorder patients shows increased global efficiency compared to controls.
- The left inferior frontal gyrus pars opercularis shows enhanced resting-state functional connectivity with its right counterpart in patients compared to controls.

Limitations

- The small number of enrolled patients is a limitation of this study.
- The cross-sectional nature of our study precluded the verification of our results over a prospective period.

Introduction

Tic disorders typically manifest at an early age and involve repetitive, involuntary movements or vocal sounds. They are notably prevalent with an incidence rate as high as 5.6% (Knight *et al.*, 2012). The most severe manifestation of tic disorders is called Tourette syndrome, characterised by the concurrence of motor and vocal tics for over one year. While not life-threatening, tic disorders are associated with impaired self-esteem, social life, and academic performance. These issues may persist into adulthood, adversely influencing career choices and interpersonal relationships. Tic disorders are also linked to a higher prevalence of attention-deficit hyperactivity disorder (ADHD), which can independently lead to various psychiatric and behavioural problems. These challenges significantly impact not only the patients but often their entire families.

Our current understanding of tic disorders, derived from various imaging, genetic, and postmortem studies, suggests that tic disorders are associated with abnormalities in the corticospinal tract, particularly within the striatum. Imaging studies documented decreases in volume in the striatum and the globus pallidus in patients with tic disorders (Makki *et al.*, 2009;

© The Author(s), 2025. Published by Cambridge University Press on behalf of Scandinavian College of Neuropsychopharmacology. This is an Open Access article, distributed under the terms of the Creative Commons Attribution licence (<http://creativecommons.org/licenses/by/4.0/>), which permits unrestricted re-use, distribution and reproduction, provided the original article is properly cited.



Y. Worbe *et al.*, 2015). Intriguingly, an ongoing study on tic disorder patients reported that the severity of the condition was predicted not by striatal volumes but by hippocampal volumes (Black *et al.*, 2020). A relatively recent study proposed a model dividing the underlying mechanism into two discrete networks: the expression network and the control network (Yael *et al.*, 2015). The expression network, associated with behavioural symptoms, includes motor-related areas such as the pre- and primary motor cortices, putamen, and limbic areas, as highlighted by functional magnetic resonance imaging (fMRI) studies (Neuner *et al.*, 2014). Conversely, the control network, which modulates the expression of these behavioural symptoms, is thought to encompass the frontal cortical areas. This hypothesis is supported by a study showing correlations between tic suppression and increased regional homogeneity of the left inferior frontal gyrus (Ganos *et al.*, 2014). Premonitory urges, on the other hand, are believed to span both networks, mediated by sensory and limbic brain regions (Neuner *et al.*, 2014; Z. Wang *et al.*, 2011). Church *et al.* also investigated the resting-state functional connections in 33 adolescents with tic disorder and 210 healthy individuals and found that patients showed many less mature functional connections in the fronto-parietal network and the cingulo-operculo network (Church *et al.*, 2009). The authors defined 'maturity' as how developed each functional brain connection is in the patient group compared to typical development in people without the disease. Such defects in brain maturation was further supported by a study on the functional connectivity of 59 adult Tourette syndrome patients and 27 controls, revealing stronger functional integration and global disorganisation in sensory motor, associative, and limbic cortico-basal ganglia networks among patients (Yulia Worbe *et al.*, 2012).

Our research endeavoured to extend these earlier studies by employing graph theory to conceptualise the brain as a network of interconnected nodes. Investigations on animal brains deduced that nervous systems possess properties of small-world networks, making them suitable for analysis using graph theory (Watts and Strogatz, 1998; Hilgetag *et al.*, 2000). The advent of fMRI facilitated practical applications of graph theoretical analysis on the human brain. Early studies already reported small-world structures within cortical and subcortical regions of the brain network (Salvador *et al.*, 2005). This methodology has been adopted in various clinical studies, exploring a range of psychiatric disorders, such as depression and schizophrenia, in greater depth (Su *et al.*, 2015; Ye *et al.*, 2015). The application of network analysis offers a comprehensive perspective on the brain's connectivity, capturing both anatomical pathways and correlations in activity, providing a more nuanced understanding of whole-brain effective connectivity and the inherent dynamics of brain activity (Gilson *et al.*, 2019; J. Wang *et al.*, 2010). This was applied in tic disorder research by Wen *et al.*, who constructed whole-brain, region of interest (ROI)-level functional connectivity networks for 29 drug-naïve tic disorder children and 37 healthy controls, and used graph theory to investigate topological disruptions (Wen *et al.*, 2018). The identified regions involved the sensorimotor, visual, language, and default-mode areas. They also analysed white matter networks in 44 tic disorder children and 41 healthy controls, finding that patients exhibited decreased global and local efficiency, increased path length, and disrupted network balance (Wen *et al.*, 2017).

Despite this extensive amount of existing research, a comprehensive understanding of this complex disorder remains elusive. This study aimed to investigate the resting-state functional neuroimaging data of tic disorder patients through a data-driven

network analysis followed by a hypothesis-driven functional connectivity analysis of the prior results.

Material and methods

Participants and clinical measures

A total of 39 patients with tic disorder and 37 healthy controls were initially enrolled in the study. All participants were between the ages of 6 and 18, psychotropic medication free for at least 3 weeks, and had no history of neurologic disorders including head trauma, tumours, or seizures. Patients were clinically diagnosed with tic disorders (Tourette's disorder, persistent motor or vocal tic disorder, provisional tic disorder, other specified tic disorder, and unspecified tic disorder) based on the 5th edition of the Diagnostic and Statistical Manual of Mental Disorder (DSM-5) by child and adolescent psychiatrists. Intelligence quotients of all patients and controls were examined using the Korean version of the Wechsler Intelligence Scale for Children fourth edition (K-WISC-IV). Patients were recruited from the department of psychiatry of Korea University Guro Hospital. Healthy controls were recruited from local schools and kindergartens.

Patients were assessed using the Korean version of the Kiddie-Schedule for Affective Disorders and Schizophrenia-Present and Lifetime Version (K-SADS-PL) for psychiatric comorbidities, and the Yale Global Tic Severity Scale (YGTSS) for tic disorder symptom severity.

The research processes were approved by the Institutional Review Board (IRB) of the Korea University Guro Hospital (2021GR0275). All research methods were performed in accordance with the relevant guidelines and regulations. Written consent was obtained from parents or legal guardians of each participant.

Functional MRI image acquisition

Participants were instructed to close their eyes but stay awake, relax, and remain motionless throughout the scan. The head was stabilised using sponges, and sedatives were administered in case of excessive movement. A 3.0-Tesla Siemens MR scanner (MAGNETOM Prisma; SIEMENS Healthineers, Erlangen, Germany) at Korea University Guro Hospital was used. Structural data were scanned using a T1-weighted magnetisation-prepared rapid gradient-echo sequence (repetition time: 2,300 ms; echo time: 2.32 ms; inversion time: 900 ms; flip angle: 8°; field of view: 230 mm; voxel size: 0.9 mm isotropic; 208 slices; generalised auto-calibrating partially parallel acquisition acceleration factor: factor of two along the phase-encoding direction; received bandwidth per pixel: 200 Hz/pixel; echo spacing: 7.1 ms). Resting-state fMRI scans were acquired through 200 contiguous echo-planar imaging volumes of the whole brain (repetition time: 2,000 ms; echo time: 30 ms; flip angle: 70°; field of view: 224 mm; voxel size: 2.0 mm isotropic; multi-slice mode; interleaved; simultaneous multi-slice factor: three; phase-encoding shift factor: two; received bandwidth per pixel: 2,480 Hz/pixel; echo spacing: 0.55 ms). Images were manually inspected for abnormalities and artefacts.

Brain image preprocessing and analysis

Data were preprocessed and analysed using the CONN-fMRI Functional Connectivity toolbox v20b (Whitfield-Gabrieli and Nieto-Castanon, 2012) (<http://www.nitrc.org/projects/conn>),

MATLAB R2019a (MathWorks, Natick, MA, USA), and SPM12 (The Wellcome Department of Cognitive Neurology, London, UK, <http://www.fil.ion.ucl.ac.uk/spm/software/spm12>). All sequences were preprocessed using the default pipeline of the CONN toolbox to remove physiological confounds such as head movements: resampling to 2-mm voxels, realigning, unwarping, centring, slice time correction, normalisation using the Montreal Neurological Institute (MNI) echo-planar imaging template, smoothing using an 8-mm Gaussian kernel, and outlier detection. Data were denoised, and signal data from the cerebrospinal fluid and white matter were regressed out and processed with a band-pass filter of 0.008–0.09 Hz to reduce noise effects from physiological sources and scanner drift. Additional image scrubbing, using ART (artefact detection tools) in the CONN toolbox with a frame-wise displacement threshold of 0.5, outlier timepoints at 97th percentiles, global signal Z-scores of 5, and linear de-trending were performed.

Statistical analysis

ROI-to-ROI maps for the whole brain were constructed using the toolbox. All ROIs were defined using the toolbox, based on the Harvard-Oxford atlas. The mean time series of each seed region was used as a predictor in a multiple regression general linear model at each ROI. An analysis of covariance controlling for age, sex, and IQ was performed between the patients and controls. Graph theory parameters of the whole brain network were calculated using the toolbox with a false discovery rate (FDR) adjusted $p < 0.05$ as the threshold. The following parameters were analysed.

Degree

Degree refers to the number of edges from/to each node. It represents a measure of network centrality, showing the degree of local connectedness of the ROI (Nieto-Castanon, 2020).

Betweenness centrality

Betweenness centrality also represents the centrality of a node. It is the proportion of times that a certain node is part of a shortest-path between any two nodes within the graph (Nieto-Castanon, 2020).

Global efficiency

Global efficiency is the average of inverse-distances between a node and all other nodes in the network. It represents a measure of centrality within the network, showing the degree of global connectedness of the node (Nieto-Castanon, 2020).

Local efficiency

Local efficiency refers to the global efficiency of a node within the neighbouring sub-graph of the node. It represents a measure of local coherence (Nieto-Castanon, 2020).

ROIs that showed significant differences in the data-driven network analysis were considered to have high/low centrality within the network and were selected as seed areas for a hypothesis-driven ROI-to-ROI resting-state functional connectivity (rsFC) analysis. The threshold for ROI-to-ROI connections was set as uncorrected $p < 0.05$ for assessing statistical significance.

Statistical analyses of clinical and demographic data were performed using SPSS version 23 (IBM Corp., Armonk, NY, USA).

Table 1. Demographics and clinical measures

	Patients ($n = 22$)	Controls ($n = 26$)	p -value
Sex (male/female)	18/4	14/12	
Age	10.36 ± 2.84	10.15 ± 2.15	0.772
IQ	96.45 ± 9.16	102.62 ± 10.05	0.033*
YGTSS	24.73 ± 7.81	0 ± 0	<0.001*
Comorbid ADHD	6	0	

* $p < 0.05$.

Table 2. Network analysis and ROI-to-ROI analysis between patients and controls

ROI	β	T	p -FDR	p -unc
Global efficiency				
Inferior frontal gyrus pars opercularis, left	0.06	3.96	0.0428	0.0003
ROI-to-ROI				
Inferior frontal gyrus pars opercularis, left to Inferior frontal gyrus pars opercularis, right		2.05	0.9996	0.0464

Abbreviations: ROI, region of interest; p -FDR, false discovery rate adjusted p -value; p -unc, uncorrected p -value.

The significance level was set at $p < 0.05$. Means and standard deviations for demographic and clinical data were calculated.

Results

Demographics and clinical characteristics

Several enrolled participants were excluded from analysis based on our exclusion criteria. Out of the 39 patients one patient was excluded due to an IQ under 70, one patient was excluded due to co-diagnosis of obsessive-compulsive disorder (OCD), two patients were excluded due to imaging artefacts, and 13 patients failed to undergo a full MRI scan due to motion artefacts. Two out of the 37 controls were reassigned to the patient group after clinical assessment, one participant was excluded due to poor image quality, and eight failed to undergo MRI scans. A total of 22 patients (14 males, 4 females) and 26 controls (13 males, 9 females) were included in the final analysis, and 6 patients were co-diagnosed with ADHD. Details are shown in table 1.

Network analysis between patients and controls

All four graph theory measures were analysed for all ROIs. Degree, betweenness centrality, and local efficiency did not show any significant differences between patients and controls. The left inferior frontal gyrus pars opercularis showed significantly higher global efficiency in the patient group ($\beta = 0.06$, $T = 3.96$, p -FDR = 0.0428). All graph theory measures did not show significant associations with YGTSS scores or other clinical measures. Table 2 shows statistical details and Fig. 1 shows a graphical representation.

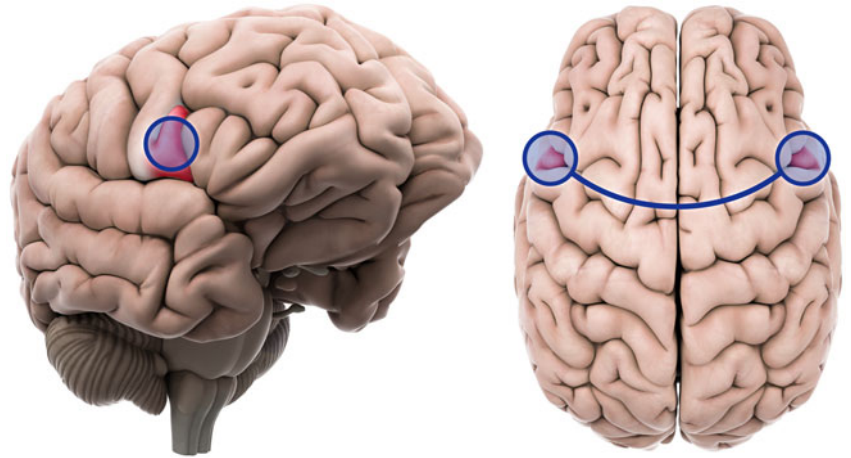


Figure 1. The inferior frontal gyrus pars opercularis showing significantly increased network hubness and resting state functional connectivity in tic disorder patients. Left: inferior frontal gyrus pars opercularis, left. Right: inferior frontal gyrus pars opercularis, both.

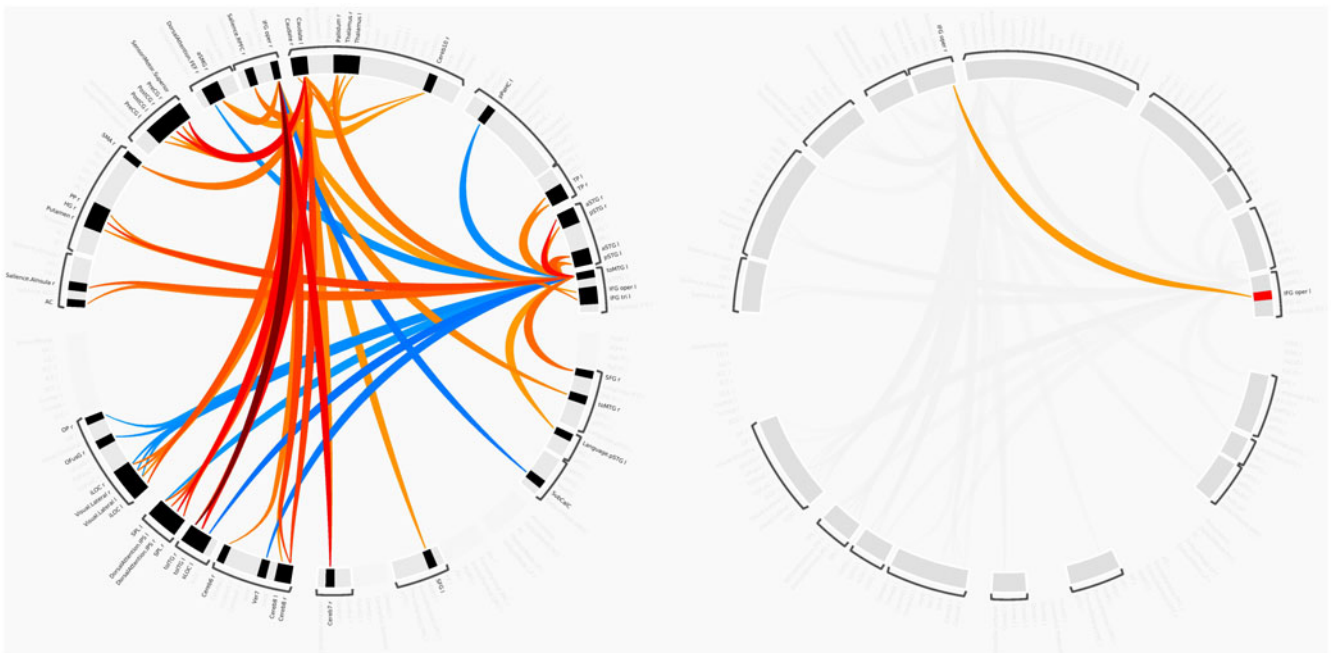


Figure 2. ROI-to-ROI connectome ring. Left: connectome ring of all significant ROI-to-ROI interactions; right: significant connection between left and right inferior frontal gyrus pars opercularis.

ROI-to-ROI analysis between patients and controls

Tic disorder patients and healthy controls showed different functional connectivities between various brain areas. ROIs with significant centrality were used as seed ROIs for analysis. The rsFC between the left inferior frontal gyrus pars opercularis and the right inferior frontal gyrus pars opercularis ($T = 2.05$, $p = 0.0464$) was shown to be higher in the patient group. Table 2 includes detailed statistics on the ROI-to-ROI analysis and Fig. 1 shows a graphical representation. Fig. 2 shows connectome ring representations of the ROI of significant network centrality, as well as the connectome ring of all significant rsFC differences between patients and controls.

Discussion

One of the strengths of this study is in the participant selection. Although it is not a perfectly homogeneous group, efforts to

maintain the highest possible level of homogeneity aimed to minimise the variability typically seen in more diverse groups. This approach ensures that the observed neuroimaging patterns are more confidently attributed to tic disorders rather than confounded by other co-existing psychiatric conditions. It is already widely known that a notable subset of tic disorder patients is co-diagnosed with OCD. Decades of research have been invested on this topic, and even though a clear explanation has yet to be provided, we are aware that tic disorder patients, OCD patients, and patients with both disorders show many significant differences (Coffey *et al.*, 1998; Lebowitz *et al.*, 2012). We therefore decided to only include patients without OCD to maximise homogeneity.

Our analysis revealed heightened network centrality within the left inferior frontal gyrus pars opercularis. This elevated centrality indicates that this region exhibits increased hubness in patients with tic disorders, suggesting its enhanced significance within their neural network. The pars opercularis is the part of the inferior

frontal gyrus that is posterior to the ascending ramus of the lateral sulcus, overlying the insular cortex. This region was known to associate with recognising spoken language as it overlaps with a segment of Broca's area (Schremm *et al.*, 2018) and was also believed to play a central role in executive control and cognitive inhibition (Aron *et al.*, 2004). Recent advancements in neuroimaging have underscored the significance of this region in inhibitory controls (Swick *et al.*, 2008). Notably, lesions in the right inferior frontal gyrus have been correlated with deficits in stop-signal inhibition (Aron *et al.*, 2003). A non-invasive study employing theta burst transcranial magnetic stimulation on this region also revealed augmented inhibitory control in patients with nicotine addiction (Newman-Norlund *et al.*, 2020). Based on these and other related studies, it has been concluded that this region is posited to have a unique association with motor inhibition. Interestingly, the inhibitory function of the right inferior frontal gyrus appears to manifest predominantly in later stages of life, while the left inferior frontal gyrus demonstrates heightened inhibitory activity in children (Bunge *et al.*, 2002). Similar to its right counterpart, lesions of the left inferior frontal gyrus were also linked to deficits in GoNoGo tasks (Swick *et al.*, 2008). Altogether, these findings highlight the critical role of both right and left inferior frontal gyri in response inhibition, a hallmark characteristic that is affected in tic disorder. A recent study observing increased surface curvature of the pars opercularis and the pars triangularis in tic disorder patients compared to controls further substantiates this assertion (McCann *et al.*, 2022). The authors also suggested that abnormalities of this region are possibly associated with vocal tics, since damage to this area may give rise to hesitant speech that is also evident in Broca's aphasia, but it has to be noted that the brain regions responsible for language and inhibition do not completely overlap, and there is still a lack of research supporting the idea that regions associated with language also play a role in inhibition. A diffusion tensor imaging (DTI) study on adults with tic disorder showed decreased fractional anisotropy of several brain regions including the left pars opercularis, further suggesting that alterations of this area are related to the inhibitory impairments in tic disorder (Müller-Vahl *et al.*, 2014). This was also demonstrated in a study that observed impaired ability to stop an action while the right pars opercularis was temporarily deactivated by repetitive transcranial magnetic stimulation (Chambers *et al.*, 2006). Collectively, these findings suggest the pars opercularis's involvement in the inhibitory mechanism governing tics. Increased hubness of this area can be hypothesised to be an acquired change in response to frequent motor tics during the developmental ages. This 'secondary neuroplastic compensatory mechanism' in tic disorders was already proposed by many researchers including Müller-Vahl and others (Müller-Vahl *et al.*, 2014). Such compensatory adaptations are thought to result from continuous tic suppression, also possibly linked to the known decline of tic symptoms with increasing age (Peterson *et al.*, 2001).

A study by Openneer *et al.*, also investigated the brain network of tic disorder by comparing patients with tic disorder, ADHD, and healthy controls (Openneer *et al.*, 2020). Patients were also divided into groups with and without a co-diagnosis of ADHD. The authors reported that tic disorder patients with ADHD showed lower local efficiency and clustering coefficients in the default-mode network compared to controls, and in the fronto-parietal network when compared to ADHD patients. The pars opercularis, which was significant in our study, does not traditionally belong to one of those networks, so our results do not exactly match those of Openneer *et al.*, Our results show increased network centrality in

tic disorder patients whereas Openneer *et al.*, reported decreased network centrality in the patient group. Of course, it must be noted that the two studies had different patient groups (all tic disorder patients vs. only tic disorder patients with ADHD), but the different results indicate that tic disorder is a complicated mixture of various brain activities.

Our study is not without limitations. First, the small number of enrolled patients is a major limitation of all tic disorder studies. The young age and frequent movement inherent to tic disorder patients make it difficult to obtain high quality MRI data. Nonetheless, it is crucial to highlight the high homogeneity and drug-naïve status of our patient group. Second, the cross-sectional design of the study made it impossible to verify our results through a prospective time period. Third, it can be observed that the YGTSS scores of the enrolled patients are not very high. In addition, to participate in the study, children and adolescents with motor tics had to be able to lie still and cooperate with the MRI for a certain amount of time. This was a limiting factor for participants with severe, uncontrolled tics. Therefore, some participants with severe tics were not able to participate in the study. This contributed to lower YGTSS scores in those who were able to participate. Fourth, there is a gender imbalance in the study population. While it is expected that more males are affected due to the nature of the disorder, it is undeniable that a more balanced sample would have been more appropriate for the study.

We did not separate patients with comorbid ADHD. Although some previous studies suggested that tic disorders with comorbid ADHD may have different pathophysiological mechanisms compared to those without ADHD, these patients were not excluded due to practical constraints in the study design. In future research, we aim to address this by using a larger sample size to enable such a distinction. Nevertheless, our study suggests that the brains of tic disorder patients may exhibit different developmental traces when compared to controls, as they are continuously inhibiting tics during their developmental ages. These findings will aid in unveiling the pathophysiology of tic disorders. Further research and follow-up studies are necessary to verify our results and to develop clinical applications.

Conclusion

This study revealed that tic disorder patients have increased network hubness in the left inferior frontal gyrus pars opercularis. This region also showed higher rsFC with its right counterpart in the patient group relative to controls. This area is considered to be linked with inhibitory mechanisms, and its increased hubness could be associated to the constant suppression of frequent tics during developmental years.

Data availability. Please contact the corresponding author for data and material.

Acknowledgements. None.

Author contributions. S.C contributed to drafting and data analysis.

Y.M., J.K., and J.G. contributed to data gathering and data analysis.

M.L. contributed to drafting and managed the whole project.

All authors reviewed and approved the final manuscript.

Financial support. This research was supported by a grant from the Korea Health Technology R&D Project through the Korea Health Industry Development Institute (KHIDI), funded by the Ministry of Health & Welfare, Republic of Korea (grant number: HI21C0012).

Competing interests. The authors declare none.

Ethics standard. The research processes were approved by the Institutional Review Board (IRB) of the Korea University Guro Hospital (2021GR0275). All research methods were performed in accordance with the relevant guidelines and regulations.

Consent to participate. Written informed consent was obtained from parents or legal guardians (if parents not available) of all participants.

Consent for publication. Written informed consent for publishing was obtained from parents or legal guardians (if parents not available) of all participants.

References

- Aron AR, Fletcher PC, Bullmore ET, Sahakian BJ and Robbins TW (2003) Stop-signal inhibition disrupted by damage to right inferior frontal gyrus in humans. *Nature Neuroscience* 6(2), 115–116.
- Aron AR, Robbins TW and Poldrack RA (2004) Inhibition and the right inferior frontal cortex. *Trends in Cognitive Sciences* 8(4), 170–177.
- Black KJ, Kim S, Schlaggar BL and Greene DJ (2020) The new tics study: a novel approach to pathophysiology and cause of tic disorders. *Journal of Psychiatry and Brain Science* 5, e200012.
- Bunge SA, Dudukovic NM, Thomason ME, Vaidya CJ and Gabrieli JD (2002) Immature frontal lobe contributions to cognitive control in children: evidence from fMRI. *Neuron* 33(2), 301–311.
- Chambers CD, Bellgrove MA, Stokes MG, Henderson TR, Garavan H, Robertson IH, Morris AP and Mattingley JB (2006) Executive “brake failure” following deactivation of human frontal lobe. *Journal of Cognitive Neuroscience* 18(3), 444–455.
- Church JA, Fair DA, Dosenbach NU, Cohen AL, Miezin FM, Petersen SE and Schlaggar BL (2009) Control networks in paediatric tourette syndrome show immature and anomalous patterns of functional connectivity. *Brain* 132(1), 225–238.
- Coffey BJ, Miguel EC, Biederman J, Baer L, Rauch SL, O’Sullivan RL, Savage CR, Phillips K, Borgman A, Green-Leibovitz MI, Moore E, Park KS and Jenike MA (1998) Tourette’s disorder with and without obsessive-compulsive disorder in adults: are they different? *Journal of Nervous and Mental Disease* 186(4), 201–206.
- Ganos C, Kahl U, Brandt V, Schunke O, Bäumer T, Thomalla G, Roessner V, Haggard P, Münchau A and Kühn S (2014) The neural correlates of tic inhibition in Gilles de la Tourette syndrome. *Neuropsychologia* 65, 297–301.
- Gilson M, Kouvaris NE, Deco G, Mangin JF, Poupon C, Lefranc S, Rivière D and Zamora-López G (2019) Network analysis of whole-brain fMRI dynamics: a new framework based on dynamic communicability. *Neuroimage* 201, 116007.
- Hilgetag CC, Burns GA, O’Neill MA, Scannell JW and Young MP (2000) Anatomical connectivity defines the organization of clusters of cortical areas in the macaque monkey and the cat. *Philosophical Transactions of the Royal Society of London. Series B, Biological Sciences* 355(1393), 91–110.
- Knight T, Steeves T, Day L, Lowerison M, Jette N and Pringsheim T (2012) Prevalence of tic disorders: a systematic review and meta-analysis. *Pediatric Neurology* 47(2), 77–90.
- Lebowitz ER, Motlagh MG, Katsovich L, King RA, Lombroso PJ, Grantz H, Lin H, Bentley MJ, Gilbert DL, Singer HS, Coffey BJ, Kurlan RM and Leckman JF (2012) Tourette syndrome in youth with and without obsessive compulsive disorder and attention deficit hyperactivity disorder. *European Child & Adolescent Psychiatry* 21(8), 451–457.
- Makki MI, Govindan RM, Wilson BJ, Behen ME and Chugani HT (2009) Altered fronto-striato-thalamic connectivity in children with tourette syndrome assessed with diffusion tensor MRI and probabilistic fiber tracking. *Journal of Child Neurology* 24(6), 669–678.
- McCann B, Lam MY, Shiohama T, Ijner P, Takahashi E and Levman J (2022) Magnetic resonance imaging demonstrates gyral abnormalities in tourette syndrome. *International Journal of Developmental Neuroscience* 82(6), 539–547.
- Müller-Vahl KR, Grosskreutz J, Prell T, Kaufmann J, Bodammer N and Peschel T (2014) Tics are caused by alterations in prefrontal areas, thalamus and putamen, while changes in the cingulate gyrus reflect secondary compensatory mechanisms. *BMC neuroscience* 15(1), 1–10.
- Neuner I, Werner CJ, Arrubla J, Stöcker T, Ehlen C, Wegener HP, Schneider F and Shah NJ (2014) Imaging the where and when of tic generation and resting state networks in adult tourette patients. *Frontiers in Human Neuroscience* 8, 362.
- Newman-Norlund RD, Gibson M, McConnell PA and Froeliger B (2020) Dissociable effects of theta-burst repeated transcranial magnetic stimulation to the inferior frontal gyrus on inhibitory control in nicotine addiction. *Frontiers in Psychiatry* 11, 260.
- Nieto-Castanon A (2020) *Handbook of functional connectivity magnetic resonance imaging methods in CONN*. Boston, MA: Hilbert Press
- Openneer TJC, Marsman JC, van der Meer D, Forde NJ, Akkermans SEA, Naaïjen J, Buitelaar JK, Dietrich A and Hoekstra PJ (2020) A graph theory study of resting-state functional connectivity in children with tourette syndrome. *Cortex* 126, 63–72.
- Peterson BS, Staib L, Scahill L, Zhang H, Anderson C, Leckman JF, Cohen DJ, Gore JC, Albert J and Webster R (2001) Regional brain and ventricular volumes in tourette syndrome. *Archives of general psychiatry* 58(5), 427–440.
- Salvador R, Suckling J, Coleman MR, Pickard JD, Menon D and Bullmore E (2005) Neurophysiological architecture of functional magnetic resonance images of human brain. *Cerebral Cortex (New York, NY)* 15(9), 1332–1342.
- Schremm A, Novén M, Horne M, Söderström P, van Westen D and Roll M (2018) Cortical thickness of planum temporale and pars opercularis in native language tone processing. *Brain and Language* 176, 42–47.
- Su TW, Hsu TW, Lin YC and Lin CP (2015) Schizophrenia symptoms and brain network efficiency: a resting-state fMRI study. *Psychiatry Research* 234(2), 208–218.
- Swick D, Ashley V and Turken AU (2008) Left inferior frontal gyrus is critical for response inhibition. *BMC Neuroscience*. 9(1), 102.
- Wang J, Zuo X and He Y (2010) Graph-based network analysis of resting-state functional MRI. *Frontiers in Systems Neuroscience*. 4, 16.
- Wang Z, Maia TV, Marsh R, Colibazzi T, Gerber A and Peterson BS (2011) The neural circuits that generate tics in tourette’s syndrome. *American Journal of Psychiatry* 168(12), 1326–1337.
- Watts DJ and Strogatz SH (1998) Collective dynamics of ‘small-world’ networks. *Nature* 393(6684), 440–442.
- Wen H, Liu Y, Rekić I, Wang S, Chen Z, Zhang J, Zhang Y, Peng Y and He H (2018) Combining disrupted and discriminative topological properties of functional connectivity networks as neuroimaging biomarkers for accurate diagnosis of early tourette syndrome children. *Molecular neurobiology* 55(4), 3251–3269.
- Wen H, Liu Y, Rekić I, Wang S, Zhang J, Zhang Y, Peng Y and He H (2017) Disrupted topological organization of structural networks revealed by probabilistic diffusion tractography in tourette syndrome children. *Human Brain Mapping* 38(8), 3988–4008.
- Worbe Y, Malherbe C, Hartmann A, Péligrini-Issac M, Messé A, Vidailhet M, Lehericy S and Benali H (2012) Functional immaturity of cortico-basal ganglia networks in Gilles de la Tourette syndrome. *Brain* 135(6), 1937–1946.
- Worbe Y, Murrakhchi-Kacem L, Lecomte S, Valabregue R, Poupon F, Guevara P, Tucholka A, Mangin JF, Vidailhet M, Lehericy S, Hartmann A and Poupon C (2015) Altered structural connectivity of cortico-striato-pallido-thalamic networks in Gilles de la Tourette syndrome. *Brain* 138(Pt 2), 472–482.
- Yael D, Vinner E and Bar-Gad I (2015) Pathophysiology of tic disorders. *Movement Disorders* 30(9), 1171–1178.
- Ye M, Yang T, Qing P, Lei X, Qiu J and Liu G (2015) Changes of functional brain networks in major depressive disorder: a graph theoretical analysis of resting-state fMRI. *PLoS One* 10(9), e0133775.