

## Original Article

# Initial assessment of a novel delivery system (NuDEL™) for the covered Cheatham-Platinum stent

Gareth J. Morgan,<sup>1</sup> Damien Kenny,<sup>2</sup> Christopher Duke,<sup>3</sup> Kevin P. Walsh,<sup>2</sup> Shakeel A. Qureshi<sup>1</sup>

<sup>1</sup>Departments of Paediatric and Adult Congenital Cardiology, Evelina London Children's Hospital, Guy's and St Thomas' NHS Foundation Trust, King's College London, London, United Kingdom; <sup>2</sup>Department of Paediatric Cardiology, Our Lady's Hospital for Sick Children, Crumlin, Dublin, Ireland; <sup>3</sup>East Midlands Congenital Heart Centre, Glenfield Hospital, Leicester, United Kingdom

**Abstract** *Aims:* We sought to evaluate the first-in-man use of a new system for implantation of covered stents in patients with complex structural and CHD. *Methods and results:* Retrospective data were collected of the first 13 NuDEL™ delivery systems used in patients. The NuDEL™ comprises a covered Cheatham-Platinum stent mounted on a balloon-in-balloon and pre-loaded in a long delivery sheath. Data were collected from three centres in the United Kingdom and Ireland. A total of 13 covered stents were delivered via 12 NuDEL™ delivery systems in 12 patients. Among them, six patients had coarctation of the aorta, five patients had right ventricular outflow tract stenosis, and one patient had severe stenosis of a Mustard systemic venous baffle. There were no complications, and all the stents were deployed in the desired position with satisfactory haemodynamic results. *Conclusions:* The development of a bespoke system of a pre-mounted, pre-loaded covered stent may negate some of the technical challenges that complicate large-calibre stent deployment. Our preliminary results suggest that the NuDEL™ system is a safe and effective means of covered stent deployment in challenging anatomy.

**Keywords:** Covered stent; coarctation; right ventricular outflow tract stent; percutaneous pulmonary valve

Received: 14 December 2016; Accepted: 19 February 2017; First published online: 15 June 2017

STENT IMPLANTATION IN THE RIGHT VENTRICULAR outflow tract and for the treatment of coarctation of the aorta has become standard practice for congenital interventional cardiologists.<sup>1</sup> The range of stents available for these therapies has developed well over the last 10–15 years, allowing us to make semi-quantitative decisions about stent choice for each individual case.<sup>2</sup> Safety and accuracy of deployment are at least partially dependent on the precise mounting of the stent on its delivery balloon and passing it into and along the delivery sheath to its required position.<sup>3</sup>


Progress made in the field of CHD brings increasingly complex anatomy into the catheterisation laboratory. This often means that the most difficult part of the

procedure is getting the stent into the required anatomical position before deploying it.

A lot of time is taken in getting these essential steps right, and there is potential for safety, efficiency, and efficacy problems at every step. Slipping of the stents off balloons leading to migration of the stent before or during deployment and damage to the balloon or stent during mounting are some of the problems encountered, which may require re-crossing of the target areas, lead to vascular risk of removing and re-inserting a long, large-calibre sheath, and at worst can have major safety consequences. To this end, the NuDEL™ system has been developed (Numed Inc., Hopkinton, New York, United States of America) to streamline the delivery of covered stents.

The NuDEL™ system consists of a covered, 8-zig, Cheatham-Platinum stent mounted on a balloon-in-balloon system of matched length and prescribed diameter, loaded on a long, non-braided delivery

Correspondence to: Dr G. J. Morgan, Department of Congenital Cardiology, Children's Hospital of Colorado, University of Colorado, Denver, CO 80045, United States of America. Tel: +1 720 777 3379; Fax: +1 720 777 7177; E-mail: drgarethjmorgan@gmail.com



**Figure 1.** The NuDEL™ system. The stent and balloon complex are exposed by pulling the sheath back over the shaft of the balloon. Inset (a) illustrates the system fully covered; (b) illustrates the sheath partially withdrawn over the stent; and the main picture (c) shows the stent and balloon fully uncovered and ready to deploy.

sheath. The dilator of the sheath is replaced by a short (2 cm), tapered, rubber-nose cone, thermal-bonded to the end of the balloon shaft (Fig 1). Deployment of the stent is performed in three simple steps. First, once in position, the stent is fully uncovered by withdrawing the sheath guided by a distal fluoroscopic marker and markers placed on the proximal shaft of the balloon catheter. These markers define when the assembly is fully closed and when the stent and balloon have been fully uncovered by the sheath. The balloon-in-balloon is then inflated in the usual manner. After deployment and deflation of the balloon, the tip of the sheath should be brought back into contact with the nose cone, and the entire assembly is withdrawn over the wire.

Implantation of large-calibre, covered stents for the treatment of coarctation of the aorta and to prepare the right ventricular outflow tract for percutaneous valve implantation has become a major part of practice in congenital interventional cardiology. Increasingly challenging anatomical variations have forced us to use more innovative techniques to safely implant stents in these lesions.<sup>4</sup>

## Methods

We carried out a retrospective, multicentre study at two United Kingdom centres and one centre in Ireland. We gathered data from the first 12 patients in whom a NuDEL™ system was inserted to deliver a covered stent during the 12-month period between July, 2015 and June, 2016. Patient demographics, procedural details, and acute results were assessed. Observations on the behaviour of the system and any inherent problems were noted throughout each case. Data were gathered and analysed according to the institutional guidelines.

Individual consent for data acquisition was waived because of the retrospective nature of the study.

## Results

In this study, 12 NuDEL™ systems were used to deploy 13 stents in 12 patients. Among them, nine patients were treated at Evelina London Children's Hospital and Guy's and St Thomas' NHS Foundation Trust, two of them were treated at Our Lady's Hospital for Sick Children in Crumlin, Ireland, and one patient was treated at Glenfield Hospital in Leicester, United Kingdom. No record was found of any patient where a NuDEL™ system was unpacked and not deployed, according to clinician testimony and manufacturers' records. All the procedures were elective, and none of the cases involved emergency use of the NuDEL™ to deploy a covered stent – for example, in cases of conduit rupture. Among all patients, six of them had severe coarctation of the aorta – three of which were atretic and one was near atretic (<1 mm flow through the coarctation site on angiography). Only one patient had severe stenosis of a Mustard superior venous baffle, and the remaining six systems were used in cases of right ventricular outflow tract stenosis in preparation for percutaneous pulmonary valve implantation.

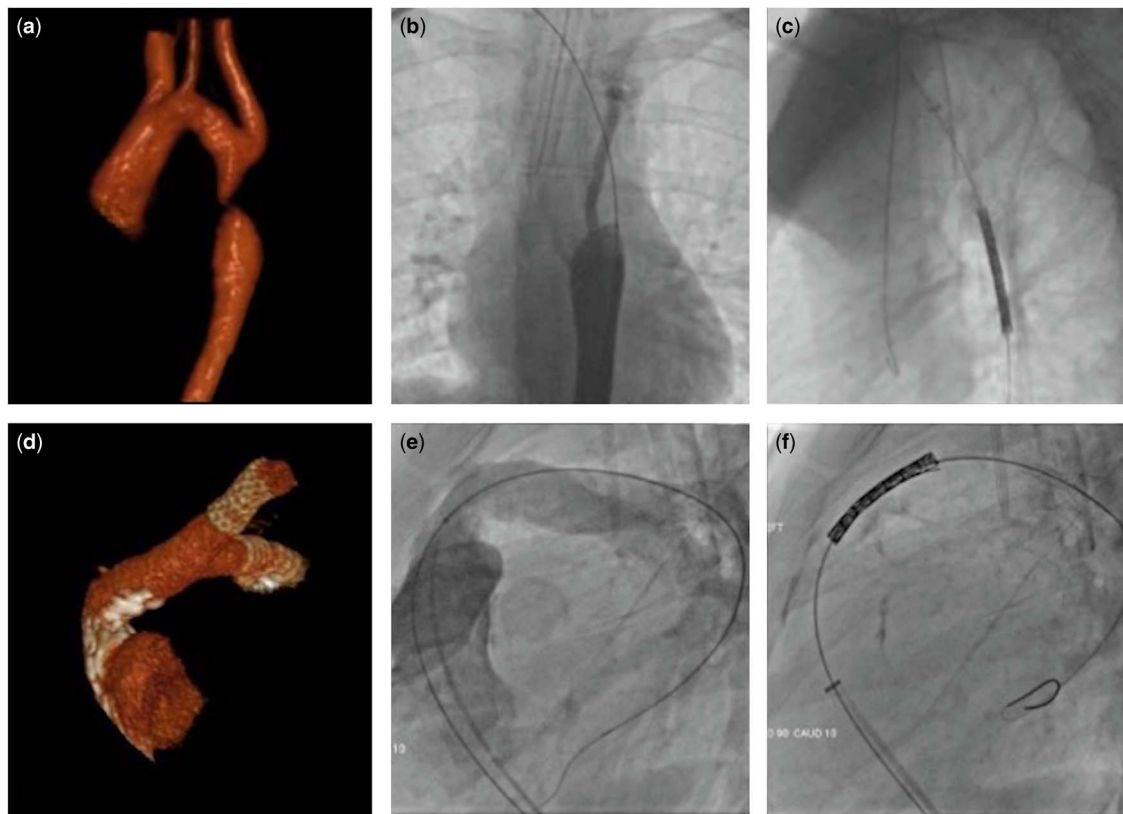
Table 1 illustrates patient details and procedural data of 11 patients. Figure 2 shows two examples of challenging anatomy in which the NuDEL™ was thought to confer significant advantage. In two patients (not shown), the delivery system was used to pass through a newly opened atretic descending aorta to place a covered stent. The atretic segments were first opened using radiofrequency energy, before passing the NuDEL™ system across, without the need for pre-dilation. There were no procedural complications and no reports of equipment failure or dysfunction. In three cases, after stent deployment, the nose cone and deflated balloon-in-balloon were pulled through the length of the NuDEL™ sheath to allow it to be used as a regular, long delivery system. The tip of the sheath was not damaged after this manoeuvre, but it did have an impact on the competency of the haemostatic valve. In these cases, the NuDEL™ sheath was then used to either deploy an additional stent or to position a high-pressure balloon to post-dilate the stent. Given the preliminary nature of this study, no quantification of the time saved by having a pre-loaded, pre-mounted stent was carried out. The system required minimal preparation – flushing only; therefore, despite a lack of familiarity, it was ready for deployment in each case in under 2 minutes after removing the packaging. Key positive feedback and observations (Table 1) were that the assembly tracked well through the access site and through tortuous and narrowed anatomy in either the

Table 1. Patient demographics and patient details.

Patient	Age (years)	Weight (kg)	Diagnosis	Specific indication	Minimum diameter (mm)	Target vessel diameter (mm)	Complication	Outer balloon diameter (mm)	Stent length (mm)	Sheath size (F)	Support wire	Comment
1	24	67	NaCoA	Near atresia	2	16	None	18	45	14	Superstiff	None
2	39	89	PAVSD	Conduit stenosis	18	23	None	24	45	16	Superstiff	Previous hand-crimped stent had slipped passing through the RVOT
3	24	48	NaCoA	Atretic	0	12	None	16	45	14	Superstiff	
4	22	54	PAVSD	Conduit stenosis	9	20	None	20	39	14	Superstiff	Extreme angulation of outflow
5	10	53	CoA	Severe re-coarctation	9	15	None	16	39	12	Extrastiff	
6	16	75	Ross	Conduit stenosis	11	20	None	20	45	14	Extrastiff	Complex stenosis
7	15	58	Tetralogy	RVOT patch stenosis	10	24	None	22	45	16	Lunderquist	
7					19	24	None	24	45	16	Lunderquist	Second stent placed to reinforce outflow tract
8	23	74	DORV; malposed	Conduit stenosis	9	18	None	18	39	14	Lunderquist	Extreme angulation of outflow
9	18	58	NaCoA	PDA coil in situ	12	16	None	16	39	12	Superstiff	
10	31	75	NaCoA	Atretic	0	18	None	16	45	12	Superstiff	RF perforation of atretic plate with subsequent passage of NuDEL
11	43	83	NaCoA	Severe coarctation	4	17	None	18	39	14	Superstiff	

CoA = coarctation of the aorta; DORV = double-outlet right ventricle; NaCoA = Native coarctation; PAVSD = pulmonary atresia ventricular septal defect; PDA = patent ductus arteriosus; RF = radio frequency; Ross = following Ross procedure for aortic valve disease; RVOT = right ventricular outflow

In total, 13 NuDEL™ systems were used to deploy 13 stents in 12 patients. Among them, three patients had angiographically atretic coarctation, retrograde and antegrade angiography, with two (patients 10 and 11) requiring RF perforation of the atretic segment. Patient 7 needed two NuDEL™ systems to provide additional support before percutaneous valve implantation



**Figure 2.**

*NuDEL™ being used in challenging anatomy. (a) Atretic aortic coarctation, which after being crossed with a wire (b) was then crossed without pre-dilation with the NuDEL™ system (c). (d and e) Highly angulated and calcified complex right ventricular outflow (RVOT). This was traversed easily with the NuDEL™ system (f) to allow placement of a covered Cheatham-Platinum in the RVOT before placing a percutaneous pulmonary valve.*

outflow tract or the descending aorta. The stent was easy to uncover, and the markers on the system provided added re-assurance to this process. Check angiography could be easily performed through the side-arm of the sheath. Key negative feedback (Table 1) including the distance from the tip of the balloon to the tip of the sheath of ~35 mm seemed excessive; this did not have any clinical impact on our patients. The nose cone also seemed to be made of very soft rubber, which may hinder the passage of the sheath through more challenging subcutaneous tissue at the access site or complex stenoses. Again this was not encountered in our group. In fact, the system tracked very smoothly even through the freshly perforated aortic atresia tract.

## Discussion

Our initial series suggests that the NuDEL™ system provides a safe, efficient method of deploying a covered stent in patients with complex outflow tract stenosis and those with aortic coarctation. Using this system avoids some of the pitfalls associated with stent mounting and management of the stent–balloon–delivery system complex. Most operators would have experienced a stent

slipping off the balloon during passage from the hub to the tip of the sheath, sometime associated with kinking of non-braided sheaths in tortuous anatomy, a phenomenon negated by this system.<sup>3,5</sup>

Conduit rupture is an anxiety-provoking potential complication; the availability of a “ready-to-go” covered stent system may provide an attractive emergency backup.<sup>6,7</sup> This may be of benefit to operators who perform a low volume of large-calibre stent procedures and are not conversant with the techniques involved, even in the elective setting.

There are some lessons from our brief experience that may influence any second iteration modifications to the system:

- Availability of an 80-cm as well as 100-cm working-length NuDEL™ sheath: this would provide greater flexibility in using the sheath to deploy other stents or balloons to post-dilate.
- The current system has a length of ~35 mm between the tip of the nose cone and the leading edge of the pre-mounted stent. Decreasing this distance would improve the ergonomics at the proximal end of the system as well as decrease the chances of problems with tracking the distal end of



the system in the branch pulmonary arteries for outflow tract stenting. A shorter gap would also allow unsheathing in coarctation patients to take place in the descending aorta and not in the transverse arch, potentially reducing the risk of cerebral thrombus or air embolism (Fig 2).

- Our impression was that too great a margin of error had been left for the sheath calibre, and that the sheath size could be reduced by at least a French size in each system.
- The technology is still based on the Mullins type of non-braided sheath. This was an excellent innovation in interventional practice 20 years ago; however, the tendency of the sheath to kink when it is being manoeuvred through challenging anatomy can cause significant problems. Consideration of braiding the distal portion of the sheath should be made.

*Re-using* the NuDEL™ sheath for second stent delivery or stent post-dilation with other balloons: although the NuDEL™ sheath may be used for secondary stent deployment and additional balloon dilation of the stent, care has to be taken if this off-label practice is to be adopted. In order to re-use the delivery system, the original balloon and nose cone first need to be removed over the wire and through the sheath. The nose cone is soft and can be withdrawn into the sheath with minimal resistance. We checked several NuDEL™ systems after clinical use to determine how much force would be required to pull the nose cone off the balloon system. We were not able to pull the system apart by hand, and were therefore confident that the risk of damaging the system in vivo using the manoeuvre described above was very low. We noted that opening the side-arm of the sheath stopped any build-up of pressure that might occur when drawing the balloon and nose cone back through the delivery sheath. The length of the delivery system should be checked against the shaft length of the prospective balloon to avoid a disappointing mismatch. A short calibre-matched sheath should be available to deal with potential leakage from the haemostatic valve if it becomes damaged when withdrawing the inner portion of the system; in our experience, the amount of leakage was easily managed without this.

## Conclusion

The NuDEL™ delivery system provides definite efficiency and potential safety advantages when compared with hand-crimped and hand-loaded covered stents. Many of the advantages were related to the process of preparation and loading. We should note, however, that there was no direct comparison performed against the standard methodology for covered stent deployment in this study. The NuDEL™ may also facilitate rapid deployment of a covered stent in cases of conduit rupture

or iatrogenic aortic dissection. Our initial experience suggests that the presence of the stent complex at the distal portion of the sheath is advantageous. The almost bespoke nature of the systems means that inventory and stocking could provide a major challenge. Some improvements could be made to the design to decrease the sheath size and improve the ergonomics of the distal portion of the system.

## Acknowledgements

None.

## Financial Support

This research received no specific grant from any funding agency or from commercial or not-for-profit sectors.

## Conflicts of Interest

None.

## Ethical Standards

The authors assert that all procedures contributing to this study comply with the ethical standards of the relevant national UK guidelines on human experimentation and with the Helsinki Declaration of 1975, as revised in 2008, and has been approved by the institutional committees of the three hospitals involved.

## References

1. Boe BA, Zampi JD, Schumacher KR, Yu S, Armstrong AK. The use and outcomes of small, medium and large premounted stents in pediatric and congenital heart disease. *Pediatr Cardiol*, 2016; 37: 1525–1533.
2. Danon S, Gray RG, Crystal MA, et al. Expansion characteristics of stents used in congenital heart disease: serial dilation offers improved expansion potential compared to direct dilation: results from a Pediatric Interventional Cardiology Early Career Society (PICES) Investigation. *Congenit Heart Dis*, 2016; 11: 741–750.
3. Meadows J, Teitel D, Moore P. Anatomic and technical predictors of stent malposition during implantation for vascular obstruction in patients with congenital and acquired heart disease. *JACC Cardiovasc Interv* 2010; 3: 1080–1086.
4. Taggart NW, Minahan M, Cabalka AK, et al. Immediate outcomes of covered stent placement for treatment or prevention of aortic wall injury associated with coarctation of the aorta (COAST II). *JACC Cardiovasc Interv* 2016; 9: 484–493.
5. Vanagt WY, Cools B, Boshoff DE, et al. Use of covered Cheatham-Platinum stents in congenital heart disease. *Int J Cardiol* 2014; 175: 102–107.
6. Boudjemline Y, Malekzadeh-Milani S, Patel M, et al. Predictors and outcomes of right ventricular outflow tract conduit rupture during percutaneous pulmonary valve implantation: a multicenter study. *Eurointervention* 2016; 11: 1053–62.
7. Tretter JT, Jones TK, McElhenney DB. Aortic wall injury related to endovascular therapy for aortic coarctation. *Circ Cardiovasc Interv* 2015; 8: e002840.