

Letter to the Editor: New Observation

Paraneoplastic Neuronal Intermediate Filament Autoimmunity with Hepatocellular Carcinoma

Robin Sawaya¹, Geneviève Ricard², Andrew McKeon^{3,4} and Adrian Budhram^{1,5} 

¹Department of Clinical Neurological Sciences, London Health Sciences Centre, Western University, London, ON, Canada, ²Hôpital régional de Saint-Jérôme, Saint-Jérôme, Québec, Canada, ³Department of Neurology, Mayo Clinic, Rochester, MN, USA, ⁴Department of Laboratory Medicine and Pathology, Mayo Clinic, Rochester, MN, USA and ⁵Department of Pathology and Laboratory Medicine, London Health Sciences Centre, Western University, London, ON, Canada

Keywords: autoimmune disease; neuroimmunology; CNS inflammation; neuroinflammation; inflammatory diseases; paraneoplastic conditions; paraneoplastic encephalomyelitis

A 63-year-old man presented to the neurology clinic with a one-year history of progressive limb numbness and gait difficulty. Past medical history was remarkable for hepatitis C leading to liver cirrhosis and hepatocellular carcinoma (HCC), which was diagnosed and treated with chemoembolization and radiofrequency ablation one year prior to symptom onset. He had also previously been diagnosed with type 2 diabetes mellitus. On examination, he had findings of bilateral lower extremity weakness with spasticity and hyperreflexia, decreased vibration sense in the feet, as well as limb and gait ataxia, suggestive of multifocal neurologic dysfunction with spinal cord and cerebellar involvement. Brain and spinal cord MRIs were unremarkable. Routine metabolic bloodwork was remarkable for a low-normal serum B12 level of 160 pg/mL, so he was started on oral B12 supplementation, but had symptom progression leading to need for a wheelchair. Serial electrodiagnostic studies showed development of a chronic axonal sensorimotor neuropathy, indicative of peripheral nerve involvement. Infectious serologic testing for human immunodeficiency virus and syphilis was negative. Rheumatologic testing including C-reactive protein, anti-nuclear antibodies, and anti-neutrophil cytoplasmic antibodies was negative. Abdominal CT for surveillance of previously treated HCC showed local hepatic adenopathy. This was followed by PET/CT that showed an intensely hypermetabolic hepatic lymph node concerning for malignancy, although subsequent biopsy was negative. A lumbar puncture was performed that showed a cerebrospinal fluid white blood cell (WBC) pleocytosis of 21 WBC/microliter with lymphocytic predominance, elevated protein of 1.15 g/L, and negative cytology. Although not typically associated with HCC, concern for a paraneoplastic neurologic syndrome was raised given his progressive multifocal neurologic dysfunction, history of cancer, and inflammatory CSF. For this reason, serum and CSF were submitted to London Health Sciences Centre Clinical Immunology Laboratory for neural antibody testing. Serum testing was negative; however, CSF testing revealed staining of mouse tissue by indirect immunofluorescence (TIIF) compatible with

neuronal intermediate filament (NIF) antibodies (Fig. 1), which was confirmed by cell-based assays at the Mayo Clinic Neuroimmunology Laboratory (positive for alpha-internexin [aIN], neurofilament light chain [NF-L], and heavy chain [NF-H]). He was diagnosed with paraneoplastic NIF autoimmunity and received intravenous methylprednisolone and intravenous immunoglobulins that were transitioned to high-dose oral prednisone. Four months after initiating immunotherapy, disease stabilization was noted with no further progression and some improvement in spasticity, but he continued to have severe gait impairment requiring a wheelchair. Close clinical follow-up as well as abdominal surgery for possible recurrence of HCC was planned, but unfortunately, the patient committed suicide one month later.

Antibodies against neuronal intermediate filaments (anti-NIF) have recently been identified as novel biomarkers of neurologic autoimmunity. Patients may present with encephalopathy, cerebellar ataxia, myelopathy, neuropathy, or combinations thereof.^{1,2} In contrast to the two prior reported cases accompanying hepatocellular carcinoma (one with pure cerebellar ataxia, and one with encephalopathy), our patient had a spinocerebellar ataxic phenotype.^{1,2} The most common risk factor for neurologic autoimmunity in patients with anti-NIF is cancer (>50% of cases), although other risk factors including systemic infection (e.g. ehrlichiosis, human immunodeficiency virus), systemic autoimmune disease (e.g. rheumatoid arthritis), and immune checkpoint inhibitor therapy have been reported.^{1,2} Cancers identified are most often of neuroendocrine lineage (e.g. small cell lung carcinoma and Merkel cell carcinoma) as observed with numerous other paraneoplastic antibodies.^{1–3} In those patients, positivity for NF-L upon reflex to cell-based assays is most common.² However, anti-NIF has also rarely been detected in patients like ours with HCC, a tumor that has not typically been associated with paraneoplastic neurologic autoimmunity.^{1–3} The profile of antibodies in hepatocellular carcinoma-associated NIF autoimmunity appears to vary (aIN, aIN and NF-H [two prior reports] and all three [this current patient]).^{1,2} Given the intracellular

Corresponding author: A. Budhram; Email: adrian.budhram@lhsc.on.ca

Cite this article: Sawaya R, Ricard G, McKeon A, and Budhram A. (2024) Paraneoplastic Neuronal Intermediate Filament Autoimmunity with Hepatocellular Carcinoma. *The Canadian Journal of Neurological Sciences* 51: 590–591, <https://doi.org/10.1017/cjn.2023.264>

© The Author(s), 2023. Published by Cambridge University Press on behalf of Canadian Neurological Sciences Federation. This is an Open Access article, distributed under the terms of the Creative Commons Attribution-NonCommercial-NoDerivatives licence (<http://creativecommons.org/licenses/by-nc-nd/4.0/>), which permits non-commercial re-use, distribution, and reproduction in any medium, provided that no alterations are made and the original article is properly cited. The written permission of Cambridge University Press must be obtained prior to any commercial use and/or adaptation of the article.

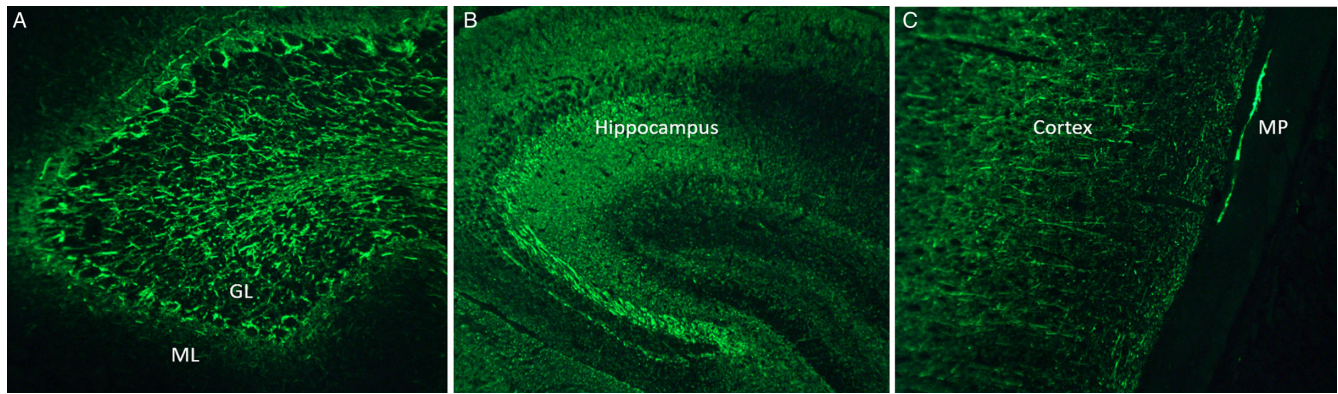


Figure 1: Detection of antibodies against neuronal intermediate filaments (anti-NIF) by mouse tissue indirect immunofluorescence (TIIF). Mouse TIIF shows staining of the cerebellum (a), hippocampus (b), and cortex as well as myenteric plexus (c) that is compatible with anti-NIF. GL=granular layer of the cerebellum; ML=molecular layer of the cerebellum; MP=myenteric plexus.

cytoplasmic location of antigenic targets, it is likely that anti-NIF is not pathogenic but rather a biomarker of possible cytotoxic T-cell mediated neural injury. Awareness of this association between NIF autoimmunity and HCC is essential to improve disease recognition, as a paraneoplastic neurologic syndrome may be lower on the differential diagnosis of patients with HCC and neurologic symptoms.

In addition to highlighting this unique disease association, our case illustrates several important points regarding anti-NIF detection. Anti-NIF was identified by TIIF in our patient, a testing methodology that allows for comprehensive screening of neural antibodies.⁴ More limited testing that does not incorporate TIIF can miss novel neural antibodies such as anti-NIF in patients with suspected neurologic autoimmunity, emphasizing the value of performing neural antibody testing at clinical laboratories with expertise in TIIF. Staining compatible with anti-NIF was identified using CSF but not serum in our case, in keeping with the reportedly higher sensitivity and specificity of CSF testing for anti-NIF compared to serum.^{1,2,5} Following identification of characteristic TIIF staining, confirmatory testing for anti-NIF was performed using CBAs in our case, which serves to maximize specificity.^{1,2,5} Accurate detection of anti-NIF by TIIF-based testing using CSF led to initiation of immunotherapy for NIF neurologic autoimmunity in our patient, with subsequent disease stabilization. Improved clinical recognition and laboratory detection of novel antibodies such as anti-NIF serve to advance the diagnosis and management of patients with neurologic autoimmunity.

Statement of authorship. RS: design and conceptualization, literature review, and drafting of the manuscript.

GR: design and conceptualization, critical revision of the manuscript for intellectual content.

AM: design and conceptualization, critical revision of the manuscript for intellectual content.

AB: design and conceptualization, literature review, and drafting of the manuscript.

Funding. Dr McKeon reports grants from the National Institutes of Health (grants RO1NS126227 and U01NS120901) during the conduct of the study; consulting fees from Janssen and Roche (all paid to Mayo Clinic) outside the submitted work; and had a patent for MAP1B antibody issued, a patent for Septins 5, 7, GFAP, PDE10A, KLHL11 antibodies pending, a patent for Septin antibodies licensed, and a patent for MAP1B antibodies with royalties paid.

Dr Budhram reports that he holds the London Health Sciences Centre and London Health Sciences Foundation Chair in Neural Antibody Testing for Neuro-Inflammatory Diseases, and receives support from the Opportunities Fund of the Academic Health Sciences Centre Alternative Funding Plan of the Academic Medical Organization of Southwestern Ontario.

Competing interests. None.

References

- McKeon A, Shelly S, Zivelonghi C, et al. Neuronal intermediate filament IgGs in CSF: autoimmune axonopathy biomarkers. *Ann Clin Transl Neurol.* 2021;8:425–39.
- Basal E, Zalewski N, Kryzer TJ, et al. Paraneoplastic neuronal intermediate filament autoimmunity. *Neurology.* 2018;91:e1677–e1689.
- Graus F, Vogrig A, Muñiz-Castrillo S, et al. Updated diagnostic criteria for paraneoplastic neurologic syndromes. *Neurol Neuroimmunol Neuroinflamm.* 2021;8:e1014.
- Budhram A, Dubey D, Sechi E, et al. Neural antibody testing in patients with suspected autoimmune encephalitis. *Clin Chem.* 2020;66:1496–509.
- Budhram A, Yang L, Bhayana V, Mills JR, Dubey D. Clinical sensitivity, specificity, and predictive value of neural antibody testing for autoimmune encephalitis. *J Appl Lab Med.* 2022;7:350–6.