


## Letter to the Editor: New Observation

# The Capsular Warning Syndrome in a Young Male Patient with Systemic Lupus Erythematosus

Victor Aguilar-Fuentes<sup>1,2</sup> , Patricia Orozco-Puga<sup>3</sup>, Juan Antonio Sotelo-Ramirez<sup>4</sup>, José Luis Ruiz-Sandoval<sup>1</sup> and Amado Jiménez-Ruiz<sup>1</sup>

<sup>1</sup>Stroke & Cerebrovascular Disease Clinic, Neurology Department, Hospital Civil de Guadalajara “Fray Antonio Alcalde”, Guadalajara, Jalisco, México, <sup>2</sup>Faculty of Medicine, Benemérita Universidad Autónoma de Puebla, Puebla, México, <sup>3</sup>Internal Medicine Department, Hospital Angeles del Carmen, Guadalajara, México and <sup>4</sup>Faculty of Medicine, Centro Universitario de Tonalá, Universidad de Guadalajara, Guadalajara, Jalisco, México

**Keywords:** Capsular warning syndrome; ischemic stroke; magnetic resonance imaging; systemic lupus erythematosus; tenecteplase

A 24-year-old male, with a history of systemic lupus erythematosus (SLE) and no other comorbidities, presented to the emergency department with dysarthria and right-sided hemiparesis one hour after symptom onset.

Upon first examination, he had an NIHSS of 14 points. The brain computerized tomography (CT) was unremarkable (Fig. 1b), and we administered tenecteplase (TNK) with marked clinical improvement at 15-minute reevaluation (NIHSS of 2 points). However, after 8 minutes, symptoms reappeared, disappearing spontaneously after 15 minutes and then reappearing without resolving (Fig. 1a).

On the second hospital day, magnetic resonance imaging (MRI) revealed a left thalamo-capsular stroke (Fig. 1c,d), confirming a capsular warning syndrome (CWS) with subsequent infarction. During workup, we performed carotid Doppler ultrasonography, echocardiography and Holter monitoring, ruling out large vessel atherosclerosis, valvular disease, structural cardiac abnormalities, and cardiac arrhythmias, respectively. During hospitalization, there were no indicators of active infection and antiphospholipid antibodies were negative. Both laboratory analyses and clinical evaluations indicated hypocomplementemia and lupus disease activity, suggesting a probable contribution of SLE vasculopathy to the presentation. The patient was discharged with atorvastatin, aspirin, hydroxychloroquine, azathioprine and rituximab (mRS 5 points). At one- and four-month follow-ups, the patient showed slight (mRS 4 points) and marked (mRS 2) motor improvement, respectively. Antiphospholipid antibodies remained negative on three-month follow-up.

CWS is a rare form of recurrent transient ischemic attacks (TIA) first described by *Donnan et al.*<sup>1</sup> CWS diagnosis is based on the presence of at least three stereotyped motor or sensorimotor episodes; previous studies have reported up to 22 sensorimotor episodes.<sup>2,3</sup> Incidence of CWS in TIA patients is low (1.5%). However, it poses a high risk of disability with more than half of the patients presenting subsequent infarction within 7 days.<sup>4</sup> CWS is

mainly caused by small vessel disease (51%) and large artery atherosclerosis (25%).<sup>5</sup>

Individuals with SLE face a twofold increased risk of stroke compared to the general population, especially with high disease activity. The pathophysiology of cerebrovascular disease in patients with SLE is not well understood, but has been related to accelerated atherosclerosis, hypercoagulability, thromboembolic disease and vascular inflammation.<sup>6</sup> The relationship between CWS and SLE has not yet been reported. In this case, conventional risk factors such as atherosclerosis, hypercoagulability and heart disease were ruled out; laboratory findings were remarkable for hypocomplementemia. Although complement measurement is not a reliable diagnostic tool or indicator of disease activity, its depletion may indicate vasculopathy secondary to immune complexes deposition in small vessels.<sup>7,8</sup>

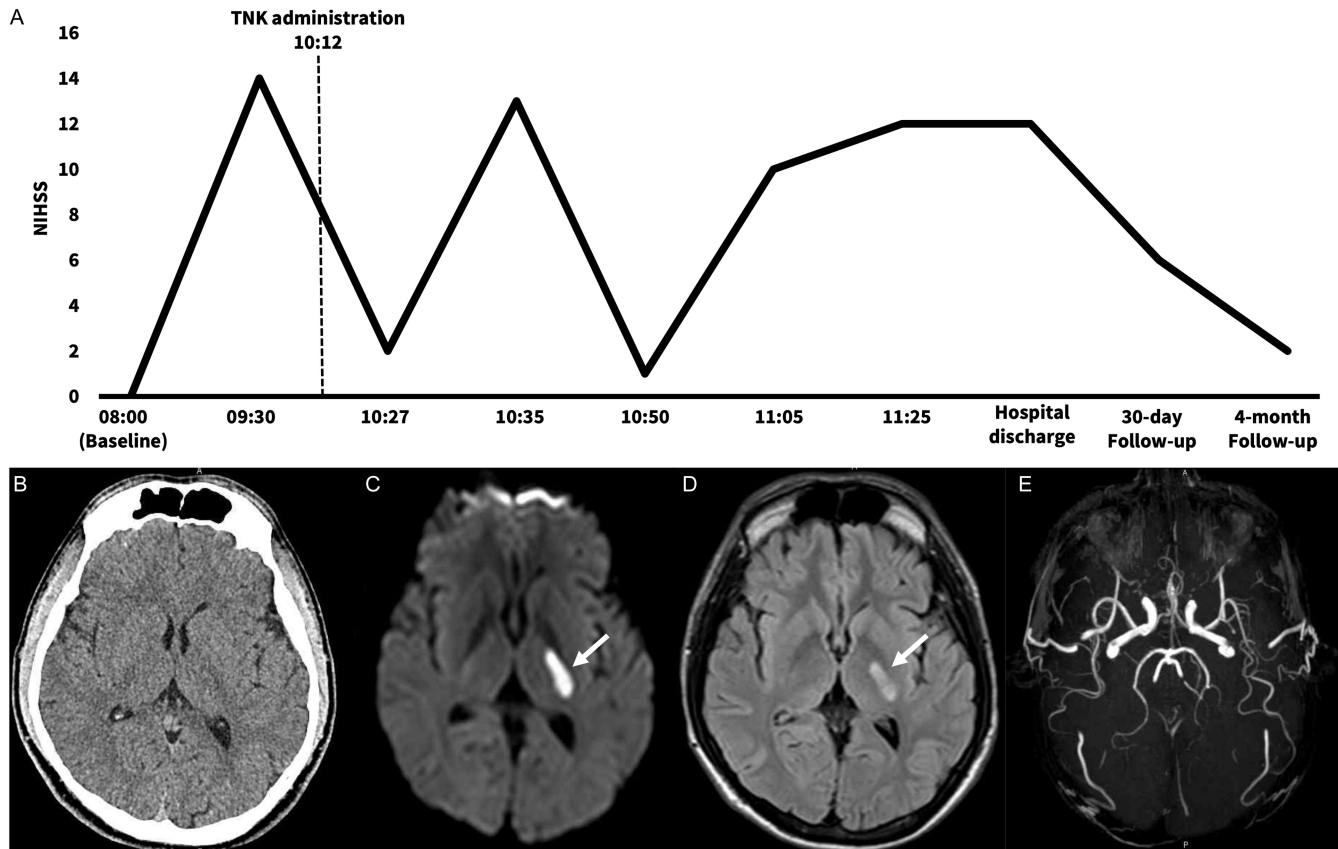
Treatment of CWS remains unknown; previous reports have shown adequate responses to anticoagulation (ACT), dual antiplatelet therapy (DAPT) and fibrinolytic therapy. The combination of DAPT plus ACT has shown the best functional outcomes.<sup>5</sup> Nonetheless, some reports state that the difference in therapeutic effects between fibrinolytic therapy, single antiplatelet therapy and dual antiplatelet therapy groups is not statistically significant.<sup>3</sup> In our case, the patient arrived at the emergency department during the early stages of the disease and was first treated as an ischemic stroke with TNK; consequently, DAPT plus ACT could not be administered. Although the patient showed great clinical improvement at first with the administration of fibrinolytic therapy (TNK), he then presented neurological deterioration.

To our knowledge, this is the first case of CWS in a male patient with SLE. Moreover, treatment of CWS with TNK has not been thoroughly explored. In our patient, this therapy was not effective in the acute phase. The patient's clinical improvement on the follow-up may be attributed to effective disease activity control and the implementation of secondary stroke prevention measures.

**Corresponding author:** V. Aguilar-Fuentes; Email: [victor.aguilar.c60@gmail.com](mailto:victor.aguilar.c60@gmail.com)

**Cite this article:** Aguilar-Fuentes V, Orozco-Puga P, Sotelo-Ramirez JA, Ruiz-Sandoval JL, and Jiménez-Ruiz A. (2025) The Capsular Warning Syndrome in a Young Male Patient with Systemic Lupus Erythematosus. *The Canadian Journal of Neurological Sciences* 52: 333–334, <https://doi.org/10.1017/cjn.2024.268>

© The Author(s), 2024. Published by Cambridge University Press on behalf of Canadian Neurological Sciences Federation.



**Figure 1.** (a) Patient timeline showing initial fluctuating course with unresolved hemiparesis at discharge (9th day of hospitalization) and significant improvement at follow-up. (b) Brain unenhanced-computerized tomography (CT) at hospital admission with no signs of infarction. (c) Diffusion-weighted imaging (DWI) revealing diffusion restriction in the left thalamus and posterior limb of the internal capsule (arrow). (d) Fluid-attenuated inversion recovery (FLAIR) MRI showing a hyperintense lesion in the left thalamus and posterior limb of the internal capsule (arrow), confirming an established ischemic lesion. (e) 3D-time of flight (TOF) MRI with no large vessel occlusion.

However, more studies should be conducted to determine SLE's role in CWS.

**Author contributions.** VAF contributed to the script, editing and submission of the manuscript, POP performed the literature review and contributed to the script, JASR contributed to the script and imaging editing, JLRS contributed to the critical revision of the manuscript and AJR contributed to the conceptualization and supervision.

**Funding statement.** None.

**Competing interests.** None.

## References

- Donnan GA, O'Malley HM, Quang L, Hurley S, Blandin PF. The capsular warning syndrome: pathogenesis and clinical features. *Neurology*. 1993; 43:957–62. DOI: [10.1212/wnl.43.5.957](https://doi.org/10.1212/wnl.43.5.957).
- Ruiz-Sandoval JL, García-Navarro V, Lizaola-Murillo AR, Pineda-Razo TD, González-Cornejo S. Status isquémico cerebral transitorio arteriolo-lacunar. Síndrome de Donnan o de alarma capsular. Reporte de caso. *Rev Mex Neurosci*. 2003;4:271–4.
- He L, Xu R, Wang J, et al. Capsular warning syndrome: clinical analysis and treatment. *BMC Neurol*. 2019;19:285. DOI: [10.1186/s12883-019-1522-0](https://doi.org/10.1186/s12883-019-1522-0).
- Paul NL, Simoni M, Chandratheva A, Rothwell PM. Population-based study of capsular warning syndrome and prognosis after early recurrent TIA. *Neurology*. 2012;79:1356–62. DOI: [10.1212/WNL.0b013e31826c1af8](https://doi.org/10.1212/WNL.0b013e31826c1af8).
- Martínez HR, Figueroa-Sanchez JA, Arreola-Aldape CA, Moran-Guerrero JA, Trujillo-Bracho AL, Cantú-López A. Capsular warning syndrome and its clinical awareness and therapeutic approach: two case reports and a systematic review of literature. *Front Neurol*. 2023;14:1177660. DOI: [10.3389/fneur.2023.1177660](https://doi.org/10.3389/fneur.2023.1177660).
- Jafri K, Patterson SL, Lanata C. Central nervous system manifestations of systemic lupus erythematosus. *Rheum Dis Clin North Am*. 2017;43:531–45. DOI: [10.1016/j.rdc.2017.06.003](https://doi.org/10.1016/j.rdc.2017.06.003).
- Weinstein A, Alexander RV, Zack DJ. A review of complement activation in SLE. *Curr Rheumatol Rep*. 2021;23:16. DOI: [10.1007/s11926-021-00984-1](https://doi.org/10.1007/s11926-021-00984-1).
- Calle-Botero E, Abril A. Lupus vasculitis. *Curr Rheumatol Rep*. 2020;22:71. DOI: [10.1007/s11926-020-00937-0](https://doi.org/10.1007/s11926-020-00937-0).