



Tricuspid valve annular tilt for assessment of pre- and post-intervention right ventricular volume in patients undergoing transcatheter pulmonary valve replacement

Original Article

Cite this article: Reddy CD, Yokota R, and Punn R (2024) Tricuspid valve annular tilt for assessment of pre- and post-intervention right ventricular volume in patients undergoing transcatheter pulmonary valve replacement. *Cardiology in the Young* **34**: 171–177. doi: [10.1017/S1047951123001452](https://doi.org/10.1017/S1047951123001452)

Received: 1 June 2022
Revised: 11 May 2023
Accepted: 20 May 2023
First published online: 13 June 2023

Keywords:

Tetralogy; pulmonary valve; echocardiography; cardiac catheterization; annular tilt

Corresponding author: C. D. Reddy;
Email: reddydc@stanford.edu

C. D. Reddy , R. Yokota and R. Punn 

Department of Pediatrics, Division of Pediatric Cardiology, Stanford University, Palo Alto, CA, USA

Abstract

Introduction: Transcatheter pulmonary valve replacement serves as a successful alternative to surgical replacement of a right ventricle to pulmonary artery conduit. Guidelines for recommending transcatheter pulmonary valve replacement depend on MRI right ventricular volumes, which have been correlated to the echocardiographic measure of right ventricular annular tilt. We aim to assess whether right ventricular annular tilt can be a clinically useful alternative tool in the acute and long-term periods after transcatheter pulmonary valve replacement to assess right ventricular health. **Methods:** We reviewed 70 patients who underwent transcatheter pulmonary valve replacement at a single institution. Echocardiographic measurements were obtained prior to transcatheter pulmonary valve replacement, immediately after transcatheter pulmonary valve replacement, and within 6 months to 1 year after transcatheter pulmonary valve replacement. Right ventricular annular tilt measures the angle of the tricuspid valve plane relative to the mitral valve plane at end-diastole in the apical four-chamber view. Right ventricular fractional area change, right ventricular systolic strain, tissue Doppler velocity, and tricuspid annular plane systolic excursion Z-scores were obtained using published methods. **Results:** Right ventricular annular tilt decreased significantly immediately after transcatheter pulmonary valve replacement ($p = 0.0004$), and this reduction in right ventricular volume persisted at the mid-term follow-up ($p < 0.0001$). Fractional area change did not change significantly after transcatheter pulmonary valve replacement while right ventricular global strain improved at mid-term follow-up despite no significant difference immediately after transcatheter pulmonary valve replacement. **Conclusions:** Right ventricular annular tilt decreases both immediately after transcatheter pulmonary valve replacement and at mid-term follow-up. Right ventricular strain also improved after transcatheter pulmonary valve replacement, corresponding to the improved volume load. Right ventricular annular tilt can be considered as an additional echocardiographic factor to assess right ventricular volume and remodeling after transcatheter pulmonary valve replacement.

In patients with CHD requiring right ventricle to pulmonary artery conduit placement, common complications include right ventricular outflow obstruction as well as pulmonary regurgitation. Chronic stenosis, regurgitation, or a combination of the two can lead to right ventricular dysfunction due to the pressure and volume load.^{1,2} The haemodynamic effects on the right ventricle can lead to diminished functional capacity, left ventricular dysfunction, as well as arrhythmias.^{3–5}

Transcatheter pulmonary valve replacement for pulmonary regurgitation and pulmonary stenosis offers a successful alternative to surgical replacement of right ventricle to pulmonary artery conduit.^{6,7} Similar to surgical replacement, transcatheter pulmonary valve replacement improves biventricular function and exercise intolerance, while having the additional benefits of avoiding sternotomies and cardiopulmonary bypass. In addition, recent studies have shown biventricular functional improvement and remodelling both in the early stages as well as at mid-term follow-up.^{8–12}

Guidelines for surgical pulmonary valve replacement in patients with post-operative pulmonary regurgitation are generally based on right ventricular volumes assessed by cardiac MRI.^{13–16} Indications for transcatheter pulmonary valve replacement have historically followed the indications for surgical pulmonary valve replacement.¹³ Indexed right ventricular end diastolic volumes $> 150 \text{ ml/m}^2$ by MRI is one of the factors considered when determining eligibility for transcatheter pulmonary valve replacement.¹³ An elevated right ventricular annular tilt of $> 20^\circ$ has been associated with elevated right ventricular end diastolic volumes $> 150 \text{ ml/m}^2$ by MRI, compared to right ventricular annular tilts that range from $0.1 \pm 9.4^\circ$ in children with structurally and functionally normal hearts.¹⁷ The acute and long-

© The Author(s), 2023. Published by Cambridge University Press. This is an Open Access article, distributed under the terms of the Creative Commons Attribution licence (<http://creativecommons.org/licenses/by/4.0/>), which permits unrestricted re-use, distribution and reproduction, provided the original article is properly cited.



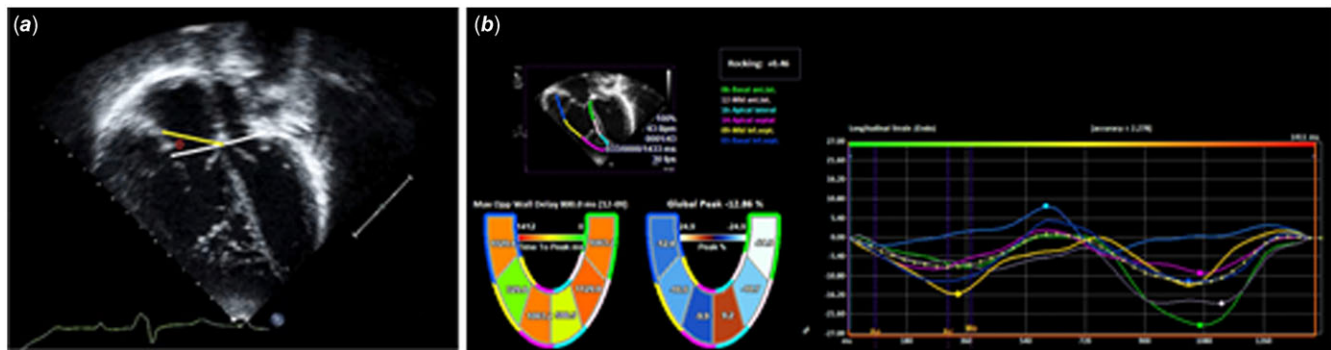


Figure 1. A. apical four chamber view of a study patient with the right ventricular annular tilt technique described in Punn, et al. a line is drawn through the mitral valve hinge points (white), a second line is drawn from the tricuspid valve free wall hinge point to the interventricular septum (yellow). the bisecting angle (θ), is the right ventricular annular tilt. Figure 1B. apical four chamber view of a study patient with right ventricular global strain tracing on the Siemens velocity vector imaging version 3.0.1.15 deformation analysis software (Siemens medical solutions USA).

term effects of transcatheter pulmonary valve replacement on right ventricular annular tilt have not been assessed. This technique would be clinically useful if echocardiographic measures of right ventricular enlargement and dysfunction could be used to evaluate improvement post transcatheter pulmonary valve replacement, particularly in young patients. The purpose of this study was to evaluate the effect on right ventricular annular tilt in the immediate and mid-term follow-up periods, with the hypothesis that right ventricular annular tilt would continue to improve over time and serve as a marker of right ventricular global health. A secondary purpose was to investigate other measures of ventricular performance during the same time course.

Methods

Study subjects and design

We retrospectively collected all patients who underwent transcatheter pulmonary valve replacement at Lucile Packard Children's Hospital at Stanford between January 1, 2011 and January 1, 2017. We included patients with pre- and post-procedural echocardiograms. All pre-procedural echocardiograms were done within 3 months of the transcatheter pulmonary valve replacement, with 75% of the echocardiograms done within the 7 days of the procedure. Pre-intervention echocardiograms were retrospectively compared to immediate post-procedure echocardiograms, as well as to mid-term follow-up (defined as > 1 year and < 2 years after intervention) evaluations. Adults (greater than 18 years of age) and children participated in this study. The indication for transcatheter pulmonary valve replacement was determined to establish subcategories of the entire cohort.

Catheterisation

Patients underwent cardiac catheterisation under general anaesthesia for transcatheter pulmonary valve replacement. Baseline values for right ventricular pressure, peak gradient across the conduit, and mean right atrial pressures were obtained before and after transcatheter pulmonary valve replacement. Melody transcatheter pulmonary valves (Medtronic Inc., Minneapolis, Minnesota) or Sapien transcatheter pulmonary valves (Edwards Lifesciences LLC., Irvine, California) were used in all patients. Test occlusion was performed, to ensure no coronary artery encroachment with subsequent device deployment based on size.

Echocardiography

We obtained echocardiograms using commercially available equipment, including the Philips iE33 (Philips Medical Systems, Bothell, WA), Philips Epiq (Philips Medical Systems, Bothell, WA), or the Acuson C512 (Siemens Medical Solutions USA, Mountain View, CA). Offline independent measurements were done using the syngoDynamics workstation (Siemens Medical Solutions USA; syngoDynamics Solutions, Ann Arbor, MI) and followed standard recommendations for image acquisition as recommended by the American Society of Echocardiography. Images were stored in a DICOM format for measurements and for offline speckle-tracking strain analysis by Siemens Velocity Vector Imaging version 3.0.1.15 deformation analysis software (Siemens Medical Solutions USA, Mountain View, CA).

Continuous wave Doppler was used to assess degree of pulmonary stenosis across the right ventricle to pulmonary artery conduit. Degree of pulmonary regurgitation was graded according to the American Society of Echocardiography's Nomenclature and Standards Committee and the Task Force on Valvular Regurgitation¹⁸ and was recorded from the official pre-catheterisation echocardiogram report. Pulsed-wave Doppler was used to evaluate mitral valve inflow E and A waves to calculate the E/A ratio. Tissue Doppler velocities were also used to obtain peak S, 'E,' and A' waves.^{19,20}

Functional measurements of the right and left ventricles were also completed. The right ventricular end-diastolic area and end-systolic area were measured and a fractional area change was calculated. In order to evaluate left ventricular function, left ventricular ejection fraction was calculated using end-diastolic and end-systolic volumes derived from the 5/6 area x length method.^{19,21–23}

The highest quality apical four-chamber view images were identified to perform right ventricular annular tilt measurements and strain measurements (Fig. 1A). Right ventricular annular tilt was determined by measuring the angle of the tricuspid valve plane relative to the mitral valve plane at end-diastole in the apical four-chamber view.¹⁷ Right ventricular systolic strain measurements were used to assess strain along each right ventricular segment after a user-defined tracing along the endocardial borders (Fig. 1B). These manual tracings were done in the apical four chamber view and were adjusted by the user to ensure adequate endocardial tracking. Deformation measurements were obtained from the pre-intervention, immediately post-intervention, and mid-term

Table 1. Patient demographics (n = 70).

Variable	
Age (y)	13.1 (3.1–48.1)
Adults	15 (21%)
Female	24 (34%)
Primary indication	
Severe pulmonary stenosis (PS)	12 (17%)
Severe pulmonary regurgitation (PR)	21 (30%)
Both severe PS and PR	5 (7%)
Mixed (non-severe PR and PS)	32 (46%)

Data are expressed as median (range) or number (percentage).

post-intervention echocardiograms when available. Images were excluded if the endocardial borders were not visible. All measurements were done by a single physician, blinded to patient and timing of study.

Statistics

All data are expressed as a mean with standard deviation, or median with range as appropriate. Pre- and immediate post-intervention right ventricular function and strain data were compared with paired t-tests, as well as pre versus mid-term, and immediate post versus mid-term. A subanalysis was completed after stratifying the patients based on primary indication for transcatheter pulmonary valve replacement, namely pulmonary stenosis, regurgitation, or mixed presentation. The statistics package of SAS EG 7.2 (SAS Institute, Cary, NC) was used for statistical analysis. P values ≤ 0.05 were considered to indicate statistical significance.

Results

Study subjects

Seventy patients met diagnostic criteria for inclusion constituted the study cohort (median age 13.2 years; range, 3.1–48.1 years); the group with a primary indication for transcatheter pulmonary valve replacement of pulmonary stenosis included 12 patients, pulmonary regurgitation included 21 patients (Table 1). Thirty-two patients had neither criterion, meaning regurgitation and stenosis were less than severe. Sixty-four patients (91%) underwent transcatheter pulmonary valve replacement with a Melody valve; the remainder received a Sapien valve.

Outcomes in the entire cohort

Table 2 illustrates the significant differences between measures of right ventricular function before and after transcatheter pulmonary valve replacement. There is an abrupt decrease in right ventricular annular tilt suggestive of decreased volume load on the right ventricle. This change remains significant when comparing the immediate post-transcatheter pulmonary valve replacement group and the mid-term group, indicating a continued improvement. Similarly, the tricuspid valve Z-score also decreases immediately post-transcatheter pulmonary valve replacement though it is not maintained into the mid-term follow-up cohort.

Fractional area change measured normally in the pre-transcatheter pulmonary valve replacement group and remains

unchanged both immediately and in the mid-term follow-up period after transcatheter pulmonary valve replacement. In comparison, the left ventricular ejection fraction has an immediate statistically significant increase after transcatheter pulmonary valve replacement, though clinically, the function only increases by 2–3%. This change also appears to be transient as the left ventricular ejection fraction at the mid-term follow-up is similar to the pre-intervention state. Interestingly, global strain is not different between the pre- and immediately post-transcatheter pulmonary valve replacement groups; however, there is a statistical improvement between the pre- and mid-term groups. Tricuspid annular plane systolic excursion Z-score, as an additional measure of right ventricular function was abnormal in the pre, immediately-post, and mid-term-post groups with no significant improvement longitudinally. The S' wave increase immediately post-intervention neared significance ($P = 0.057$), but there did not appear to be continued change into the mid-term follow-up period.

Comparison between Adults and Children after transcatheter pulmonary valve replacement

The smaller subset of adult patients undergoing transcatheter pulmonary valve replacement were compared to the paediatric patients before and after transcatheter pulmonary valve replacement. These findings are shown in Tables 3 and 4. There were no significant differences between children and adults in the measures of right ventricular size and function prior to transcatheter pulmonary valve replacement. Immediately post-transcatheter pulmonary valve replacement, both adults and children show a significant difference in the right ventricular annular tilt. The gross values of the right ventricular annular tilt are significantly higher in children. The gross values post-intervention are significantly lower in adults, consistent with a more drastic change after transcatheter pulmonary valve replacement. Children also appeared to show a trend towards a decrease in the right ventricular annular tilt at mid-term follow-up, compared to the adults. However, the immediate post-intervention gross right ventricular annular tilt value was already quite low in the adult population, and there was only a small pool of mid-term follow-up patients.

Discussion

In this retrospective study, we focussed on right ventricular annular tilt as a marker of right ventricular health in patients after transcatheter pulmonary valve replacement. This study found an abrupt decrease in annular tilt values immediately post intervention, indicating an abrupt decrease in right ventricular size when positioning a competent pulmonary valve. Moreover, the tricuspid valve size decreased and left ventricular ejection fraction increased, presumably from the decrease in right ventricular preload. In addition, we showed that the physiological benefits of decreased right ventricular enlargement were maintained at 1-year post-intervention, since the right ventricular annular tilt, left ventricular ejection fraction, and tricuspid valve Z-score remained similar to the immediate post-intervention values.

Right ventricular enlargement plays an important predictor of morbidity and mortality in patients requiring right ventricular to pulmonary artery conduits.¹ Right ventricular enlargement leads to right ventricular failure, ventricular arrhythmias, and sudden death.^{3–5} Pulmonary valve replacements have been shown to decrease the progression of right ventricular enlargement, and even have the potential to reduce the enlargement through

Table 2. Comparison of right ventricular function before and after TPVR in the entire cohort.

Clinical Measurement	Pre-TPVR	Immediately post-TPVR	p-Value	Mid-Term post-TPVR	p-Value Pre- v. Mid-Term, Imm-post v. Mid-Term
Catheterisation					
RVED Pressure (mmHg)	9.0 ± 2.7	8.1 ± 2.8	0.0008	N/A	N/A
RV Systolic Pressure (mmHg)	52.6 ± 16.9	32.8 ± 8.4	< 0.0001	N/A	N/A
Echocardiogram					
RV Annular Tilt (°)	18.2 ± 9.3	13.9 ± 10.1	0.0004	12.1 ± 7.0	< 0.0001 , 0.047
FAC, (%)	42.4 ± 8.3	44.3 ± 9.0	0.1505	42.5 ± 10.1	0.395, 0.665
LV Ejection Fraction (%)	63.1 ± 6.3	66.0 ± 6.8	0.0025	62.4 ± 7.4	0.806, 0.178
Tricuspid Valve Z-Score	-0.2 ± 1.2	-0.6 ± 1.3	0.0007	-0.2 ± 0.9	0.969, 0.424
RV Global Longitudinal Strain	-15.1 ± 6.3	-13.9 ± 6.6	0.2154	-12.8 ± 7.3	0.031 , 0.8245
TAPSE Z-Score	-6.1 ± 2.3	-5.7 ± 2.3	0.0792	-6.3 ± 1.9	0.745, 0.424
S' wave (m/s)	0.06 ± 0.02	0.07 ± 0.02	0.0573	0.07 ± 0.01	0.790, 0.354

FAC = fractional area change; LV = left ventricle; N/A = not applicable; RV = right ventricle; RVED = right ventricular end diastolic; TAPSE = tricuspid valve annular plane systolic excursion; TPVR = transcatheter pulmonary valve replacement.

Data are expressed as mean ± SD, P-value is bolded if significant.

Table 3. Comparison of right ventricular function in children and adults before and after TPVR.

Echocardiographic Measures	Adult (N)	Child (N)	p-Value
Pre-TPVR			
Tricuspid Valve Z-Score	-0.2 ± 1.4 (15)	-0.1 ± 1.2 (55)	0.913
RV Annular Tilt (°)	15.6 ± 8.5 (15)	18.9 ± 9.4 (55)	0.200
TAPSE Z-Score	-3.2 ± 1.6 (7)	-4.5 ± 2.4 (34)	0.085
FAC (%)	44.7 ± 7.2 (15)	41.9 ± 8.5 (55)	0.210
RV Global Strain	-14.8 ± 7.3 (15)	-15.2 ± 6.1 (54)	0.802
LV Ejection Fraction (%)	61.2 ± 7.8 (15)	63.7 ± 5.8 (53)	0.272
S' Wave (m/sec)	0.07 ± 0.04 (14)	0.06 ± 0.01 (52)	0.263
Immediately Post-TPVR			
Tricuspid Valve Z-Score	-0.69 ± 1.6 (15)	-0.53 ± 1.2 (54)	0.729
RV Annular Tilt (°)	7.4 ± 6.7 (15)	15.7 ± 10.2 (54)	0.0007
TAPSE Z-Score	-5.1 ± 1.9 (13)	-5.8 ± 2.4 (54)	0.219
FAC (%)	42.6 ± 10.1 (15)	44.8 ± 8.8 (55)	0.454
RV Global Strain	-14.6 ± 5.1 (13)	-13.7 ± 6.9 (53)	0.657
LV Ejection Fraction (%)	67.8 ± 6.6 (15)	65.6 ± 6.8 (54)	0.270
S' Wave (m/sec)	0.08 ± 0.03 (13)	0.07 ± 0.02 (47)	0.066
Mid-Term Post-TPVR			
Tricuspid Valve Z-Score	-1.4 ± 0.4 (2)	-0.03 ± 0.9 (17)	0.041
RV Annular Tilt (°)	8.5 ± 4.6 (4)	12.9 ± 7.3 (18)	0.173
TAPSE Z-Score	-8.1 ± 0.8 (2)	-6.0 ± 2.0 (15)	0.072
FAC (%)	38.3 ± 8.4 (3)	43.1 ± 10.4 (18)	0.439
RV Global Strain	-11.1 ± 3.8 (5)	-13.1 ± 7.8 (24)	0.572
LV Ejection Fraction (%)	58.4 ± 17.7 (3)	65.1 ± 6.0 (17)	0.580
S' Wave (m/sec)	0.08 ± 0.0 (2)	0.06 ± 0.01 (15)	0.134

FAC = fractional area change; LV = left ventricle; N/A = not applicable; RV = right ventricle; RVED = right ventricular end diastolic; TAPSE = tricuspid valve annular plane systolic excursion; TPVR = transcatheter pulmonary valve replacement.

Data are expressed as mean ± SD, P-value is bolded if significant.

Table 4. Comparison of right ventricular function in adults and children before and after TPVR.

Variable	Pre-TPVR	Immediately post-TPVR	p-Value	Mid-Term post-TPVR	p-Value Imm-post v. Mid-Term
Child					
RV Annular Tilt (°)	18.9 ± 9.4 (55)	15.7 ± 10.2 (54)	0.018	12.9 ± 7.3 (18)	0.061
Tricuspid Valve Z-Score	-0.1 ± 1.2 (55)	-0.53 ± 1.2 (54)	0.004	-0.03 ± 0.9 (17)	0.394
Adult					
RV Annular Tilt (°)	15.6 ± 8.5 (15)	7.4 ± 6.7 (15)	0.003	8.5 ± 4.6 (4)	0.577
Tricuspid Valve Z-Score	-0.2 ± 1.4 (15)	-0.69 ± 1.6 (15)	0.082	-1.4 ± 0.4 (2)	0.916

RV = right ventricle; TPVR = transcatheter pulmonary valve replacement. Data are expressed as mean ± SD, P-value is bolded if significant.

remodelling.⁹⁻¹¹ Right ventricular annular tilt represents a successful method to recognise increased right ventricular volumes in paediatric patients with tetralogy of Fallot,¹⁷ but the change in annular tilt pre- and post-transcatheter pulmonary valve replacement or as a progression over time has not been evaluated.

In our study, the indications for pulmonary valve replacement include isolated severe pulmonary stenosis, isolated severe pulmonary regurgitation, both severe stenosis and regurgitation, and a combination of non-severe pulmonary regurgitation and stenosis. Only 12 patients underwent transcatheter pulmonary valve replacement for isolated severe pulmonary stenosis, and as expected, the right ventricular pressure decreases with transcatheter pulmonary valve replacement as noted in the catheterisation data. The rest of the groups all had a component of volume overload due to pulmonary regurgitation. The last group was the most common indication, suggesting that the right ventricle is particularly susceptible to both conditions due to a combined pressure and volume load. The right ventricular annular tilt decreased immediately after intervention, suggesting an extremely effective decrease in right ventricular volume after transcatheter pulmonary valve replacement. This abrupt decrease in volume benefited both adults and children when evaluated separately. The difference between right ventricular annular tilt between the immediately post-transcatheter pulmonary valve replacement group and the mid-term transcatheter pulmonary valve replacement group was nearly significant ($P = 0.06$) with the mean right ventricular annular tilt in the mid-term follow-up group lower than the immediately-post transcatheter pulmonary valve replacement group. This change may indicate ongoing remodelling, but the sample volume was low for mid-term follow-up.

Other measures associated with increased right ventricular volume, like tricuspid valve size, had similar findings. There was a statistically significant decrease in tricuspid valve size between the pre-intervention and immediate-post transcatheter pulmonary valve replacement group, but no ongoing change between the tricuspid valve Z-score in the immediately-post transcatheter pulmonary valve replacement and mid-term follow-up groups. Notably, the tricuspid valve Z-score was not dilated in the pre-intervention state. Pulmonary valve dysfunction may predominantly contribute to right ventricular body and infundibulum dilation and cause corresponding right ventricular shoulder elevation without as obvious of an impact on tricuspid valve size. Right ventricular annular tilt may therefore be more sensitive to changes in right ventricular volume from pulmonary valve dysfunction than tricuspid valve annular size.

Left ventricular ejection fraction is known to be affected by ventriculo-ventricular interactions.¹² The left ventricular ejection fraction predictably increased immediately after transcatheter pulmonary valve replacement, but did not increase further by 1 year follow-up. The absolute percentage difference in ejection fraction was notably small and could be due to measurement variability. The lack of difference between left ventricular ejection fraction and tricuspid valve Z-score between the immediate and mid-term follow-up periods may signify that the remodelling is immediate and does not continue, or it may be related to the low number of patients in the mid-term follow-up group.

In order to evaluate other markers of right ventricular performance, we analysed variables that assessed right ventricular function. Prior studies have suggested that fractional area change, tricuspid valve annular plane systolic excursion, tissue Doppler derived velocity, and global strain constitute reasonable methods to estimate right ventricular function.²⁴⁻²⁶ Interestingly, there was no significant change in fractional area change between any of the groups, with mean values of all three groups in the normal ranges. Function appears to be relatively preserved in these patients despite the volume and pressure overload. This observation is similar to findings of prior studies looking at both echocardiographic and MRI measures of right ventricular function²⁷ pre- and post-transcatheter pulmonary valve replacement.

Tricuspid annular plane systolic excursion Z-scores were stably abnormal in the pre-, immediately-post-, and mid-term groups. Tricuspid valve annular plane systolic excursion measures longitudinal motion of the right ventricular body and has been reported at lower values in patients with tetralogy of Fallot than other forms of non-CHD.^{28,29} Moreover, prior studies have demonstrated that tricuspid annular plane systolic excursion may not correlate well with assessment of function in tetralogy of Fallot,^{28,30} perhaps explaining why the values are abnormal while the fractional area change values are normal throughout the study period. Tricuspid annular S' velocity similarly measures right ventricular longitudinal motion to assess function. The tricuspid annular S' velocity significantly increased between pre- and immediately-post transcatheter pulmonary valve replacement. These results suggest that there may be subtle improvements in right ventricular function over time that are at least maintained at 1-year post- transcatheter pulmonary valve replacement.

Global right ventricular strain on two-dimensional echocardiographic images has been shown to correlate to right ventricular ejection fraction by MRI,³¹ and multiple studies have shown that global longitudinal strain detects subtle decreases in ventricular

function that are not appreciated by conventional measures.^{32–34} Our results indicated no difference prior to intervention and immediately after intervention; however, right ventricular strain significantly improved between the pre-intervention group and the mid-term follow-up group. Tricuspid annular plane systolic excursion and S' wave both utilise the longitudinal motion of the right ventricular shoulder and ignore the apex,^{28,35} which may make these measures more susceptible to volumetric changes, thereby resulting in an immediate change post-transcatheter pulmonary valve replacement. In contrast, the improvement in right ventricular global strain at mid-term follow-up rather than immediately post-intervention suggests that right ventricular global strain may be less impacted by sudden volume shifts and instead indicate predictably slower right ventricular remodelling.

Limitations and Future Directions

The retrospective nature of the data limits this current study. There is a lack of prospective studies that confirm and correlate the various echocardiographic measures of right ventricular health to MRI and catheterisation-based assessments. In addition, the adult population only made up a small proportion of our total cohort. Thus, the lack of difference between the adult and paediatric patients may represent a Type I error. Lastly, mid-term follow-up data was challenging to obtain, particularly for the adults, due to many of our patients undergoing procedures at our institution and having their general cardiology maintenance at outside centres. While there was a significant immediate decrease to low right ventricular annular tilt post-intervention, it is unclear whether this change was sustained because it had already reached maximal improvement or whether there was insufficient data to assess ongoing decrease in right ventricular annular tilt. Thus, we need prospective studies with larger sample sizes and longer follow-up that may better illustrate the subtle changes in right ventricular remodelling that occur later.

Conclusions

Right ventricular annular tilt appropriately decreases after successful transcatheter pulmonary valve replacement, indicating a decrease in right ventricular volume. In addition, our findings indicate that right ventricular annular tilt correlates with other findings of right ventricular health both in the immediate and mid-term follow-up groups. Right ventricular annular tilt is feasible to incorporate in to the workflow to assess right ventricular volume and has previously been shown to have low interobserver variability.¹⁷ Right ventricular annular tilt is a simple method to estimate right ventricular volume and also track changes in right ventricular enlargement over time.

Author contribution. Charitha Reddy: Concept/Design, Data Collection, Data Analysis/Interpretation, Drafting Article, Statistics.

Rumi Yokota: Data Collection, Data Analysis, Approval of Article.

Rajesh Punn: Data Analysis/Interpretation, Statistics, Critical Revision of Article, Statistics, Approval of Article.

Financial support. This research received no specific grant from any funding agency, commercial, or not-for-profit sectors.

Competing interests. None.

References

- Carvalho JS, Shinebourne EA, Busst C, et al. Exercise capacity after complete repair of tetralogy of Fallot: deleterious effects of residual pulmonary regurgitation. *Br Heart J* 1992; 67: 470–473.
- Williams WG, Quaegebeur JM, Kirklín JW, et al. Outflow obstruction after the arterial switch operation: a multiinstitutional study. *Congenital heart surgeons society. J Thorac Cardiovasc Surg* 1997; 114: 975–87.
- Davlouros PA, Kilner PJ, Hornung TS, et al. Right ventricular function in adults with repaired tetralogy of Fallot assessed with cardiovascular magnetic resonance imaging: detrimental role of right ventricular outflow aneurysms or akinesia and adverse right-to-left ventricular interaction. *J Am Coll Cardiol* 2002; 40: 2044–2052.
- Gatzoulis MA, Balaji S, Webber SA, et al. Risk factors for arrhythmia and sudden cardiac death late after repair of tetralogy of Fallot: a multicentre study. *Lancet* 2000; 356: 975–981.
- Valente AM, Gauvreau K, Assenza GE, et al. Contemporary predictors of death and sustained ventricular tachycardia in patients with repaired tetralogy of Fallot enrolled in the INDICATOR cohort. *Heart* 2014; 100: 247–253.
- Gillespie MJ, Rome JJ, Levi DS, et al. Melody valve implant within failed bioprosthetic valves in the pulmonary position: a multicenter experience. *Circ Cardiovasc Interv* 2012; 5: 862–870.
- Zahn EM, Hellenbrand WE, Lock JE, et al. Implantation of the melody transcatheter pulmonary valve in patients with a dysfunctional right ventricular outflow tract conduit early results from the U.S. clinical trial. *J Am Coll Cardiol* 2009; 54: 1722–1729.
- Lunze FI, Hasan BS, Gauvreau K, et al. Progressive intermediate-term improvement in ventricular and atrioventricular interaction after transcatheter pulmonary valve replacement in patients with right ventricular outflow tract obstruction. *Am Heart J* 2016; 179: 87–98.
- Coats L, Khambadkone S, Derrick G, et al. Physiological consequences of percutaneous pulmonary valve implantation: the different behaviour of volume- and pressure-overloaded ventricles. *Eur Heart J* 2007; 28: 1886–1893.
- Coats L, Khambadkone S, Derrick G, et al. Physiological and clinical consequences of relief of right ventricular outflow tract obstruction late after repair of congenital heart defects. *Circulation* 2006; 113: 2037–2044.
- Coats L, Tsang V, Khambadkone S, et al. The potential impact of percutaneous pulmonary valve stent implantation on right ventricular outflow tract re-intervention. *Eur J Cardiothorac Surg* 2005; 27: 536–543.
- Frigiola A, Tsang V, Bull C, et al. Biventricular response after pulmonary valve replacement for right ventricular outflow tract dysfunction: is age a predictor of outcome? *Circulation*. *Circulation* 2008; 118: S182–S190.
- Tretter JT, Friedberg MK, Wald RM, et al. Defining and refining indications for transcatheter pulmonary valve replacement in patients with repaired tetralogy of Fallot: contributions from anatomical and functional imaging. *Int J Cardiol* 2016; 221: 916–925.
- Geva T. Is MRI the preferred method for evaluating right ventricular size and function in patients with congenital heart disease?: MRI is the preferred method for evaluating right ventricular size and function in patients with congenital heart disease. *Circ Cardiovasc Imaging* 2014; 7: 190–197.
- Geva T. Repaired tetralogy of fallot: the roles of cardiovascular magnetic resonance in evaluating pathophysiology and for pulmonary valve replacement decision support. *J Cardiovasc Magn Reson* 2011; 13: 9.
- Valente AM, Cook S, Festa P, et al. Multimodality imaging guidelines for patients with repaired tetralogy of fallot: a report from the American Society of echocardiography: developed in collaboration with the society for cardiovascular magnetic resonance and the society for pediatric radiology. *J Am Soc Echocardiogr* 2014; 27: 111–141.
- Punn R, Behzadian F, Tacy TA. Annular tilt as a screening test for right ventricular enlargement in patients with tetralogy of fallot. *J Am Soc Echocardiogr* 2010; 23: 1297–1302.
- Zoghbi WA, Enriquez-Sarano M, Foster E, et al. Recommendations for evaluation of the severity of native valvular regurgitation with two-dimensional and Doppler echocardiography. *J Am Soc Echocardiogr* 2003; 16: 777–802.

19. Sluysmans T, Colan SD. Theoretical and empirical derivation of cardiovascular allometric relationships in children. *J Appl Physiol* (1985) 2005; 99: 445–457.
20. Colan SD, Parness IA, Spevak PJ, et al. Developmental modulation of myocardial mechanics: age- and growth-related alterations in afterload and contractility. *J Am Coll Cardiol* 1992; 19: 619–629.
21. Lopez L, Colan SD, Frommelt PC, et al. Recommendations for quantification methods during the performance of a pediatric echocardiogram: a report from the pediatric measurements writing group of the American society of echocardiography pediatric and congenital heart disease council. *J Am Soc Echocardiogr* 2010; 23: 465–95; quiz 576–7.
22. Lang RM, Bierig M, Devereux RB, et al. Recommendations for chamber quantification: a report from the American society of echocardiography's guidelines and standards committee and the chamber quantification writing group, developed in conjunction with the European association of echocardiography, a branch of the European society of cardiology. *J Am Soc Echocardiogr* 2005; 18: 1440–1463.
23. Lang RM, Badano LP, Mor-Avi V, et al. Recommendations for cardiac chamber quantification by echocardiography in adults: an update from the American society of echocardiography and the European association of cardiovascular imaging. *Eur Heart J Cardiovasc Imaging* 2015; 16: 233–270.
24. Selly JB, Iriart X, Roubertie F, et al. Multivariable assessment of the right ventricle by echocardiography in patients with repaired tetralogy of Fallot undergoing pulmonary valve replacement: a comparative study with magnetic resonance imaging. *Arch Cardiovasc Dis* 2015; 108: 5–15.
25. Li Y, Xie M, Wang X, et al. Impaired right and left ventricular function in asymptomatic children with repaired tetralogy of Fallot by two-dimensional speckle tracking echocardiography study. *Echocardiography* 2015; 32: 135–143.
26. Brown DW, McElhinney DB, Araoz PA, et al. Reliability and accuracy of echocardiographic right heart evaluation in the U.S. melody valve investigational trial. *J Am Soc Echocardiogr* 2012; 25: 383–392 e4.
27. Lurz P, Nordmeyer J, Giardini A, et al. Early versus late functional outcome after successful percutaneous pulmonary valve implantation: are the acute effects of altered right ventricular loading all we can expect? *J Am Coll Cardiol* 2011; 57: 724–731.
28. Mercer-Rosa L, Parnell A, Forfia PR, et al. Tricuspid annular plane systolic excursion in the assessment of right ventricular function in children and adolescents after repair of tetralogy of Fallot. *J Am Soc Echocardiogr* 2013; 26: 1322–1329.
29. Bonnemains L, Stos B, Vaugrenard T, et al. Echocardiographic right ventricle longitudinal contraction indices cannot predict ejection fraction in post-operative Fallot children. *Eur Heart J Cardiovasc Imaging* 2012; 13: 235–242.
30. Koestenberger M, Nagel B, Ravekes W, et al. Systolic right ventricular function in pediatric and adolescent patients with tetralogy of Fallot: echocardiography versus magnetic resonance imaging. *J Am Soc Echocardiogr* 2011; 24: 45–52.
31. Lee JH, Park JH. Strain analysis of the right ventricle using two-dimensional echocardiography. *J Cardiovasc Imaging* 2018; 26: 111–124.
32. Adamson GT, Arunamata A, Tacy TA, et al. Postoperative recovery of left ventricular function following repair of large ventricular septal defects in infants. *J Am Soc Echocardiogr* 2020; 33(3): 368–377.
33. Arunamata A, Stringer J, Balasubramanian S, et al. Cardiac segmental strain analysis in pediatric left ventricular noncompaction cardiomyopathy. *J Am Soc Echocardiogr* 2019; 32: 763–773 e1.
34. Lowenthal A, Tacy TA, Behzadian F, et al. Echocardiographic predictors of early postsurgical myocardial dysfunction in pediatric patients with aortic valve insufficiency. *Pediatr Cardiol* 2013; 34: 1335–1343.
35. Bao SF, Zhang YQ, Chen LJ, et al. Assessment of right ventricular systolic function in children with repaired tetralogy of Fallot by multiple-view from single acoustic window with speckle tracking echocardiography. *Echocardiography* 2019; 36: 133–141.