




# Giant aortic aneurysm repair in a child due to arterial tortuosity syndrome

Dominykas Budrys<sup>1</sup> , Virgilijus Tarutis<sup>2</sup> and Karolis Jonas<sup>2</sup>

<sup>1</sup>Vilnius University Faculty of Medicine, Vilnius, Lithuania and <sup>2</sup>Vilnius University Faculty of Medicine, Institute of Clinical Medicine, Department of Cardiovascular Diseases, Cardiothoracic Surgery Center, Vilnius, Lithuania

## Brief Report

**Cite this article:** Budrys D, Tarutis V, and Jonas K (2024) Giant aortic aneurysm repair in a child due to arterial tortuosity syndrome. *Cardiology in the Young* **34**: 1156–1158. doi: [10.1017/S1047951124000544](https://doi.org/10.1017/S1047951124000544)

Received: 19 February 2024  
Revised: 14 March 2024  
Accepted: 15 March 2024  
First published online: 1 April 2024

### Keywords:

connective tissue disorders; arterial tortuosity syndrome; CHD; paediatric cardiac surgery

### Corresponding author:

D. Budrys; Email: [dbudrys99@gmail.com](mailto:dbudrys99@gmail.com)

### Abstract

Arterial tortuosity syndrome is an extremely rare hereditary connective tissue disorder. We present a case of an incidentally diagnosed aneurysm of the aortic root and the ascending aorta caused by arterial tortuosity syndrome, which was confirmed genetically. The aneurysm was repaired surgically. One year after the procedure, there was no further dilation of the aorta or formation of new aneurysms.

Arterial tortuosity syndrome (OMIM #208050) was first reported in the late sixties of the last century.<sup>1</sup> It is distinguished by twisting and tangling of large and medium arteries caused by structural alterations in the wall of the vessel. These changes are determined by an autosomal-recessive mutation in SLC2A10 gene (20q13.12; MIM: 606145).<sup>2</sup> Unpredictable clinical presentations and scarce scientific literature complicate the diagnosis and management of this syndrome.

### Case report

A 5-year-old male was presented to the hospital with rhinorrhea, cough, subfebrile fever, neck lymphadenopathy, left-side chest pain, and history of dysphagia. Oxygen saturation was 96%, blood pressure and heart rate were in normal range.

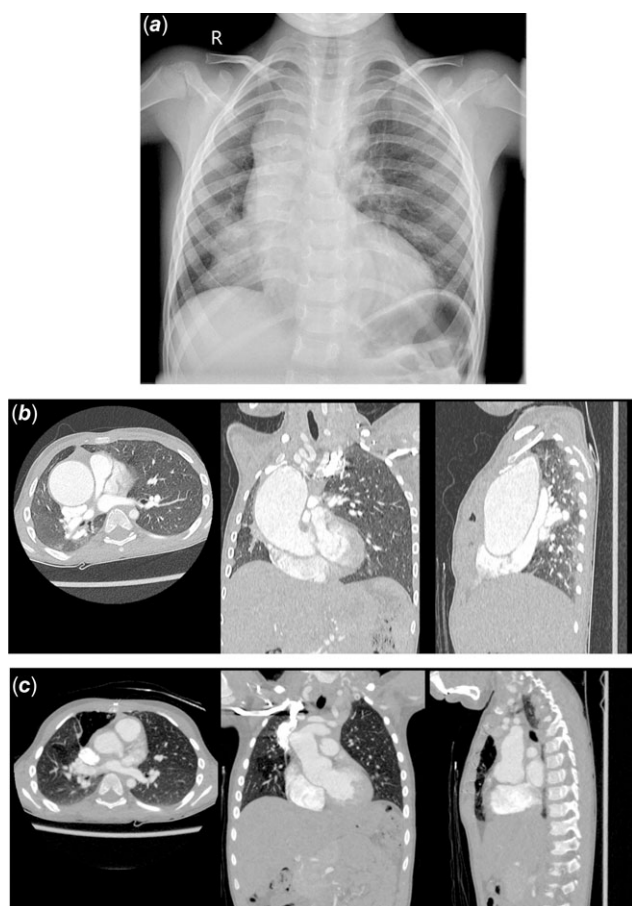
Auscultation revealed reduced breath sounds in the lower part of the right lung and pronounced systolic murmur extending to the right side of the chest. Laboratory tests showed neutrophilic leukocytosis and increased concentration of C-reactive protein. Chest X-ray (Fig. 1a) showed infiltration in the lower third of the right lung and enlargement of the upper mediastinum. The patient was hospitalised and started on oral amoxicillin.

A more detailed inspection revealed periorbital fullness, joint hypermobility, and a slightly deformed chest. Ultrasound of the neck and mediastinum showed non-specific bilateral neck lymphadenopathy. Significant regurgitant flow through the aortic valve and dilation of the ascending aorta and the aortic arch were noticed. CT angiography revealed tortuous aorta, aneurysm of the aortic root and the ascending aorta (the diameters were 35 mm at the level of the Valsalva sinuses and 49 mm at the level of right atrial appendage), right dislocation of the mediastinum, and compression of the trachea by the aortic arch (Fig. 1b and Fig. 2a). Arterial tortuosity syndrome was suspected. Whole exome sequencing revealed one likely pathogenic single nucleotide variant and one pathogenic deletion in SLC2A10 gene, which confirmed the suspected diagnosis. Proband's parents declined further evaluation of the family.

After four days of inpatient treatment, the patient was discharged home. Surgery was planned in two months, due to the extremely enlarged ascending aorta, which caused tracheal displacement and intermittent dysphagia. Metoprolol and enalapril were prescribed in an attempt to slow the aortic growth rate.

The surgery was performed via median sternotomy using cardiopulmonary bypass. The aorta was cross clamped. Antegrade cold blood cardioplegia was administered to the aortic root and the heart was arrested. The aorta was transected at the level of sinotubular junction. The aortic annulus and sinotubular junction were narrowed to 20 mm and stabilised using a knitted polyester ring fashioned from a 20 mm vascular prosthesis. The patient was cooled down to 18° C. After repositioning the arterial cannula to the brachiocephalic trunk, the circulation was arrested and antegrade cerebral perfusion was commenced. Myocardial protection was maintained using direct intermittent antegrade cardioplegia. The aortic cross-clamp was removed, and the aneurysm was resected at the level of the proximal aortic arch. A direct anastomosis between the aortic root and the proximal aortic arch was made. A knitted 20 mm vascular graft was wrapped around the reconstructed part externally and secured to the previously reinforced sinotubular junction and to the proximal aortic arch. Total cardiopulmonary bypass time was 156 minutes, the aorta was cross clamped for 84 minutes.

The patient was treated in a paediatric cardiac ICU for 2 days and discharged from the hospital on the 10<sup>th</sup> postoperative day after an uneventful perioperative course.



**Figure 1.** [a] Posteroanterior chest radiograph acquired at the time of initial presentation; [b] (from left to right) axial, coronal, and sagittal preoperative images of CT angiography (CTA), exhibiting the aneurysm. Axial image is at the level of Th7 vertebra; [c] (from left to right) axial, coronal, and sagittal postoperative CTA images acquired one year after the procedure. Axial image is at the level of Th7 vertebra.

One year after the procedure, the patient was in good general health and had no signs of dyspnoea and dysphagia. CT angiography showed no further dilation of the aorta or formation of new aneurysms (the dimensions were 33 mm at the level of the Valsalva sinuses and 28 mm at the level of right atrial appendage) (Fig. 1c and Fig. 2b).

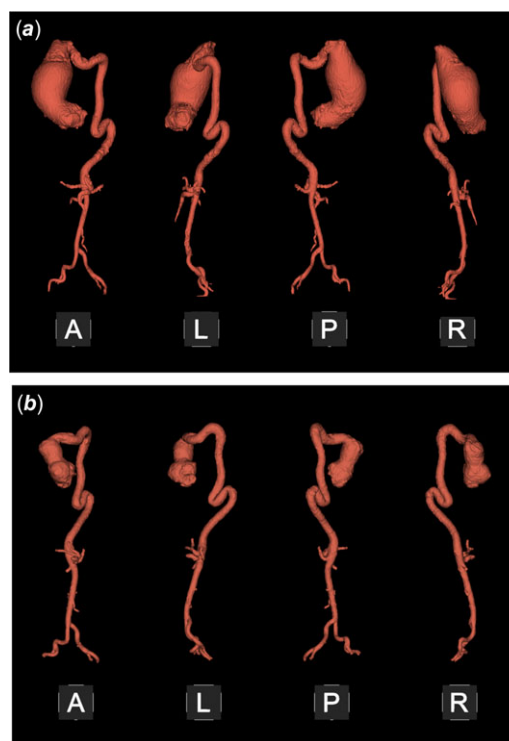
The patient continues to use metoprolol and enalapril.

## Discussion

SLC2A10 gene, highly expressed in organs with abundant smooth muscle cells,<sup>3</sup> encodes for a GLUT10 protein (facilitative glucose transporter 10). Current studies on the pathogenesis of arterial tortuosity syndrome suggest that defective GLUT10 may be related to worse redox state in the cells causing structural abnormalities of the arterial walls.<sup>4,5</sup>

Patient age on the diagnosis of arterial tortuosity syndrome varies from neonatal to adult cases. No gender specificity is reported.<sup>2,6</sup>

Cardiovascular symptoms (murmurs, signs of aortic coarctation, or pulmonary artery stenosis) are the most frequent manifestations of arterial tortuosity syndrome.<sup>2,6</sup> Tortuous large and medium arteries with aneurysms and/or stenoses are distinct



**Figure 2.** [a] Preoperative 3D reconstruction of the aorta; [b] 3D reconstruction of the aorta one year after the surgery. A = anterior; L = left side; R = right side; P = posterior view.

features of the syndrome and the main source of this syndrome-related morbidity. The risk of severe vascular complications, such as aneurysm rupture, dissection, and ischaemic stroke, is unclear due to low prevalence and limited research on this condition.<sup>2,6</sup> Less frequent signs of arterial tortuosity syndrome include respiratory symptoms, dysphagia, skin, facial, skeletal, and joint abnormalities (skin and joint laxity, aged appearance, long face, contractures, chest deformities, arachnodactyly, camptodactyly, and similar). Patients can also have hernias, which may lead to medical emergencies.<sup>2,7</sup>

Genetic testing is the only way to confirm arterial tortuosity syndrome. Autosomal-recessive inheritance indicates higher chance of consanguinity in proband's family. Young patient age, cardiovascular complaints, pathological vascular findings, and signs of connective tissue disorder could raise suspicion of this pathology. Arterial tortuosity syndrome should be differentiated from Loeys-Dietz, Ehlers-Danlos, and Marfan syndromes.<sup>1</sup> Antenatally, intrauterine growth retardation, oligohydramnios, and aortic tortuosity on ultrasound can raise suspicion of arterial tortuosity syndrome.<sup>1,2</sup>

There are no clear recommendations for the treatment of arterial tortuosity syndrome. The management is multidisciplinary, and surgery is often required at some age. However, the literature reports very few cases of surgical repair of aortic aneurysms in paediatric patients. Medications, such as beta-blockers and calcium channel blockers, can reduce stress on arterial walls as well as diminish the growth rate of the arteries but should be used with caution in presence of arterial stenosis (especially when renal circulation is compromised). Close follow-up of the patients is recommended. Literature indicates positive prognosis for arterial tortuosity syndrome patients when managed properly.<sup>2,8,9</sup>

**Acknowledgements.** Authors would like to thank Rūta Gegieckienė for her contribution to this work and the patient's family for their consent.

**Financial support.** This research received no financial support.

**Competing interests.** None.

**Ethical standard.** Written informed consent has been obtained from the patient's parents to publish this paper.

## References

1. Callewaert B, Paeppe A De, Coucke P. Arterial Tortuosity Syndrome. GeneReviews® [Internet]; Available from: <https://www.ncbi.nlm.nih.gov/books/NBK253404/>. Accessed February 23, 2023.
2. Beyens A, Albuissou J, Boel A, et al. Arterial tortuosity syndrome: 40 new families and literature review. *Genet Med* 2018; 20: 1236–1245.
3. Jian L, Wu Q, Min X, et al. GLUT10 is a novel immune regulator involved in lung cancer immune cell infiltration and predicts worse survival when transcriptionally downregulated. *Heliyon* 2023; 9: e13836.
4. Boel A, Burger J, Vanhomwegen M, et al. Slc2a10 knock-out mice deficient in ascorbic acid synthesis recapitulate aspects of arterial tortuosity syndrome and display mitochondrial respiration defects. *Hum Mol Genet* 2020; 29: 1476–1488.
5. Syu YW, Lai HW, Jiang CL, Tsai HY, Lin CC, Lee YC. GLUT10 maintains the integrity of major arteries through regulation of redox homeostasis and mitochondrial function. *Hum Mol Genet* 2018; 27: 307–321.
6. Callewaert BL, Willaert A, Kerstjens-Frederikse WS, et al. Arterial tortuosity syndrome: clinical and molecular findings in 12 newly identified families. *Hum Mutat* 2008; 29: 150–158.
7. Esmel-Vilomara R, Valenzuela I, Riaza L, et al. Arterial tortuosity syndrome: phenotypic features and cardiovascular manifestations in 4 newly identified patients. *Eur J Med Genet* 2023; 66: 104823.
8. Al-Khaldi A, Momenah T, Alshari A, et al. Late outcomes after pulmonary arterial reconstruction in patients with arterial tortuosity syndrome. *Ann Thorac Surg* 2022; 113: 1569–1574.
9. Al-Khaldi A, Mohammed Y, Tamimi O, Alharbi A. Early outcomes of total pulmonary arterial reconstruction in patients with arterial tortuosity syndrome. *Ann Thorac Surg* 2011; 92: 698–704.