



Letter to the Editor: New Observation

Posterior Cranial Fossa Malformation and Vascular Dysplasia in GJB2 Gene Mutation

Carlo Alberto Cesaroni¹ , Manuela Napoli², Carlotta Spagnoli¹ , Susanna Rizzi¹, Daniele Frattini¹ and Carlo Fusco¹

¹Department of Pediatrics, Child Neurology Unit, Azienda USL-IRCCS Di Reggio Emilia, Reggio Emilia, Italy and ²Neuroradiology Unit, Azienda Unità Sanitaria Locale-IRCCS di Reggio Emilia, Reggio Emilia, Italy

Keywords: Malformation; cerebellum; connexin-26; deafness

The gap junction β -2 (*GJB2*) gene is the main gene responsible for congenital non-syndromic hearing loss.¹ *GJB2* encodes for a protein called connexin-26 (Cx26). Cx26 is responsible for intercellular substance transfer and signal communication and plays a critical role in hearing acquisition and maintenance. Cx26 mutations can cause not only congenital deafness but also delayed deafness.² Posterior cranial fossa malformations can arise because of any insult to this pathway occurring from early embryogenesis to neural maturation.³ There are many well-described malformations affecting the cerebellum and posterior cranial fossa, either syndromic (e.g., Chiari malformation or Dandy–Walker malformation (DWM)), or non-syndromic. In the following case report, we will describe brain malformations of the posterior cranial fossa in a patient carrying two biallelic pathogenic variants in the *GJB2* gene, diagnosed at 40 years of age, in obvious diagnostic delay, after performing whole exome sequencing (WES). A 40-year-old patient presented to our unit for investigations regarding deafness. She started to walk independently at 12 months of age. Apparently, no

hearing impairment was suspected in her first year of life. Afterward, she developed deafness/deaf-mutism, initially attributed to a possible viral infection. She also had a right hemifacial angioma spontaneously reducing over time. She also reported a previous diagnosis of glaucoma made in her country of origin, for which unfortunately documentation is lacking. In the past several years, he has been suffering from fronto-temporal tightening headache of moderate intensity not associated with dysautonomic symptoms. Attacks occur with variable frequency and increasing intensity in correlation with menstrual period. They respond to paracetamol. Brain computed tomography (CT) and magnetic resonance imaging (MRI) were performed at the age of 38 years, which disclosed the malformations and vascular changes in the posterior cranial fossa described in Figures 1 and 2, respectively.

There was no family history of malformation, deafness, or similar genetic mutation. Considering the early onset of hearing problems, genetic testing was performed. By WES, the patient was found to be compound heterozygous for two variants in the *GJB2*

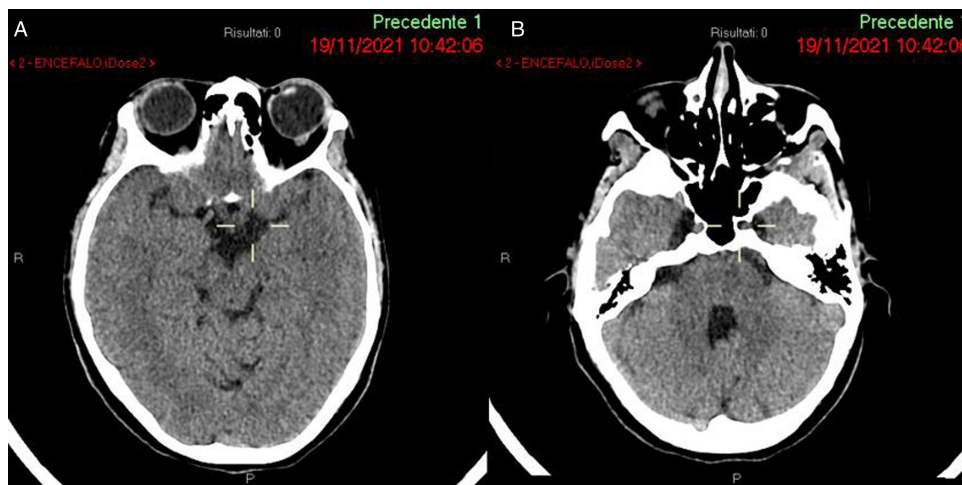


Figure 1: Patient's brain CT performed at the age of 38 years. Figure 1 a–b: Vermian dysmorphism with secondary fourth ventricle dysmorphism and enlargement of Meckel's cave.

Corresponding author: C. A. Cesaroni; Email: carloalberto.cesaroni@ausl.re.it

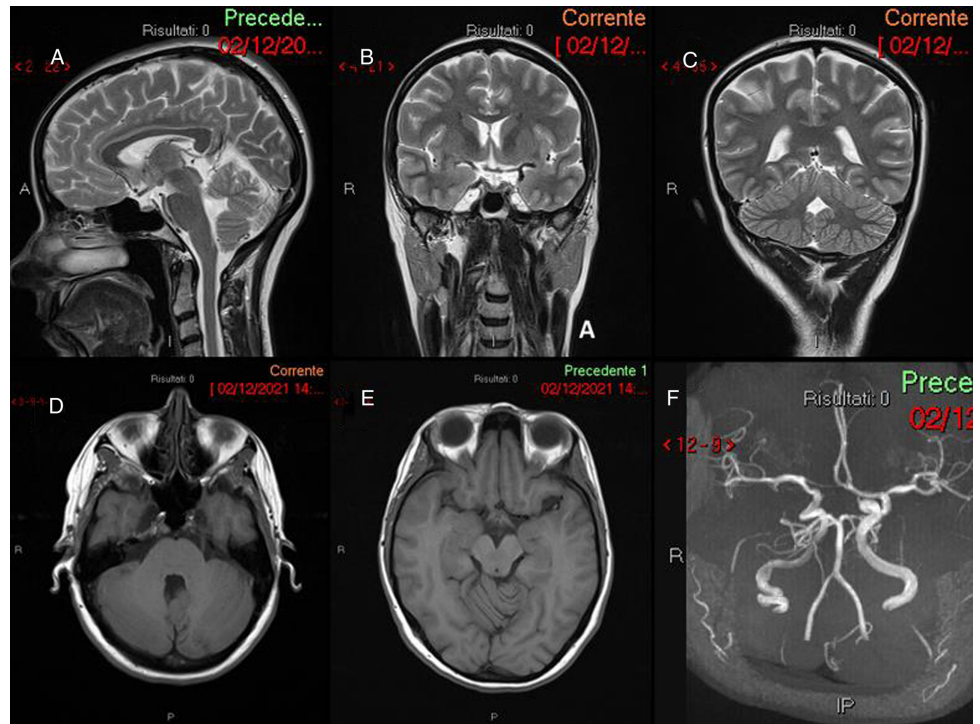
Cite this article: Cesaroni CA, Napoli M, Spagnoli C, Rizzi S, Frattini D, and Fusco C. (2024) Posterior Cranial Fossa Malformation and Vascular Dysplasia in *GJB2* Gene Mutation. *The Canadian Journal of Neurological Sciences* 51: 592–594, <https://doi.org/10.1017/cjn.2023.271>

© The Author(s), 2023. Published by Cambridge University Press on behalf of Canadian Neurological Sciences Federation.

Table 1: Neurological symptoms in patients with DWM and *GJB2* pathogenic variants

Neurological symptoms	Reference
Tension-type headache	This report
Migraine	5
Mild ataxia	4,6
Developmental delay	4,7

Figure 2: Patient's MRI performed at the age of 38 years. Figure 2a: Sagittal T2w. Figure 2b–c: Coronal T2w. Figure 2d–e: Axial T1w. Figure 2f: 3D-TOF (MIP). Vermian hypoplasia (a) with fourth ventricle dysmorphism (d), disorganized superior vermis and upper cerebellar hemisphere folia orientation, without parenchymal signal changes (c,e). Asymmetry between the cerebellar hemispheres (right < left) secondary to right occipital platybasia (C). Bilateral enlargement of Meckel's cave (b). Vascular dysplasia with left-M1 caliber change with proximal stenosis and distal fusiform ectasia (f). Right internal carotid artery (ICA) coiling (pre-petrous segment) and left intracavernous segment (ICA) (f). Left superior cerebellar artery anatomical variant, originating from the posterior cerebral artery (PCA) and right A1 segment (ACA; anterior cerebral artery) hypoplasia (f).



gene: c.139G>T, (p. Glu47*), and c.35del, (p. Gly12Valfs*2), both described in the ClinVar database as pathogenic.

In the literature, patients carrying pathogenic variants in the *GJB2* gene and displaying cerebellar or posterior cranial fossa malformations have been reported with DWM. Neurological symptoms vary,⁴ as can be outlined in Table 1, summarizing previous cases from the literature.

All cases previously described in the literature have keratitis–ichthyosis–deafness (KID) syndrome. However, our patient does not meet all the diagnostic criteria. Keratitis also does not appear to be present in our patient, although she reports a previous diagnosis of glaucoma in her home country. Brain MRI, performed aged 38 years, showed posterior cranial fossa malformation, specifically vermian hypoplasia with cerebellar dysplasia and vascular dysplasia.

At present, the reason why disease-causing variants affecting Cx26 production are associated with complex brain malformations such as DWM is also unclear. Valiente *et al.*⁸ described how focal adhesion kinase (FAK) mediates neuronal migration by regulating the assembly of Cx26-mediated adhesions in pyramidal neurons membrane. These studies were performed on mice and indicate that FAK plays a key role in the dynamic

regulation of Gap-mediated adhesions during glial-driven neuronal migration. This mechanism might underlie the disruption of neuronal migration underlying posterior cranial fossa malformations found in patients harboring pathogenic *GJB2* gene variants. The association between pathogenic *GJB2* gene variants and posterior cranial fossa malformation seems definitely more than coincidence. The underlying pathogenic mechanism is still unclear, and we can only speculate that there is an association with FAK function, mediating neuronal migration.

Further studies, along with neuroimaging, will be critical in the future, in order to understand how mutations in this gene can result in such a brain malformation picture.

Statement of authorship. Conceptualization: CAC and CF; clinical data collection and data curation: CAC, MN, CS, DF, SR, and CF; writing – original draft preparation: CAC; writing – review and editing: CAC, CS, and CF; neuroimaging selection and description: MN; and supervision: CF. All authors have read and agreed to the published version of the manuscript.

Competing interests. The authors declare that the research was conducted in the absence of any commercial or financial relationships that could be construed as a potential conflict of interest.

References

1. Ray M, Sarkar S, Sable MN. Genetics landscape of nonsyndromic hearing loss in Indian populations. *J Pediatr Genet*. 2021;11:5–14. DOI: [10.1055/s-0041-1740532](https://doi.org/10.1055/s-0041-1740532).
2. Chen P, Wu W, Zhang J, et al. Pathological mechanisms of connexin26-related hearing loss: potassium recycling, ATP-calcium signaling, or energy supply? *Front Mol Neurosci*. 2022;15:976388. DOI: [10.3389/fnmol.2022.976388](https://doi.org/10.3389/fnmol.2022.976388).
3. Moosavi A, Kanekar S. Congenital malformations of cerebellum. *Clin Perinatol*. 2022;49:603–21. DOI: [10.1016/j.clp.2022.04.003](https://doi.org/10.1016/j.clp.2022.04.003).
4. Todt I, Mazereeuw-Hautier J, Binder B, Willems PJ. Dandy-walker malformation in patients with KID syndrome associated with a heterozygote mutation (p. Asp50Asn) in the GJB2 gene encoding connexin 26. *Clin Genet*. 2009;76:404–8. DOI: [10.1111/j.1399-0004.2009.01211.x](https://doi.org/10.1111/j.1399-0004.2009.01211.x).
5. Bygum A, Betz RC, Kragballe K, et al. KID syndrome: report of a scandinavian patient with connexin-26 gene mutation. *Acta Derm Venereol*. 2005;85:152–5. DOI: [10.1080/00015550410024148](https://doi.org/10.1080/00015550410024148).
6. Binder B, Hennies HC, Kraschl R, Smolle J. Connexin-26-mutation bei “keratitis-ichthyosis-deafness”-syndrom (KID-Syndrom) [connexin 26 mutation and keratitis-ichthyosis-deafness (KID) syndrome]. *J Dtsch Dermatol Ges*. 3:2005;105–8. DOI: [10.1111/j.1610-0378.2005.04748.x](https://doi.org/10.1111/j.1610-0378.2005.04748.x).
7. Boudghene-Stambouli O, Merad-Boudia A, Abdelali S. KID-syndrome, pachydermatoglyphie et syndrome du Dandy Walker [KID syndrome, pachydermatoglyphy and Dandy-Walker syndrome]. *Ann Dermatol Venereol*. 1994;121:99–102.
8. Valiente M, Ciceri G, Rico B, Marín O. Focal adhesion kinase modulates radial glia-dependent neuronal migration through connexin-26. *J Neurosci*. 2011;31:11678–91. DOI: [10.1523/JNEUROSCI.2678-11.2011](https://doi.org/10.1523/JNEUROSCI.2678-11.2011).