

# Cervical emphysema: an unusual presentation of laryngeal cancer

T PÉZIER<sup>1</sup>, B SCHUKNECHT<sup>2</sup>, S SCHMID<sup>1</sup>, G HUBER<sup>1</sup>

<sup>1</sup>ENT and Head and Neck Clinic, University Hospital Zurich, and <sup>2</sup>Radiology Department, MRI Bethanien, Zurich, Switzerland

## Abstract

**Background:** Acute respiratory decompensation can occur on a background of slowly progressive airway compromise, for example in laryngeal squamous cell cancer. Surgeons in ENT, together with anaesthetists, are often asked to evaluate airway risk and as yet there is no widely adopted standardised approach.

**Case report:** This paper reports the case of an 82-year-old male, who presented with acute airway compromise due to both endolaryngeal obstruction from a squamous cell cancer and extralaryngeal compression from massive subcutaneous emphysema.

**Results:** Primary total laryngectomy was performed, but the patient declined adjuvant radiotherapy. He died a year later from a heart attack without evidence of recurrence.

**Conclusion:** To the best of our knowledge, this is the first case report of acute airway compromise from extralaryngeal subcutaneous emphysema secondary to laryngeal cancer. Options for acute airway management are discussed.

**Key words:** Laryngeal Cancer; Emphysema; Airway Management; Airway Obstruction

## Introduction

We present a patient with acute stridor caused by both an endolaryngeal tumour and extraluminal compression from subcutaneous air. This subcutaneous air was a result of the tumour perforating through the laryngeal cartilage, which allowed air to escape subcutaneously when the patient coughed. To our knowledge, this is the first such case reported in the literature.

It was possible to stabilise the patient with conservative measures from the time of presentation until definitive laryngectomy some two weeks later. Despite declining adjuvant radiotherapy, the patient had no signs of recurrence in the neck when he died a year later from a heart attack.

## Case report

An 82-year-old male presented as an airway emergency to the ENT emergency clinic at the University Hospital Zurich, Switzerland. Initial examination revealed that the patient was tachypnoeic with slow atrial fibrillation (under beta-blocker therapy) and normal blood pressure. He had both inspiratory and expiratory stridor, and oxygen saturation of 88 per cent. Clearly in distress, the patient complained of an acute, large (5 × 5 cm) swelling on the left of his neck, at the level of the thyroid cartilage. This had appeared suddenly during a bout of coughing.

After stabilisation, a more detailed history revealed that the patient had experienced hoarseness for roughly one year. Four months previously, he had been investigated in a neighbouring hospital, and clinical tumour–node–metastasis (TNM) staging had resulted in a T<sub>2</sub>N<sub>0</sub> exophytic glottic

cancer diagnosis. The patient had undergone transoral laser debulking and had been scheduled to undergo curative chemoradiotherapy. Unfortunately, feeling much better after the debulking, the patient had failed to attend for definitive treatment.

Endoscopic examination revealed an incompetent larynx with penetration of saliva. The left vocal fold was paretic, with an exophytic cancer growing transglottically. Upon neck palpation, the large swelling on the left side completely disappeared under pressure, greatly relieving the patient's stridor. The mass had been a large collection of subcutaneous air.

Restaging computed tomography was performed (Figures 1 and 2), which indicated a clinically staged T<sub>4</sub>N<sub>0</sub> transglottic cancer. The cancer had destroyed the thyroid cartilage, allowing air to escape into the subcutaneous tissues whenever there was a high subglottic pressure build-up, when coughing for example.

The patient was treated for aspiration pneumonia, medically optimised (treated with intravenous antibiotics and inhalational therapy) and appropriately counselled for surgery. Two weeks later, the patient underwent total laryngectomy with an elective left neck dissection and pectoralis major flap wound protection. Unfortunately, he had high post-operative troponin levels (0.149 mcg/l (norm <0.014 mcg/l)) and remained in hospital for three weeks. During this time, he underwent a secondary transoesophageal puncture for a voice prosthesis (Provox<sup>®</sup>).

After discharge, the patient made an uneventful recovery, and had good speech and swallow function. He again refused adjuvant radiotherapy. The patient died just over a year later

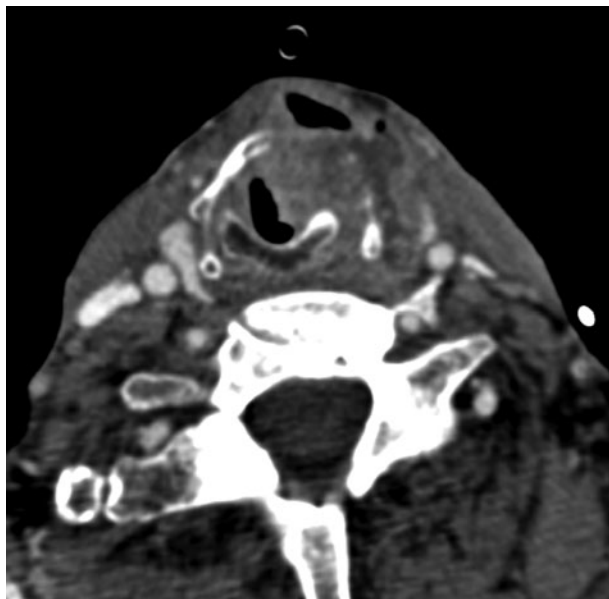


FIG. 1

Axial, contrast-enhanced computed tomogram showing subcutaneous air and left-sided tissue bulk consistent with tumour.

from a myocardial infarction without clinical or positron emission tomography radiographic signs of disease recurrence.

### Discussion

Tracheal and laryngeal injury can occur from an 'extraluminal' or 'endoluminal' injury, and may present with surgical emphysema. The emphysema may in turn lead to extraluminal compression of the airway and subsequent airway

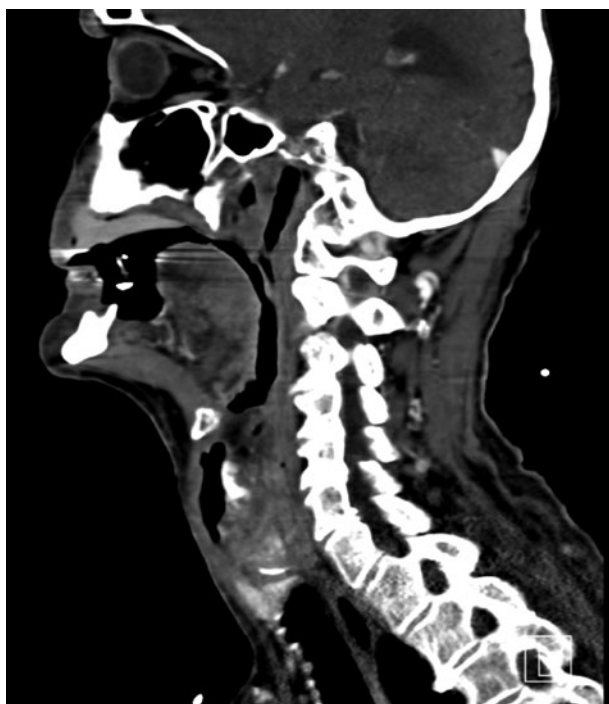

FIG. 2

Sagittal, contrast-enhanced computed tomogram showing subcutaneous air and left-sided tissue bulk consistent with tumour.

obstruction. Several papers have documented traumatic<sup>1–3</sup> or iatrogenic<sup>4</sup> injuries to the airway. Neonates are known to be particularly at risk of laryngeal injury from intubation.<sup>5</sup> There is even a case report of iatrogenic laryngeal perforation occurring during the intubation of a pig.<sup>6</sup> Large, external laryngoceles are also a well described entity<sup>7</sup> that can present with an acute neck swelling following coughing; however, these still have an intact epithelial lining and are therefore not associated with emphysema.

- **Extraluminal compression, intraluminal changes and/or endoluminal obstruction can cause airway obstruction**
- **There is no widely accepted standardised approach for evaluating the 'at risk' airway**
- **Patients need to be carefully counselled as to the risks of airway obstruction, especially if they decline definitive treatment**
- **Despite the risk of tumour seeding from a perforated larynx, our patient declined adjuvant therapy; there was no sign of recurrence**

To our knowledge, this is the first case report of tumour breaking through the laryngeal cartilage leading to acute extraluminal airway compromise. Fortunately, the patient did not require immediate intubation to secure his airway: once the extraluminal component had been resolved with direct compression, the intraluminal component was not sufficiently large to cause airway compromise. The patient was monitored in an intermediate care bed; the option of rapid intubation was available should the need have arisen. The appropriate investigations were then carried out and the patient was discussed by our tumour board. The patient was then counselled before undergoing definitive therapy.

Interestingly, despite the patient declining adjuvant radiotherapy, there was no disease recurrence in the neck. One would imagine that the extralaryngeal infiltration and perforation required to present with a 'pneumo-larynx' would have meant extensive tumour seeding in the neck. This would normally have presented itself as persistent disease after surgery, yet this was not the case.

Airway emergencies must be handled with great care. Even after the acute stridor had subsided, our patient could not be considered completely stable until the cancer had been definitively treated.

Assessment of the airway at risk is often based on objective markers, such as tachypnoea and oxygen saturation, and subjective factors, such as patient fatigue. Any airway intervention will depend on the acuteness of presentation and available expertise. Several options exist for securing the airway in patients with laryngeal cancer.<sup>8,9</sup> These include endotracheal intubation, transoral debulking,<sup>10,11</sup> tracheostomy<sup>12</sup> or the now defunct emergency laryngectomy.<sup>9,13</sup> The choice will be physician and unit specific, and may even depend on whether the patient presents out of normal hours.

### References

- 1 Dissanaik S, Shalhub S, Jurkovich GJ. The evaluation of pneumomediastinum in blunt trauma patients. *J Trauma* 2008;**65**: 1340–5

- 2 Baumgartner F, Sheppard B, de Virgilio C, Esrig B, Harrier D, Nelson RJ *et al.* Tracheal and main bronchial disruptions after blunt chest trauma: presentation and management. *Ann Thorac Surg* 1990;**50**:569–74
- 3 Kolber MR, Aspler A, Sequeira R. Conservative management of laryngeal perforation in a rural setting: case report and review of the literature on penetrating neck injuries. *CJEM* 2011;**13**: 127–32
- 4 Luers JC, Bovenschulte H, Beutner D. Perforation of the hypopharynx after esophagogastroduodenoscopy [in German]. *Dtsch Med Wochenschr* 2012;**137**:1045–8
- 5 Wei JL, Bond J. Management and prevention of endotracheal intubation injury in neonates. *Curr Opin Otolaryngol Head Neck Surg* 2011;**19**:474–7
- 6 Steinbacher R, von Ritgen S, Moens YP. Laryngeal perforation during a standard intubation procedure in a pig. *Lab Anim* 2012; **46**:261–3
- 7 Dursun G, Ozgursoy OB, Beton S, Batikhan H. Current diagnosis and treatment of laryngocele in adults. *Otolaryngol Head Neck Surg* 2007;**136**:211–15
- 8 American Society of Anesthesiologists Task Force on Management of the Difficult Airway. Practice guidelines for management of the difficult airway: an updated report by the American Society of Anesthesiologists Task Force on Management of the Difficult Airway. *Anesthesiology* 2003;**98**: 1269–77
- 9 Moorthy SS, Gupta S, Laurent B, Weisberger EC. Management of airway in patients with laryngeal tumors. *J Clin Anesth* 2005; **17**:604–9
- 10 Hassani DA, Bhananker SM. Postoperative airway obstruction after airway tumor debulking. *J Anesth* 2006;**20**:237–9
- 11 Laccourreye O, Lawson G, Muscatello L, Biacabe B, Laccourreye L, Brasnu D. Carbon dioxide laser debulking for obstructing endolaryngeal carcinoma: a 10-year experience. *Ann Otol Rhinol Laryngol* 1999;**108**:490–4
- 12 Pezier TF, Nixon IJ, Joshi A, Pang L, Guerrero-Urbano T, Oakley R *et al.* Pre-operative tracheostomy does not impact on stomal recurrence and overall survival in patients undergoing primary laryngectomy. *Eur Arch Otorhinolaryngol* 2013;**270**: 1729–35
- 13 Narula AA, Sheppard IJ, West K, Bradley PJ. Is emergency laryngectomy a waste of time? *Am J Otolaryngol* 1993;**14**:21–3

## Address for correspondence:

Dr T Pezier,  
ENT and Head and Neck Clinic,  
University Hospital Zurich,  
Frauenklinikstrasse 24,  
8008 Zurich, Switzerland

E-mail: [tfpezier@gmail.com](mailto:tfpezier@gmail.com)

---

Dr T Pezier takes responsibility for the integrity  
of the content of the paper  
Competing interests: None declared

---