

## Clinical Records

# Hearing loss in the Saethre-Chotzen syndrome

ROBERT J. H. ENSINK, M.D.\*, HENRI A. M. MARRES, M.D., PH.D.\*, HAN G. BRUNNER, M.D., PH.D.†,  
COR W. R. J. CREMERS, M.D., PH.D.\*

### Abstract

A three-generation family with Saethre-Chotzen syndrome and an isolated case are presented. The proband presented with conductive hearing loss. His mother and grandmother showed minor features of the syndrome including conductive hearing loss.

Symptoms of the craniosynostosis syndromes can include stapes ankylosis, a fixed ossicular chain in a too small epitympanum, and small or even absent mastoids. The proband was treated with a bone-anchored hearing aid (BAHA) instead of reconstructive middle ear surgery. Current literature on the results of ear surgery is reviewed. In general, reconstructive middle ear surgery should only be considered if congenital anomalies of the middle ear are the only presenting symptom. In cases with additional anomalies such as atresia of the ear canal or damage due to chronic ear infections, the outcome of reconstructive surgery to correct the anomalous ossicular chain is unsatisfactory. In such cases the BAHA is probably the best solution.

**Key words:** Hearing loss, conductive, genetic; Saethre-Chotzen syndrome; Hearing aid, bone-anchored

### Introduction

The Norwegian psychiatrist Haakon Saethre was the first to describe a syndrome characterized by premature closure of the cranial sutures, a low-set hairline, parrot-beaked nose, nasal septum deviation, brachydactyly, soft tissue syndactyly, defects in the vertebral column and ptosis in a mother and two daughters (Saethre, 1931). One year later Chotzen described identical malformations in a father and two sons. Additional findings in this family included a high arched and narrow palate, conductive hearing loss and cryptorchidism (Chotzen, 1932). A number of cases have since been reported under a variety of different diagnoses (Carter *et al.*, 1982; Kurczinsky and Casperson, 1988; Legius *et al.*, 1989; Cantrell *et al.*, 1994). Currently the Saethre-Chotzen syndrome is classified as type III acrocephalosyndactyly (McKusick, 1992). The most extensive discussion of the acrocephalosyndactyly syndromes describes the Saethre-Chotzen syndrome as uncommon, but it is relatively common among the craniosynostosis syndromes (Pantke *et al.*, 1975). The syndrome is transmitted as an autosomal dominant trait with full penetrance and great variability in expression. Recently the responsible locus has been mapped on the long arm of chromosome seven (Brueton *et al.*, 1992). A small three generation family with the Saethre-Chotzen syndrome and one isolated case are presented in this report. Special attention is paid to the severity of the hearing loss in our cases and to the rehabilitation of the patient. The literature

on the craniosynostosis syndromes was reviewed for middle ear anomalies.

### Case reports

#### Family

The proband (Figure 1) is now a 21-year-old man. He was referred to the Nijmegen University Department of Otorhinolaryngology at the age of 17 years because of conductive hearing loss and chronic otitis media. Hearing loss was suspected from early childhood. A conventional hearing aid had caused chronic otorrhoea and pain because of pressure so it was impossible for him to use this type of hearing aid.

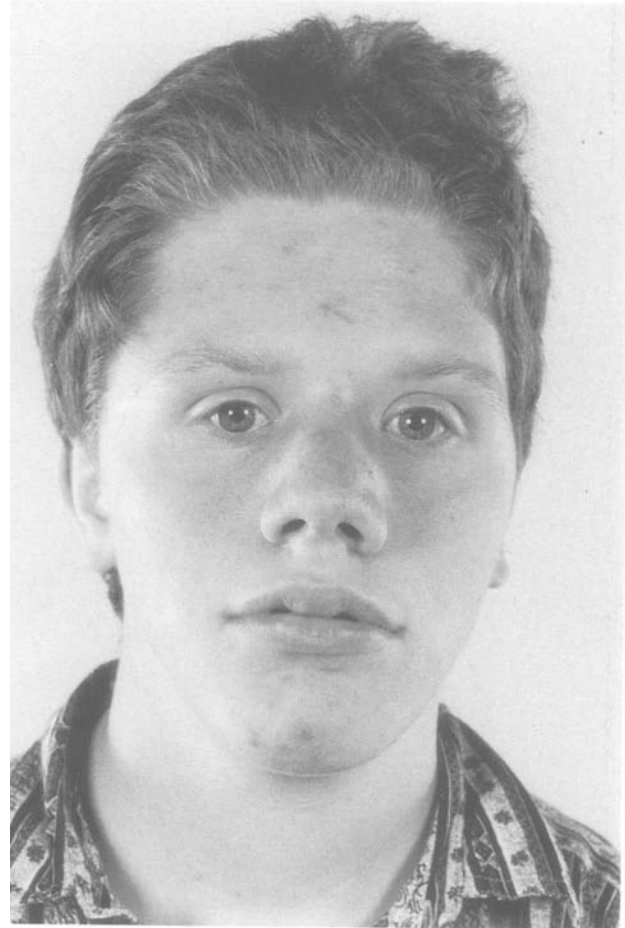
Otological examination showed small, normally-shaped ears with a normal position and normal auditory canals. Both tympanic membranes showed retraction. The middle ear was pneumatised on the right, there was a glue ear on the left side. Pure tone audiometry revealed a conductive hearing loss of 35 dB on the right and 60 dB on the left. Impedance measurements showed a flat curve bilaterally.

He is the only child of unrelated parents. He was treated for neonatal seizures until the age of one year. Because of premature closure of sutures a craniotomy was performed at the age of eight months. Later he was evaluated for a heart murmur, based on enlargement of a medially localised heart. At 11 years, he was treated for cryptorchidism of his left testicle. Various early developmental milestones were reported to have been delayed; at the age

From the Departments of Otorhinolaryngology\* and Human Genetics†, University Hospital Nijmegen, The Netherlands.  
Accepted for publication: 26 July 1996.



(a)



(b)

FIG. 1

Mother and proband with the typical appearances of Saethre-Chotzen.

of six years, his verbal IQ was equivalent to that of a developmental age of three years. At the age of seven years he was transferred to a special school for hearing-impaired children.

General physical examination revealed anomalies and other associated features of the Saethre-Chotzen syndrome (Figure 2) and are summarised in Table I.

Computed tomography (CT) scanning of the petrosal bones revealed a normal configuration of the inner and middle ear structures. Pneumatisation was markedly reduced bilaterally due to under development of the mastoids. Due to the small mastoids, presumed epitympanic fixation, lack of well-aerated middle ears and recurrent ear infections, known from literature to be present in various craniosynostosis syndromes; it was decided not to perform a exploratory tympanotomy.

His conventional hearing aid was replaced by a left-sided BAHA to rehabilitate his hearing. Hearing improved post-operatively with a functional gain to approximately an aided pure tone average (PTA) of 25 dB for his left ear.

His 43-year-old mother (Figure 1) was found to show minor features of the Saethre-Chotzen syndrome (Table I): small, non-dysplastic ears with normal position and minimal atresia of the right external auditory canal were present. Her audiogram showed pure conductive hearing loss with a PTA of 35 dB bilaterally.

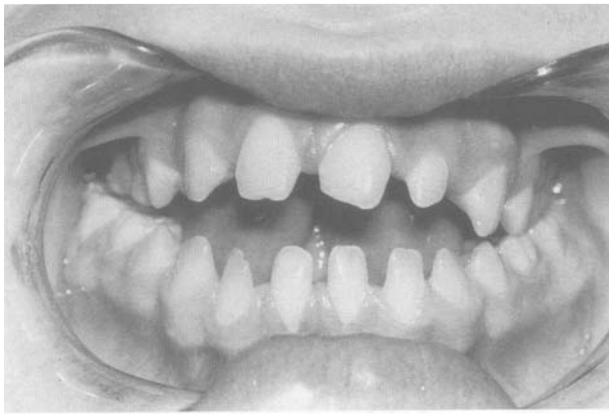
An audiogram of the proband's 65-year-old grandmother revealed pure conductive hearing loss with a PTA of 25 dB bilaterally. Mild characteristics of the Saethre-Chotzen syndrome were found at general physical examination (Figure 3).

The mother of the proband is the only child of unrelated parents. Her maternal uncle was not reported to exhibit any visible signs of Saethre-Chotzen syndrome but was not examined by the authors.

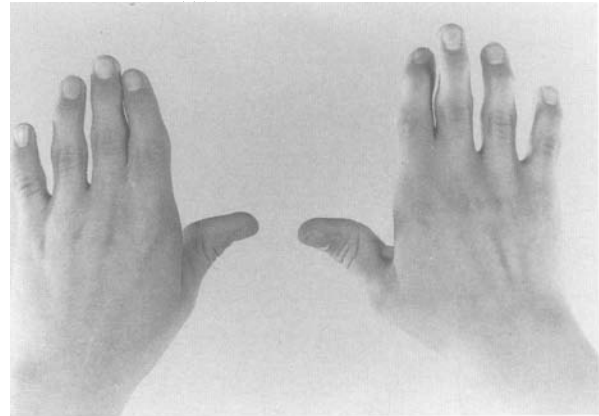
#### *Isolated case*

A 23-year-old woman with the Saethre-Chotzen syndrome presented with bilateral flat conductive hearing loss of 45 dB on the right and 30 dB on the left. There was bilateral congenital atresia of the external auditory canal type IIa. Characteristics of the Saethre-Chotzen syndrome were found at examination (Table I). The findings of CT scanning of the petrosal bones are shown in Figure 4.

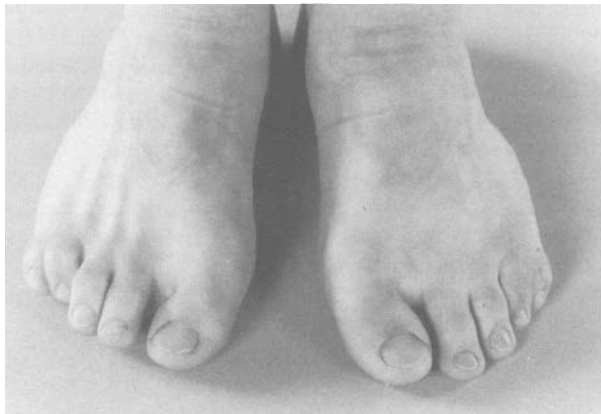Surgery was performed on the right ear to create a new auditory canal and tympanic membrane. This ear was selected for surgery because it had the most severe hearing loss. However, asymmetrical underdevelopment of the petrosal bones was more pronounced on this side and was considered to form a disadvantage for successful surgery. After removal of the bony plate, causing malleus fixation, the ossicular chain was found to be intact. The hearing level on the right side improved from 45 dB to 30 dB.



(a)



(c)



(b)

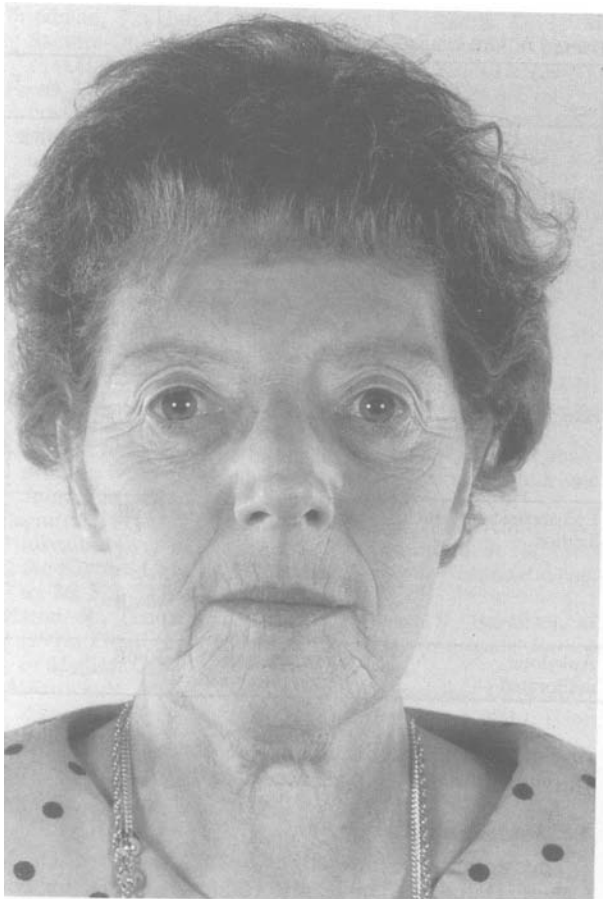FIG. 2  
Some characteristics of the proband; dental spacing with anomalous lateral incisors. Soft tissue syndactyly of the 2nd and 3rd fingers and 4th and 5th toes. Valgus position of a broad first toe.

TABLE I  
FEATURES PRESENT IN THE SAETHRE-CHOTZEN SYNDROME

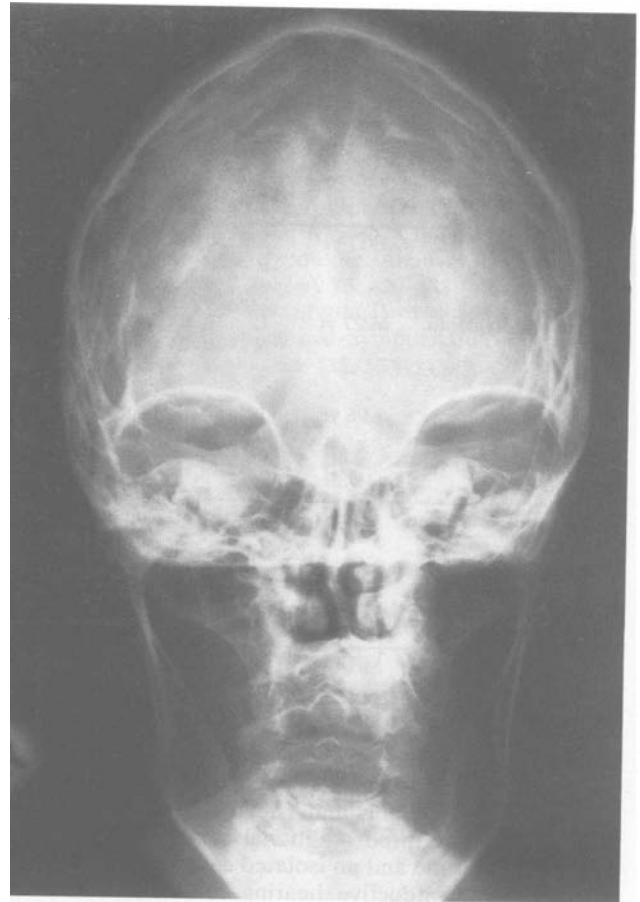
Findings	Pantke 120 cases	Case I (Figure 1)	Case II (Figure 1)	Case III (Figure 3)	Case IV
Low set frontal hairline		+	○	-	+
Acrocephaly	>75%	+	+	+	+
Nasal septum deviation		+	+	*	○
Ptosis of eyelids		+	+	+	+
Parrot-beaked nose		○	+	+	+
Brachydactyly		+	+	+	+
Low set ears	50-70%	-	-	-	-
Tear duct stenosis		-	-	-	-
Strabismus		-	-	-	-
Facial asymmetry		+	+	-	+
High arched palate		-	-	+	*
Spinal anomalies	25-50%	+ <sup>1</sup>	*	*	-
Dystopia cantorum		+	-	-	-
An.Lat.incisors (Figure 2)		+	*	*	-
Hypertelorism		-	-	-	-
Impaired hearing		+	+	+	+
Optic atrophy		*	*	*	*
Tissue syndactyly (Figure 2)	25%	+	+	-	+
Clinodactyly		+	+	*	-
Cleft palate		*	-	-	-
Cryptorchidism		+	-	-	-
Heart murmur		+	*	*	-
Renal anomalies	0-25%	+	*	*	*
Imperforate anus		-	-	-	-
Mental retardation		○	-	-	-

+ = present; ○ = moderate; - = absent; \* = unknown.

<sup>1</sup> Fusion of third and fourth cervical bodies; butterfly shaped VL<sub>5</sub>.



(a)



(b)

FIG. 3

Grandmother with Saethre-Chotzen syndrome and skull X-ray showing variations in bone density which is typical of the craniosynostosis syndromes.

### Discussion

Table II shows a summary of the specific anomalies of the middle ear in the Saethre-Chotzen, Apert, Crouzon and Pfeiffer syndromes reported in literature. In Saethre-Chotzen syndrome non-specified hearing loss has been reported (Chotzen, 1932; Aase and Smith, 1970; Friedman *et al.*, 1977; Kopysc *et al.*, 1980). The largest series reported conductive hearing loss in 15 per cent (Pantke *et al.*, 1975), but mixed hearing loss has also been mentioned (Marini *et al.*, 1991).

Hearing loss in the Apert syndrome was exclusively of a conductive nature. Middle ear effusion was present in the majority of investigated ears (Bergström *et al.*, 1972; Gould and Caldarelli, 1982; Phillips and Miyamoto, 1986). A primary anatomical malformation was noted infrequently in Apert syndrome by polytomography. Hearing loss in the Apert syndrome was primarily caused by altered nasopharyngeal anatomy (Peterson-Falzone *et al.*, 1981). It can be compared to otopathology in cleft palate, although in the Apert syndrome there is no resolution with age.

Large studies on the Crouzon syndrome have estimated that the incidence of conductive hearing loss is 55 per cent but pure sensorineural hearing loss has also been described. Middle ear effusion is less frequent (Kreiborg, 1981; Corey *et al.*, 1987). In one case with the Crouzon syndrome a second stage procedure was necessary after endaural widening epitympanotomy had resulted in re-fixation of the ossicular chain in the epitympanum (Cremers and Teunissen, 1991). In another case

stapedectomy improved the patients hearing (Boedts, 1967).

In the Pfeiffer syndrome conductive hearing loss, and ossicular chain anomalies have been described (Cremers, 1981). A mother and son with one of the rare craniosynostosis syndromes which presented as a distinct entity, pure conductive hearing loss and pure sensorineural hearing loss were described that involved the low and middle frequencies (Fryns *et al.*, 1990).

The most frequently encountered inherited syndromes with craniosynostosis are the Apert, Crouzon, Pfeiffer and Saethre-Chotzen syndromes. All have an autosomal dominant pattern of inheritance.

The physical findings in our proband closely resembled those in the original descriptions by Saethre and Chotzen. The proband, his mother and grandmother demonstrate aggravated and more pronounced features present in next generations of this dominant inherited condition.

The literature describes 16 families diagnosed as having the Saethre-Chotzen syndrome and some sporadic cases (Gorlin *et al.*, 1995).

Typical congenital anomalies of the middle ear in the cranio-synostosis syndromes include fixation of the ossicular chain in a small epitympanum and ankylosis of the stapes. Bony meatal atresia can also be present and in most cases the mastoid is small. Ventilation of the middle ear seems to be impaired because of Eustachian tube dysfunction.

TABLE II  
FINDINGS AND RESULTS OF EXPLORATORY EPITYMPANOTOMYS IN THE CRANIOSYNOSTOSIS SYNDROMES

Author/syndrome	Sex/age	Ear	Hearing loss	Malleus	Incus	Stapes	Recommended surgery	Hearing gain
Marini <i>et al.</i> , 1991 Saethre-Chotzen	M/2yr	L R	Mixed Mixed	Short handle Short handle			Unknown	Moderate hearing loss with sensorineural component.
Bergström <i>et al.</i> , 1972 Apert	F/17 yr	L R	50 dB, cond. 40 dB, cond.			Fixed footplate	Teflon prosthesis	None, slipped prosthesis
Philips and Miyamoto, 1986 Apert	M/27 yr	L R	30 dB, cond. 30 dB, cond.	Deformed Deformed		Bilateral thickened Footplate and posterior crus	Stapes mobilisation	Unknown
Phillips and Miyamoto, 1986 Apert	M/6 yr	L R	40 dB, cond. 50 dB, cond.		Fixed	Fixed	Incus removed Homograft malleus head placed on stapes capitulum	Minimal
Cremers and Teunissen, 1991 Crouzon		L R	55 dB, cond. none	Epitympanic fixation	Epitympanicankylotic fixation		Epitympanotomy of 15 dB congenital too small epitympanum	
Boedts, 1967 Crouzon	M/38 yr	L R	70 dB, cond. 20 dB, mixed				Shea piston	40 dB
Cremers, 1981 Pfeiffer	M/14 yr	L	45 dB, cond.	Ankylotic	Ankylotic, malformed		Stapedectomy, Teflon interposition	30 dB

Few results of ear surgery have been published on patients with craniosynostosis syndromes (Boedts, 1967; Cremers, 1981; Cremers and Theunissen, 1991).

In this report three additional cases of the Saethre-Chotzen syndrome and an isolated case are described. All of them had conductive hearing loss. The two oldest patients could be managed satisfactorily with a conventional hearing aid.

In the proband, reconstruction of the ossicular chain combined with stapes surgery was not performed mainly due to the combination of a small mastoid and recurrent ear infections. He proved to be a good candidate for a BAHA because he was unable to wear an air conduction hearing aid.

If surgical intervention is considered to be an option for patients with craniosynostosis, and fixation of the ossicular chain in the epitympanum and oval window has occurred, it may be possible to remove the incus and the head of the malleus and then perform a stapedectomy procedure by fixing the piston to the malleus handle. This procedure

would mean that refixation of the ossicular chain in the epitympanum is no longer necessary.

#### Acknowledgements

The authors acknowledge the assistance of Dr M. Cohen, Dalhousie University, Halifax, Canada, for confirming the diagnosis of the Saethre-Chotzen syndrome in the above reported family.

#### References

- Aase, J., Smith, D. (1970) Facial asymmetry and abnormalities of palms and ears. A dominantly inherited developmental syndrome. *Journal of Pediatrics* **6**: 928-930.
- Bergström, L., Neblett, L., Hemenway, G. (1972) Otologic manifestations of craniosynostosis syndromes. *Archives of Otolaryngology, Head and Neck Surgery* **96**: 117-123.
- Boedts, D. (1967) La surdit  dans la dysostose craniofaciale ou maladie de Crouzon. *Acta Oto-Rhino-Laryngologica Belgica* **21**: 43-55.
- Brueton, L., Herwerden van, L., Chotai, K., Winter, R. (1992) The mapping of a gene for craniosynostosis: Evidence for linkage of Saethre-Chotzen syndrome to distal chromosome 7p. *Journal of Medical Genetics* **21**: 681-685.
- Cantrell, S., Moore, M., Trott, J., Morris, R., David, D. (1994) Phenotypic variation in acrocephalosyndactyly syndromes: Unusual findings in patients with features of Apert and Saethre-Chotzen syndromes. *Craniofacial Cleft-Palate Journal* **31**: 487-493.
- Carter, C., Till, K., Fraser, V., Coffey, R. (1982) A family study of craniosynostosis with probable recognition of a distinct syndrome. *Journal of Medical Genetics* **19**: 280-285.
- Chotzen, F. (1932) Eine eigenartige Entwicklungsst rung (Acrocephalosyndactylie, Dysostosis craniofacialis und Hypertelorismus). *Monatsschrift f r Kinderheilkunde* **55**: 97-122.
- Corey, J., Caldarelli, D., Gould, H. (1987) Otopathology in cranial facial dysostosis. *American Journal of Otolaryngology* **8**: 14-17.
- Cremers, C. (1981) Hearing loss in Pfeiffer syndrome. *International Journal of Pediatric Otorhinolaryngology* **3**: 343-353.
- Cremers, C., Teunissen, E. (1991) The impact of a syndromal diagnosis on surgery for congenital minor ear anomalies. *International Journal of Pediatric Otorhinolaryngology* **22**: 159-174.

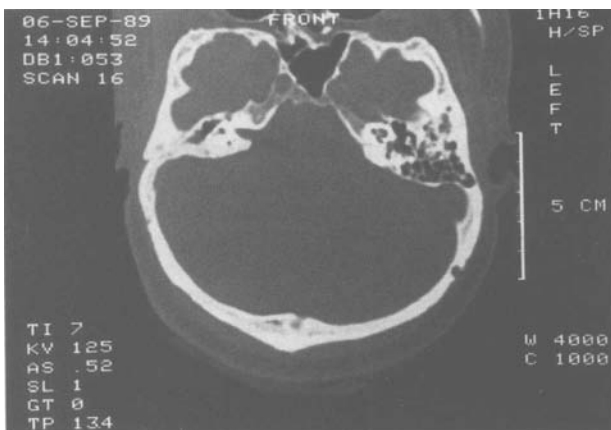

FIG. 4

CT scanning of the petrous bones in isolated case: marked asymmetry with reduced pneumatisation of the right petrous bone.

- Friedman, J., Hanson, J., Graham, C., Smith, D. (1977) Saethre-Chotzen syndrome: A broad and variable pattern of skeletal malformations. *Journal of Pediatrics* **12**: 929–933.
- Fryns, J., Vogels, A., Van den Berghe, H. (1990) Craniosynostosis and low middle frequency perceptive deafness in mother and son. A distinct entity? *Genetic Counselling* **1**: 63–66.
- Gorlin, R., Toriello, H., Cohen, M. (1995) *Hereditary hearing loss and its syndromes. The Saethre-Chotzen syndrome*. 1st Edition. Oxford University Press, New York pp 174–175.
- Gould, H., Caldarelli, D. (1982) Hearing and otopathology in Apert syndrome. *Archives of Otolaryngology, Head and Neck Surgery* **108**: 347–350.
- Kopysc, Z., Stanska, M., Ryszko, J., Kulczyk, B. (1980) The Saethre-Chotzen syndrome with partial bifid of the distal phalanges of the great toes. *Human Genetics* **56**: 195–204.
- Kreiborg, S. (1981) Crouzon syndrome. *Scandinavian Journal of Plastic and Reconstructive Surgery (Suppl 18)*: 1–109.
- Kurczinsky, T. W., Casperson, S. M. (1988) Auralcephalosyndactyly: A new hereditary craniosynostosis syndrome. *Journal of Medical Genetics* **25**: 491–493.
- Legius, E., Fryns, J., Berghe van den, H. (1989) Auralcephalosyndactyly: a new craniosynostosis syndrome or variant of the Saethre-Chotzen syndrome? *Journal of Medical Genetics* **26**: 522–524.
- Marini, R., Temple, K., Chitty, L., Genet, S., Baraitser, M. (1991) Pitfalls in counselling: the craniosynostoses. *Journal of Medical Genetics* **28**: 117–121.
- McKusick, V. A. (1992) *Catalogue of Autosomal Dominance, Autosomal Recessive and X-linked Phenotypes*. XII Edition. John Hopkins Press, Baltimore, pp 14–15.
- Pantke, O., Cohen, M., Witkop, C., Murray Feingold, M., Schaumann, B., Pantke, H., Gorlin, R. (1975) *The Saethre-Chotzen syndrome: Birth Defects: Original Article Series*. Vol. XI, no. 2, The Williams and Wilkins Company, Baltimore, pp 190–225.
- Peterson-Falzone, S., Pruzansky, S., Parris, P., Laffer, J. (1981) Nasopharyngeal dysmorphology in the syndromes of Apert and Crouzon. *Cleft Palate Journal* **18**: 237–250.
- Phillips, S., Miyamoto, R. (1986) Congenital conductive hearing loss in Apert syndrome. *Archives of Otolaryngology, Head and Neck Surgery* **95**: 429–433.
- Saethre, H. (1931) Ein Beitrag zum Turmschädelproblem (Pathogenese, Erblichkeit und Symptomatologie). *Deutsch Zeitschrift Nervenheilkunde* **117**: 533–543.

Address for correspondence:  
Dr H. A. M. Marres,  
Department of Otorhinolaryngology,  
University Hospital Nijmegen,  
P. O. Box 9101,  
6500 HB Nijmegen,  
The Netherlands.

Fax: 00-31-24-3540251