

## Brief Report

**Cite this article:** Said AS, McBride ME, Gazit AZ (2018) Successful preoperative bridge with extracorporeal membrane oxygenation in three neonates with D-transposition of the great vessels and pulmonary hypertension. *Cardiology in the Young* 28: 1175–1177. doi: 10.1017/S1047951118001038

Received: 29 December 2017

Revised: 7 May 2018

Accepted: 18 May 2018

**Key words:**

ECMO; PPHN; D-TGA; arterial switch; intensive care

**Author for correspondence:**

A. Z. Gazit, 660S. Euclid ave, Campus Box 8116, St. Louis, MO 63110, USA. Tel: +314 286 1246; Fax +13147478880. Email: Gazit\_a@wustl.edu

# Successful preoperative bridge with extracorporeal membrane oxygenation in three neonates with D-transposition of the great vessels and pulmonary hypertension

Ahmed S. Said<sup>1</sup>, Mary E. McBride<sup>2</sup> and Avihu Z. Gazit<sup>1</sup>

<sup>1</sup>Department of Pediatrics, Division of Critical Care, Washington University in St. Louis, St. Louis, MO, USA and

<sup>2</sup>Department of Pediatrics, Divisions of Cardiology and Critical Care, Northwestern University Feinberg School of Medicine, Chicago, IL, USA

**Abstract**

Pulmonary hypertension with transposition of the great arteries is associated with significant morbidity and mortality. At the worst end of the spectrum are patients who undergo extracorporeal support perioperatively. We describe our experience with three patients who received preoperative extracorporeal support and separated from cardiopulmonary bypass successfully on conventional postoperative care, with no significant deficits on follow-up.

Dextro-transposition of the great arteries and intact ventricular septum associated with persistent pulmonary hypertension is uncommon and associated with poor outcomes.<sup>1</sup> Several therapeutic interventions have been described to improve systemic oxygen delivery and reduce oxygen consumption including balloon atrial septostomy, prostaglandin infusion to maintain ductal patency, inotropic support,<sup>2</sup> inhaled nitric oxide,<sup>3,4</sup> epoprostenol,<sup>5</sup> bosentan<sup>6</sup>, and extracorporeal membrane oxygenation.<sup>4,7,8</sup> We present three patients with dextro-transposition of the great arteries, intact ventricular septum, and refractory persistent pulmonary hypertension of the newborn supported with extracorporeal membrane oxygenation preoperatively, separated from bypass following their arterial switch operation and survived to discharge with favourable long-term follow-up.

**Case presentations****Case 1**

A term male newborn was diagnosed postnatally with dextro-transposition of the great arteries and intact ventricular septum with a large atrial septal defect and patent ductus arteriosus. He remained hypoxaemic with evidence of low systemic oxygen delivery likely secondary to pulmonary hypertension in spite of escalation in support. Given continued evidence of cardiogenic shock, he underwent veno-arterial extracorporeal membrane oxygenation cannulation on day of life 1 and arterial switch operation on day 8 of support. He was separated from bypass successfully, albeit with evidence of pulmonary hypertension requiring sedation, neuromuscular blockade, mechanical ventilation, inhaled nitric oxide, and inotropic support. He was extubated on postoperative day 9 and discharged on postoperative day 12. At the most recent follow-up visit, he was 5 years old and doing well. He has no evidence of adverse sequelae related to extracorporeal support.

**Case 2**

A near-term male infant – 37 weeks' gestation – was diagnosed postnatally with dextro-transposition of the great arteries and intact ventricular septum and restrictive atrial septum. Following intubation and initiation of prostaglandin E1, balloon atrial septostomy was performed. In spite of initiation of inhaled nitric oxide and significant escalation in support, he developed evidence of cardiogenic shock and underwent initiation of veno-arterial extracorporeal membrane oxygenation on day of life 3. After an arterial switch operation on extracorporeal support day 3, he was separated successfully from bypass and returned to the ICU with an open sternum, on inhaled nitric oxide and inotropic support. Following delayed sternal closure on postoperative day 12, the patient had ongoing respiratory failure, persistent chylothorax, and pulmonary hypertension. Thus, an open lung biopsy was performed, which revealed diffuse arterial wall and venous intima thickening, as well as pulmonary interstitial

glycogenosis. Given these findings, he was treated with a course of systemic steroids, extubated on postoperative day 40, and transitioned from inhaled nitric oxide to sildenafil and bosentan. These medications were weaned gradually and discontinued 5 months after discharge. At his last follow-up visit, he was 7 years old. He has mild right-ventricular outflow tract obstruction with no evidence of adverse sequelae related to extracorporeal support.

### Case 3

A premature twin male infant – 35 weeks' gestation – was postnatally diagnosed with dextro-transposition of the great arteries and intact ventricular septum with right to left flow across a restrictive patent foramen ovale, as well as right to left ductus arteriosus flow (Fig 1). He was intubated and treated with surfactant followed by initiation of prostaglandin E1, inhaled nitric oxide, inotropic support, and balloon atrial septostomy. On day of life 2 – because of evidence of cardiogenic shock – he was urgently placed on veno-arterial extracorporeal membrane oxygenation and developed posterior subdural haematoma while on support. He underwent an arterial switch operation on support day 8 and was successfully separated from bypass. The post-operative course was favourable, allowing weaning and discontinuation of inhaled nitric oxide, and inotropic support followed by extubation on postoperative day 3. At his last follow-up visit, he was 8 years old, and asymptomatic with evidence of mild pulmonary and aortic insufficiency. He has no evidence of adverse sequelae related to extracorporeal support or the subdural haematoma.

### Discussion

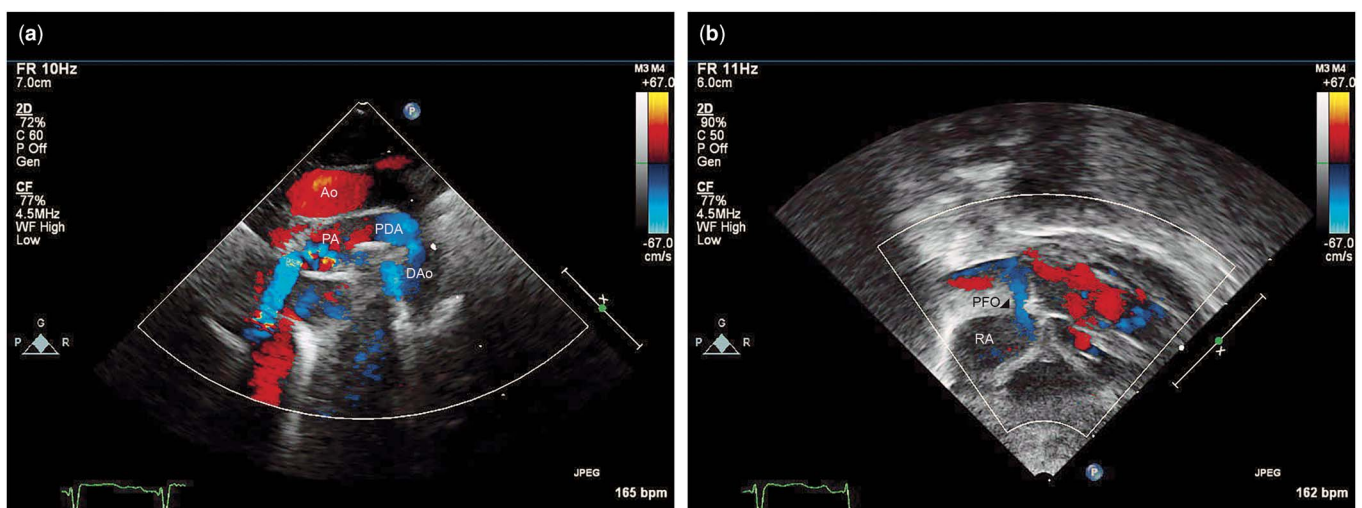
Transient postnatal elevation of pulmonary vascular resistance is common and relatively benign. However, persistent pulmonary hypertension of the newborn defined as failure to achieve or sustain the normal decrease in pulmonary vascular resistance at birth may lead to severe hypoxaemia and need for aggressive cardiorespiratory support including – albeit less frequent following introduction of inhaled nitric oxide – extracorporeal oxygenation. Persistent pulmonary hypertension refractory to medical management and – when indicated – balloon atrial

septostomy in neonates with dextro-transposition of the great arteries and intact ventricular septum significantly increases the mortality of these patients, with preoperative mortality rates of up to 28.6%<sup>9</sup> as compared with the reported mortality rates of the transposition of the great arteries population of <5%.<sup>10</sup>

At the most severe end of the spectrum are patients who require extracorporeal oxygenation preoperatively because of progressive cardiogenic shock and risk for end-organ injury and cardiac arrest. These cases are uncommon, especially with introduction of inhaled nitric oxide and other potent pulmonary vasodilators. However, such patients require a thoughtful approach with regard to the timing and mode of support (veno-arterial vs. veno-venous), management on extracorporeal support, and timing of the arterial switch operation. Unfortunately, only few reports are available on these patients, and none of them describe successful separation from bypass following arterial switch operation with favourable long-term outcomes.<sup>4,7,8</sup> Each of our patients showed clinical and biochemical signs of progressive shock leading to oxygen debt in spite of significant escalation of support. To prevent irreversible end-organ injury and cardiac arrest with further escalation of conventional support, veno-arterial extracorporeal membrane oxygenation was initiated. Veno-arterial rather than veno-venous support was thought to be indicated in our patients because of the degree of cardiogenic shock. However, if oxygen delivery meets uptake needs, veno-venous support may be beneficial as it would lead to return of oxygenated blood into the right atrium and from there mostly into the right ventricle and aorta while sparing the carotid artery.

Timing of initiation of extracorporeal support is critical, as shown by Gill et al<sup>11</sup> who studied neonates with meconium aspiration syndrome cannulated for extracorporeal support between 1989 and 1998. They found that delay in cannulation while assessing the effects of inhaled nitric oxide and high-frequency ventilation was associated with an increase in mortality and prolongation of hospital stay.

The pathophysiology of complete transposition of the great arteries places neonates with persistent pulmonary hypertension at a disadvantage in comparison with a neonate with normal cardiac anatomy because of high-volume physiological shunting and the dependency of effective pulmonary blood flow on small-



**Figure 1.** (a) Suprasternal notch long-axis colour flow Doppler view showing a patent ductus arteriosus (PDA) with evidence of pulmonary artery (PA) to descending aorta (DAo) flow. (b) Subcostal coronal colour flow Doppler view showing right atrium (RA) to left atrium flow across the patent foramen ovale (PFO). Both flow patterns may occur in the context of pulmonary hypertension.

volume anatomical shunting via the patent ductus arteriosus and atrial septal defect.

While correcting the anatomy in the operating room is the ultimate goal, cardiopulmonary bypass and cross-clamping of the aorta may cause further increase in pulmonary vascular resistance, as well as myocardial inflammation and low cardiac output syndrome, leading to risk of further end-organ injury post-operatively. We believe that preoperative extracorporeal support in these patients provides optimisation of end-organ function, facilitates protective mechanical ventilation and safe administration of pulmonary vasodilators, and haemodynamic unloading of the pulmonary vascular tree before the unavoidable operation-related insults. The shortest duration of support that provides normalisation of end-organ function, discontinuation of vaso-pressors, and weaning ventilator settings is preferred as a bridge to the arterial switch operation to avoid complications related to the support.

### Conclusion

Patients with dextro-transposition of the great arteries and intact ventricular septum and pulmonary hypertension with refractory hypoxaemia and haemodynamic compromise may benefit from a period of stabilisation on extracorporeal support before their arterial switch operation. An attempt should be made to separate such patients from cardiopulmonary bypass rather than transitioning back to extracorporeal support at the conclusion of a successful operation.

**Acknowledgements.** The authors would like to acknowledge the critical care, cardiology, cardiothoracic surgery and perfusion divisions who successfully cared for these patients.

**Financial Support.** This research received no specific grant from any funding agency or from commercial or not-for-profit sectors.

**Conflicts of Interest.** None.

**Ethical Standards.** This article does not contain any studies with human participants performed by any of the authors.

### References

1. Kirklin JW, Blackstone EH, Tchervenkov CI, Castaneda AR. Clinical outcomes after the arterial switch operation for transposition. Patient, support, procedural, and institutional risk factors. *Congenital Heart Surgeons Society. Circulation* 1992; 86: 1501–1515.
2. Chang AC, Wernovsky G, Kulik TJ, Jonas RA, Wessel DL. Management of the neonate with transposition of the great arteries and persistent pulmonary hypertension. *Am J Cardiol* 1991; 68: 1253–1255.
3. El-Segaier M, Hellstrom-Westas L, Wettrell G. Nitric oxide in neonatal transposition of the great arteries. *Acta Paediatr* 2005; 94: 912–916.
4. Jaillard S, Belli E, Rakza T, et al. Preoperative ECMO in transposition of the great arteries with persistent pulmonary hypertension. *Ann Thorac Surg* 2005; 79: 2155–2158.
5. Kovach J, Ibsen L, Womack M, Steusse D, Law YM. Treatment of refractory pulmonary arterial hypertension with inhaled epoprostenol in an infant with congenital heart disease. *Congenit Heart Dis* 2007; 2: 194–198.
6. Goissen C, Ghyselen L, Tourneux P, et al. Persistent pulmonary hypertension of the newborn with transposition of the great arteries: successful treatment with bosentan. *Eur J Pediatr* 2008; 167: 437–440.
7. Luciani GB, Chang AC, Starnes VA. Surgical repair of transposition of the great arteries in neonates with persistent pulmonary hypertension. *Ann Thorac Surg* 1996; 61: 800–805.
8. Trittenwein G, Furst G, Golej J, et al. Preoperative ECMO in congenital cyanotic heart disease using the AREC system. *Ann Thorac Surg* 1997; 63: 1298–1302.
9. Roofthoof MT, Bergman KA, Waterbolk TW, Ebels T, Bartelds B, Berger RM. Persistent pulmonary hypertension of the newborn with transposition of the great arteries. *Ann Thorac Surg* 2007; 83: 1446–1450.
10. Khairy P, Clair M, Fernandes SM, et al. Cardiovascular outcomes after the arterial switch operation for D-transposition of the great arteries. *Circulation* 2013; 127: 331–339.
11. Gill BS, Neville HL, Khan AM, Cox CS Jr, Lally KP. Delayed institution of extracorporeal membrane oxygenation is associated with increased mortality rate and prolonged hospital stay. *J Pediatr Surg* 2002; 37: 7–10.