

## Short Communication

# Closure of large tracheocutaneous fistula using turn-over hinge flap and V-Y advancement flap

BYUNG-JOO LEE, M.D., EUI-KYUNG GOH, M.D., SOO-GEUN WANG, M.D., SO-MIN HWANG, M.D.\*

### Abstract

Tracheocutaneous fistula is a frequent sequel of long-term tracheostomy or tracheal fenestration. Closure of fistula is complicated by the presence of extensive scar tissue, mucopurulent secretions, and tension from insufficient advancement of adjacent soft tissue. We report two successfully closed cases of large tracheocutaneous fistulae using a hinge flap and a V-Y advancement flap.

**Key words:** Trachea; Skin; Fistula; Surgical Procedures, Operative

### Introduction

A tracheocutaneous fistula is a complication of the tracheotomy, and it has been reported that its frequency of occurrence ranges from 3.3 per cent to 29 per cent.<sup>1</sup> A fistula represents an overgrowth of the epithelial layer up to the mucosa of the trachea along the tracheotomy tract. The incidence of fistula formation is closely related to the time of cannulation. Kulber *et al.*<sup>2</sup> reported that a fistula does not develop when the duration of cannulation is less than 16 weeks, but its incidence goes up to 70 per cent when the retention period is 16 weeks or more. Also, it is sometimes difficult to close the tracheocutaneous fistula developed during tracheal fenestration performed for conservative laryngeal surgery.

Fistulae increase the possibility of respiratory tract infections, including repeated aspiration and pneumonia. They also cause difficulties in phonation, coughing, cosmetic problems, and limitations to daily activities, including swimming and bathing. Therefore, a surgical closure is necessary when a fistula occurs.

Tracheocutaneous fistulae can be closed using concha cartilage,<sup>3</sup> skin flap,<sup>4</sup> or Z-plasty.<sup>5,6</sup> Keenan *et al.*<sup>7</sup> stated that there was a high possibility of pneumomediastinum, pneumothorax, and wound breakdown in the case of the primary closure following a fistulectomy, and therefore, that the secondary intention was better. However, when a fistula is too large to be naturally closed with the secondary intention, a secondary surgical closure is necessary. In addition, a study<sup>8</sup> has reported that a fistula can be closed with a multilayer suture after a fistulectomy. Another study<sup>9</sup> reported that the tracheocutaneous fistula developed after a cricothyroidectomy was closed with the perichondrial flap of the thyroid cartilage. Also, there is a report<sup>10</sup> that a radiated tracheocutaneous fistula was closed with the use of a skin flap. However, it is hard to find a report on the surgical closure of a fistula whose

diameter is 1 cm or greater. Only Berenholz *et al.*<sup>11</sup> have reported that a fistula of greater than 1 cm was successfully closed using a muscular flap after a fistulectomy, but there has not been a report on a simple and safe surgical closure for a large tracheocutaneous fistula of greater than 1 cm.

This paper reports two successfully closed cases of large tracheocutaneous fistulae (diameter of 10 mm or greater) with a new method using a hinge flap and a V-Y advancement flap in patients who underwent tracheal fenestration during conservative partial laryngectomy.

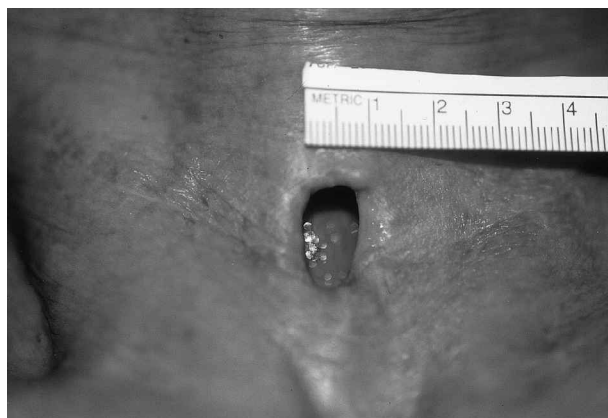### Surgical technique

The procedure was performed under local anaesthesia with two per cent lidocaine added to 1:100 000 epinephrine. A triangular flap with the superior and the inferior margin of the fistula as a base, and a tetragonal flap with the lateral margin as a base, were elevated (Figure 1). The turn-over hinge flaps were sutured with 5.0 PDS to make an inner lining. Both the superior and the inferior triangular regions of the hinge flaps were de-epithelized to prevent a 'dog-ear' developing (Figure 2). The outer lining was created by suturing it with 5.0 nylon after conducting the V-Y advancement flap (Figure 3). A drain was not inserted after careful control of bleeding. Antibiotics and mucolytic agents were administered for several days following the operation.

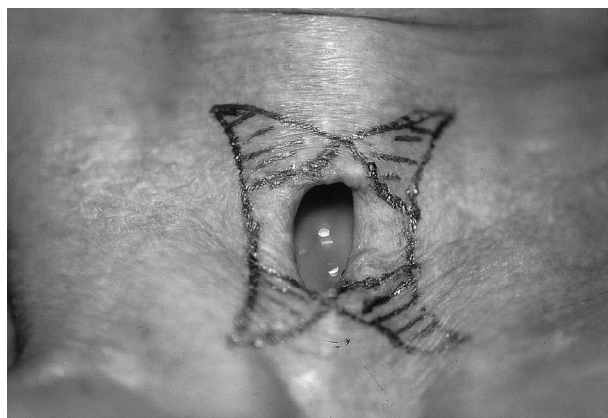
### Discussion

A tracheocutaneous fistula may generally be sutured after a fistulectomy or the fistula can be closed using a hinge flap or a bipedicle flap. However these methods can only be employed for small fistulae. When these methods are used for a fistula with a diameter of 1 cm or greater, the fistula may recur, due to the tension of the skin, or a cosmetic problem may arise with the development of a 'dog-ear'.

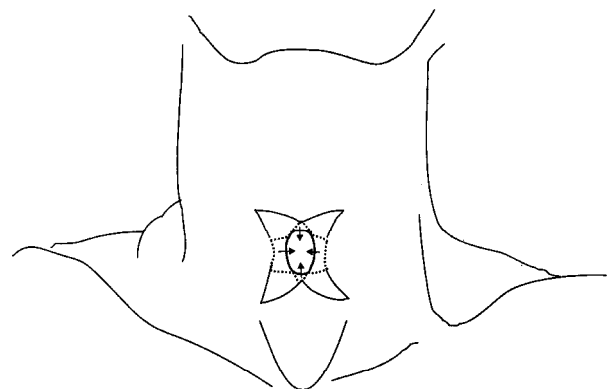
Departments of Otolaryngology, and Plastic Surgery\*, College of Medicine, Pusan National University, Pusan, Korea.  
Presented at the 75th congress of Korean Society of Otolaryngology, Seoul, Korea, October 12–14, 2001.  
Accepted for publication: 21 February 2002.



(a)



(b)

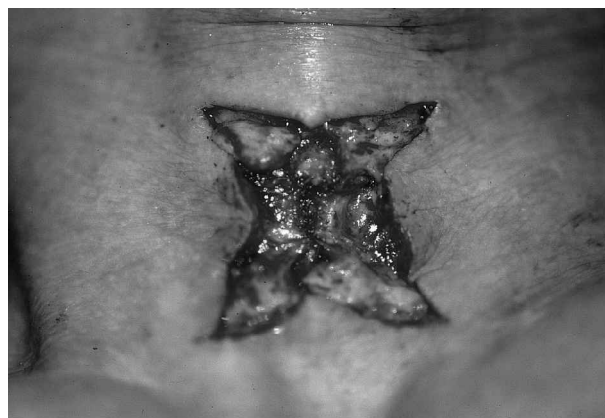


(c)

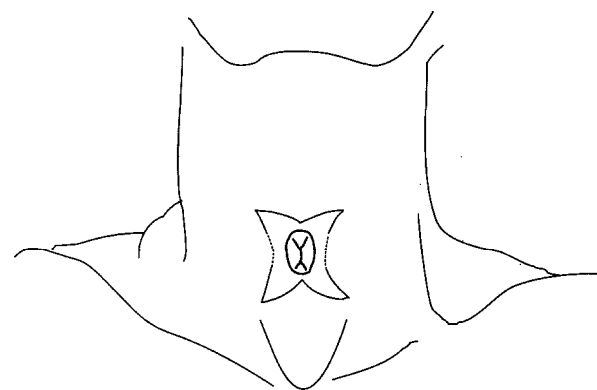
FIG. 1

Pre-operative findings. (a) A large tracheocutaneous fistula (10 × 17 mm). (b) Superior, inferior, and both lateral hinge flaps are outlined around the fistula. Both superior and inferior triangular regions (marked area) will be de-epithelialized. (c) Illustration of a hinge flap.

The method invented by the authors can make a two-layer closure with just a single operation. The V-Y advancement flap decreases the tension of the skin and therefore reduces the possibility of a fistula recurring. It is also an excellent method in a cosmetic sense because it can prevent the occurrence of a 'dog-ear' (Figure 4). In addition, the new method does not use a muscle or a perichondrial layer to close a fistula, so there is little possibility of bleeding, making the insertion of a drain unnecessary. Keenan *et al.*<sup>7</sup> reported that in the case of suturing after a fistulectomy, complications such as



(a)



(b)

FIG. 2

Intra-operative finding. (a) The inner layer is closed by turn-over hinge flaps. (b) Illustration of the inner layer closure.

pneumomediastinum, pneumothorax, subcutaneous emphysema, or airway obstruction can develop. But no complication arose during the use of this method.

### Conclusion

This paper describes a simple method for closing large tracheocutaneous fistulae that developed after conservative partial laryngectomy. Good cosmetic results were obtained without any complications or recurrence.

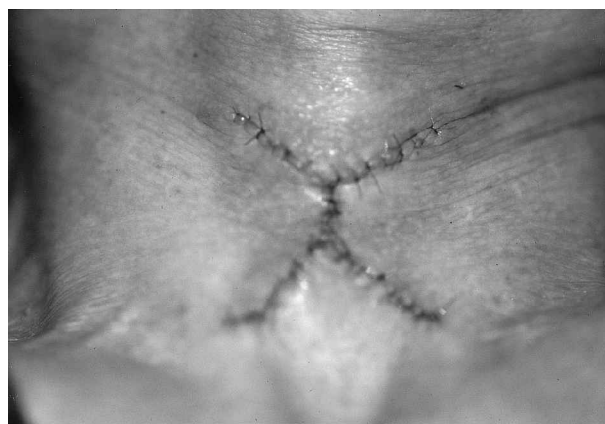

FIG. 3

Immediate post-operative finding after the closure of the outer layer by V-Y advancement flap.

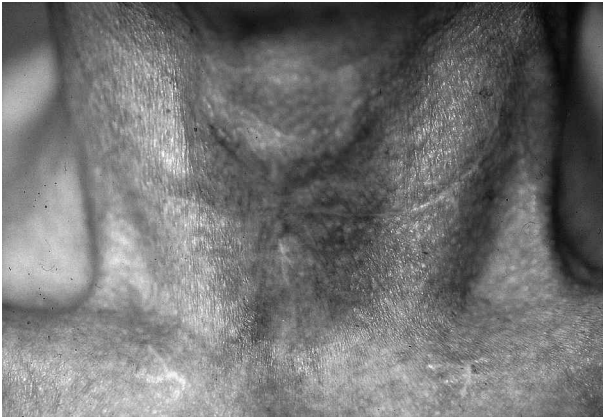


FIG. 4

Good cosmetic and functional results three months after closure using a turn-over hinge flap and a V-Y advancement flap.

#### References

- 1 White KA, Smitheringale AJ. Treatment of tracheocutaneous fistula in children. *J Otolaryngol* 1989;**18**:49–52
- 2 Kulber H, Passy V. Tracheotomy closure and scar revisions. *Arch Otolaryngol* 1972;**96**:2–26
- 3 Jackson C, Babcock WW. Plastic closure of tracheocutaneous fistula. *Surg Clin N Am* 1934;**14**:199–221
- 4 Lawson DW, Grillo HC. Closure of persistent tracheal stoma. *Surg Gynecol Obstet* 1970;**30**:495–6
- 5 Vecchione TR, Pickering PP. The subcutaneous Z-plasty. *Plast Reconstr Surg* 1975;**51**:579–80
- 6 Goldsmith AJ, Abramson AL, Myssiorek D. Closure of tracheocutaneous fistula using a modified cutaneous Z-plasty. *Am J Otolaryngol* 1993;**14**:240–5
- 7 Keenan JP, Snyder GG 3rd, Lehmann WB, Ruiz JW. Management of tracheocutaneous fistula. *Arch Otolaryngol* 1978;**104**:530–1
- 8 Stern Y, Cosenza M, Walner DL, Cotton RT. Management of persistent tracheocutaneous fistula in the pediatric age group. *Ann Otol Rhinol Laryngol* 1999;**108**:880–3
- 9 Fisher SR. Closure of tracheocutaneous fistula with perichondrial flap following cricothyroidotomy. *Laryngoscope* 1991;**101**:684–5
- 10 Jacobs JR. Bipedicle delayed flap closure of persistent radiated tracheocutaneous fistulas. *J Surg Oncol* 1995;**59**:196–8
- 11 Berenholz LP, Vail S, Berlet A. Management of tracheocutaneous fistula. *Arch Otolaryngol Head Neck Surg* 1992;**118**:869–71

Address for correspondence:

So-Min Hwang, M.D.,  
Department of Plastic Surgery, College of Medicine,  
Pusan National University,  
10, Ami-dong, Seo-gu,  
Pusan, Korea, 602-739,

---

Dr S.-M. Hwang takes responsibility for the integrity of the content of the paper.

Competing interests: None declared

---