

# Where's the Tube? Evaluation of Hand-held Ultrasound in Confirming Endotracheal Tube Placement

Rosaleen Chun, MD, FRCPC;<sup>1</sup> Andrew W. Kirkpatrick, MD, FRCSC, FACS;<sup>2,3</sup>  
M. Sirois, MD, FRCSC;<sup>4</sup> A.E. Sargasyn, MD;<sup>5</sup> S. Melton, PEng;<sup>5</sup>  
D.R. Hamilton, FRCPC, PhD;<sup>5</sup> S. Dulchavsky, MD, FACS, PhD<sup>6</sup>

1. Department of Anesthesia, Foothills Medical Centre, Calgary, Alberta, Canada
2. Department of Critical Care Medicine, Foothills Medical Centre, Calgary, Alberta, Canada
3. Department of Surgery, Foothills Medical Centre, Calgary, Alberta, Canada
4. Section of Trauma Services, Vancouver Hospital and Health Sciences Centre, Vancouver, British Columbia, Canada
5. Wyle Life Sciences, Houston, Texas USA
6. Henry Ford Hospital, Detroit, Michigan USA

#### Correspondence:

AW Kirkpatrick  
Foothills Medical Centre  
1403 29th Street NW  
Calgary, Alberta, T2N 2T9 Canada  
E-mail: andrew.kirkpatrick@calgary-healthregion.ca

This manuscript is based in part on a presentation at the 74<sup>th</sup> Annual Scientific Meeting of the Aerospace Medical Association (AsMA), San Antonio, Texas, 07 May 2003.

**Keywords:** endotracheal tube placement; portable, hand-held ultrasound; pulmonary ventilation; resuscitation; thoracic ultrasound

#### Abbreviations:

CPD = color-power Doppler  
CTA = comet-tail artifacts  
ETT = endotracheal tube  
LS = lung sliding  
PHHU = portable, hand-held ultrasound  
RMI = right main-stem intubation  
US = ultrasound  
VPPI = visceral-parietal pleural interface

Received: 01 February 2004

Accepted: 17 June 2004

Revised: 12 July 2004

Web publication: 10 November 2004

#### Abstract

**Introduction:** The diagnosis of endotracheal tube (ETT) mal-position may be delayed in extreme environments. Several methods are utilized to confirm proper ETT placement, but these methods can be unreliable or unavailable in certain settings. Thoracic sonography, previously utilized to detect pneumothoraces, has not been tested to assess ETT placement.

**Hypothesis:** Thoracic sonography could correlate with pulmonary ventilation, and thereby, help to confirm proper ETT placement.

**Methods:** Thirteen patients requiring elective intubation under general anesthesia, and data from two trauma patients were evaluated. Using a portable, hand-held, ultrasound (PHHU) machine, sonographic recordings of the chest wall visceral-parietal pleural interface (VPPI) were recorded bilaterally in each patient during all phases of airway management: (1) pre-oxygenation; (2) induction; (3) paralysis; (4) intubation; and (5) ventilation. **Results:** The VPPI could be well-imaged for all of the patients. In the two trauma patients, right mainstem intubations were noted in which specific pleural signals were not seen in the left chest wall VPPI after tube placement. These signs returned after correct repositioning of the ETT tube. In all of the elective surgery patients, signs correlating with bilateral ventilation in each patient were imaged and correlated with confirmation of ETT placement by anesthesiology.

**Conclusions:** This report raises the possibility that thoracic sonography may be another tool that could be used to confirm proper ETT placement. This technique may have merit in extreme environments, such as in remote, pre-hospital settings or during aerospace medical transports, in which auscultation is impossible due to noise, or capnography is not available, and thus, requires further scientific evaluation.

Chun R, Kirkpatrick AW, Sirois M, Sargasyn AE, Melton S, Hamilton DR, Dulchavsky S: Where's the tube? Evaluation of hand-held ultrasound in confirming endotracheal tube placement. *Prehosp Disast Med* 2004;19(4):366-369.

#### Introduction

Medical and surgical emergencies in extreme environments often rely on early endotracheal intubation, as medical resources to recoup an unanticipated lost airway are limited. Endotracheal tubes (ETTs) may be misplaced into the esophagus or hypopharynx, or may be placed too far into a main-stem bronchus, with resultant atelectasis of the non-ventilated lung. In-hospital rates of incorrect ETT placement into a mainstem bronchus range from 5% to 10%.<sup>1</sup> Rates of ETT misplacement in those arriving to emergency departments already intubated range from 5.8% to 18%.<sup>2-3</sup> Moreover, the presence of end-tidal CO<sub>2</sub>, the gold standard for confirmation of ETT placement, has been observed in mal-positioned ETTs.<sup>2-3</sup>

Particularly in prehospital and operational settings, confirmation of proper ETT placement can be challenging. Ultrasound (US), and more specifi-

Lung ventilation	Lung Sliding (LS)		Comet-tail Artefact (CTA)		Color-power Doppler (CPD)	
	Right	Left	Right	Left	Right	Left
Hemi-thorax	Right	Left	Right	Left	Right	Left
Normal	+	+	+	+	+	+
Apnea*	-	-	+	+	-	-
Right main-stem intubation	+	-	+	+	+	-

Prehospital and Disaster Medicine © 2004 Kirkpatrick

**Table 1**—Thoracic ultrasound definitions (+ = present; - = absent; \*failure of lungs to be ventilated either from paralysis or esophageal intubation)

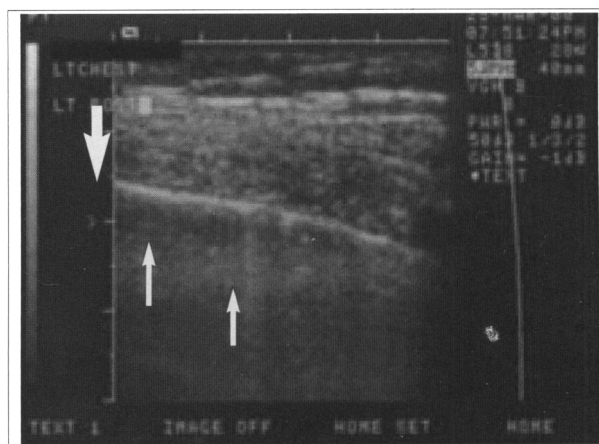
cally, portable, hand-held, ultrasound (PHHU), is a light-weight, diagnostic modality that is being used increasingly by clinicians to provide an additional sensory modality to the physical examination. These devices have been shown to demonstrate excellent diagnostic performance after abdominal and extremity injuries.<sup>4-5</sup> More recently, the use of US also has been demonstrated to quickly exclude pneumothoraces after multi-system traumatic injuries.<sup>6-8</sup>

The specific attributes of thoracic sonography in detecting pneumothoraces have been well-described.<sup>9-11</sup> In brief, although only artifacts actually are seen as deep to the normal visceral-parietal pleural interface (VPPI), a wealth of information can be obtained from the real-time examination of the normal physiologic movement of these two surfaces against one another (Figure 1). The observation of the sonographic signs of lung sliding (LS), its enhanced depiction with color-power Doppler (CPD) (Figure 2), and moving comet-tail artefacts (CTA), require pleural apposition. Thus, these signs are lost when even small amounts of air (pneumothorax) separate the two pleural surfaces.<sup>9</sup>

While studying the utility of emergent thoracic US examinations in the critically ill, it was hypothesized that by reinterpreting the diagnostic algorithm previously reported to detect pneumothoraces,<sup>7,9,12</sup> the US inspection of the VPPI would further correlate with pulmonary ventilation. Thus, by using this technique, the ability to confirm ETT position would be conceivable. Therefore, patients were enrolled prospectively into this case series.

## Methods

Patients were evaluated for the study if they required endotracheal intubation for elective surgery. After informed consent and ethics approval, 13 patients were enrolled in the study. Data from two ultrasound examinations also were available from a separate trauma study. Both of these patients had had thoracic ultrasound examinations after multi-system traumatic injury, and were examined immediately prior to and following intubation. Approval by the Institutional Human Ethics Committee was obtained to include data from the trauma patients. Both hemi-thoraces in each patient were examined using a high frequency 10-5 MHz linear array transducer and a 2.4 kg hand-held, ultrasound unit (Sonosite 180, Sonosite Corporation,



Prehospital and Disaster Medicine © 2004 Kirkpatrick

**Figure 1**—Visceral-parietal pleural interface (VPPI). The large arrow illustrates the Actual VPPI surface; the smaller arrows point out what resembles a faint “comet tail,” with the head at the VPPI surface and echogenic “tail” reflecting toward the smaller arrows. The “tail” is thought to arise from hyperechogenic reverberation artefact that is believed to arise from the pleural line, hence the “comet-tail artefact (CTA)”. In real time, the CTA is seen to translate in time with the moving apposed pleural surfaces. This can be viewed on the Internet at <http://www.tac.medical.org/videolinks.htm>.

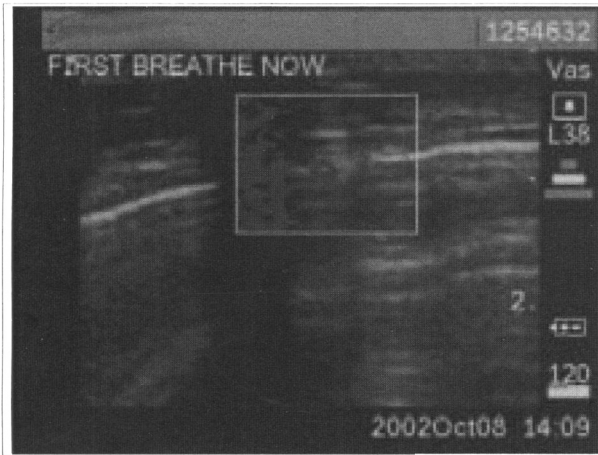
Bothell, WA). All examinations were recorded for later analysis using a digital videocassette recorder (GV-D800 NTSC, Sony Corp., Japan).

The VPPI was the focal point of the ultrasonic evaluation. To obtain a standardized image, the transducer was placed between the third and fourth intercostal space of the left, and then the right hemi-thorax, and manipulated to bring the VPPI into the focal point of the sonographic image during a period of normal ventilation. Within each VPPI image, the presence or absence of the lung sliding, color-power Doppler, and comet-tail artifacts signs was determined. This allowed a baseline assessment of the normal pleural US findings pre-intubation, during intubation, and post-intubation (Figures 1 and 2). Diagnostic US definitions are provided in Table 1.

In the elective intubation cases, both hemi-thoraces were imaged with the PHHU during all phases including: (1) pre-oxygenation; (2) anesthesia induction with ensuing apnea and mask ventilation; (3) during endotracheal intubation; and (4) with positive pressure ventilation immediately after ETT placement.

## Results

In all 13 elective surgery patients and two trauma patients, the VPPI could be well imaged. There were no “indeterminate” examinations. In the operating theatre, LS, CPD, and CTA signs were visualized on both the left and right lung fields, pre-induction of anesthesia (Figure 2). While the CTA sign remained at all times (inferring normal pleural apposition), the LS and CPD signs were absent bilaterally at all apneic time points (i.e., after induction



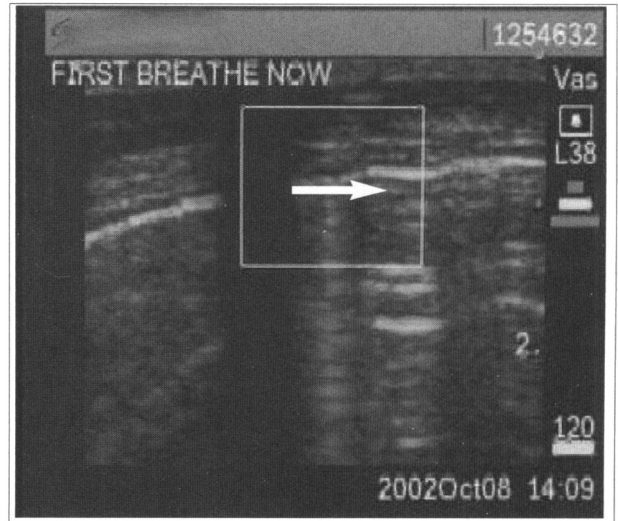
Prehospital and Disaster Medicine © 2004 Kirkpatrick

**Figure 2**—Color-power doppler (CPD). Cursor indicates location of doppler interrogation. The color-power doppler signal (in box) is the amplification of motion and is the doppler correlate of lung sliding (LS). The CPD and LS signs are seen at the VPPI only when the pleural surfaces are apposed and sliding against each other (as in a normal lung). The CPD is not seen when there is no motion, such as with a pneumothorax or during apnea. An image with excessive gain has been selected for illustration as a black and white image. Lung sliding or the pleural surfaces sliding against each other is better seen in real-time imaging and is illustrated on the Internet at <http://www.tac.medical.org/videlinks.htm>.

with a muscle relaxant and prior to bag-valve-mask ventilation, during endotracheal intubation, and prior to positive pressure ventilation via the ETT), thereby suggesting apposition, but lack of motion between the pleural surfaces. An example of the sonographic windows seen during apnea is in Figure 3. Post-intubation, there was a return of both the LS and CPD signals in all lung fields. This correlated with the concomitant conclusion by anesthesiology regarding proper intubation and adequate ventilation in all of the elective patients. In the two trauma patients, the CTA, but not the LS or CPD, was visualized in the left hemi-thorax, but all were visualized on the right. The LS and CPD signs returned to the left hemi-thorax after withdrawal of the ETT by a few centimeters, suggesting right main-stem intubation (RMI) had been the cause of the absent LS and CPD signs on the left hemi-thorax. This later was confirmed on chest radiography. There was no morbidity or mortality attributed to any patient due to the sonographic examination.

#### Discussion

There are several routine clinical measures to confirm proper ETT placement.<sup>13</sup> However, none of these clinical signs have proven to be fail-safe. Sixty percent of RMIs occur despite the presence of equal breath sounds on auscultation, and 70% occur despite observation of apparent symmetrical chest excursion.<sup>1</sup> The apparent auscultation of bilateral breath sounds also is not uncommon with cases in which an esophageal intubation later is recognized.<sup>14</sup>



Prehospital and Disaster Medicine © 2004 Kirkpatrick

**Figure 3**—Apnea. Doppler window shows the absence of the color-power doppler, but the presence of comet-tail artefact indicating that the pleural surfaces are in apposition but are not in motion (arrow). When seen in real-time imaging, lung sliding also is absent. These sonographic signs together correlated with apnea.

Other clinical signs, including epigastric auscultation, water condensation in the lumen of the ETT, and measured exhaled gas volumes can be falsely reassuring.<sup>14</sup>

As a result, several technical adjuncts have been described to aid in confirmation of correct ETT placement. These include chest radiography, fiberoptic bronchoscopy, pulse oximetry, esophageal detection devices, and capnography, with the latter being considered the gold standard. Although the absence of end-tidal CO<sub>2</sub> on capnography is an accurate, real-time indicator of ETT misplacement, it cannot exclude RMI, as exhaled CO<sub>2</sub> still will be detected from the right lung. Furthermore, in the cardiac arrest situation, the sensitivity of capnography for detecting inappropriate tube position is reduced. Low or absent expired CO<sub>2</sub> in this setting could indicate an esophageal intubation, but also could indicate inadequate circulation, prolonged arrest time, hypothermia, or significant ventilation/perfusion mismatch.<sup>15</sup>

In an operational military or emergency setting, portable US may have utility in ensuring proper ETT positioning. Not only can optimal patient position for intubation be less than ideal, the usual methods to confirm proper ETT placement often are not applicable or available. Noise levels in military and civilian transport helicopters, for example, routinely range from 90 to 111 decibels.<sup>16</sup> Evaluations of both amplified electronic and standard stethoscopes have concluded that breath sounds cannot be heard in flight.<sup>16</sup> Noise levels in many parts of the International Space Station (ISS) also are likely to preclude attempts at auscultation.<sup>8,12</sup> Moreover, other monitors, such as capnography, represent more equipment that must be carried or loaded on already space/weight-limited vehicles.



In this series, US findings correlated well with pulmonary ventilation. However, the *adequacy* of this ventilation was not addressed. Loss of LS and CPD, but not the CTA, were visualized in the left lung in the two trauma patients when the diagnosis of pneumothorax was ruled out and right mainstem intubation ruled in by chest radiography. This was confirmed further when the normal signs of LS and CPD from the left VPPI returned upon repositioning of the ETT. In the elective surgery patients, loss of the LS and CPD, but not the CTA signs, were coincident only with apneic episodes throughout the intubation sequence, confirming that the ultrasound image at the VPPI did appear to correlate with lung ventilation.

Sonography is a technology that is becoming increasingly available, and produces digital output that readily is stored and transmitted, and may be interpreted remotely. Astronauts have been tele-mentored successfully by ground experts to perform diagnostic ultrasound in low earth orbit. Terrestrially, portable ultrasound devices already have been investigated by air ambulance services for expediently detecting abdominal injuries at the scene of the traumatic

event or during air transport.<sup>17</sup> Medical care providers responding to catastrophic emergencies in hostile and/or remote environments someday may be equipped with portable ultrasound capability supported by remote telemedical support,<sup>18</sup> while lacking the ability to auscultate or utilize other non-invasive physiologic monitors, such as capnography.

### Conclusions

Further study is needed to properly evaluate the potential use of thoracic US via the PHHU in confirmation of ETT placement. If this preliminary work is confirmed in larger populations, use of the PHHU device may provide another diagnostic capability in operational environments.

### Endnote

A complete video sequence demonstrates the teaching points of this manuscript much more graphically than the still images. A complete video sequence of a normal intubation may be downloaded for viewing from the website at <http://www.tac.medical.org/videolinks.htm>.

## References

1. Brunel W, Coleman DL, Schwartz DE, et al: Assessment of routine chest roentgenograms and the physical examination to confirm endotracheal tube position. *Chest* 1989;96:1043-1045.
2. Katz SW, Falk JL: Misplaced endotracheal tubes by paramedics in an urban emergency medical services system. *Ann Emerg Med* 2001;37:32-37.
3. Jones JH, Murphy MP, Dickson RL SG, Brizendine EJ: Emergency physician-verified out-of-hospital intubation: Miss rates by paramedics. *Acad Emerg Med* 2004;11:707-709.
4. Dulchavsky SA, Henry SE, Moed BR, et al: Advanced ultrasonic diagnosis of extremity trauma: The FASTER exam. *J Trauma* 2002;53:28-32.
5. Kirkpatrick AW, Simons RK, Brown R, et al: The hand-held FAST: Experience with hand-held trauma sonography in a level-I urban trauma center. *Injury* 2002;33:303-308.
6. Kirkpatrick AW, Sirois M, Laupland KB, et al: Hand-held thoracic sonography for detecting post-traumatic pneumothoraces: The extended focussed assessment with sonography for trauma (EFAST). *J Trauma* (in press).
7. Cunningham J, Kirkpatrick AW, Nicolaou S, et al: Enhanced recognition of "lung sliding" with power color Doppler imaging in the diagnosis of pneumothorax. *J Trauma* 2002;52:769-771.
8. Dulchavsky SA, Hamilton DR, Diebel LN, et al: Thoracic ultrasound diagnosis of pneumothorax. *J Trauma* 1999;47:970-971.
9. Rowan KR, Kirkpatrick AW, Liu D, et al: Traumatic pneumothorax detection with thoracic US: Correlation with chest radiography and CT—Initial experience. *Radiology* 2002;22:210-214.
10. Liechtenstein D, Meier G, Bideman P, Genre A: The comet-tail artifact: An ultrasound sign ruling out pneumothorax. *Intensive Care Med* 1999; 25:383-388.
11. Lichtenstein DA, Menu Y: A bedside ultrasound sign ruling out pneumothorax in the critically ill: Lung sliding. *Chest* 1995;108:1345-1348.
12. Dulchavsky SA, Schwarz KW, Kirkpatrick AW, et al: Prospective evaluation of thoracic ultrasound in the detection of pneumothorax. *J Trauma* 2001; 22:210-214.
13. Zwillich CW, Pierson DJ, Creagh CE, et al: Complications of assisted ventilation. A prospective study of 354 consecutive episodes. *Am J Med* 1974;57:161-170.
14. Birmingham PK, Cheney FW, Ward RJ: Esophageal intubation: A review of detection techniques. *Anesth Analg* 1986;65:886-891.
15. Ornato JP, Shiple JB, Racht EM SC, et al: Multicenter study of a portable, hand-size, colorimetric end-tidal carbon dioxide detection device. *Ann Emerg Med* 1992;21:518-523.
16. Hunt RC, Bryan DM, Brinkley S, et al: Inability to assess breath sounds during air medical transport by helicopter. *JAMA* 1991;265:1982-1984.
17. Price DD, Wilson SR, Murphy TG: Trauma ultrasound feasibility during helicopter transport. *Air Med J* 2000;19:144-146.
18. Strode CA, Rubal BJ, Gerhardt RT, Bulgrin JR BS: Wireless and satellite transmission of prehospital focused abdominal sonography for trauma. *Prehosp Emerg Care* 2003;7:375-379.