

Altered cingulum bundle microstructure in autism spectrum disorder

Ameis SH, Fan J, Rockel C, Soorya L, Ting Wang A, Anagnostou E.
Altered cingulum bundle microstructure in autism spectrum disorder.

Objective: Here, we examined the cingulum bundle, a long-range white matter tract mediating dorsal limbic connectivity, using diffusion tensor imaging (DTI) tractography, in children and adolescents with autism spectrum disorder (ASD) versus controls. We hypothesised that cingulum bundle microstructure would be altered in ASD, based on evidence implicating abnormal white matter connectivity in this disorder.

Methods: DTI data were acquired for 19 ASD participants (IQ \geq 70; 7–18 years; mean = 12.4 \pm 3.1) and 16 age-matched controls (7–18 years; mean = 12.3 \pm 3.6) on a 3 T magnetic resonance imaging system. Deterministic tractography was used to isolate the cingulum bundle. Left and right cingulum bundles were examined for differences in several DTI metrics in ASD children/adolescents versus controls, including: fractional anisotropy (FA), mean, axial, and radial diffusivity.

Results: Significant age \times group interaction effects were found for all DTI metrics (mean diffusivity: $F_{1,28} = 9.5$, $p = 0.005$, radial diffusivity: $F_{1,28} = 7.8$, $p = 0.009$, axial diffusivity: $F_{1,28} = 5.2$, $p = 0.03$, FA: $F_{1,28} = 4.4$, $p = 0.04$). Interaction effects were driven by increases in cingulum bundle diffusivity (mean, radial, and axial diffusivity), and decreased FA, in younger ASD participants within our sample versus controls.

Conclusion: Our results point to immature microstructural organisation of the cingulum bundle in ASD, particularly during the early years of life, with implications for limbic network synchronisation and complex socio-emotional performance.

**Stephanie H. Ameis¹,
Jin Fan^{2,3}, Conrad Rockel¹,
Latha Soorya³,
A. Ting Wang³,
Evdokia Anagnostou^{3,4}**

¹Department of Psychiatry, The Hospital for Sick Children, University of Toronto, Toronto, ON, Canada; ²Department of Psychology, Queens College, The City University of New York, Flushing, NY, USA; ³Department of Psychiatry, Mount Sinai School of Medicine, New York, NY, USA; and ⁴Department of Pediatrics, Holland Bloorview Kids Rehabilitation Hospital, Bloorview Research Institute, University of Toronto, Toronto, ON, Canada

Keywords: autism spectrum disorder, diffusion tensor imaging, limbic system

Evdokia Anagnostou, Department of Pediatrics, Holland Bloorview Kids Rehabilitation Hospital, Bloorview Research Institute, University of Toronto, 150 Kilgour Road, Toronto, ON, Canada M4G 1R8.
Tel: +1 (416) 425-6220 ext. 6005;
Fax: +1 (416) 422-7036;
E-mail: eanagnostou@hollandbloorview.ca

Accepted for publication October 13, 2012

First published online 27 February, 2013

Significant outcomes

- Altered cingulum bundle microstructure was found in autism spectrum disorder (ASD) participants versus controls.
- Microstructural differences signalled atypical development of the cingulum bundle in ASD.
- Our work provides further evidence for impaired limbic system connectivity in developing individuals with ASD.

Limitations

- To further validate these results, studies using larger sample sizes will be needed.
- As ASD participants examined in this study were high functioning (IQ \geq 70), results may not generalise to lower functioning individuals on the autism spectrum.

Introduction

The ASD is a neurodevelopmental disorder characterised by impaired social interaction and communication, and inflexible behaviours (1).

Recently, evidence for altered *brain connectivity* in ASD has indicated that impaired integration of large-scale neural networks may play a central role in the aetiology of the disorder (2). In particular, the high-order socio-emotional functioning that is otherwise

impaired in ASD is reliant on integrated activity across a broad network of structures involved in socio-emotional processing. Socio-emotional processing structures include ventral (i.e., amygdala, orbito-frontal cortex) and dorsal (i.e., anterior/posterior cingulate cortex, precuneus) limbic structures within frontal and temporal lobes, which are linked by long-range white matter tracts facilitating broad network synchronisation (3). Post-mortem and magnetic resonance imaging (MRI) findings in ASD include: altered expression of genes involved in regulating synapse structure in frontal and temporal cortex (4), reduced functional connectivity between limbic regions during socio-emotional performance (5), abnormal frontal and temporal white matter growth (6), and altered axonal density within anterior cingulate white matter (7), which collectively implicate the presence of disrupted connectivity within the limbic network in the disorder. Further examination of the microstructural properties of impaired limbic connectivity in ASD is central to gaining insight into the biology of characteristic socio-emotional deficits in this disorder.

Diffusion tensor imaging (DTI) is a non-invasive MRI-based imaging modality that can track diffusion of water molecules in brain tissue (8). Given the highly restricted structure of white matter tracts, different DTI metrics [i.e., fractional anisotropy (FA), mean diffusivity, radial, and axial diffusivity] reflecting the extent of water molecule movement within three principal eigenvectors can provide detailed *in vivo* information regarding white matter microstructure, in a manner not possible with conventional MRI (9). In a recently published study, our research group added to a growing number of DTI publications in ASD (10). Using tract-based spatial statistics (TBSS), an optimised method for voxel-wise comparisons of DTI data, we showed increased mean and radial diffusivity across cortico-cortical and inter-hemispheric white matter voxels in children with ASD, compared with controls; a finding that was consistent with several voxel-wise comparison studies highlighting broad impairments of white matter integrity in the developing ASD brain (11–14). Our follow-up comparisons of white matter tracts featuring prominent voxel-based alterations on TBSS (i.e., corona radiata, inferior longitudinal fasciculus, uncinate fasciculus, inferior fronto-occipital fasciculus, corpus callosum, and superior longitudinal fasciculus) highlighted increased diffusivity in corona radiata, inferior longitudinal fasciculus, and the uncinate fasciculus in ASD (10), and provided added information regarding the potential for altered connectivity within neural networks linked by these tracts. As the uncinate fasciculus and inferior longitudinal fasciculus are long-range white matter tracts that integrate ventral

brain structures involved in emotion and face processing across a broad fronto-temporo-occipital circuit, microstructural abnormalities affecting these tracts point to secondary impairments in ventral limbic connectivity in ASD. These findings raise questions as to whether impaired limbic connectivity extends to the cingulum bundle, a long-range white matter tract integrating dorsal limbic structures in ASD, with implications for impaired synchronisation across an extended network of structures involved in socio-emotional processing.

Whereas the uncinate fasciculus primarily links ventral (fronto-temporal) limbic system structures, the cingulum bundle, representing a major means for intra-hemispheric long-range brain connectivity, mediates dorsal limbic system integration. The cingulum bundle provides a link between grey matter structures that are important for mentalisation, abstraction, and emotional reflection, domains of core deficiency in ASD (3). Therefore, investigating whether structural white matter alterations extend to the cingulum bundle in ASD, is of significant interest with respect to furthering our understanding of etiopathogenic factors contributing to ASD social impairments. Previously, diffusion tensor tractography, enabling isolation and characterisation of specific white matter tracts using DTI data (15), has shown reduced FA (signalling impaired white matter integrity) in the cingulum bundle in children with ASD (16). However, a DTI tractography study in adolescents, failed to find reduced FA within the cingulum bundle in ASD, compared with controls (17). Further, the only tractography study to examine radial and axial diffusivity values in addition to FA and mean diffusivity in cingulum bundle (DTI indices that can provide additional information regarding the primary orientation of water diffusion in white matter tissue and insight into cellular properties that may drive differences in structural white matter indices) did so in young children with ASD (~3 years of age) (18). In this tractography study of young children, increased as opposed to decreased FA was found in the cingulum bundle in ASD (18). Therefore, based on conflicting results from previous DTI tractography studies in ASD, questions remain regarding the presence and profile of microstructural white matter alterations affecting the cingulum bundle in children and adolescents with this disorder.

Aims of the present study

The aim of the present study was to use DTI tractography to examine FA, mean diffusivity, as well as radial and axial diffusivity values in the cingulum bundle in children and adolescents with

ASD, compared with controls, as a means to further characterise the nature of impaired limbic system connectivity in this population, and resolve some outstanding questions regarding microstructural alterations affecting the cingulum bundle in ASD.

Material and methods

Participants

Participants included children and adolescents with ASD and full scale $IQ \geq 70$ (estimated by the Wechsler Intelligence Scale for Children – 4th edn) (19), recruited through the Seaver Autism Center at the Mount Sinai School of Medicine (New York, NY, USA). Participants were excluded based on a history of: head injury, genetic disorder associated with autism (e.g., Fragile X syndrome), or co-morbid psychiatric or medical conditions. Diagnoses of autistic disorder and Asperger disorder were made according to DSM-IV-TR criteria (1), and supported by the Autism Diagnostic Observation Schedule (ADOS) (20) and Autism Diagnostic Interview-Revised (ADI-R) (21). Nineteen unmedicated children and adolescents with ASD (7–18 years of age; mean 12.4 ± 3.1 years; three females, 16 males; 14 Asperger disorder, five autistic disorder) made up our ASD group. Our control group consisted of 16 typically developing children and adolescents (7–18 years of age; mean 12.3 ± 3.6 years; eight females, eight males) recruited using advertisements in local media. Ethics approval was obtained from the Institutional Review Board of the Mount Sinai School of Medicine. Informed consent and child assent was obtained from all participants in accordance with the Helsinki agreement and institutional guidelines. The DTI data from the sample described above were previously analysed using a TBSS approach (10).

Diffusion tensor imaging acquisition

All DTI scans were acquired on a 3T Siemens Allegra head-dedicated MRI system (Siemens AG, Medical Solutions, Erlangen, Germany) using a pulsed-gradient spin-echo sequence with echo-planar imaging acquisition (repetition time = 4100 ms, echo time = 80 ms, field of view = 21 cm, matrix = 128×128 , 28 slices, thickness = 3 mm, skip = 1 mm, b factor = 1250 s/mm^2). One non-diffusion-weighted ($b = 0$) image, along with data for 12 gradient directions with five averages, was acquired.

Image analysis

Following Eddy current correction of raw diffusion-weighted images using FSL 4.1 (Functional Magnetic Resonance Imaging of the Brain Software Library;

www.fmrib.ox.ac.uk/fsl/) software (22,23), the diffusion tensor and three diagonal tensor elements (eigenvalues λ_1 , λ_2 , and λ_3) were calculated for each image voxel using Diffusion Toolkit software (<http://trackvis.org>) (24). Four DTI metrics were extracted for the left and right cingulum bundle in the present study: (i) FA; a tensor-derived metric representing the degree of directionality of water diffusion for a given image voxel on a scale from 0 (random diffusion) to 1 (diffusion in one direction), (ii) mean diffusivity; average diffusion across all eigenvectors of the diffusion tensor $[(\lambda_1 + \lambda_2 + \lambda_3)/3]$, (iii) axial diffusivity; a measure of diffusion within the principle eigenvector (eigenvalue = λ_1), thought to represent diffusion that is parallel to white matter axons, and (iv) radial diffusivity; an index of average diffusion across the two minor axes of the diffusion tensor $[(\lambda_2 + \lambda_3)/2]$, thought to reflect diffusion perpendicular to white matter axons (8,9,25). The Diffusion toolkit (Trackvis, <http://trackvis.org>) (24) was used for fibre tracking based on a standard Fiber Assignment by Continuous Tracking approach with step length 0.5 mm; FA threshold of 0.2, angle threshold of 45° (15); propagating streamlines from 'seed' regions of interest (ROI) and between adjacent voxels to reconstruct the three-dimensional trajectory of underlying white matter tracts. A single ROI was manually defined by the first author of this study (S.H.A.) for the cingulum bundle on each participant's FA map, in accordance with an established ROI template for diffusion tensor tractography of long-range white matter tracts (26). Following fibre tracking, FA, mean diffusivity, axial, and radial diffusivity values were sampled along the right and left cingulum bundle, and means computed.

Statistical analysis

Statistical comparisons of the data were carried out using SPSS software, version 20 (SPSS Inc., Chicago, Illinois, USA). First, to test for intra-rater reliability (and the level of variation present in diffusion measures derived from tract reconstructions in our sample), intra-class correlation coefficients were calculated for FA, and mean diffusivity values for diffusion tensor tractography reconstructions of left and right cingulum bundle on eight participant scans, which were randomly selected from our overall sample. Next, between-group differences in DTI metrics for the cingulum bundle were examined using a general linear model analysis for repeated measures with hemispheric DTI metric (i.e., left and right cingulum bundle FA) entered as within-subjects factors and group entered as between-subjects factor; age and gender were added as covariates. Main effects for group, age, and gender were examined as well as

interaction effects for these variables (group × age, group × gender, age × gender). This same statistical model was then repeated separately for all remaining DTI outcome measures (i.e., mean diffusivity, axial, and radial diffusivity). η^2 estimates of effect size were also examined. Where significant between-group effects were found, *post hoc* independent samples *t*-tests were performed and Bonferroni’s multiple comparison corrections applied to correct for comparisons of two white matter tracts (i.e., left and right cingulum bundle, $p \leq 0.025$).

Results

Demographics

No between-group differences for age or full scale IQ were found ($t_{1,33} = 0.03$, $p = 0.1$; $t_{1,29} = -3.4$, $p = 0.8$, respectively) (see Table 1). No difference in gender distribution was found between groups using the Fisher exact test (all $p > 0.05$).

Intra-rater reliability

High intra-class correlation coefficients were found on tests for intra-rater reliability of diffusion measures derived from tractography reconstructions. Intra-class correlation coefficients for left cingulum bundle were: 0.93 ($p < 0.001$) and 0.99 ($p < 0.001$) for FA and mean diffusivity values, respectively. In right cingulum bundle, intra-class correlation coefficients were: 0.93 ($p < 0.001$) and 0.96 ($p < 0.001$) for FA and mean diffusivity values, respectively.

Between-group differences for diffusion tensor imaging outcome measures

A significant group × age interaction effect was found for cingulum bundle: mean diffusivity ($F_{1,28} = 9.5$, $p = 0.005$, $\eta^2 = 0.25$), radial diffusivity ($F_{1,28} = 7.8$, $p = 0.009$, $\eta^2 = 0.22$), and axial diffusivity ($F_{1,28} = 5.2$, $p = 0.03$, $\eta^2 = 0.16$). A significant group × age interaction effect was also found for cingulum bundle FA ($F_{1,28} = 4.4$, $p = 0.04$, $\eta^2 = 0.14$). No significant findings were found for group × gender (FA: $F_{1,28} = 0.00$, $p = 0.99$, mean diffusivity:

$F_{1,28} = 0.21$, $p = 0.65$, radial diffusivity: $F_{1,28} = 0.06$, $p = 0.80$, axial diffusivity: $F_{1,28} = 0.6$, $p = 0.45$) or age × gender (FA: $F_{1,28} = 0.26$, $p = 0.62$, mean diffusivity: $F_{1,28} = 0.001$, $p = 0.98$, radial diffusivity: $F_{1,28} = 0.07$, $p = 0.80$, axial diffusivity: $F_{1,28} = 0.57$, $p = 0.46$) interaction terms for any of the DTI outcome measures examined in the present study. To further examine consistent group × age interaction effects found for all four DTI metrics, *post hoc t*-tests were performed after dividing our sample into ‘younger’ and ‘older’ sub-groups based on whether participants’ ages fell below or above the median group age for the overall sample (median age = 11 years; younger sub-group: age < 11, older sub-group: age > 11, see supplementary table 1). *Post hoc t*-tests revealed significant increases in diffusion values in the young ASD sub-group, compared with controls, for: bilateral cingulum bundle mean diffusivity (left: $t_{1,12} = 3.9$, $p = 0.002$, right: $t_{1,12} = 2.6$, $p = 0.024$), left cingulum axial diffusivity ($t_{1,12} = 3.8$, $p = 0.003$), and radial diffusivity for bilateral cingulum bundle (left: $t_{1,12} = 3$, $p = 0.011$, right: $t_{1,12} = 2.9$, $p = 0.014$). Decreased FA in right cingulum was also found ($t_{1,12} = -2.8$, $p = 0.016$). No between-group differences were found for the older sub-group (see Fig. 1).

To examine for associations between behaviour and DTI metrics derived for the cingulum bundle, we performed exploratory correlation analyses between our DTI metrics (i.e., FA, mean, axial, and radial diffusivity for right and left cingulum bundle) and total scores for the social interaction, communication, and stereotyped behaviours and restricted interests sections of the ADOS and ADI-R diagnostic algorithms. These analyses did not reveal significant correlations between DTI metrics for the cingulum bundle and ADOS/ADI-R behavioural scores in the present sample.

Discussion

In the present study we examined FA, mean diffusivity, radial, and axial diffusivity of the left and right cingulum bundle using diffusion tensor tractography in children and adolescents with ASD, compared with controls. Our aim was to further explore limbic connectivity in ASD, and expand

Table 1. Demographic characteristics

Group	N	Gender (M/F)	Age (years)	Statistic		FSIQ	Statistic	
				t	p		t	p
ASD	19	16/3	12.4 (3.1)	$t_{1,33} = 0.03$	0.97	98.5 (20.4)	$t_{1,29} = 3.4$	0.74
HC	16	8/8	12.3 (3.6)			100.7 (14.5)		

ASD, autism spectrum disorder; F, female; FSIQ, full scale IQ; HC, healthy controls; M, male. Data are expressed as mean (standard deviation).

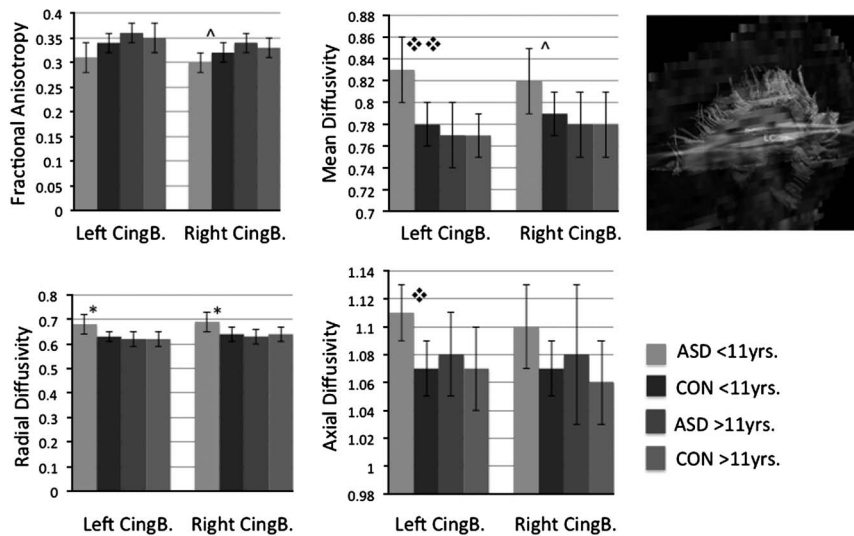


Fig. 1. Cingulum bundle microstructure in autism spectrum disorder versus healthy controls. Top left: tractography results for left and right cingulum bundle are displayed. Top right and bottom: bar graphs for fractional anisotropy, mean diffusivity, and radial diffusivity ($R \times D$) displayed for left and right cingulum bundle in young (<11 years) and older (>11 years) autism spectrum disorder (ASD) participants versus controls (CON). For mean diffusivity, radial diffusivity, and axial diffusivity, units = $\times 10^{-3}$ mm^2/s ; ^ p -value = 0.02; * p -value = 0.01; ** p -value = 0.002; * p -value = 0.003.

on our previous work highlighting prominent microstructural disorganisation within ventral limbic white matter connections in affected children (10). Here, we found significant age \times group interaction effects across DTI metrics for the cingulum bundle. These differences were driven by increases in cingulum bundle diffusivity (i.e., mean, radial, and axial diffusivity), and decreased FA, in young ASD participants within our sample, compared with controls. Our work provides further evidence for impaired limbic system connectivity in developing individuals with ASD.

Normative studies of white matter maturation demonstrate that typical white matter development is characterised by increasing FA, and decreasing mean diffusivity, radial diffusivity, and to a lesser extent axial diffusivity values, with increased age (9,27,28). These DTI measured changes are thought to reflect reduced water content, increased parallel organisation of axons, decreased extra-axonal space, and myelination, occurring over a protracted (i.e., decades long) period of typical white matter maturation (9). Mature white matter tracts are capable of rapid signal transmission between neurons, and facilitate tight control over the speed and timing of activation across neural networks; essential to complex mental performance (29,30). Increased mean diffusivity, radial and axial diffusivity, and decreased cingulum bundle FA, as found in children with ASD (rather than adolescents) compared with controls, may therefore be consistent with immature underlying white matter microstructure (27,28). As the cingulum bundle

integrates cortical structures such as anterior and posterior cingulate cortex, precuneus, and temporo-parietal junction, which together activate in response to tasks involving mentalisation, personal reflection, and emotional attribution (3), immature connectivity between these structures would likely translate into sub-optimal performance of complex socio-emotional tasks, as is found in individuals with ASD (31).

Consistent with our findings, previous voxel-wise DTI studies have most often found decreased FA, and increased diffusivity affecting widespread white matter in ASD, including cingulum bundle (10–12,14). Reduced FA has been observed on tract-specific examination of the cingulum bundle in children with ASD (16), and in regional evaluation of anterior cingulate white matter in affected adults (32). Conversely, in older adolescents and adults with ASD, no FA differences have been found for cingulum bundle using DTI tractography. However, macrostructural abnormalities of the cingulum bundle such as altered symmetry (17) and increased numbers of streamlines (33) have been found in ASD compared with controls, in older age groups. Interestingly, the only published tractography study of very young children with ASD compared with controls, found increased cingulum bundle FA in ASD (18). Inconsistencies in DTI findings for different age groups, as well as the age \times group interaction effects found in the present study, may signal abnormal development of the cingulum bundle in ASD beginning in early life. Ongoing structural white matter changes occurring with development into

childhood and adolescence may then contribute to an evolving picture of cingulum bundle pathology in ASD, depending on the age-range under examination.

It is of interest that in the present study, FA values were reduced in ASD in right but not left cingulum bundle. In DTI, FA describes the degree to which water diffusion occurs along one axis, and is restricted in all other directions (9). In left cingulum bundle, significant increases in axial diffusivity were seen alongside increases in radial diffusivity in ASD versus controls. Therefore, FA differences may not have differed between groups for left cingulum bundle, if axial diffusivity increases in ASD (i.e., increases in the principal axis of diffusion) exceeded radial diffusivity increases (i.e., diffusion in all other directions) for this tract. In contrast, radial diffusivity increased in right cingulum bundle in ASD versus controls, without significant change to axial diffusivity, thus causing overall reductions in anisotropic water restriction for the right cingulum bundle, and reduced FA. The cellular properties that may drive increases in axial and radial diffusivity are not well defined (25,34–36); therefore, biological interpretations must be made cautiously. However, we can speculate that increased axonal density within the cingulum bundle, could increase axial diffusivity (i.e., diffusion that is parallel to axon orientation), and reduced myelin thickness in white matter tracts could account for increased radial diffusivity (decreased water diffusion restriction perpendicular to axon orientation) (35). Interestingly, preliminary evidence for altered myelin thickness and axonal density has been found on post-mortem white matter examination in ASD (7).

Our work adds to a growing body of evidence supporting altered brain development, especially in white matter tracts and affecting fronto-limbic connectivity, in ASD (37). Longitudinal MRI studies indicate that altered grey and white matter development in early childhood ASD localises prominently to frontal and temporal cortical regions (6). Genetic risk loci for ASD often localise to genes involved in regulating synapse structure (38). A recent study indicating dramatic reductions in differential gene expression patterns within frontal and temporal cortex in post-mortem ASD was largely driven by prominent alterations in synaptic function genes, implicating impaired development of neuronal connectivity within these broad cortical regions (4). Within fronto-limbic regions specifically, pronounced increases in minicolumn (i.e., cortical processing unit) width and number in ASD are postulated to promote increased short-range connections at the expense of typical development of long-range white matter connectivity (39,40). Altered density among large and small diameter

axons within anterior cingulate white matter in ASD, and abnormal local growth protein expression found within this region, provides strong evidence that abnormal development of connectivity extends to the cingulum bundle (7). Taken together, the extant literature, including DTI findings pointing to immature limbic white matter connections, strongly implicates abnormal development of limbic white matter connectivity in ASD.

Limitations of the present study include a small sample size, and examination of children and adolescents with high functioning ASD; therefore, our results may not generalise across the autism spectrum. Further, although gender distribution did not differ significantly between our groups, upon visual inspection there were more males in our ASD versus control groups. Gender-based comparisons have found white matter differences between the sexes, including increased white matter integrity in males (the opposite profile to what was found here in ASD) that did not involve the cingulum bundle (41,42), mitigating the possibility that sex differences contributed to the present findings. Finally, correlational analyses between DTI metrics and symptom severity scales have been helpful in interpreting the clinical significance of structural DTI results in children with neurodevelopmental disorders (43). In the present study, we did not find correlations between white matter findings and behaviour scores derived from the ADOS and ADI-R. However, ADOS and ADI-R scores are not normalised to provide an index of symptom severity (44). In future, collection of a continuous measure assessing severity of social symptoms in ASD may prove useful for determining the clinical relevance of structural white matter findings within socio-emotional circuitry.

Our results indicate that white matter tract development within the limbic system in ASD is impaired, particularly during the early years of life. Impaired cingulum bundle microstructure may contribute significantly to the complex socio-emotional impairments that characterise the ASDs. Longitudinal studies tracking structural and functional development of the limbic system in ASD, compared with controls, are now needed to further understand network-based disruption within this circuitry, and the etiopathogenic factors contributing to characteristic social impairments in this disorder.

Acknowledgements

The research work presented here was carried out at: The Mount Sinai School of Medicine (Department of Psychiatry), The Hospital for Sick Children (Department of Psychiatry), and Holland Bloorview

Kids Rehabilitation Hospital. The authors would like to thank Ms. Nadia Tanel (Holland Bloorview Kids Rehabilitation Hospital) for assistance with data organisation. This work was supported by NARSAD (PI: Anagnostou), Autism Speaks (PI: Anagnostou), NIMH MH083164 (PI: Fan), and the Autism Research Training Program (salary support to S.H.A.), funded by the Canadian Institutes of Health Research (CIHR) Strategic Training Initiative in Health Research (STIHR), with supplemental funding from the Sinneave Family Foundation.

Declaration of conflicting interests: Evdokia Anagnostou has consulted with no fee to Neuropharm and Proximagen.

Authors' contributions: S.H.A. contributed to analysis, interpretation of data, drafting, and revision of the article. J.F., L.S., and A.T.W. contributed to conception, design of the study, and acquisition of the data. C.R. contributed to analysis and interpretation of the data. E.A. contributed to study conception, design, data acquisition, interpretation, and article revision.

References

1. AMERICAN PSYCHIATRIC ASSOCIATION. Diagnostic and statistical manual of mental disorders, 4th edn, text revision. Washington, DC: American Psychiatric Association, 2000.
2. BELMONTE MK, ALLEN G, BECKEL-MITCHENER A, BOULANGER LM, CARPER RA, WEBB SJ. Autism and abnormal development of brain connectivity. *J Neurosci* 2004;**24**:9228–9231.
3. CATANI M, THIEBAUT DE SCHOTTEN M. Limbic pathways. In: Atlas of human brain connections. New York: Oxford University Press, 2012;439–451.
4. VOINEAGU I, WANG X, JOHNSTON P et al. Transcriptomic analysis of autistic brain reveals convergent molecular pathology. *Nature* 2011;**474**:380–384.
5. WICKER B, FONLUPT P, HUBERT B, TARDIF C, GEPNER B, DERUELLE C. Abnormal cerebral effective connectivity during explicit emotional processing in adults with autism spectrum disorder. *Soc Cogn Affect Neurosci* 2008;**3**:135–143.
6. SCHUMANN CM, BLOSS CS, BARNES CC et al. Longitudinal magnetic resonance imaging study of cortical development through early childhood in autism. *J Neurosci* 2010;**30**:4419–4427.
7. ZIKOPOULOS B, BARBAS H. Changes in prefrontal axons may disrupt the network in autism. *J Neurosci* 2010;**30**:14595–14609.
8. CICCARELLI O, CATANI M, JOHANSEN-BERG H, CLARK C, THOMPSON A. Diffusion-based tractography in neurological disorders: concepts, applications, and future developments. *Lancet Neurol* 2008;**7**:715–727.
9. BEAULIEU C. The basis of anisotropic water diffusion in the nervous system – a technical review. *NMR Biomed* 2002;**15**:435–455.
10. AMEIS SH, FAN J, ROCKEL C et al. Impaired structural connectivity of socio-emotional circuits in autism spectrum disorders: a diffusion tensor imaging study. *PLoS One* 2011;**6**:e28044.
11. BARNEA-GORALY N, LOTSPEICH LJ, REISS AL. Similar white matter aberrations in children with autism and their unaffected siblings: a diffusion tensor imaging study using tract-based spatial statistics. *Arch Gen Psychiatry* 2010;**67**:1052–1060.
12. SHUKLA DK, KEEHN B, MULLER RA. Tract-specific analyses of diffusion tensor imaging show widespread white matter compromise in autism spectrum disorder. *J Child Psychol Psychiatry* 2011;**52**:286–295.
13. CHENG Y, CHOU KH, CHEN IY, FAN YT, DECETY J, LIN CP. Atypical development of white matter microstructure in adolescents with autism spectrum disorders. *Neuroimage* 2010;**50**:873–882.
14. SAHYOUN CP, BELLIVEAU JW, MODY M. White matter integrity and pictorial reasoning in high-functioning children with autism. *Brain Cogn* 2010;**73**:180–188.
15. MORI S, CRAIN BJ, CHACKO VP, VAN ZIJL PC. Three-dimensional tracking of axonal projections in the brain by magnetic resonance imaging. *Ann Neurol* 1999;**45**:265–269.
16. KUMAR A, SUNDARAM SK, SIVASWAMY L et al. Alterations in frontal lobe tracts and corpus callosum in young children with autism spectrum disorder. *Cereb Cortex* 2010;**20**:2103–2113.
17. LO YC, SOONG WT, GAU SS et al. The loss of asymmetry and reduced interhemispheric connectivity in adolescents with autism: a study using diffusion spectrum imaging tractography. *Psychiatry Res* 2011;**192**:60–66.
18. WEINSTEIN M, BEN-SIRA L, LEVY Y et al. Abnormal white matter integrity in young children with autism. *Hum Brain Mapp* 2011;**32**:534–543.
19. WECHSLER D. The Wechsler Intelligence Scale for Children, 4th edn. London: Pearson Assessment, 2004.
20. LORD C, RISI S, LAMBRECHT L et al. The Autism Diagnostic Observation Schedule-Generic: a standard measure of social and communication deficits associated with the spectrum of autism. *J Autism Dev Disord* 2000;**30**:205–223.
21. LORD C, RUTTER M, LE COUTEUR A. Autism Diagnostic Interview-Revised: a revised version of a diagnostic interview for caregivers of individuals with possible pervasive developmental disorders. *J Autism Dev Disord* 1994;**24**:659–685.
22. SMITH SM, JENKINSON M, WOOLRICH MW et al. Advances in functional and structural MR image analysis and implementation as FSL. *Neuroimage* 2004;**23**(Suppl. 1):S208–S219.
23. JENKINSON M, BANNISTER P, BRADY M, SMITH S. Improved optimization for the robust and accurate linear registration and motion correction of brain images. *Neuroimage* 2002;**17**:825–841.
24. WANG RBT, SORENSEN AG, WEDEEN VJ. Diffusion toolkit: a software package for Ddfusion imaging data processing and tractography. *Proc Intl Soc Mag Reson Med* 2007:3720.
25. WHEELER-KINGSHOTT CA, CERCIGNANI M. About ‘axial’ and ‘radial’ diffusivities. *Magn Reson Med* 2009;**61**:1255–1260.
26. CATANI M, THIEBAUT DE SCHOTTEN M. A diffusion tensor imaging tractography atlas for virtual in vivo dissections. *Cortex* 2008;**44**:1105–1132.
27. FARIA AV, ZHANG J, OISHI K et al. Atlas-based analysis of neurodevelopment from infancy to adulthood using diffusion tensor imaging and applications for automated abnormality detection. *Neuroimage* 2010;**52**:415–428.
28. HUPPI PS, DUBOIS J. Diffusion tensor imaging of brain development. *Semin Fetal Neonatal Med* 2006;**11**:489–497.
29. FIELDS RD. White matter in learning, cognition and psychiatric disorders. *Trends Neurosci* 2008;**31**:361–370.
30. FIELDS RD. White matter matters. *Sci Am* 2008;**298**:42–49.
31. STARR E, SZATMARI P, BRYSON S, ZWAIGENBAUM L. Stability and change among high-functioning children with pervasive

- developmental disorders: a 2-year outcome study. *J Autism Dev Disord* 2003;**33**:15–22.
32. THAKKAR KN, POLLI FE, JOSEPH RM et al. Response monitoring, repetitive behaviour and anterior cingulate abnormalities in autism spectrum disorders (ASD). *Brain* 2008;**131**(Pt 9):2464–2478.
 33. PUGLIESE L, CATANI M, AMEIS S et al. The anatomy of extended limbic pathways in Asperger syndrome: a preliminary diffusion tensor imaging tractography study. *Neuroimage* 2009;**47**:427–434.
 34. GAO W, LIN W, CHEN Y et al. Temporal and spatial development of axonal maturation and myelination of white matter in the developing brain. *AJNR Am J Neuroradiol* 2009;**30**:290–296.
 35. KLAWITER EC, SCHMIDT RE, TRINKAUS K et al. Radial diffusivity predicts demyelination in ex-vivo multiple sclerosis spinal cords. *Neuroimage* 2011;**55**:1454–1460.
 36. SONG SK, SUN SW, RAMSBOTTOM MJ, CHANG C, RUSSELL J, CROSS AH. Demyelination revealed through MRI as increased radial (but unchanged axial) diffusion of water. *Neuroimage* 2002;**17**:1429–1436.
 37. WOLFF JJ, GU H, GERIG G et al. Differences in white matter fiber tract development present from 6 to 24 months in infants with autism. *Am J Psychiatry* 2012;**169**:589–600.
 38. MARSHALL CR, SCHERER SW. Detection and characterization of copy number variation in autism spectrum disorder. *Methods Mol Biol* 2012;**838**:115–135.
 39. CASANOVA MF. White matter volume increase and minicolumns in autism. *Ann Neurol* 2004;**56**:453.
 40. CASANOVA MF, BUXHOEVEDEN DP, SWITALA AE, ROY E. Minicolumnar pathology in autism. *Neurology* 2002;**58**:428–432.
 41. BAVA S, BOUCQUEY V, GOLDENBERG D et al. Sex differences in adolescent white matter architecture. *Brain Res* 2011;**1375**:41–48.
 42. MENZLER K, BELKE M, WEHRMANN E et al. Men and women are different: diffusion tensor imaging reveals sexual dimorphism in the microstructure of the thalamus, corpus callosum and cingulum. *Neuroimage* 2011;**54**:2557–2562.
 43. ZWICKER JG, MISSIUNA C, HARRIS SR, BOYD LA. Developmental coordination disorder: a pilot diffusion tensor imaging study. *Pediatr Neurol* 2012;**46**:162–167.
 44. GOTHAM K, PICKLES A, LORD C. Standardizing ADOS scores for a measure of severity in autism spectrum disorders. *J Autism Dev Disord* 2009;**39**:693–705.