



Incidental finding of atrial myxoma following curative treatment for paediatric neuroblastoma

Brief Report

Cite this article: Legro T, Mehta B, and Patel P (2024) Incidental finding of atrial myxoma following curative treatment for paediatric neuroblastoma. *Cardiology in the Young* **34**: 192–193. doi: [10.1017/S1047951123003670](https://doi.org/10.1017/S1047951123003670)

Received: 22 January 2023

Accepted: 22 August 2023

First published online: 3 November 2023

Keywords:

Neuroblastoma; chemotherapy; atrial myxoma; surveillance CT scan

Corresponding author:

P. Patel; Email: pritim@uic.edu

Tyler Legro¹, Brinda Mehta²  and Priti Patel³

¹Division of Pediatric Cardiology, University of Wisconsin School of Medicine and Public Health, Madison, Wisconsin, USA; ²Division of Pediatric Hematology Oncology, UICOMP, Peoria, IL, USA and ³Division of Pediatric Cardiology, UICOMP, Peoria, IL, USA

Abstract

Cardiac tumours are uncommon in the general population and even more so in the paediatric population. Here we present a case of an asymptomatic 7-year-old male with history of high-risk neuroblastoma who underwent 1-year post-treatment surveillance scan with an incidental finding of intracardiac lesion found to be an atrial myxoma.

Myxomas are benign tumours derived from mesenchymal origin and account for about half of the benign cardiac tumours.¹ In the paediatric population, rhabdomyomas, teratomas, fibromas, and haemangiomas of the heart all are more common than myxomas, which account for only 2–4% of cardiac tumours.² Cardiac myxomas are known to cause neurological symptoms due to thromboembolic events and/or metastases to the brain.³ Surgical resection is the treatment of choice.¹ Here we present a case of a 7-year-old male with history of high-risk neuroblastoma incidentally found to have cardiac myxoma at 1-year surveillance scan.

Case report

This is a 7-year-old male with history of stage IV high-risk neuroblastoma of the left adrenal gland, N-Myc non-amplified. He received intense therapy for neuroblastoma, which included chemotherapy (cyclophosphamide, topotecan, vincristine, doxorubicin, etoposide), I-131-Metaiodobenzylguanidine therapy, tandem autologous stem cell transplants, left adrenalectomy, proton beam therapy, immunotherapy with Anti-GD2 antibody (Dinutuximab), and Isotretinoin. During treatment, he also received Granulocyte-Macrophage Colony Stimulating Factor as well as Dexrazoxane.

A patent foramen ovale was noted on routine screening echocardiogram performed to assess cardiotoxicity from anthracycline therapy.

Physical exam was overall unremarkable except for pectus excavatum. His exam revealed proper growth with positive trend in his weight and height curves. Cardiac exam was unremarkable. On his routine one-year off-therapy CT scan of the chest and abdomen, he was found to have a 9 × 6 mm filling defect in the right atrium adjacent to the atrial septum. Subsequent transthoracic echocardiography was unable to visualise the mass. Transesophageal echocardiography revealed 8 × 6 mm echo-dense mass in the atrial septum, near the patent foramen ovale on the right side (Fig. 1). This study documented a finding most likely consistent with thrombus. He was started on therapeutic enoxaparin 1mg/kg twice daily dosing and thrombophilia workup was performed. Only lupus anticoagulant returned positive. EKG was normal. A three-month follow-up transthoracic echocardiogram was obtained, which revealed progression of the mass, now measuring 1.4 cm x 1.7 cm. This study revealed the lesion was more echobright than before, so there was uncertainty as to whether the lesion was truly larger or simply seen better with the increased echobrightness. Cardiac MRI showed a 16.3 × 11.3 mm pedunculated mobile mass attached to the right side of the atrial septum (Fig. 2). It had low signal on T1-weighted imaging and relatively high signal on T2-weighted imaging. There was a cleft of enhancement on first pass perfusion. Late gadolinium-enhanced sequences prescribed 10 minutes following administration of contrast demonstrate a cleft of central enhancement. The central enhancement made atrial thrombus less likely, as did progression of the lesion despite anticoagulation. An Metaiodobenzylguanidine diagnostic scan obtained also did not show abnormal uptake in the heart making it unlikely that the lesion was from neuroblastoma metastases. Tumour markers were within normal limits.

The patient underwent total atrial septectomy and atrial septal patch closure. Transesophageal echocardiography in the operating room showed the mass to be pedunculated and attached to the atrial septum on the right side of the septum. Flow cytometry was negative for malignancy. Pathology revealed 2 cm atrial myxoma. He was admitted to the cardiac ICU for

© The Author(s), 2023. Published by Cambridge University Press. This is an Open Access article, distributed under the terms of the Creative Commons Attribution licence (<http://creativecommons.org/licenses/by/4.0/>), which permits unrestricted re-use, distribution and reproduction, provided the original article is properly cited.

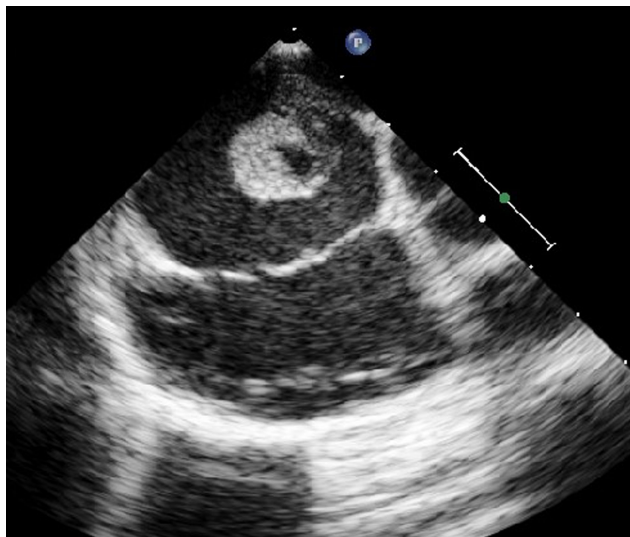


Figure 1. Transesophageal echocardiography showing an echo-dense pedunculated mass attached to the atrial septum.

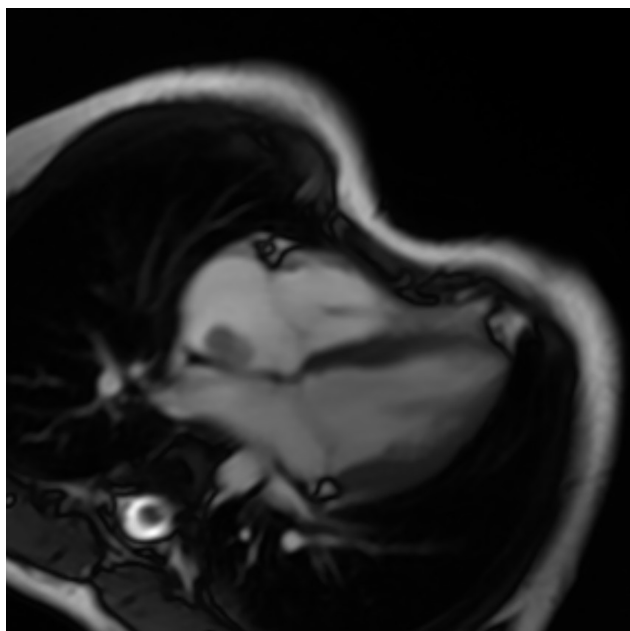


Figure 2. Cardiac MRI showed a 16 × 11 mm pedunculated mobile mass attached to the right side of the atrial septum.

monitoring and discharged home on post-operative day 2. He was prescribed 2 weeks of prophylactic dose enoxaparin at discharge given the association between thrombosis and myxoma.

Follow-up surface echocardiogram 2 weeks after discharge was without evidence of atrial mass or residual shunting lesion.

Discussion

Primary cardiac tumours in and of themselves are exceedingly rare with autopsy frequency reportedly ranging from 0.001 to 0.03%.¹ In the paediatric population, myxomas account for only 2–4% of cardiac tumours.² There is also a tendency for the cardiac myxoma to be most located in the left atrium in up to 75% of cases, close to

18% of cases in the right atrium, and 7% within the ventricles.¹ Familial cases are less common, occurring in up to 10% of cases (Carney syndrome).¹ Myxomas are usually pedunculated and attached to the atrial septum. Symptoms could be due to atrioventricular valve obstruction or embolic events. Myxomas typically are visualised by surface echocardiography, however further imaging with CT chest and cardiac MRI can be utilised to locate the lesion with more specific characteristics if needed. Surgical resection is curative and the treatment of choice. Sudden death in untreated patients can occur in up to 15% of the patients due to embolisation or atrioventricular valve obstruction. It is important to know that recurrence is relatively common, reported in 5% of sporadic cases and in up to 20% of familial cases in the first six years following surgical resection.¹ Some report at least annual surveillance surface echocardiogram and others every 6 months to monitor recurrence.⁴

Exposure to chemotherapy and radiation increases risk for second malignant neoplasms in childhood cancer survivors.⁵ Hence, the finding of a lesion in the heart raises concern for secondary neoplasm or metastases necessitating detailed oncology and cardiac workup as described in our young patient. Hill et al reported an incidental case of cardiac myxoma in a child with neuroblastoma as well but after 5.5 years of being off therapy who also survived after complete resection of the tumour.⁶

Due to the possibility of cardiac myxoma embolism and the risk of sudden death, surgery should be performed as soon as possible once cardiac myxoma is diagnosed to remove as much of the tissue surrounding the tumour as possible and reduce the recurrence rate.⁷

In conclusion, our case describes incidental finding of cardiac lesion in a child with neuroblastoma that mimicked a cardiac thrombus at initial finding. Subsequent follow-up revealed enlarged lesion raising concern for cardiac tumour triggering detailed cardiac and oncology workup. Multidisciplinary involvement and vigilance are crucial for management of rare cases such as our patients.

Acknowledgements. We would like to thank the patient and family for allowing us to publish his case.

Financial support. This research received no specific grant from any funding agency, commercial, or not-for-profit sectors.

Competing interests. None.

Ethical standards. None.

References

1. Yesodharan G. Atrial Myxoma. *Ferri's Clinical Advisor* 2022. Elsevier In, 2022, 218.e2–218.e4.
2. McAllister HA Jr. Primary tumors of the heart and pericardium. *Pathol Annu* 1979; 14: 325–355.
3. Lee VH, Connolly HM, Brown RD Jr. Central nervous system manifestations of cardiac myxoma. *Arch Neurol* 2007; 64: 1115–1120.
4. Grant Christa N, Rhee Daniel, Tracy Elisabeth T, et al. Pediatric solid tumors and associated cancer predisposition syndromes: workup, management, and surveillance. A summary from the APSA cancer committee. *J Pediatric Surg* 2021; 57: 430–442. DOI: [10.1016/j.jpedsurg.2021.08.008](https://doi.org/10.1016/j.jpedsurg.2021.08.008).
5. Cohen RJ, Curtis RE, Inskip PD, Fraumeni JF. The risk of developing second cancers among survivors of childhood soft tissue sarcoma. *Ann Ny Acad Sci* 2005; 103: 2391–2396.
6. Hill Garick, Castellino Sharon, Williams Derek. Cardiac myxoma after treatment for childhood neuroblastoma. *Pediatr Cardiol* 2009; 30: 340–342.
7. Tao TY, Yahyavi-Firouz-Abadi N, Singh GK, Bhalla S. Pediatric cardiac tumors: clinical and imaging features. *Radiographics* 2014; 34: 1031–1046.