



Acta Genet Med Gemellol 33:75-80 (1984)  
© 1984 by The Mendel Institute, Rome

TWIN RESEARCH 4 — Part A: Biology and Obstetrics  
Proceedings of the Fourth International Congress on Twin Studies (London 1983)

## Case Reports of 16 Sets of Conjoined Twins from a Uganda Hospital

**E.Z.N. Zake**

*Obstetrical/Gynecological Unit, Upcountry General Hospital, Mbale, Uganda*

---

**Abstract.** During a 10-year period (1971-1980) 16 sets of conjoined twins were delivered in the author's hospital. The incidence of those twins was 1 in 4242 deliveries, 1 in 69 multiple births, and 1 in 139 congenitally malformed babies. All diagnoses were made during labour or at operation and all babies were lost. There were no maternal deaths.

**Key words:** Congenital malformations, Conjoined twins

---

### INTRODUCTION

Conjoined twins result from a imperfect division of the embryo after the formation of two embryonic discs. Subsequent fetal wastage from congenital malformations as illustrated by this study of 16 sets of conjoined twins, cannot be clearly separated from fetal wastage due to other congenital malformations in singletons [3].

This is a retrospective study conducted in Mbale Government Hospital in Eastern Uganda, about 300 km from Kampala City [7]. It is a 400 bedded hospital, with 80 gynecological and obstetrical beds. The records were retrieved and analysed. The 16 sets of conjoined twins were all diagnosed and photographed during labour or at operation. Five sets are fully reported and the rest are summarized in the Table.

### CASE REPORTS

#### Case 1

Mother aged 34, para 6 + 1 (including a set of twins). The 7th pregnancy ended into a spontaneous abortion at 8 weeks gestation. She was unbooked and was admitted in an advanced obstructed labour. She was exhausted, dehydrated and moderately anemic (Hb 9.2/dl) with a blood pressure (BP) of 110/70. Other systems were normal. The fundal height corresponded to 36 weeks. The lower uterine segment was ballooned and

tender. The fetal heart sounds were absent. A breech, born to the level of its groins, was visible at the vulva. Its penis was bifid. A diagnosis of locked twins was made and the mother was prepared for an abdominal delivery.

The partially delivered breech was thoroughly cleaned with an antiseptic solution and wrapped in sterile linen. The thinned edematous lower uterine segment was opened transversely. This revealed conjoined twins. They were delivered by applying traction to the anterior head. The rest of the operation was accomplished without complication. The mother lost 300-400 ml of blood and was transfused with 1500 ml of whole blood. The twins were stillborn dicephalous males weighing 5.6 kg (Fig. 1). They shared limbs, umbilical cord, and scrotum. Permission for postmortem examination was refused. However, radiography of the babies, taken after an injection of urograffin (60%), showed that the babies shared the main circulation.

The mother made uneventful recovery and was discharged from hospital after 12 days. Sixteen months later, she gave birth to a set of dizygotic twins, one of whom was a stillborn female with arthrogyposis (Fig. 2).

## Case 2

Mother aged 19, para 1+0. The first pregnancy ended in spontaneous vaginal delivery of a set of twins. The first twin was a macerated female stillborn weighing 3.3 kg, while the 2nd was an acardius (Fig. 3). The mother's second pregnancy was by a different husband. She booked early and her pregnancy progressed normally until the 31st week, when she developed ankle edema. Her BP was normal and urine examination was negative. The presence of twins was confirmed by X-ray. Both were in cephalic presentation. She declined an admission offer. She was strongly advised to report to the antenatal clinic at weekly intervals. She defaulted and was next seen in an advanced premature labour at 35 weeks. She had developed hydramnios, but she was in good general condition with a BP of 120/60. The cervix was 8 cm dilated. The membranes were ruptured during that examination and plenty of clear liquor drained away. The presentation of the leading twin was vertex. The patient reached a second stage of labour after 50 min and was prepared for a vaginal delivery. The head descended to the level of the introitus and its further advance became arrested.

A repeat vaginal examination revealed a thick band of tissue connecting the twins. The head of the second twin was felt in the right iliac fossa. A diagnosis of conjoined twins was made and arrangements were made for delivery in the operating theatre. With the patient in a lithotomy position, the connecting band was exposed by retracting the vaginal wall with a vaginal retractor, and, under direct vision, the band was divided with a pair of scissors. The leading head was pulled down manually while an assistant pushed the abdominal head into the pelvis. The twins were then delivered easily. These were stillborn females weighing 4.6 kg. They were joined in the epigastric region. A digital exploration through the cut showed that the twins shared the liver, stomach and the spleen. There were 2 upper limbs and a single umbilical cord. The mother left hospital 36 hours later.

## Case 3

Mother aged 29, para 4+0, admitted at 30 weeks because of acute polyhydramnios. She was dyspneic and in severe pain, BP 105/65. The uterus was very tense and tender. The fundal height had reached a 36 weeks mark. Under aseptic procedure, amniocentesis was

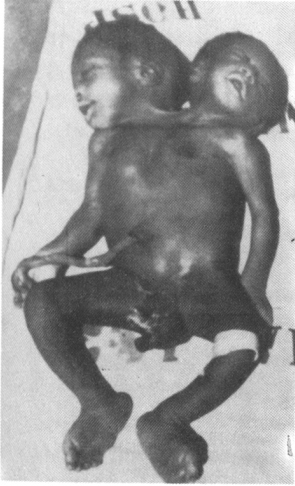


Fig. 1

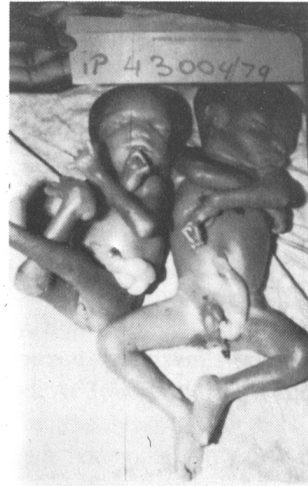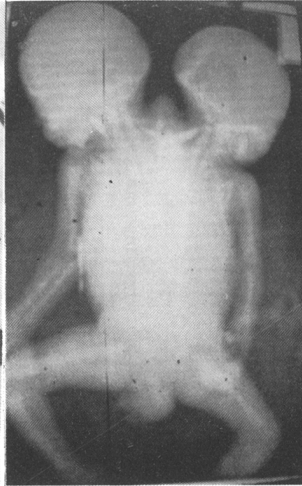


Fig. 2

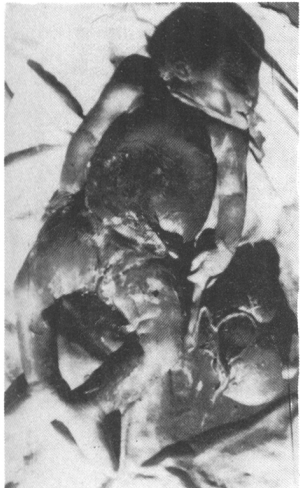


Fig. 3

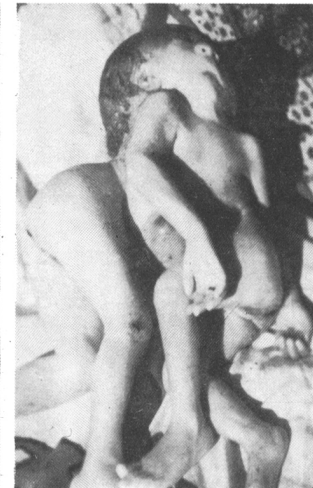

Fig. 4

Fig. 1 - Case no. 1: A dicephalus with shared heart.

Fig. 2 - Dead twins born to the same mother of case no. 1. (Twin with arthrogyposis on the left).

Fig. 3 - Case no. 2: Macerated stillborn female twin and acardius (bottom right).

Fig. 4 - Case no. 3 - A thoracopagus, with single face, 6 limbs, and 2 sets of genital organs.

Fig. 5 - Case no. 4: A thoracopagus, with hyperextended necks. The arrow shows a small tube used for introducing radiopaque material.

Fig. 6 - Case no. 5: A thoracopagus.

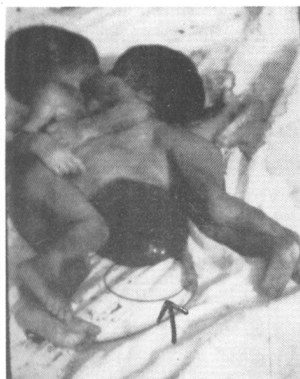

Fig. 5

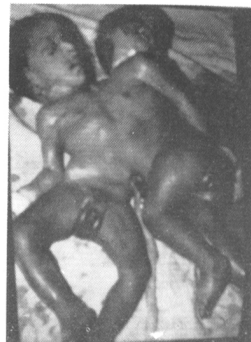
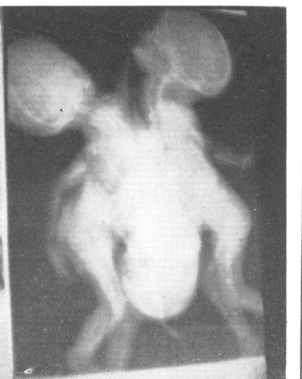

Fig. 6

TABLE - Case Reports of Conjoined Twins

Case no.	Maternal Age	Parity	Past obstetrical history	Present pregnancy history	Mode of delivery	Conjoined twins
6	22	1+0			SVD	Stillborn craniopagous males weighing 3.1 kg
7	25	4+0		Hydramnios	LSCS	Alive thoracopagous females weighing 7.34 kg; died 1 hr later
8	41	8+6	A set of normal female twins, pregnancies nos. 9-14 ended in spontaneous abortion at 8-18 weeks; two were twin pregnancies	Antepartum hemorrhage at 32 weeks, obstruction of labour	LSCS	Stillborn thoracopagous females weighing 6.1 kg
9	23	2+0		Hydramnios at 33 weeks, persistent transverse lie	CCS	Alive males joined by abdominal and pelvic regions, 4 upper and lower limbs and 1 cord. Died a few minutes later They weighed 6.6 kg
10	23	2+0	A macerated stillborn	Spontaneous abortion at 26 weeks	Abortion	Stillborn pygopagous males weighing 1.8 kg
11	34	6+1	An abortion at 10 weeks	Hydramnios, mild pre-eclamptic toxemia, transverse lie, arm prolapse	LVCS	Alive thoracopagous females weighing 1.8 kg
12	39	9+0	2 sets of twins (one DZ, one MZ)	Obstruction of labour	LSCS	Fresh stillborn thoracopagous males weighing 4.93 kg, 8 limbs 2 cords and bifid penis
13	17	0+0			SVD	Alive craniopagous females weighing 3.3 kg. Died 30 min later
14	33	4+2	2 spontaneous abortions at 8 and 12 weeks	Hydramnios at 28 weeks, Failure of labour to advance	LSCS	Fresh stillborn thoracopagous females weighing 6.13 kg.
15	38	8+1	2 sets of normal twins and a spontaneous abortion at 24 weeks	Obstruction of labour	LSCS	Fresh stillborn pygopagous males weighing 7.82 kg
16	32	6+0		Spontaneous abortion at 24 weeks	Abortion	Stillborn dicephalous females weighing 1.4 kg

performed and 1500 ml of clear liquor were removed. Four hours later the mother started labouring. The labour lasted 9 hr 40 min and ended in an uncomplicated spontaneous vaginal delivery of a pair of conjoined twins. These were alive cephalothoracopagous syncephalous females weighing 4.2 kg, who died after a few minutes (Fig. 4). There was a single face, 2 ears, 3 upper limbs, 4 lower limbs and a single umbilical cord.

#### Case 4

Mother aged 31, para 5+0. She booked early and her pregnancy progressed normally until the 28th week, when she developed a mild preeclamptic toxemia (BP 130/90, a trace of albumin in urine, and slight ankle edema). There was a moderate hydramnios. The presence of twin pregnancy was confirmed by X-ray. Both twins lay transversely and were facing one another. She was admitted into hospital and the toxemia responded to the bed rest. However, the hydramnios steadily worsened. At 36 weeks, the mother went into spontaneous labour. The twins were presenting by the heads. After 8 hours of labour, the mother reached a second stage, but both heads remained high and it was decided to terminate the labour by cesarean section. At operation, conjoined twins were found. They were stillborn thoracopagous females weighing 5.9 kg (Fig. 5). They had a shared umbilical cord. The mother made a successful progress and left hospital 10 days after.

#### Case 5

Mother aged 27, para 4+0, admitted as an emergency because of obstructed labour due to conjoined twins. The twins had been born to the level of their abdomen. Her uterus had already ruptured. She was anemic, with a BP of 90/50. After resuscitation, she was taken to theatre for laparotomy. The partially delivered breeches were treated as described in Case 2. An anterior complete tear was found in the lower uterine segment. The twins were delivered through the tear, followed by a subtotal hysterectomy. The twins were stillborn thoracopagous females weighing 5.42 kg (Fig. 6). The mother recovered completely and was discharged from hospital 12 days after.

Cases 6-16 are summarised in the Table.

## DISCUSSION

The incidence of conjoined twins of 1 in 4242 deliveries, 1 in 69 multiple births, and 1 in 139 congenitally malformed babies, as reported in this study, is very high, conjoined twins being considered much rarer [2, 4]. There were 6 male and 10 female sets, the maternal age ranged from 16 to 41 years, with an average of 29, and the parity was between 0 and 10, with a mean of 4.4. The main presenting features were polyhydramnios (7 cases) and obstructed labour (6 cases). Nine sets were delivered by cesarean operation and six sets terminated vaginally. Two of these were miscarriages at 24 and 26 gestational weeks. One laparotomy was performed for a rupture of uterus.

All the conjoined twins were lost. There were 6 thoracopagus sets, 5 pygopagus, 1 craniopagus, 1 dicephalus, 1 cephalothoracopagus syncephalus, and 2 unclassified. All the mothers survived. One mother had previously given birth to an acardius (Fig. 3) while another subsequently gave birth to a 3rd set of twins one of whom was grossly malformed (Fig. 2). Relatives and associates to six of the mothers who had given birth to

conjoined twins, gave birth to congenitally malformed singletons, eg, cyclop, limb anomalies, ears in the neck, sacral tumour, and facial tumour.

The causes of conjoined twins may be the same or different from the causes of congenital malformations in singletons. They also result from faulty organogenesis at a vulnerable stage of development [1,5], usually on the first trimester [6]. The factors which contribute to both conjoined twinning and other congenital malformations include genetic as well as environmental, teratogenic factors, and maternal age, parity, nutritional status, and disease, may also play a role.

Fetal wastage of hundred percent is reported. Since the successful separation of conjoined twins by Ian Aird [2], many attempts have been made to improve fetal survival. Not much success has been achieved since the outcome depends on a multitude of factors such as prenatal diagnosis, planned delivery, the ability of the operator, and especially on what organs are shared by the conjoined twins. In unexperienced hands, destructive deliveries are better avoided, since they are difficult and dangerous [4]. As for prenatal diagnosis, this is certainly feasible in developed countries, but not so in developing areas.

A delivery of conjoined twins is a shocking experience to the couple and generates a sense of guilt. The couple requires careful counselling. Besides chromosomal or genetic anomalies, consanguinity, history of illness during gestation, attention should also be paid to history of local herbs or other medicaments taken by the mother around the gestational period, and presence of alkaloids or vasoactive amines in the spoiled root or grain (C.L. Berry, personal communication).

**Acknowledgements:** I am grateful to the Commonwealth Foundation and to the Director of Medical Services, Uganda Government for support, as well as to Professor C.L. Berry (London), who kindly classified some of the fetal abnormalities; Professor I. MacGillivray (Aberdeen), for encouragement and constructive suggestions; Professor J.W. Mugerwa (Makerere), Mr. A. Upoki (Mbale Hospital), and Mr. J. Tomusange (St. Stephen's Hospital), for reading through the manuscript; the Medical and Nursing staff of the Obstetrical and Gynecological Unit, Mbale Hospital, for their cooperation; and Miss Sussie Cherotich for her secretarial services.

## REFERENCES

1. Beelay L. (1981): Adverse effects of drugs in the first trimester of pregnancy. *Clin Obstet Gynecol* 8: 261-272.
2. Doy JR, Svensen TG (1978): Conjoined twins. *Aust NZJ Obstet Gynaecol* 18: 215-217.
3. Greenhill JP, Friedman EA (1974): *Biological Principles and Modern Practice of Obstetrics*, 1st Ed. Philadelphia, London, Toronto: WB Saunders Co, p 715-729.
4. MacGillivray I, Nylander PPS, Corney G (1975): *Human Multiple Reproduction*, 1st Ed. London, Philadelphia, Toronto: WB Saunders Co, p 169-172.
5. Ver Blerk, Majerus TC, Myers RAM (1980): Teratogenic potential of some psycho-pharmacological drugs: A brief review. *Int J Gynaecol Obstet* 17: 399-402.
6. Willison JR (1961): *The Management of Obstetrical Difficulties*, 6th Ed. St Louis: The CV Mosby Co, p 637-642.
7. Zake EZN (1982): Uterine rupture during labour in a Ugandan general hospital – Improved prognosis following reorganisation of antenatal care. *Singapore J Obstet Gynaecol* 13: 133-136.

Correspondence: Dr. E.Z.N. Zake, Head, Obstetrics and Gynaecology, Mbale Hospital, P.O. Box 65, Mbale, Uganda.