



Neuroimaging Highlight

Widening the Spectrum of Neuroradiological Manifestations of B12 Deficiency: Hyperintensities in the Inferior Cerebellar Peduncles on T2 Images

Teresa Vilela Pereira , Daniela Miti Tsukumo Seixas, Fabiano Reis, Luiz Fernando Monte Borella  and Lucas Martim Moschem

Hospital de Clínicas da Universidade Estadual de Campinas (UNICAMP), Campinas, Brazil

Keywords: neurology – clinical; neuroradiology; radiology

(Received 27 November 2023; date of acceptance 20 December 2023; First Published online 5 January 2024)

We report the case of a 54-year-old woman with no previous medical history who presented with confusion, tetraparesis, and bilateral Babinski signs. Cranial nerve examination was normal. Macrocytic anemia with hypersegmented neutrophils (hemoglobin 6.3 g/dl; hematocrit 20.4%; mean corpuscular volume 113.3 fl; mean corpuscular hemoglobin 35 pg), vitamin B12 levels below 150 pg/mL (reference range 197–771 pg/mL), and atrophic pangastritis were noted. Serologic tests for hepatitis, syphilis, and HIV were negative, and inflammatory markers were within normal limits. Cerebrospinal fluid analysis showed no alterations. CT scan of the skull revealed no obvious abnormalities, and there were no other laboratory findings to explain the current condition, other than the B12 deficiency. Brain magnetic resonance imaging (MRI) revealed

FLAIR hyperintensities in the supratentorial course of the cortico-spinal tracts (Figure 1). In addition, there was hyperintensity on T2/FLAIR and restricted diffusion in both inferior cerebellar peduncles (Figure 1). Subsequent MRI scans after B12 replacement (1075 pg/mL) demonstrated regression of the previously observed changes (Figure 2) and clinical improvement.

Vitamin B12 deficiency has been recognized for over a century. Nevertheless, it presents in a variety of ways, either completely asymptomatic or with hematologic, psychiatric, or neurologic symptoms. Due to its heterogeneous presentation, this deficiency is often overlooked or misdiagnosed.^{1,2}

Vitamin B12 is essential for myelination and central nervous system function, and its deficiency can lead to late-onset

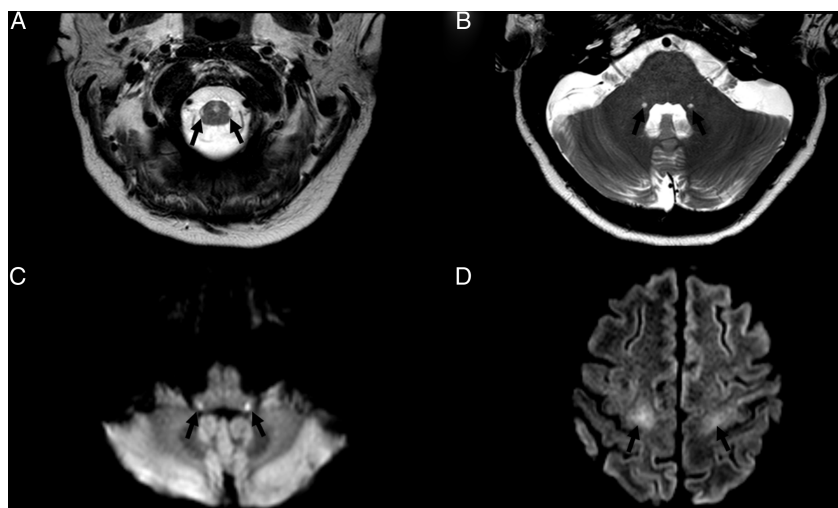


Figure 1: Axial T2-weighted image showing hyperintensities in the lateral columns, in the lateral corticospinal tract (A); symmetric hyperintensities in the inferior cerebellar peduncles (B). Axial diffusion shows hyperintensities (restricted diffusion) in the inferior cerebellar peduncles (C) and hyperintensities in the subcortical white matter of the precentral gyri (D).

Corresponding author: Teresa Vilela Pereira; Email: teresavpereira@hotmail.com

This manuscript has not been published and is not under consideration for publication elsewhere.

Cite this article: Pereira TV, Seixas DMT, Reis F, Borella LFM, and Moschem LM. (2024) Widening the Spectrum of Neuroradiological Manifestations of B12 Deficiency: Hyperintensities in the Inferior Cerebellar Peduncles on T2 Images. *The Canadian Journal of Neurological Sciences* 51: 838–839, <https://doi.org/10.1017/cjn.2023.331>

© The Author(s), 2024. Published by Cambridge University Press on behalf of Canadian Neurological Sciences Federation.

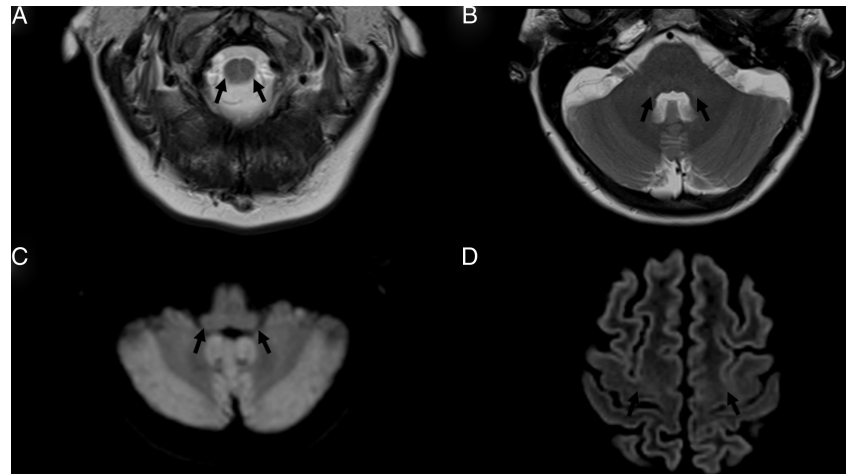


Figure 2: Decrease in the conspicuity of the signal abnormalities after treatment (Figure 1).

neurological manifestations.³ Neurological involvement occurs in approximately 40% of patients,² most commonly in the form of myelopathy, polyneuropathy, and optic neuropathy, but it rarely affects the white matter.^{4,5}

Anatomopathological studies demonstrate microscopic myelin and axonal vacuolation. There is a preferential degeneration of the posterior and lateral funiculus of the spinal cord, most commonly affecting the cervical and/or thoracic spine.⁴

Notably, the detection of signal abnormalities in the inferior cerebellar peduncles, as observed in this case, is a rare and previously unreported presentation, representing an additional imaging finding in this disorder. It is imperative to recognize this presentation because of the promising clinical and radiologic improvements following supplementation.⁴

Funding. We have no funding to report.

Competing interests. We have no competing interest to disclose.

References

1. Wolffenbuttel BHR, Wouters HJCM, Heiner-Fokkema MR, van der Klauw MM. The many faces of cobalamin (Vitamin B12) deficiency. *Mayo Clin Proc Innov Qual Outcomes.* 2019;3:200–14.
2. Das S, Dubey S, Pandit A, Ray BK. Myeloradiculoneuropathy due to vitamin B12 deficiency: an unusual clinical and radiological presentation. *BMJ Case Rep.* 2021;14:e239415.
3. Stabler SP. Clinical practice. Vitamin B12 deficiency. *N Engl J Med.* 2013;368:149–60.
4. Corrêa DG, da Cruz Jr LCH, da Rocha AJ, Pacheco FT. Imaging Aspects of Toxic and Metabolic Myelopathies. *Semin Ultrasound CT MR.* 2023; S0887-2171(23)00037-9.
5. Bimbato EM, Carvalho AG, Reis F. Toxic and metabolic encephalopathies: iconographic essay. *Radiol Bras.* 2015;48:121–5.