



Looking through the crystal ball feasibility of tele-echocardiography using smart glasses in neonates: a pilot study

Original Article

Cite this article: Michaelis A, Weidenbach M, Altmann I, Markel F, Löffelbein F, Dähnert I, Gebauer RA, and Paech C (2025) Looking through the crystal ball feasibility of tele-echocardiography using smart glasses in neonates: a pilot study. *Cardiology in the Young* 35: 87–92. doi: [10.1017/S1047951124026647](https://doi.org/10.1017/S1047951124026647)

Received: 10 April 2024

Revised: 11 June 2024

Accepted: 9 September 2024

First published online: 30 October 2024

Keywords:




telemedicine; pediatric cardiology; real-time transmission; smart glasses; digital health; neonatal functional echocardiography

Corresponding author:

A. Michaelis;

Email: michaelis@helios-gesundheit.de

*Shared first authorship, these authors contributed equally to this work

A. Michaelis^{*} , M. Weidenbach^{*}, I. Altmann, F. Markel, F. Löffelbein , I. Dähnert , R.A. Gebauer and C. Paech

Department for Pediatric Cardiology, University of Leipzig -Heart Center, Leipzig, Germany

Abstract

Background: In recent years, the importance of telemedicine has increased significantly. Especially in the field of echocardiography, virtual reality glasses offer the possibility of real-time data transmission without restrictions in the examination process. In particular, the care of critically ill newborns with suspected CHD might be improved by allowing a specialized paediatric cardiologist to remotely guide an echocardiographic examination. The current study aims to prove whether novices, under Google Glass guidance by a paediatric cardiologist, can perform an appropriate neonatal echocardiography. **Methods:** The current study is a prospective monocentric single-blinded pilot study. Participants were supposed to perform two test runs: The first test run was “unguided” and the second test run was instructed via Google Glass. A validated training simulator for neonatal echocardiography “EchocomNeo, Echocom GmbH” was used. The study took place at the Leipzig Heart Center, Department of Pediatric Cardiology from April 2022 to November 2022. **Results:** A total of 21 medical students were enrolled. In total 252 views (126 views in each test run) were recorded. The overall performance was significantly higher in the Google Glass guided test run compared to “unguided” (structure score: 77.6% vs. 63.2%. $p < 0.001$ and quality score: 58.7% vs. 47.2%, $p < 0.001$). Also, the time was significantly lower in the Google Glass guided test run than in the unguided test run, $p = 0.014$. **Conclusion:** Google Glass guidance by a paediatric cardiologist could optimize the performance of novices in echocardiography using a standardized neonatal echo-simulator with structural normal cardiac anatomy.

Introduction

Over the last decade, the interest in telemedicine has been growing rapidly. Especially during the COVID-19 pandemic, with restricted personal exchange and interaction, many attempts have been made to integrate telemedicine into everyday clinical practice.¹ Likewise, interest in telemedicine is growing in the field of cardiology, especially for echocardiography.^{2–4} It could be shown that particularly community hospitals, which do not have a specialised cardiologist on site, have profited from telemedicine.⁵ There are two methods of transmitting echocardiographic data: The “store and forward technology”^{6,7} and the “real time transmission.” The latter offers the advantage that the paediatric cardiologist can not only evaluate but also guide the examination and it provides the opportunity to communicate directly with patients and families. By the use of “tele-echocardiography,” costs could be saved, particularly by avoiding unnecessary transfers to specialised hospitals.^{3,5} Furthermore, the establishment of telemedicine enables an improved training of physicians and thus a better quality of echocardiography.^{5,8,9}

In recent years, a new wearable communication device, called “smart glasses,” has attracted interest in the clinical field. Among the various providers, Google Glass is probably the most frequently used device,¹⁰ with already promising results. Since 2014, there have been isolated publications on the applicability of Google Glass in everyday clinical practice, particularly in the surgical fields.^{11–13}

Google Glass enables a new way of telemedical communication: To the fact that controlling can be done completely verbally, physicians are able to continue their practical activities without any restrictions. For echocardiography in particular, this offers the advantage that the examination can be performed under the guidance of a specialist. The number of neonatologists performing point-of-care ultrasound is increasing.¹⁴ Ultrasound machines are thus readily available, but expertise in echocardiography is still limited.¹⁵ This may result in incorrect diagnoses, unnecessary transfers to specialised centres of paediatric cardiology, and delayed initiation of vital therapies.³ The use of Google Glass so far is mainly related to remote monitoring and barely to the assistance in procedures via virtual reality glasses. Data on the applicability of Google Glass in guiding an echocardiographic examination are scarce, with only

© The Author(s), 2024. Published by Cambridge University Press. This is an Open Access article, distributed under the terms of the Creative Commons Attribution licence (<https://creativecommons.org/licenses/by/4.0/>), which permits unrestricted re-use, distribution and reproduction, provided the original article is properly cited.

a small number of cases reported.^{16–18} In the context of increasingly present telemedicine, live data transmission using virtual reality glasses could potentially help to optimise and centralise patient care and facilitate interhospital communication. The current study aims to prove whether novices, under Google Glass guidance by an experienced paediatric cardiologist, can perform an adequate neonatal echocardiography.

Methods and materials

Study design

The current study is a prospective monocentric single-blinded pilot study to examine the feasibility of smart glasses to instruct a complete neonatal echocardiographic examination. We used Google Glass (V3 R 17). To standardise the examination and for ethical reasons, we used a well established training simulator for neonatal echocardiography “EchocomNeo, Echocom GmbH, Nieheim Germany.”

Study population and setting

The study took place at the Leipzig Heart Center, Department of Pediatric Cardiology from April 2022 to November 2022. Participants were recruited from medical school in Leipzig.

Inclusion criteria: Medical students without any experience in echocardiography.

Exclusion criteria: Previous experience in echocardiography.

Study protocol

Before participation, written informed consent was obtained from all subjects involved. Following inclusion, participants received a video briefing (five minutes) on Google Glass, as well as instructions on the principles of echocardiography. Furthermore, a briefing on the echocardiography simulator was given by the study physicians. The following standard views had to be performed—1. Subcostal long axis, 2. Apical four-chamber view, 3. Parasternal short axis at the level of the aortic valve, 4. Parasternal short axis, level of papillary muscles, 5. parasternal long axis, and 6. Suprasternal long axis. The appropriate characteristics for each plane were determined according to international standards.⁹ Participants were supposed to perform two test runs: The first test run as “unguided” and the second test run instructed via Google Glass as “Google Glass guided.”

First test run “unguided” (Pre-test)

Standard echocardiographic views were performed independently by the participants on the echo-simulator according to written instructions. The instructions contained an example image for each axis, as well as details of the obligatory structures, which had to be displayed. It also contained information on the positions and movements of the transducer. The test run was terminated after 90 s or by the participants themselves when they were satisfied with the obtained view. The participants did not receive any feedback on the correctness or evaluation of their examination.

Second test run, “Google Glass guided” (Posttest)

The participants were guided remotely via Google Glass by a paediatric cardiologist. Google Glass was connected to a computer via WiFi (5G hotspot), Figure 1. For the instruction with Google Glass, defined terms were used (e.g. tilting, positioning, clockwise and counterclockwise rotation, etc.). The test run was terminated




Figure 1. Participant with Google Glass in front of the echocardiography-simulator.

after 90 s or by the guiding paediatric cardiologist when he was satisfied with the obtained view.

For both test runs, the last ultrasound sequences were recorded (as short echocardiographic loops) for documentation and post-hoc analysis. Another paediatric cardiologist, blinded to the examinations, subsequently assessed the echocardiographic images of the participants and evaluated the examination (one score for the depiction of the required anatomical structures “structure score” and one score for the general imaging quality “quality score”). Furthermore, the time until correct axis setting was analysed and compared between both test runs (i.e. “pretest-posttest design”). For each correctly displayed anatomical structure, two points were scored. The quality score was graded by the paediatric cardiologist according to the subjective impression of the imaging quality (Table 1). In addition, the time for each view was analysed and compared between both test runs.

Technical data

Google Glass V3 R 17

Communication: wireless interface-Bluetooth 5.0, IEEE 802.11ac; connections: USB 2.0, USB-C; input: multi-touch gesture touchpad, microphone; camera: 8 megapixel; operating system: Android 8.0 (Oreo); distribution partner “Cloudwuerdig GmbH” (Software Engineer) as part of the “Public Cloud Group GmbH” (IT consultant): two limited licenses for the conference software “Meet” and the Google Workspace; WiFi connection (5G hotspot); computer: Apple MacBook (Figure 2). In order to facilitate the use of the glasses for the participants, only the live data transmission and hands-free control of Google Glass were used in this study and no other virtual reality functions.

Echo-Simulator “EchocomNeo, Echocom GmbH, Nieheim, Germany”

The simulator consists of a life-sized neonatal silicon manikin, a dummy probe, a 3D tracking device, and a computer. The 3D tracking system tracks the position of the dummy probe, and according to its position, a stored real 3D data set is sliced, simulating a real echocardiographic examination. The validated simulator is widely used to train neonatologists and paediatric cardiologists.^{20–24} In this application, a split screen displays a 2D echocardiography image side-by-side with a 3D virtual scene. The latter is used for guidance of trainees using the simulator. This

Table 1. Performance scoring system

View	required structures	point range to be achieved (structure score)	Point range to be achieved (quality score)
Subcostal long axis	LA, LV, RA, RV	0-8	0-4
Apical four chamber view	LA, LV, RA, RV, IVS*	0-10	0-4
Parasternal short axis	LA, RA, AV, PA	0-8	0-4
Parasternal short axis, ventricle plane	LV, papillary muscles	0-4	0-4
Parasternal long axis	LA, LV, A, CA, IVS**	0-10	0-4
Suprasternal long axis	AA	0-2	0-4

LA = left atrium; LV = left ventricle; RA = right atrium; RV = right ventricle; IVS* = interventricular septum vertical; IVS** = interventricular septum horizontal; AV = aortic valve cross section; PA = pulmonary artery; CA = cardiac apex; A = Aorta/ left outflow tract; AA = aortic arch; structure score - 0, 1 or 2 points were distributed for each structure; quality score - 0, 1, 2, 3 or 4 points were given for the quality; a higher score indicated a better imaging quality.

**Figure 2.** Google Glass V3 R 17.

virtual reality scene was omitted for the purpose of this study so that there was no additional support by the simulator.

Statistical analysis

A descriptive statistical analysis was performed with SPSS 29. Data are reported as median, minimum, and maximum or n (%). Data were tested for normal distribution (Shapiro-Wilk test). Data without homogeneity of variance were analysed by Wilcoxon signed-rank test.

Results

Participant characteristics

A total of 21 medical students were enrolled. The mean age was 25.5 years (minimum 22 years, maximum 34 years) and 57.1% of the participants were female.

Table 2. Time of test run “unguided” and “Google Glass guided”; mean (min; max)

	unguided n = 126	Google Glass guided n = 126	p-value
Time (s)	47.7 (6;90)	40.1 (8;90)	0.014

Table 3. Structure score and quality score of both test runs (“unguided” and “Google glass guided”); mean (min;max)

	Unguided n = 126	Google Glass guided n = 126	p-value
Structure score (%)	63.2 (0;100)	77.6 (0;100)	< 0.001
Quality score (%)	47.2 (0;100)	58.7 (0;100)	< 0.001

The test runs (“unguided” and “Google Glass guided”) were fully completed by all participants. Overall, 252 views (126 views in examination 1 and 126 views in examination 2) were recorded. One view (parasternal short axis view of student number 17, “unguided”) could not be saved properly due to technical difficulties. Therefore, no score was given for the quality of this axis.

Performance scores (structure score, quality score) and time

The time was significantly lower in the Google Glass guided test run (mean 40.1 s) than in the unguided test run (mean 47.7 s) Table 2. Also, the overall performance (structure score and quality score) was significantly higher in the Google Glass-guided test run compared to “unguided” (<0.001) Table 3. Both test runs showed minimal quality scores of 0%. It should be noted that the results of the suprasternal long axis differed from the other views. Here, an equivalent performance of the “unguided” test run compared to “Google Glass guided” was shown, but without significance (structure score 45.2% vs. 45.2% $p = 1$; quality score 42.9% vs. 33%, $p = 0.33$; time 64.1s vs. 64.7s, $p = 0.9$), Figure 3.

Discussion

To the best of our knowledge, this is the first study investigating if the performance of novices doing an echocardiographic examination on neonates can be improved through smart glass support by a paediatric cardiologist.

In recent years, the impact of telemedicine has grown rapidly, boosted by the restrictions of the COVID-19 pandemic. Especially echocardiography seems to offer excellent conditions for telemedical implementation. There are two methods of transmitting echo data: The “store and forward technology”^{4,6,7} and the “real time transmission.” Using the so-called “Tele-Echocardiography” via real-time transmission, an immediate diagnosis and influence on the examination are possible. The first live transmission of neonatal echocardiography via integrated services digital network (ISDN) lines (digital network lines) was reported in 1996 by Fisher et al.²⁵ In a recent study, using desktop videoconferencing computers for tele-echocardiography over ISDN lines, Sable et al. were able to show that real-time transmission of echocardiography in neonates could be cost-effective, improves patient care, and enhance sonographer education.³ Especially, unnecessary long transports might be avoided using tele-

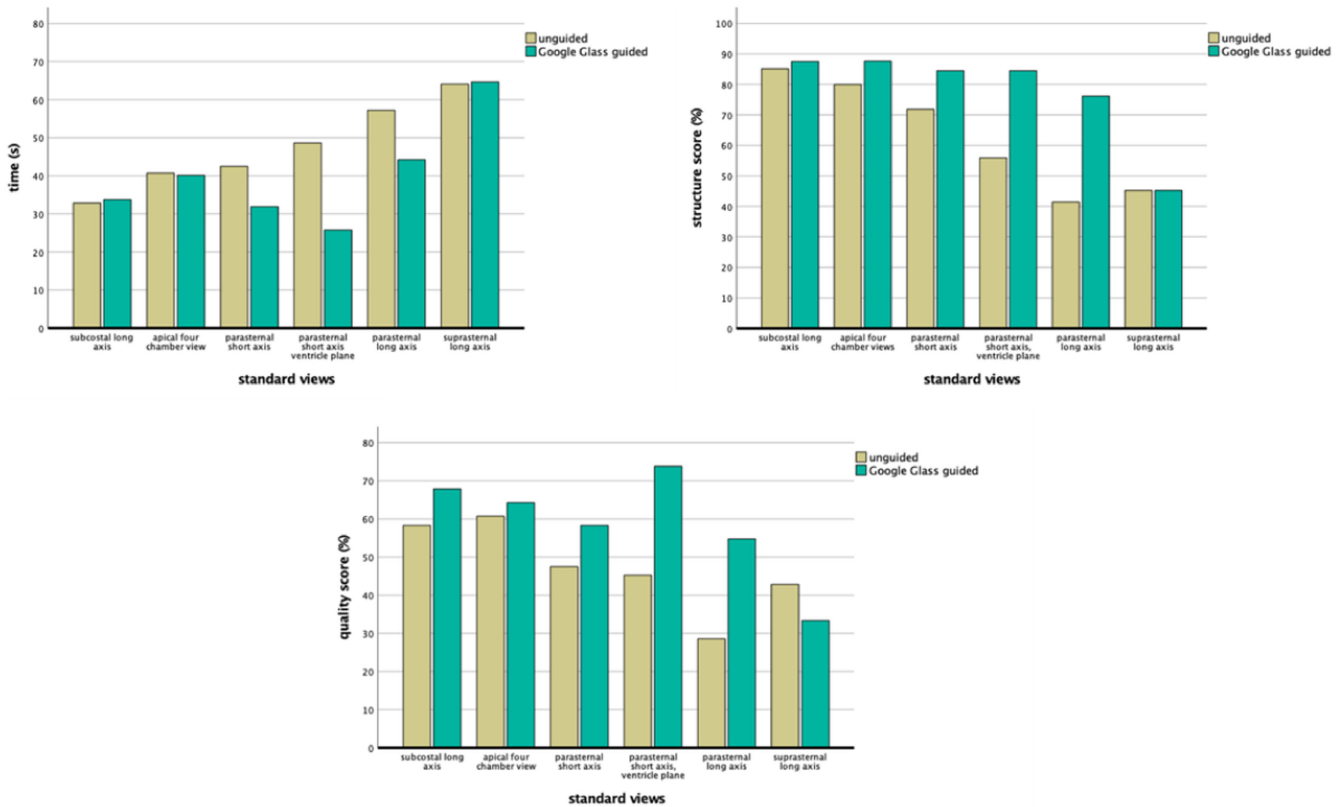


Figure 3. Bar charts of the performance scores and time: “unguided” (yellow) vs “Google Glass guided” (green); up left – time; up right – structure score; below – quality score.

echocardiography. This advantage could also be shown for the ambulatory management of CHDs in a retrospective study from Phillips et al.¹ However, the results as to which method is preferable differ. In a large study by Haley et al., there was no significant difference in real-time transmission of echocardiography and recorded echocardiography studies by the fourth year of the study.⁷ Yet, they emphasised the advantage of direct guidance of echocardiography using real-time transmission. Lewin et al. concluded from their data that real-time transmission seems to be superior to video recordings. There are numerous studies that were able to show successful paediatric tele-echocardiography with excellent quality images.^{4,5,8,26,27}

However, none of these studies used virtual reality glasses. Due to the possibility of “hands free controlling” Virtual Reality Glasses have attracted interest also in the field of cardiac ultrasound. Among the various providers, Google Glass is probably the most frequently used device.¹⁰ In a prospective pilot study by Russell et al., users were able to achieve adequate ultrasound images of the parasternal long axis and to determine the ejection fraction of a healthy adult patient using Google Glass guidance.⁶ This is consistent with our findings. With a mean structure score of 77.6% and a quality score of 58.7%, the “Google Glass guided” test run showed a significantly better overall performance compared to the “unguided” test run with a structure score of 63.2% and a quality score of 47.2%, $p < 0.001$. Furthermore, the “Google Glass guided” performance was faster, with a mean time of 40.1 s, compared to “unguided” with a mean time of 47.7 s, $p < 0.014$.

The standard views showed different impact of Google Glass guidance in comparison to the unguided examination. Especially the suprasternal long axis showed better to equivalent performance

of the “unguided” test run compared to “Google Glass guided,” but without significance (structure score 45.2% vs. 45.2% $p = 1$; quality score 42.9% vs. 33%, $p = 0.33$; time 64.1s vs. 64.7s, $p = 0.9$). In particular, the hand position of the study participant omitted the view of the transducer for the cardiologist and thus guidance was severely impeded. This influenced the performance of the echocardiography, especially in the suprasternal long axis view. Furthermore, the neonatal echocardiography simulator shows an albeit small different localisation of the suprasternal long axis view compared to real newborns and thus also could have influenced the performance score for this axis.

We used the standardised neonatal echo-simulator [“EchocomNeo, Echocom GmbH,” 22, 23, 24] for ethical reasons. Likewise, the echocardiography simulator offers better comparability of the ultrasound sequences (for example, various ultrasound conditions in different patients concerning weight or thorax shape). By using the principle echocardiographic standard views, we were able to ensure complete visualisation of the entire heart.

Our data show that Google Glass guidance by a specialised paediatric cardiologist could optimise the performance of echocardiography using a standardised neonatal echo-simulator with structural normal cardiac anatomy.

Besides the overall advantages of telemedicine mentioned above, there are some restrictions. An important restriction of tele-echocardiography is the dependency on an appropriate data transmission. In our study, we used a mobile 5G WiFi hotspot with theoretical download speeds of up to 10 gigabits per seconds (Gbit/s). This WiFi is currently not available everywhere and therefore needs to be established. Furthermore, physicians must be

instructed in the use of telemedical devices. A great challenge for clinical application will be the data protection regulations. Informed consent is mandatory before recording them with Google Glass, particularly if not using a password-protected, encrypted network.²⁸

Still, tele-echocardiography using Google Glass could potentially help to optimise and centralise patient care and facilitates interhospital communication.

Further studies are planned to analyse the impact of Google Glass guidance on the diagnosis of CHDs on the neonatal echosimulator.

Limitations

There are several possible limitations that could affect our study. First, the number of participants is small, limiting the statistical analysis. With the pre-test-posttest study design, a training effect of the participants cannot be ruled out with certainty. However, from the authors' point of view, this bias can be classified as very small, as the participants had no previous experience in handling echocardiography. In addition, the participants did not receive any feedback on the correctness or evaluation of their examination 1. From the authors' point of view, this possible training effect is therefore limited to the positioning and movement of the ultrasound probe. Furthermore, the participants were instructed to follow only the instructions of the paediatric cardiologist during examination 2 and not to adjust axes independently. The echosimulator cannot exactly replace the examination of a real patient but provides a more comparable study setting. The six standard views were included in the structure score with different weighting. Only the quality score had the same rating scale for all views (0%, 25%, 50%, 75%, and 100%). Furthermore, due to the restricted assessable suprasternal long axis, the results of the performance scores could be biased.

Conclusion

Google Glass guidance by a specialised paediatric cardiologist could optimise the performance of echocardiography using a standardised neonatal echo-simulator with structural normal cardiac anatomy.

Consent

All procedures performed with human participants were in accordance with the ethical standards of the institutional research committee and with the 1964 Helsinki Declaration and its later amendments (approval of the local ethic committee, application number 542/21-ek). Informed consent was obtained from all individual participants included in the study.

References

- Phillips AA, Sable CA, Atabaki SM, Waggaman C, Bost JE, Harahsheh AS. Ambulatory cardiology telemedicine: a large academic pediatric center experience. *J Investig Med* 2021; 69: 1372–1376. DOI: [10.1136/jim-2021-001800](https://doi.org/10.1136/jim-2021-001800).
- Chowdhury D, Hope KD, Arthur LC et al. Telehealth for pediatric cardiology practitioners in the time of COVID-19. *Pediatr Cardiol* 2020; 41: 1081–1091. DOI: [10.1007/s00246-020-02411-1](https://doi.org/10.1007/s00246-020-02411-1).
- Sable CA, Cummings SD, Pearson GD et al. Impact of telemedicine on the practice of pediatric cardiology in community hospitals. *Pediatrics* 2002; 109: e3. DOI: [10.1542/peds.109.1.e3](https://doi.org/10.1542/peds.109.1.e3).
- Mehta AR, Wakefield DS, Kienzle MG, Scholz TD. Pediatric tele-echocardiography: evaluation of transmission modalities. *Telemed J E Health* 2001; 7: 17–25. DOI: [10.1089/153056201300093831](https://doi.org/10.1089/153056201300093831).
- Grant B, Morgan GJ, McCrossan BA et al. Remote diagnosis of congenital heart disease: the impact of telemedicine. *Arch Dis Child* 2010; 95: 276–280. DOI: [10.1136/adc.2008.146456](https://doi.org/10.1136/adc.2008.146456).
- Sable C. Telemedicine applications in pediatric cardiology. *Minerva Pediatr* 2003; 55: 1–13.
- Haley JE, Klewer SE, Barber BJ et al. Remote diagnosis of congenital heart disease in southern Arizona: comparison between tele-echocardiography and videotapes. *Telemed J E Health* 2012; 18: 736–742. DOI: [10.1089/tmj.2012.0037](https://doi.org/10.1089/tmj.2012.0037).
- Widmer S, Ghisla R, Ramelli GP et al. Tele-echocardiography in paediatrics. *Eur J Pediatr* 2003; 162: 271–275. DOI: [10.1007/s00431-003-1170-6](https://doi.org/10.1007/s00431-003-1170-6).
- Miyashita T, Takizawa M, Nakai K et al. Telemedicine of the heart: real-time telemonitoring of echocardiography using satellite telecommunication. *Circ J* 2003; 67: 562–564. DOI: [10.1253/circj.67.562](https://doi.org/10.1253/circj.67.562).
- Klein GO, Singh K, von Heideken J. Smart Glasses – A New Tool in Medicine. *MEDINFO*. 2015: eHealth-enabled Health 2015; 216: 901–901. DOI: [10.3233/978-1-61499-564-7-901](https://doi.org/10.3233/978-1-61499-564-7-901).
- Muensterer OJ, Zoeller C, Bronstein M, Kübler J. Google Glass in pediatric surgery: an exploratory study. *Int J Surg* 2014; 12: 281–289. DOI: [10.1016/j.jisu.2014.02.003](https://doi.org/10.1016/j.jisu.2014.02.003).
- Gupta S, Boehme J, Manser K et al. Does wearable medical technology with video recording capability add value to on-call surgical evaluations? *Surg Innov* 2016; 22: 498–504. DOI: [10.1177/1553350616656278](https://doi.org/10.1177/1553350616656278).
- Wei NJ, Dougherty B, Myers A, Badawy SM. Using google glass in surgical settings: systematic review. *JMIR Mhealth Uhealth* 2018; 6: e54. DOI: [10.2196/mhealth.9409](https://doi.org/10.2196/mhealth.9409).
- Tissot C, Singh Y. Neonatal functional echocardiography. *Curr Opin Pediatr* 2020; 32: 235–244. DOI: [10.1097/MOP.0000000000000887](https://doi.org/10.1097/MOP.0000000000000887).
- Kluckow M, Seri I, Evans N. Echocardiography and the neonatologist. *Pediatr Cardiol* 2008; 29: 1043–1047. DOI: [10.1007/s00246-008-9275-3](https://doi.org/10.1007/s00246-008-9275-3).
- Russell PM, Mallin M, Youngquist ST, Cotton J, Aboul-Hosn N, Dawson M. First “Glass” education: telementored cardiac ultrasonography using google glass – a pilot study. *Acad Emerg Med* 2014; 21: 1297–1299. DOI: [10.1111/acem.12504](https://doi.org/10.1111/acem.12504).
- Lim H, Kim MJ, Park JM et al. Use of smart glasses for ultrasound-guided peripheral venous access: a randomized controlled pilot study. *Clin Exp Emerg Med* 2019; 6: 356–361. DOI: [10.15441/ceem.19.029](https://doi.org/10.15441/ceem.19.029).
- Romare C, Skär L. Smart glasses for caring situations in complex care environments: scoping review. *JMIR Mhealth Uhealth* 2020; 8: e16055. DOI: [10.2196/16055](https://doi.org/10.2196/16055).
- Mitchell C, Rahko PS, Blauwet LA et al. Guidelines for performing a comprehensive transthoracic echocardiographic examination in adults: recommendations from the American Society of Echocardiography. *J Am Soc Echocardiogr* 2019; 32: 1–64. DOI: [10.1016/j.echo.2018.06.004](https://doi.org/10.1016/j.echo.2018.06.004).
- Weidenbach M, Rázek V, Wild F et al. Simulation of congenital heart defects: a novel way of training in echocardiography. *Heart* 2009; 95: 636–641. DOI: [10.1136/hrt.2008.156919](https://doi.org/10.1136/hrt.2008.156919).
- Sacks LD, Motonaga KS, Krawczeski CD, et al. Abstract 15181: the national pediatric cardiology boot camp training program - five years' evidence of consistent educational benefit. *Circulation* 2020; 142. DOI: [10.1161/circ.142.suppl_3.15181](https://doi.org/10.1161/circ.142.suppl_3.15181).
- Weidenbach M, Paech C. Simulation in neonatal echocardiography. *Clin Perinatol* 2020; 47: 487–498. DOI: [10.1016/j.clp.2020.05.009](https://doi.org/10.1016/j.clp.2020.05.009).
- Dayton JD, Groves AM, Glickstein JS, Flynn PA. Effectiveness of echocardiography simulation training for paediatric cardiology fellows in CHD. *Cardiol Young* 2018; 28: 611–615. DOI: [10.1017/S104795111700275X](https://doi.org/10.1017/S104795111700275X).
- Wagner R, Rázek V, Gräfe F et al. Effectiveness of simulator-based echocardiography training of noncardiologists in congenital heart diseases. *Echocardiography* 2013; 30: 693–698. DOI: [10.1111/echo.12118](https://doi.org/10.1111/echo.12118).

25. Fisher JB, Alboliras ET, Berdusis K, Webb CL. Rapid identification of congenital heart disease by transmission of echocardiograms. *Am Heart J* 1996; 131: 1225–1227.
26. Colombo JN, Seckeler MD, Barber BJ et al. Application and utility of iPads in pediatric tele-echocardiography. *Telemed J E Health* 2016; 22:, 429–433. DOI: [10.1089/tmj.2015.0114](https://doi.org/10.1089/tmj.2015.0114).
27. Sable C, Roca T, Gold J, Gutierrez A, Gulotta E, Culpepper W. Live transmission of neonatal echocardiograms from underserved areas: accuracy, patient care, and cost. *Telemed J* 1999; 5: 339–347. DOI: [10.1089/107830299311907](https://doi.org/10.1089/107830299311907).
28. Mishra S. Google glass in medicine - the man with a computer on face. *Indian Heart J* 2016; 68: 586–587. DOI: [10.1016/j.ihj.2016.06.014](https://doi.org/10.1016/j.ihj.2016.06.014).