

Double trouble

John Foote, MD

A 22-year-old man was referred to the emergency department by his family physician for evaluation of a suspected pneumothorax. Eighteen hours earlier, while sitting in a bus, the patient had experienced the sudden onset of right-sided pleuritic chest pain. He denied shortness of breath, cough or fever, and had no history of trauma, injection drug use or HIV. He was taking no medications and had no history of a prior pneumothorax.

Physical examination revealed a well-appearing young man with a respiratory rate of 24 breaths/min and an oxygen saturation of 97% on room air. Auscultation revealed absent breath sounds over the right chest. There were no signs to suggest tension pneumothorax.

Results of a chest x-ray revealed a large pneumothorax

(Fig. 1). A pleural catheter was inserted and attached to a Heimlich valve. One hour later, a repeat x-ray confirmed 90% re-expansion. The patient was discharged home with follow-up arranged for the next day.

The patient returned, as instructed. He was feeling well, had normal vital signs and equal air entry bilaterally. A repeat chest x-ray was done (Fig. 2).

Optimal management at this time is:

- Discharge home with reassessment in 1–2 days.
- Attach the pleural catheter to suction.
- Insertion of a large bore chest tube.
- Placement of another pleural catheter.

For the Answer to this Challenge, see page 230.

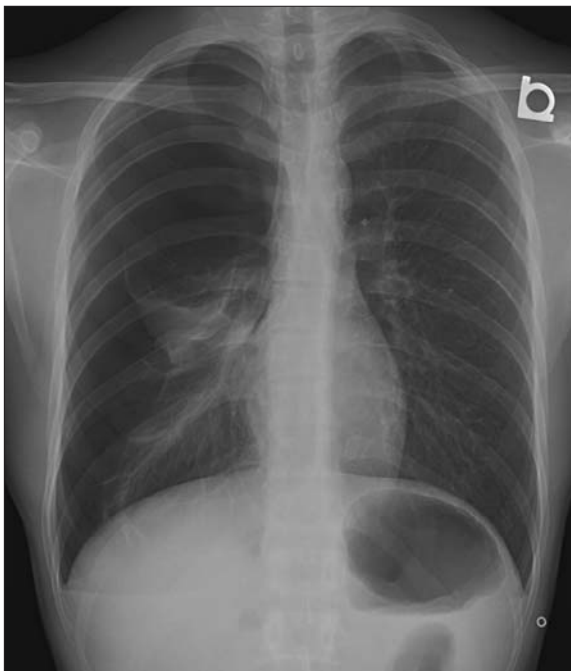

Fig. 1. Initial x-ray, revealing a large pneumothorax.

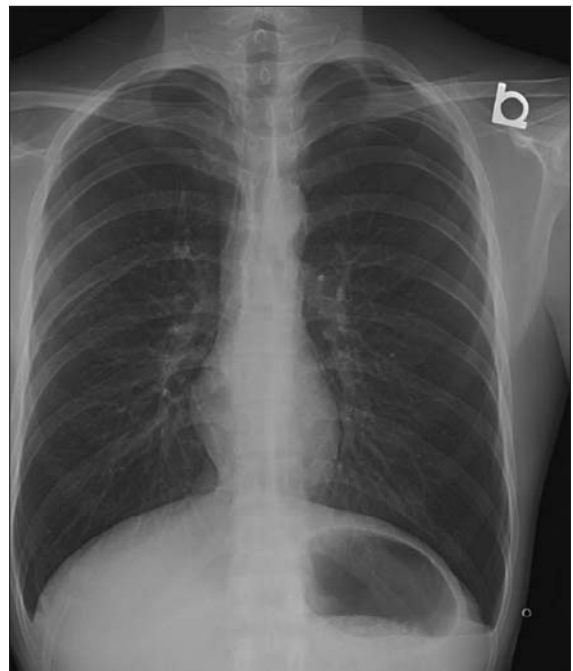


Fig. 2. X-ray performed 24 hours later.

Staff Physician, Department of Emergency Medicine, The Credit Valley Hospital, Mississauga, Ont.; Lecturer, Department of Family and Community Medicine, University of Toronto, Toronto, Ont.