

Gametogony of *Eimeria macusaniensis* Guerrero, Hernandez, Bazalar and Alva, 1971 in llama (*Lama glama*)

Research Article

Cite this article: Dubey JP (2018). Gametogony of *Eimeria macusaniensis* Guerrero, Hernandez, Bazalar and Alva, 1971 in llama (*Lama glama*). *Parasitology* **145**, 1540–1547. <https://doi.org/10.1017/S0031182018000483>

Received: 2 January 2018
Revised: 5 February 2018
Accepted: 3 March 2018
First published online: 12 April 2018

Key words:

Eimeria macusaniensis; *Lama glama*; macrogamonts; microgamonts; oocysts

Author for correspondence:

J P. Dubey, E-mail: jitender.dubey@ars.usda.gov

J P. Dubey

United States Department of Agriculture, Agricultural Research Service, Animal Parasitic Diseases Laboratory, Beltsville Agricultural Research Center, Beltsville, Maryland 20705-2350, USA

Abstract

Camelids (llama, alpaca, vicuñas, guanacos) are important for the economy of South America and *Eimeria* infections are an important cause of mortality in camelids. Of the six species of *Eimeria* in camelids, *Eimeria macusaniensis*, considered the most pathogenic, is distinctive; its oocysts are the largest among all *Eimeria* species in animals, its prepatent period is more than 1 month, and its oocysts have been found in mummies from prehistoric times. Although, *E. macusaniensis* gametogonic stages are found associated with enteritis in naturally infected camelids, the schizogonic stages are unknown and clinical disease has been reported in some camelids with no oocysts in feces. Described herein are morphological details of gametogonic development and oocyst formation of *E. macusaniensis* in a naturally infected llama (*Lama glama*), solely infected with this parasite. Microgamonts, macrogamonts and oocysts were located in large (up to 300 μm diameter) parasitophorous vacuoles of enterocytes in the ileum. Schizonts were not found. Review of previous reports suggests that multinucleated microgamonts have been mistaken for schizonts. Gametogonic development described in the present study can serve as a guide for differential diagnosis of *Eimeria* species in the histological sections of intestines.

Introduction

South American camelids consists of at least three species, llamas (*Lama glama*), alpacas (*Lama pacos*), guanacos (*Lama guanicoe*) and vicuñas (*Vicugna vicugna*); their generic distinction is controversial. Traditionally, they were distributed at high altitudes (3600–5400 m) in South America where they are source of meat, hide, fibre and transport, and their feces are used for fuel and fertilizer (Díaz *et al.* 2016). In many Western countries, they are reared for recreation and the live animal is the commercial product.

Neonatal diarrhoea is a major concern in camelids. Coccidiosis is considered an important cause of neonatal diarrhoea in camelids, but there are also many reports of fatal coccidiosis in adult alpacas and llamas (Rosadio and Ameghino, 1994; Cebra *et al.* 2007). More importantly, enteritis due to *Eimeria* species, especially *E. macusaniensis*, exposes camelids to secondary infections, including toxæmia due to *Clostridium perfringens* (Rosadio *et al.* 2010).

Six species of *Eimeria* are named from camelids: *E. macusaniensis*, *Eimeria lamae*, *Eimeria alpaca*, *Eimeria punoensis*, *Eimeria pervuiana* and *Eimeria ivitaensis* (Yakimoff, 1934; Guerrero, 1967; Guerrero *et al.* 1971; Leguia and Casas, 1998; Cafrune *et al.* 2009; Díaz *et al.* 2016). Of these, *E. macusaniensis* is the most prevalent and considered most pathogenic; mixed infections are common (Palacios *et al.* 2006; Cebra *et al.* 2007). Biologically, *E. macusaniensis* is unusual among all coccidian parasites in animals: its oocysts are the largest (>100 μm long) of any *Eimeria*, the prepatent period is very long (>30 days), and oocysts has been found in coprolites from prehistoric times in Peru and Chile (Levine and Ivens, 1970; Levine, 1973; Foreyt and Lagerquist, 1992; Jarvinen, 2008; Fugassa *et al.* 2008; de Souza *et al.* 2018).

Diagnosis of clinical coccidiosis in camelids is sometimes difficult because clinical signs can develop long before oocysts are detected in feces (Cebra *et al.* 2007). *Eimeria macusaniensis* is considered the most important coccidian of alpacas, and fatal infections have been reported in crias as young as 10 days old (Rosadio *et al.* 2010). The pathogenesis remains unclear because schizonts preceding gamonts have not been clearly demonstrated. It is likely, that immature microgamonts have been misidentified as schizonts. Therefore, details of gametogony of *E. macusaniensis* in a naturally infected llama are described herein to facilitate the diagnosis of *E. macusaniensis*.

Materials and methods

A 5-year-old male llama (*L. glama*) from Illinois, USA, had a history of chronic weight loss. It eventually became so weak that it was euthanized in 1999 and necropsied by the attending veterinarian. The animal was well cared for, it had been dewormed and was housed with several other llamas by a private owner. Coccidiosis was suspected and formalin-fixed tissues were

sent by the veterinarian to Dr D. M. Webb, Illinois Department of Agriculture, Animal Disease Laboratory (IDOA-ADL), Galesburg, Illinois, USA. All sections were stained with haematoxylin and eosin (HE). The initial diagnosis was *E. macusaniensis*-associated coccidiosis. No other cause was found, including toxæmia.

In December 1999, eight histological sections each containing two loops of the ileum of the llama were forwarded to me by post by Dr Webb, for diagnosis.

In 2017, review of the literature on camelid coccidia, I found that the description of endogenous stages of *E. macusaniensis*

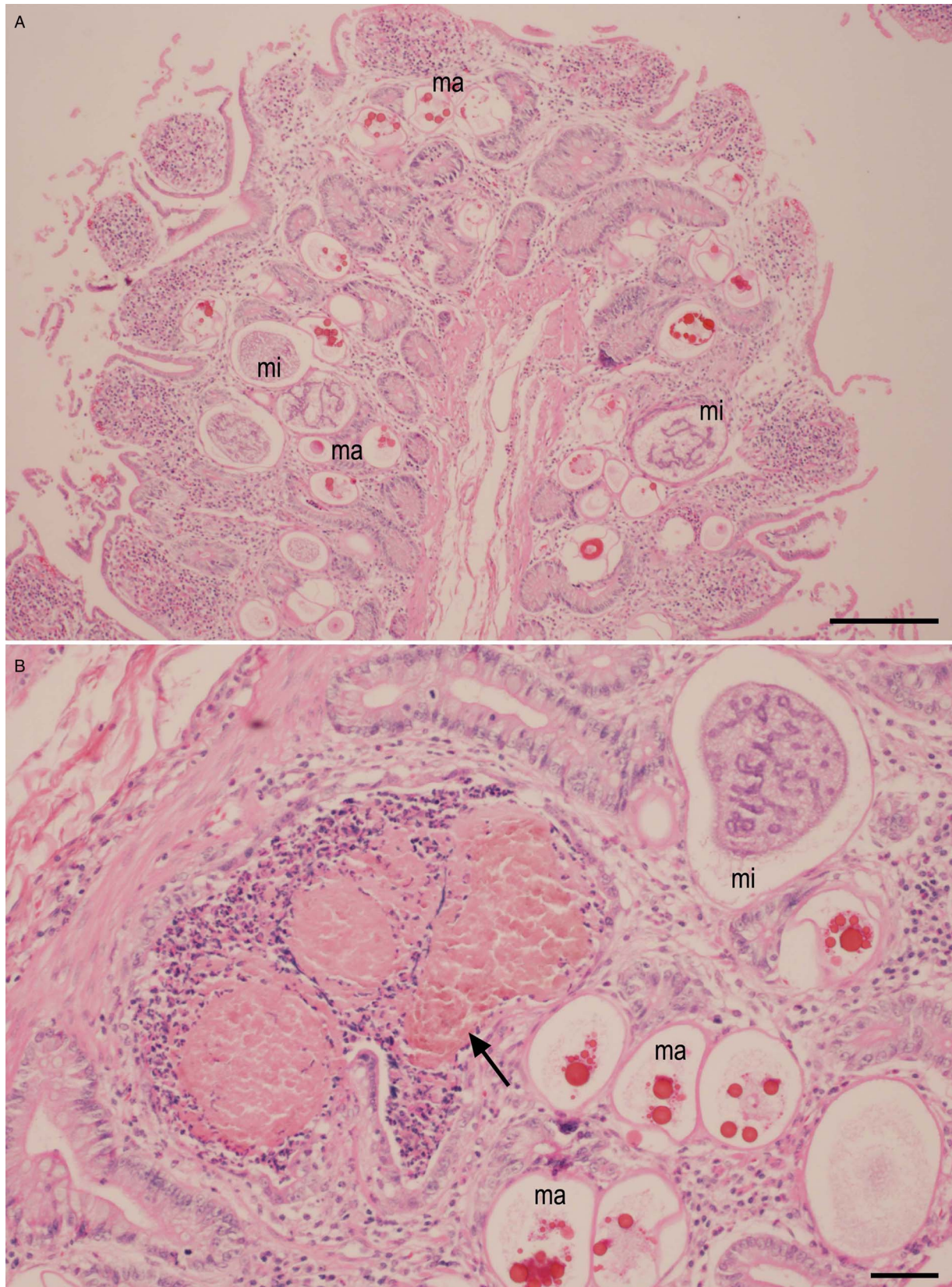


Fig. 1. *Eimeria macusaniensis*-associated lesions in the ileum of the naturally infected llama from Illinois, USA. Haematoxylin and eosin stain. Note microgamonts (mi) and macrogamonts (ma). (A) Hyperplasia with gametogonic stages in the lamina propria. Bar = 200 μm . (B) Plugging of lumen of a gland of Lieberkühn (arrow) with degenerating host cells. Bar = 50 μm .

was not complete. Therefore, I requested more information on the llama from Illinois, but discovered that the IDOA-ADL is now permanently closed, files have been discarded and Dr Webb has retired. Therefore, no additional details are available about this case other than those presented here.

Retrospectively, three HE-stained slides were de-stained and re-stained with periodic Schiff reaction (PAS), counter stained with haematoxylin (PASH). All 16 sections of intestine were examined at 1000 \times magnification, photographed and endogenous stages were measured using a digital camera (DP 73) fitted on an Olympus AX 70 microscope.

Results

All histological sections were heavily infected with *Eimeria*. There was hyperplasia of epithelium with hypercellularity in the lamina propria and occasional plugging of the lumen of the gland of Lieberkühn in crypts (Figs 1A, B). Tissue structures were well preserved. There was no evidence of bacterial infection or necrosis.

The parasitized host cell nucleus (probably an enterocyte) was indented but not hypertrophied. The heaviest infection was in crypts reaching to tunica muscularis mucosae.

All endogenous stages of the coccidium were located in large parasitophorous vacuoles (pv) with empty spaces (Figs 1–5). Merozoites or merozoite-shaped early gamonts were not seen. The earliest gamont contained a central mass with a nucleus (Fig. 2A). At this stage, it was not possible to differentiate between micro- and macrogamonts (Fig. 2A). Some parasitized pv were up to 300 μm in long and the parasitophorous vacuolar membrane was 1–2 μm thick (Figs 2 and 3).

The earliest microgamont had a 66 \times 31 μm pv with a 17 μm diameter central mass (Fig. 2A). Subsequently, nuclei were differentiated as the parasite increased in size but nuclear staining varied in intensity. In some microgamonts, the nucleus/central mass were surrounded by debris (Fig. 2C, E). There were few to several hundred nuclei, some were arranged in whorls, others were in groups, in blattophores and still others were scattered at the periphery (Fig. 2D–I). Fissures were seen in nuclear arrangement,

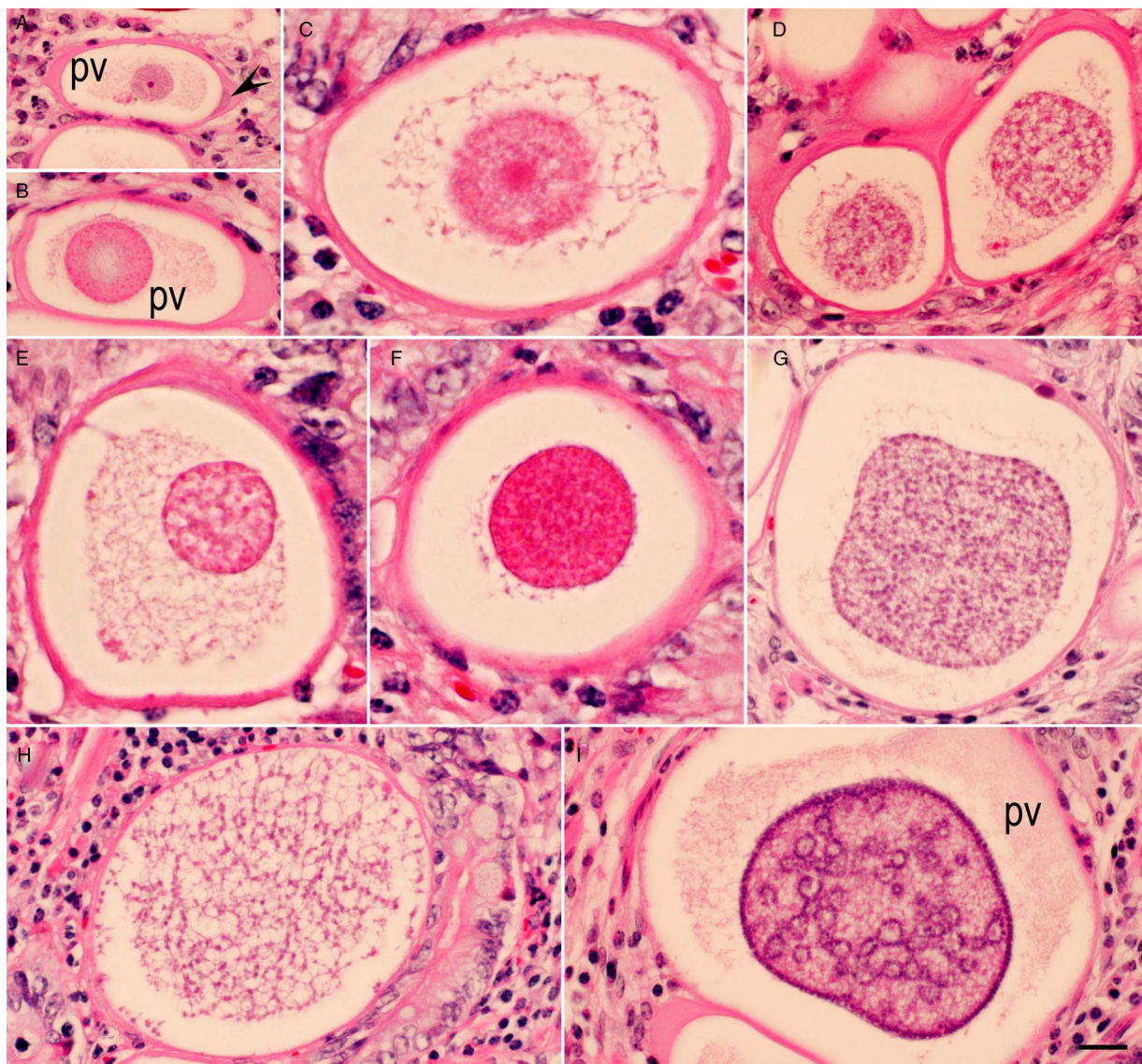


Fig. 2. Immature stages of *Eimeria macusaniensis* microgamonts in the ileum of the llama. Haematoxylin and eosin stain. Bar = 20 μm and applies to all parts. The parasites are located intracellularly in large parasitophorous vacuoles (pv). The parasitized host cell nucleus (arrowhead) is indented but not hypertrophied. (A) Earliest macrogamont with a central nucleus and a nucleolus. (B) Microgamont with a nucleus with a lightly stained central area. (C) Strands of debris is present around the central nucleus. (D–F) Varying appearance of nuclei in microgamonts. (G,H) Numerous nuclei, some are at the periphery, whereas most are in the central mass. (I) Peripheral arrangement of nuclei. Some nuclei are in circles scattered throughout the macrogamont.

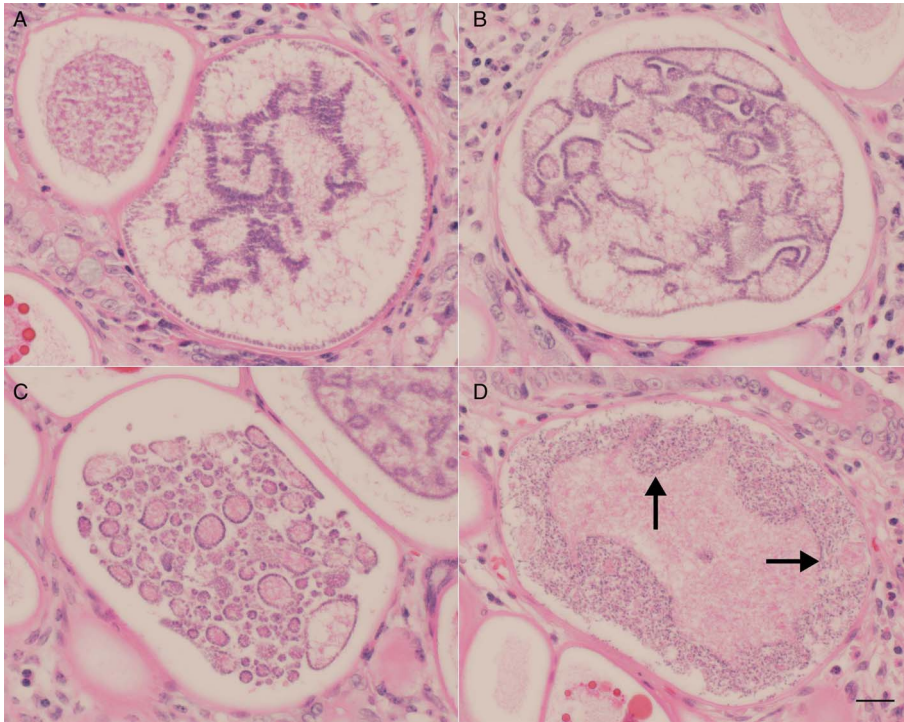


Fig. 3. Maturing stages of *Eimeria macusaniensis* microgamonts in the ileum of the llama. Haematoxylin and eosin stain. Bar = 20 μ m and applies to all parts. (A–C) Note different arrangements of nuclei in microgamonts. (D) Developing microgametes arranged peripherally (arrows). The central area contains amorphous material.

and some nuclei were arranged linearly (Figs 3A, B and 4A, B). In later stages of microgamonts, an amorphous mass was seen in between developing microgametes (Fig. 3D). Large microgamonts (excluding pv) measured $181 \times 149 \mu\text{m}$ ($164\text{--}199 \times 114\text{--}166$, $n = 17$). Mature microgametes were approximately 5 μm long; flagella were not identified (Fig. 4D). A residual body was not seen in any microgamont.

The earliest macrogamont-like structure had a $68 \times 45 \mu\text{m}$ pv with a 25 μm diameter central nucleus with a prominent nucleolus (Figs 5 and 6). The earliest macrogamont could be recognized by PAS-positive amylopectin granules (Fig. 6E), and subsequently by eosinophilic wall-forming bodies (WFB) (Fig. 5B). Initially, the PAS-positive granules were located centrally around the nucleus (Fig. 6E), later spread to the entire gamont. The location, number and size of WFB varied (Figs 5C, D and 6A, B). The WFB varied in the intensity of staining and number. The WFB bodies were <1 to 19 μm in diameter (Figs 5C, D and 6A). Debris was present in some macrogamonts (Fig. 5D).

Formation of an oocyst wall was observed in a few specimens. Figure 6A shows a macrogamont with central nucleus and varying-sized WFB, but without oocyst wall. Figure 6B shows an early oocyst with a diameter of 51 μm surrounded by a membrane (wall) of uniform thickness; the largest light pink staining WFB are 19 μm in diameter and the smallest deep red staining are 2 μm in diameter; a central nucleolus is present. Figure 6C shows an oocyst with a crumpled wall but still containing the varying-sized WFB. Figure 6D shows a mature oocyst without WFB; the inner most oocyst layer surrounding the sporont is 9 μm thick. There are two other membranes (layers) that surrounded the thick-walled oocysts. The entire sporont was PAS-positive (Fig. 6F).

Oocysts were seen intracellularly in the lamina propria, and extracellularly in the lumen of glands (Fig. 5F). Some oocysts were degenerating and surrounded by inflammatory cells. Fully developed longitudinally cut oocysts were $72 \times 50 \mu\text{m}$ ($65\text{--}80 \times 43\text{--}61$, $n = 13$). The oocyst wall was up to 11 μm thick, homogeneous and stained brilliantly with eosin. Oocysts had a micropyle and a micropylar cap was sometimes visible (Fig. 7).

Specimens deposited

Two sections of the ileum of the llama stained with HE (USNM no. 1473111) and PAS (USNM no. 1473112) were deposited in the National Museum of Natural History, Department of Invertebrate Zoology, Museum Support Center, MRC 534, Silver Hill Road, Suitland, Maryland, USA.

Discussion

There are discrepancies in the literature concerning the development of *E. macusaniensis*. It was initially found in a 5-month-old alpaca in Peru in 1967, but the species was not named until 1971 (Guerrero *et al.* 1967, 1971). The llama had a mixed infection with *Eimeria* species (Guerrero *et al.* 1967). The endogenous stages could not be assigned to specific species of *Eimeria*. Hodgkin *et al.* (1984) described gamonts and oocysts in the histological sections of a captive guanaco (*L. guanicoe*) that had died of leptospirosis and coccidiosis in Detroit Zoological Park, Detroit, Michigan, USA, and Schrey *et al.* (1991) described endogenous stages in a 3-year-old llama from Wyoming, USA that had died of coccidiosis perhaps with concurrent viral infection. In both of these reports from the USA, the gamonts and oocysts found in the histological sections were attributed to *E. macusaniensis*. Hodgkin *et al.* (1984) noted the absence of schizonts, whereas Schrey *et al.* (1991) found meronts (schizonts). The macrogamonts, microgamonts and oocysts reported in both papers are essentially similar to the findings in the present study. Minor differences in the dimensions of parasites maybe related to several factors. The endogenous stages of *E. macusaniensis* are located in large pv that are difficult to compare because of shrinkage during fixation and autolysis. In the present study, the llama was euthanized and necropsied soon after death and there was no evidence of autolysis.

The main difference between the results reported by Schrey *et al.* (1991) and the present study concerns their report of meronts. The pv containing meronts were $133\text{--}180 \times 105\text{--}169 \mu\text{m}$, and the meronts were $82\text{--}122 \times 60\text{--}90 \mu\text{m}$. The meronts contained blastophores, but the presence of merozoites was not

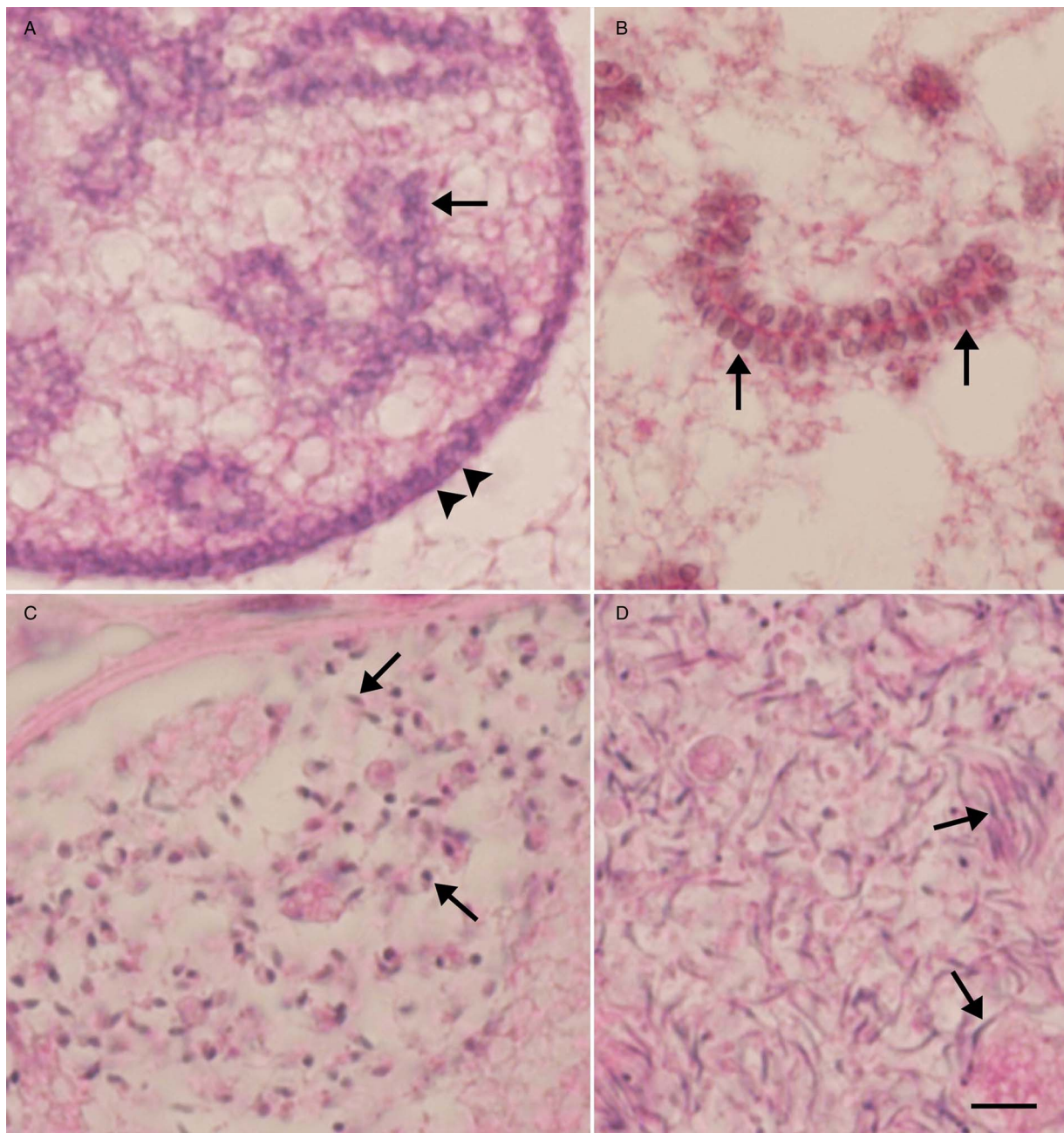


Fig. 4. Higher magnification of *Eimeria macusaniensis* microgametes in the ileum of the llama. Haematoxylin and eosin stain. Bar = 20 μm and applies to all parts. (A) Peripherally arranged nuclei (arrowheads). Some nuclei are arranged in blastophores (arrow). (B) Linear arrangement of duplicating nuclei along a nuclear strand (arrows). (C) Developing microgametes (arrows). (D) Slender microgametes (arrows).

mentioned. The illustration provided (Fig. 1 of Schrey *et al.* 1991) is identical to immature microgamonts illustrated in Figs 3 and 4 in the present study. It appears that the microgamonts were misidentified as meronts by Schrey *et al.* (1991).

Several other scientists who reported fatal coccidiosis in alpaca and llamas also mentioned meronts and gamonts in the histological sections of small intestine (Rosadio and Ameghino, 1994; Lenghaus *et al.* 2004; Palacios *et al.* 2004, 2005, 2006; Rawdon *et al.* 2006; Whitehead and Anderson, 2006; Cebra *et al.* 2007; Chigerwe *et al.* 2007; Schock *et al.* 2007; Johnson *et al.* 2009; Rosadio *et al.* 2010; Rojas *et al.* 2016), but did not describe the endogenous stages. It is likely that immature microgamonts were misinterpreted as schizonts.

To my knowledge, the schizogonic stages of *E. macusaniensis* are unknown and the pathogenesis of *E. macusaniensis* is partly unexplained. Cebra *et al.* (2007) reported severe *E. macusaniensis*-associated

coccidiosis in 49 camelids from Oregon, USA. The youngest affected alpaca was 21 days old. Histologic tissue sections of intestines were available from 13 camelids for which oocysts were not found in feces on first examination. Immature and mature gamonts were found in the tissues of 12 animals and oocysts in one of the 13 camelids on re-examination. In an outbreak of *E. macusaniensis*-associated coccidiosis on an Oregon farm, the earliest death occurred 20 days after camelids were moved to new farm; severe prepatent *E. macusaniensis* meront infection was confirmed histologically (Cebra *et al.* 2007). Thus, camelids can develop clinical coccidiosis before *E. macusaniensis* oocysts are found in feces.

As mentioned previously, oocysts of *E. macusaniensis* are morphologically distinctive, referred to as watermelon seeds or cut avacado. Oocysts in feces were 81–107 \times 61–80 μm with 8.3–11.4 μm thick wall (Guerrero *et al.* 1971). The wall consisted

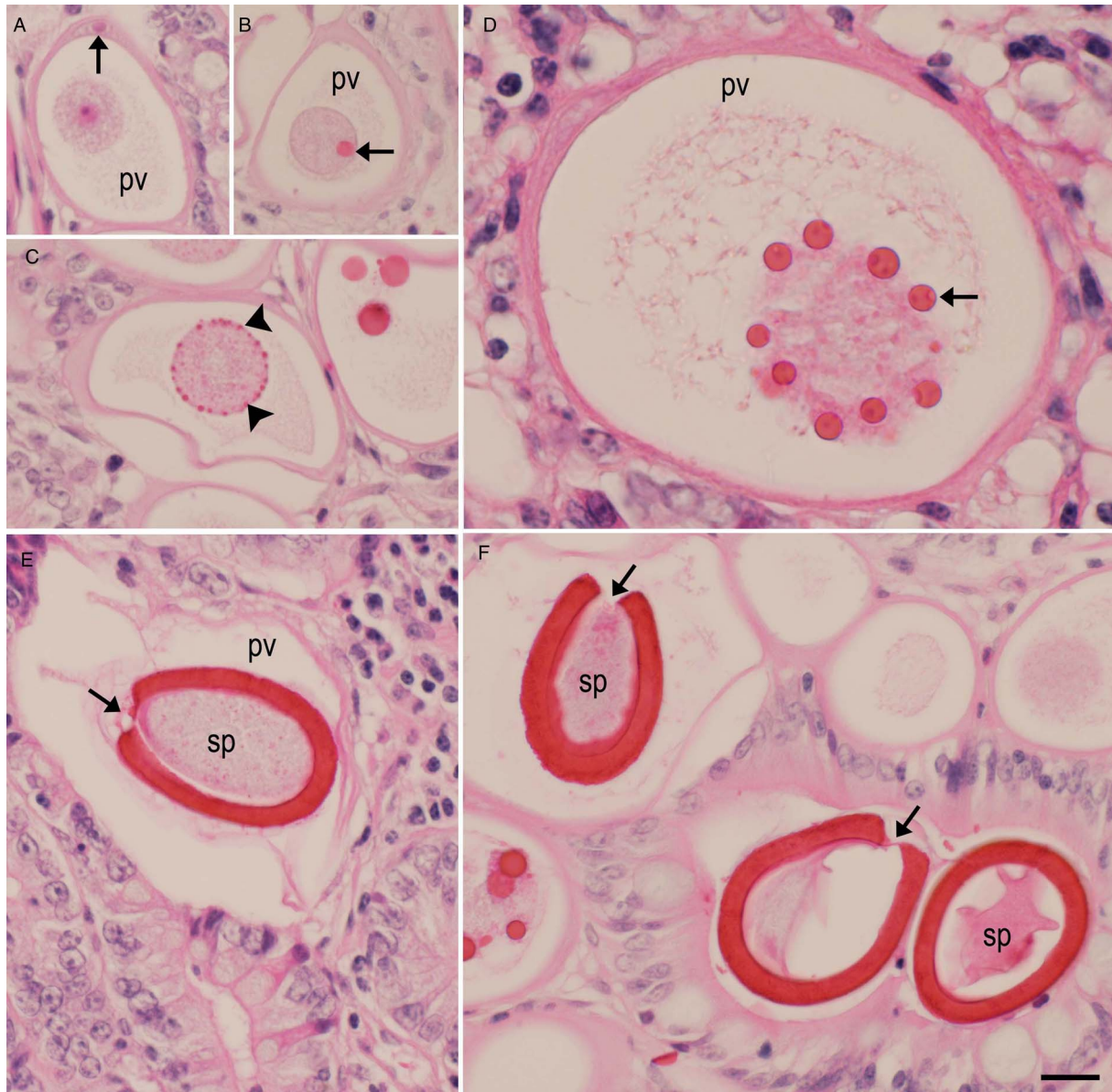


Fig. 5. Developing stages of macrogamonts of *Eimeria macusaniensis* in the ileum of the llama. The parasites are located intracellularly in large parasitophorous vacuoles (pv). Haematoxylin and eosin stain. Bar = 20 μm and applies to all parts. (A) Early stage with a nucleus and a prominent nucleolus. The parasitized host cell nucleus (arrow) is indented but not hypertrophied. (B) Central mass with one eosinophilic body (EB, arrow). (C) Collapsed pv containing a central mass with peripherally arranged small EB (arrowheads). (D) Macrogamont with varying-sized EB. Also, note debris around the central mass. (E) Longitudinally cut oocyst with collapsed pv. Note micropyle and sporont (sp) occupying the whole interior of the oocyst. (F) Three oocysts, two of them have shrunken sporont (sp). Arrows in E and F point to micropyle.

of three layers, an outer colourless 1.0 μm thick layer, middle 6.3–9.1 μm thick layer and 0.9 μm thin layer. In the present study, oocysts from feces were not available for comparison. However, in the histological sections stained with HE, two layers were recognized in mature oocysts. The outer most layer, interrupted at the micropyle, was lightly pink and <1.0 μm thick (Fig. 7). The main layer stained intensely with eosin was 7.0–11.0 μm thick and was interrupted at the micropylar end. The micropylar cap is stained light pink (Fig. 7).

In oocyst size, *E. macusaniensis* resembles another camelid *Eimeria*, *E. ivitaensis*. However, unlike *E. macusaniensis* oocysts, *E. ivitaensis* oocysts lack a micropyle. Differentiation of *E. macusaniensis* from *E. ivitaensis* in the histological sections may be problematic if oocysts are absent in feces or feces are not available for examination. Palacios *et al.* (2006) reported dual fatal infections of *E. macusaniensis* and *E. ivitaensis* in histological sections of seven young (4–5 months old) alpacas from Peru.

Schizonts (not illustrated) were detected in the jejunum and ileum; *E. ivitaensis* schizonts were said to be more pathogenic than those of *E. macusaniensis*. Location of endogenous stages of these coccidians differed; *E. macusaniensis* stages were in the jejunum, ileum, cecum and the ascending colon, whereas *E. ivitaensis* was confined to the jejunum and ileum (Palacios *et al.* 2006). The microgamonts and immature macrogamonts of both species of *Eimeria* were similar. However, their mature macrogamonts were different with respect to WFB. The WFB in *E. macusaniensis* were larger (13–18 μm) than those of *E. ivitaensis* (2–3.5 μm) (Palacios *et al.* 2006). The endogenous described in the present study were considered to be solely of *E. macusaniensis*. In the present study with *E. macusaniensis*, there was great variability in size and staining characteristics of WFB in *E. macusaniensis*.

Eimeria ivitaensis oocysts in feces are 83.5–98.6 \times 49.3–59.1 μm (Leguía and Casas, 1998). The oocyst wall is 4.0–4.5 μm thick with

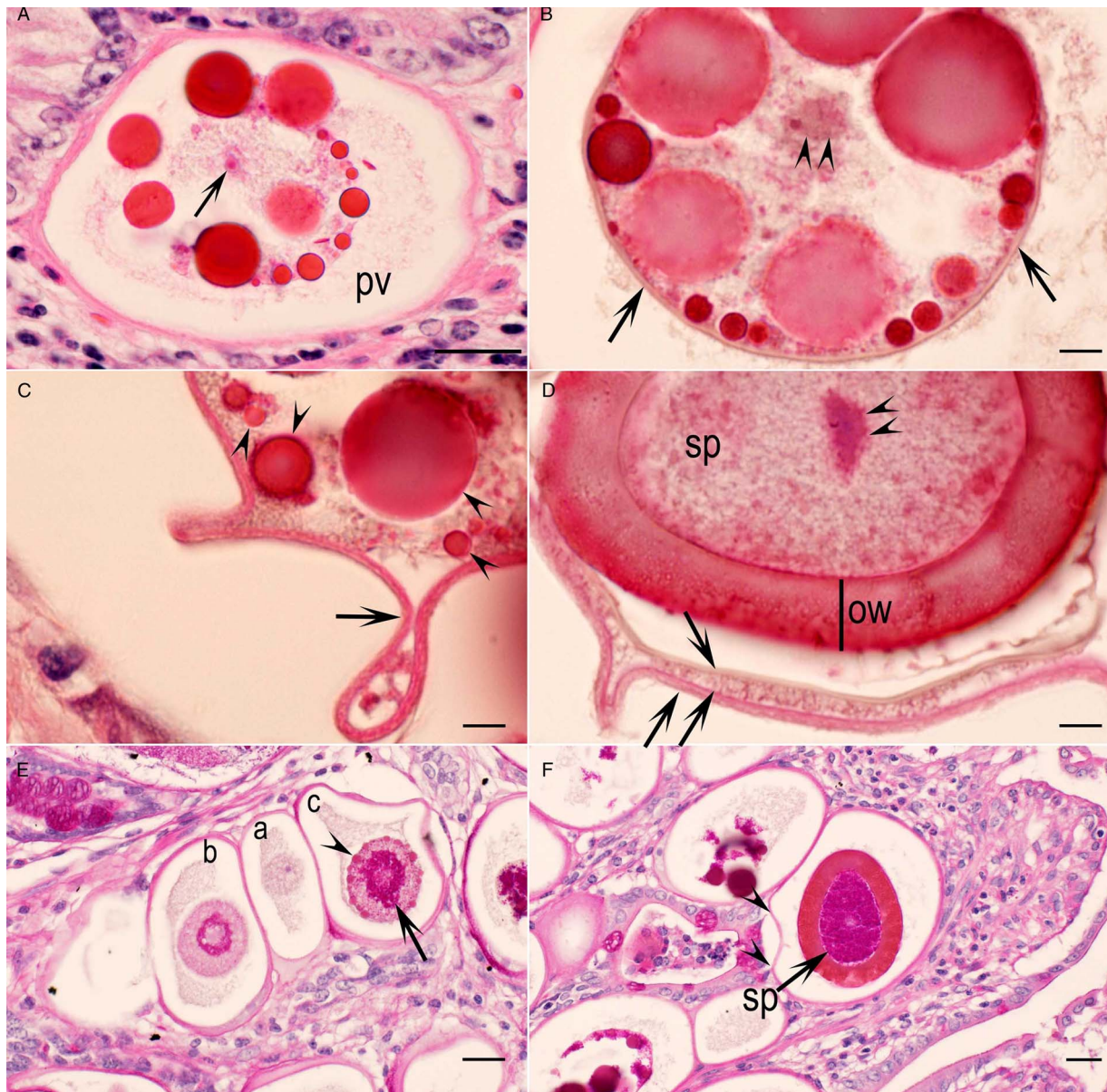


Fig. 6. Higher magnification of macrogamonts and oocysts of *Eimeria macusaniensis* in the ileum of the llama. A–D = haematoxylin and eosin stain, bar in A, E and F = 20 μm , B–D = 5 μm . (A) Large pv containing 13 varying-sized eosinophilic bodies (EB) of varying staining intensity. Note a central nucleolus (arrow). Also, note the absence of an oocyst wall. (B) Part of a macrogamont with varying-sized EB of varying staining intensity. The EB are surrounded by a well-defined membrane (wall, arrows). Arrowheads point to nucleus. (C) Collapsed oocyst wall/membrane (arrow) enclosing varying-sized EB (arrowheads). (D) Part of a longitudinally cut oocyst. Note the sporont (sp), a central nucleus (double arrowheads) and thick oocyst wall (ow). Arrows point to parasitophorous vacuolar membranes. (E) Three young macrogamonts: (a) without WFB and PAS-positive granules, (b) with PAS-positive granules surrounding the nucleus and (c) with PAS-positive granules (arrow) and WFB (arrowhead). (F) An oocyst in the lamina propria. Note the entire sporont is PAS-positive. Also, note collapsed parasitophorous vacuolar membrane (arrowheads).

three layers. Although *E. ivitaensis* oocysts are reported to lack a micropylar cap (Leguía and Casas, 1998), the micropylar cap may not be visible in the histological sections. In the present study, of all 16 sections examined, micropylar cap was found in only one *E. macusaniensis* oocyst. To my knowledge, morphology of developmental stages and oocysts has not been clearly described in the cases of *E. ivitaensis*-associated enteritis in camelids.

The development *E. macusaniensis* oocyst wall is unknown. In *Eimeria* species, the oocyst wall is initiated by the secretions of WFB. Most *Eimeria* species have two types of WFB, type 1 and type 2. The WFB1 are electron dense and larger in size than WFB2, and their characteristics are species-specific (Ferguson *et al.* 2003). The WFB arise during the maturation of the macrogamont and form the oocyst wall. In some coccidians, there are additional veil-forming bodies (VFB); they form a veil-like outer

covering on the oocyst wall that disappears when the oocysts are excreted in feces (Ferguson *et al.* 2003). Transmission electron microscopy and staining with special stains are needed for the identification of WFB and VFB.

These WFB have not been defined for camelid coccidia. In the present study, the WFB varied in size and intensity of staining with HE; other stains were not used. Initially, the WFB were small (1–2 μm), few and were located at the periphery of the central mass. Subsequently, larger sized (19 μm) and deeply eosinophilic WFB were seen. The earliest indication of oocyst wall formation was a membrane (wall) surrounding the gamont; both small and large WFB were present at this stage but some larger WFB stained lighter than others. A crumpled wall (membrane) was seen around the macrogamont that had intact WFB. In fully formed oocysts, the WFB were absent. Transmission

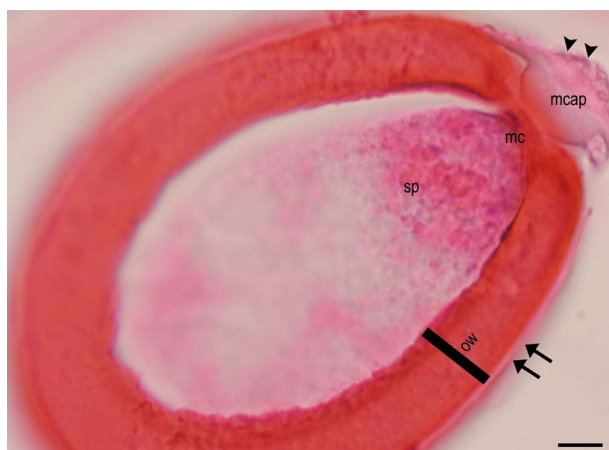

Fig. 7. Longitudinal section of a mature oocyst with a micropyle (mc), and micropylar cap (mcap) and thick oocyst wall (ow). There appears to be a thin parasitophorous vacuolar membrane (arrows) surrounding the oocyst.

electron microscopic studies will be needed to study the oocyst wall formation in camelid coccidia.

The endogenous stages of *E. macusaniensis* described here resemble the development of *Eimeria leuckarti* of horses meticulously described by Barker and Remmler (1972) in experimentally infected ponies euthanized 8, 10, 14, 23 and 28 to 52 days post inoculation (p.i.). Gamonts were seen 14 days p.i. Schizonts were not identified. The gametogony of *E. leuckarti* resembled gamonts of *E. macusaniensis*. However, the remarkable hypertrophy of host cell nucleus described by Barker and Remmler (1972) was not found in *E. macusaniensis*. Results of Barker and Remmler (1972) were confirmed by Hirayama *et al.* (2002) in the histological study of five horses naturally infected with *E. leuckarti*. Hirayama *et al.* (2002), using immunohistochemical methods, demonstrated that the hypertrophied host cell and the nucleus were enterocytes.

In conclusion, the morphological findings described in the present study should be helpful in the differential diagnosis of coccidiosis in camelids and removing the confusion between microgamonts and developing schizonts. Further studies are needed to describe asexual stages of camelid coccidia.

Acknowledgements. I would like to thank Dr D. M. Webb for sharing the case and permission to publish the results, and for his past collaborations. I am grateful to Camila Cezar, Fernando Antunes and Shiv Kumar Verma for help with illustrations and to Dr Ronald Fayer for advice.

Financial support. This research received no specific grant from any funding agency, commercial or not-for-profit sectors.

References

- Barker IK and Remmler O (1972) The endogenous development of *Eimeria leuckarti* in ponies. *Journal of Parasitology* **58**, 112–122.
- Cafrune MM, *et al.* (2009) Prevalence of *Eimeria macusaniensis* and *Eimeria ivitaensis* in South American camelids of Northwest Argentina. *Veterinary Parasitology* **162**, 338–341.
- Cebra CK, *et al.* (2007) *Eimeria macusaniensis* infection in 15 llamas and 34 alpacas. *Journal of American Veterinary Medical Association* **230**, 94–100.
- Chigerwe M, *et al.* (2007) Atypical coccidiosis in South American camelids. *Journal of Veterinary Diagnostic Investigation* **19**, 122–125.
- de Souza MV, *et al.* (2018) New paleoparasitological investigations from the pre-Inca to Hispanic contact period in northern Chile. *Acta Tropica* **178**, 290–296.
- Díaz P, *et al.* (2016) Prevalence and risk factors associated to *Eimeria* spp. infection in unweaned alpacas (*Vicugna pacos*) from Southern Peru. *Acta Parasitologica* **61**, 74–78.
- Ferguson DJP, *et al.* (2003) The development of the macrogamete and oocyst wall in *Eimeria maxima*: immuno-light and electron microscopy. *International Journal for Parasitology* **33**, 1329–1340.
- Foreyt WJ and Lagerquist J (1992) Experimental infections of *Eimeria alpacae* and *Eimeria punoensis* in llamas (*Lama glama*). *Journal of Parasitology* **78**, 906–909.
- Fugassa MH, *et al.* (2008) Eimeriid oocysts from archaeological samples in Patagonia, Argentina. *Journal of Parasitology* **94**, 1418–1420.
- Guerrero CA (1967) Coccidia (Protozoa: Eimeriidae) of the alpaca *Lama pacos*. *Journal of Protozoology* **14**, 613–616.
- Guerrero CA, *et al.* (1971) *Eimeria macusaniensis* n. sp. (Protozoa: Eimeriidae) of the alpaca *Lama pacos*. *Journal of Protozoology* **18**, 162–163.
- Guerrero DCA, Hernandez DJ and Alva MJ (1967) Coccidiosis en alpacas. *Revista de Medicina Veterinaria* **21**, 59–68.
- Hirayama K, *et al.* (2002) *Eimeria* organisms develop in the epithelial cells of equine small intestine. *Veterinary Pathology* **39**, 505–508.
- Hodgin C, *et al.* (1984) Leptospirosis and coccidial infection in a guanaco. *Journal of American Veterinary Medical Association* **185**, 1442–1444.
- Jarvinen JA (2008) Infection of llamas with stored *Eimeria macusaniensis* oocysts obtained from guanaco and alpaca feces. *Journal of Parasitology* **94**, 969–972.
- Johnson AL, Stewart JE and Perkins GA (2009) Diagnosis and treatment of *Eimeria macusaniensis* in an adult alpaca with signs of colic. *Veterinary Journal* **179**, 465–467.
- Leguía PG and Casas AE (1998) *Eimeria ivitaensis* n. sp. (Protozoa: Eimeriidae) en alpacas (*Lama pacos*). *Revista Peruana de Parasitología* **13**, 59–61.
- Lenghaus C, O'Callaghan MG and Rogers C (2004) Coccidiosis and sudden death in an adult alpaca (*Lama pacos*). *Australian Veterinary Journal* **82**, 711–712.
- Levine ND (1973). *Protozoan Parasites of Domestic Animals and of Man*, 2nd edn., Minneapolis, Minnesota, USA: Burgess Publishing Company, pp. 1–406.
- Levine ND and Ivens V (1970). *The Coccidian Parasites (Protozoa, Sporozoa) of Ruminants*. Urbana: University of Illinois Press. Illinois Biological Monographs no. 44, pp. 1–278.
- Palacios CA, *et al.* (2006) *Eimeria macusaniensis* and *Eimeria ivitaensis* co-infection in fatal cases of diarrhoea in young alpacas (*Lama pacos*) in Peru. *Veterinary Record* **158**, 344–345.
- Palacios EC, *et al.* (2004) Eimeriosis en crías de alpacas: estudio anatómico y histopatológico. *Revista de Investigaciones Veterinarias del Perú* **15**, 174–178.
- Palacios EC, *et al.* (2005) Caracterización anatómico-histopatológica de enteropatías causantes de mortalidad en crías de alpaca. *Revista de Investigaciones Veterinarias del Perú* **16**, 34–40.
- Rawdon T, *et al.* (2006) Clinical findings and risk factors associated with the first report of *Eimeria macusaniensis* in New Zealand alpacas. *Surveillance* **33**, 11–15.
- Rojas M, *et al.* (2016) Outbreak of diarrhea among preweaning alpacas (*Vicugna pacos*) in the southern Peruvian highland. *Journal of Infection in Developing Countries* **10**, 269–274.
- Rosadio RH and Ameghino EF (1994) Coccidial infections in neonatal Peruvian alpacas. *Veterinary Record* **135**, 459–460.
- Rosadio R, *et al.* (2010) *Eimeria macusaniensis* associated lesions in neonate alpacas dying from enterotoxemia. *Veterinary Parasitology* **168**, 116–120.
- Schock A, *et al.* (2007) Coccidiosis in British alpacas (*Vicugna pacos*). *Veterinary Record* **160**, 805–806.
- Schrey CF, *et al.* (1991) Coccidia of the llama, *Lama glama*, in Colorado and Wyoming. *Veterinary Parasitology* **40**, 21–28.
- Whitehead CE and Anderson DE (2006) Neonatal diarrhea in llamas and alpacas. *Small Ruminant Research* **61**, 207–215.
- Yakimoff WL (1934) Two new species of Coccidia: *Eimeria triffitt* n. sp. of the eland (*Orias canna*), and *Eimeria peruviana* n. sp. of the llama (*Lama glama*). *Parasitology* **26**, 510–511.