



## Brief Report

**Cite this article:** Dalby ST, Courtney SE, Sharma M, and Angtuaco MJ (2024) Transcatheter patent ductus arteriosus closure in premature infants requiring high-frequency ventilation. *Cardiology in the Young* **34**: 1166–1168. doi: [10.1017/S1047951124000702](https://doi.org/10.1017/S1047951124000702)

Received: 29 November 2023  
Revised: 15 February 2024  
Accepted: 8 March 2024  
First published online: 11 April 2024


**Keywords:**

patent ductus arteriosus; transcatheter closure; premature infants; high-frequency ventilation; CHD

**Corresponding author:**

Stephen Dalby; Email: [SDalby2@uams.edu](mailto:SDalby2@uams.edu)

# Transcatheter patent ductus arteriosus closure in premature infants requiring high-frequency ventilation

Stephen T. Dalby<sup>1</sup> , Sherry E. Courtney<sup>2</sup>, Megha Sharma<sup>2</sup> and Michael J. Angtuaco<sup>1</sup>

<sup>1</sup>Division of Pediatric Cardiology, Department of Pediatrics, University of Arkansas for Medical Sciences and Arkansas Children's Research Institute, Little Rock, AR, USA and <sup>2</sup>Division of Neonatology, Department of Pediatrics, University of Arkansas for Medical Sciences and Arkansas Children's Research Institute, Little Rock, AR, USA

**Abstract**

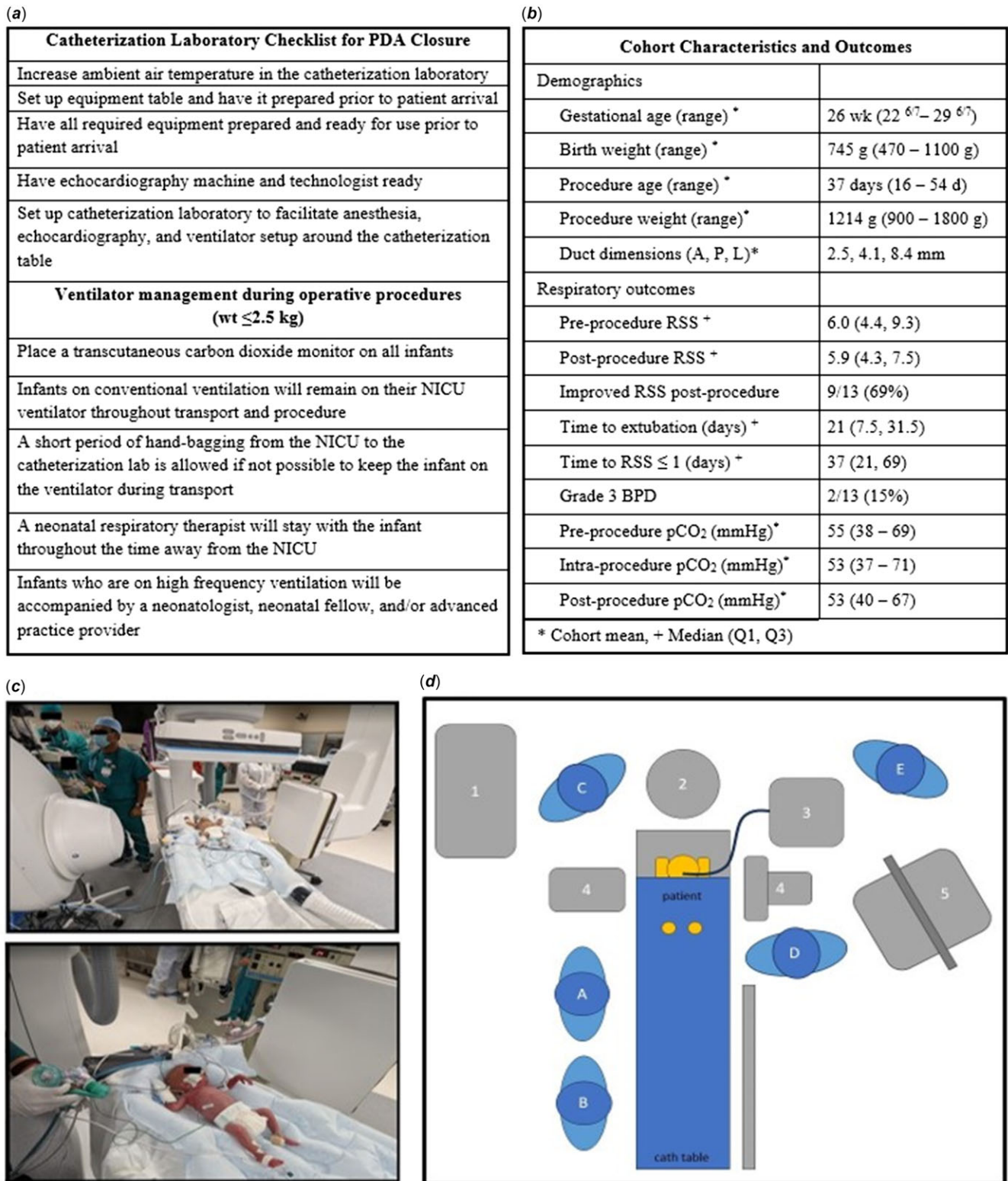
Transcatheter closure has become a common treatment method for patent ductus arteriosus in premature infants at many centres; however, many remain uncertain about the ability to perform the procedure in the catheterisation laboratory for infants requiring high-frequency ventilation. This study presents our centre's experience following the implementation of neonatal ventilatory guidelines, which resulted in 100% procedural success without any procedural or respiratory adverse events.

The ductus arteriosus is a vascular connection between the pulmonary artery and the aorta that is essential to fetal circulation and remains patent in up to 50% of premature infants. Persistent patency is associated with increased morbidity and mortality in this population.<sup>1,2</sup>

Ideal patent ductus arteriosus management remains controversial. Options include conservative management, pharmacotherapy, surgical ligation, and transcatheter closure. Anecdotally, some centres have reservations about offering transcatheter closure for infants requiring high-frequency ventilation due to perceived inability to manage the ventilator away from the neonatal ICU. Some prematurely transition infants from high-frequency ventilation to conventional mechanical ventilation, while others delay the procedure until the infant can wean to conventional mechanical ventilation. While this was initially our centre's practice, we implemented guidelines to allow infants to continue high-frequency ventilation while undergoing cardiac catheterisation (Fig 1a). This study presents our early clinical, real-world experience with transcatheter patent ductus arteriosus closure following implementation of these guidelines.

Thirteen neonates underwent transcatheter patent ductus arteriosus closure while receiving HFV with demographic, procedural, and outcome data recorded (Fig 1b) with approval of the Institutional Review Board at the University of Arkansas for Medical Sciences. Demographic data included gestational age and birth weight, as well as age and weight at time of catheterisation. Respiratory outcomes were observed, using the respiratory severity score, a measure of respiratory disease severity calculated as the product of the mean airway pressure and fraction of inhaled oxygen.<sup>3</sup> Respiratory outcomes included change in respiratory severity score immediately post-procedure, time to return to pre-procedure respiratory severity score time to respiratory severity score  $\leq 1$ , eventual diagnosis of grade 3 bronchopulmonary dysplasia, and change partial pressure of carbon dioxide by venous blood gas. Procedural outcomes included successful implantation of patent ductus arteriosus device, presence of residual ductal shunt, aortic arch or left pulmonary artery obstruction, device embolisation, and hypothermia upon return to the neonatal ICU. The most used devices were the 5-4 and 4-2 Piccolo, accounting for 85% of cases. All patients had successful placement of an Amplatzer Piccolo Occluder with single femoral venous access using fluoroscopic and transthoracic echocardiography guidance. Procedural steps, including vascular access, catheter, and wire manipulation, device deployment and release need not be altered to accommodate HFV.

The mean age and weight at time of the procedure were 37 days and 1214 g, respectively. Nine (69%) patients had an absolute improvement in respiratory severity score immediately post-procedure; however, the data did not allow for the determination of statistical significance. Twelve patients (92%) were able to extubate with median time to extubation of 21 days and a median time to achieve RSS  $\leq 1$  of 37 days. Two patients were eventually diagnosed with grade 3 bronchopulmonary dysplasia. Venous partial pressure of carbon dioxide measurements immediately before, during, and after the procedure were nearly identical. All cases were successful without any instances of adverse procedural outcomes, including residual ductal shunt, aortic arch or left pulmonary artery obstruction, device embolisation, or hypothermia.



**Figure 1.** (a) Catheterisation checklist and ventilator guidelines, (b) Cohort characteristics and outcomes (A = ampulla, P = pulmonary end, L = length); (c) Example of patient/ equipment positioning in the catheterisation laboratory; (d) sketch of catheterisation laboratory layout (1. Anaesthesiology cart, 2. Footprint of AP fluoroscopic C-arm, 3. Oscillatory ventilator, 4. Lateral fluoroscopic detector, 5. Echocardiography machine; A-B. Catheterisation personnel, C. Anaesthesiologist, D. Echocardiographer, E. Neonatologist).

Using our newly implemented ventilatory guidelines, our centre was able to perform transcatheter patent ductus arteriosus closure safely and successfully for 13 premature infants while on HFV without any respiratory or procedural adverse events. This was

accomplished utilising a multidisciplinary approach, including stakeholders from neonatology, cardiology, cardiac catheterisation team, anaesthesiology, and respiratory therapy. Key drivers for success included having providers familiar and comfortable with

these ventilators immediately available throughout transport and the procedure, as well as having a means of continuous ventilatory monitoring using a transcutaneous carbon dioxide monitor. The laboratory layout was rearranged such that the biplane fluoroscopy equipment could be in position while still allowing anaesthesiologists and neonatologists easy access to the ventilator and patient, and an echocardiographer access to the patient for intraprocedural imaging (Fig 1c and d).

This study lacks the power to make definitive conclusions regarding optimal patent ductus arteriosus management or respiratory outcomes; however, it can serve as a roadmap for other centres struggling to find a way to perform this procedure safely and effectively in the catheterisation laboratory when infants require high-frequency ventilation. Our approach and experience seek to inform clinicians that ventilation strategy need not be altered from high-frequency ventilation to conventional mechanical ventilation solely for an intervention. Further experience with this practice should reduce the chances of delaying or refusing patent ductus arteriosus closure in infants on high-frequency ventilation. Larger, prospective studies will need to be performed to help determine whether this procedure truly improves respiratory outcomes.

**Financial support.** One of the authors was supported by the Translational Research Institute, grant KL2 TR003108 through the National Center for Advancing Translational Sciences of the National Institutes of Health (NIH) and the Marion B Lyon New Scientist Development Award (Arkansas Children's Research Institute). The content is solely the responsibility of the authors and does not necessarily represent the official views of the NIH.

**Competing interests.** None.

## References

1. Gentle SJ, Travers CP, Clark M, Carlo WA, Ambalavanan N. Patent ductus arteriosus and development of bronchopulmonary dysplasia-associated pulmonary hypertension. *Am J Respir Crit Care Med* 2023; 207: 921–928.
2. Noori S, McCoy M, Friedlich P, et al. Failure of ductus arteriosus closure is associated with increased mortality in preterm infants. *Pediatrics* 2009; 123: e138–e144.
3. Sathanandam S, Gutfinger D, O'Brien L, et al. Amplatzer piccolo occluder clinical trial for percutaneous closure of the patent ductus arteriosus in patients >700 grams. *Catheter Cardiovasc Interv* 2020; 96: 1266–1276.