

The contribution of brain imaging to the understanding of psychopathy

Jesús Pujol¹, Ben J. Harrison², Oren Contreras-Rodríguez³ and Narcis Cardoner⁴

Review Article

Cite this article: Pujol J, Harrison BJ, Contreras-Rodríguez O, Cardoner N (2018). The contribution of brain imaging to the understanding of psychopathy. *Psychological Medicine* **49**, 20–31. <https://doi.org/10.1017/S0033291718002507>

Received: 15 January 2018
Revised: 20 June 2018
Accepted: 14 August 2018
First published online: 12 September 2018

Key words:

Antisocial behavior; brain; emotional dysfunction; functional connectivity; moral dilemmas; MRI

Author for correspondence:

Jesús Pujol, E-mail: 21404jpn@comb.cat

¹MRI Research Unit, Department of Radiology, Hospital del Mar, CIBERSAM G21, Barcelona, Spain; ²Department of Psychiatry, Melbourne Neuropsychiatry Centre, The University of Melbourne and Melbourne Health, Melbourne, Australia; ³Psychiatry Department, Bellvitge University Hospital, Bellvitge Biomedical Research Institute-IDIBELL, CIBERSAM G17, Barcelona, Spain and ⁴Department of Mental Health, Corporació Sanitària Parc Taulí, Sabadell, and Department of Psychiatry, Autonomous University of Barcelona, Barcelona, Spain

Abstract

Psychopathy is a personality type characterized by both callous emotional dysfunction and deviant behavior that affects society in the form of actions that harm others. Historically, researchers have been concerned with seeking data and arguments to support a neurobiological foundation of psychopathy. In the past few years, increasing research has begun to reveal brain alterations putatively underlying the enigmatic psychopathic personality. In this review, we describe the brain anatomical and functional features that characterize psychopathy from a synthesis of available neuroimaging research and discuss how such brain anomalies may account for psychopathic behavior. The results are consistent in showing anatomical alterations involving primarily a ventral system connecting the anterior temporal lobe to anterior and ventral frontal areas, and a dorsal system connecting the medial frontal lobe to the posterior cingulate cortex/precuneus complex and, in turn, to medial structures of the temporal lobe. Functional imaging data indicate that relevant emotional flow breakdown may occur in both these brain systems and suggest specific mechanisms via which emotion is anomalously integrated into cognition in psychopathic individuals during moral challenge. Directions for future research are delineated emphasizing, for instance, the relevance of further establishing the contribution of early life stress to a learned blockage of emotional self-exposure, and the potential role of androgenic hormones in the development of cortical anomalies.

Introduction

Psychopathy refers to a personality type expressed in the form of emotional callousness, lack of empathy, a grandiose estimation of self, impulsivity, and persistent antisocial behavior, among other traits (Hare, 2003). This profile notably overlaps with features defining the antisocial personality disorder (American Psychiatric Association, 2013). However, such terms are not synonymous. To meet criteria for psychopathy, an individual must exhibit emotional dysfunction (Blair, 2012). Emotional features such as callousness, lack of empathy and inflated self-appraisal are not necessary to operatively define antisocial personality disorder in the main Diagnostic and Statistical Manual of Mental Disorders (DSM)-V section, which predominantly considers antisocial deviance. However, the alternative trait-based definition section of the DSM-V includes an antisocial personality disorder variant characterized by low anxiety and a bold interpersonal style, which is closer to the traditional view of psychopathy (American Psychiatric Association, 2013; Venables *et al.*, 2014). Analogously, the presence of callous-unemotional traits may be used to define a ‘psychopathic’ variant of conduct disorders in children (Patrick, 2014). A historical account of the use of these and related terms (e.g. sociopathy and dissocial disorder) can be found in Kiehl and Hoffman (2011).

The most widely used and validated instrument for the assessment of psychopathy is the interview-based Psychopathy Checklist-Revised (PCL-R; Hare, 2003), which contains distinct affective–interpersonal and impulsive–antisocial factors. Various self-report instruments also exist for assessing psychopathy, as well as instruments adapted for children and adolescents (Patrick, 2014). Some inventories are inspired by the PCL-R, while others represent new developments, for instance, the Psychopathic Personality Inventory (Lilienfeld and Andrews, 1996) and the Triarchic Psychopathy Measure (Patrick *et al.*, 2009).

Current brain imaging tools offer a unique window to explore the structural and functional bases of normal and deviant behavior. Historically, researchers have been concerned with seeking arguments to support a neurobiological foundation of psychopathy, as one of the most enigmatic personality disorders. In the last few years, increasingly abundant data have been provided. Nevertheless, further effort is necessary to integrate the new information. In this review, we describe the anatomical and functional features that characterize the brain of psychopathic individuals from a synthesis of neuroimaging research and discuss how such brain

anomalies may account for psychopathic behavior. The available neuroimaging literature on psychopathy, defined in accordance with Hare's concept (Hare, 2003), is analyzed and the review is complemented by a secondary consideration of selected neuroimaging studies assessing young people showing antisocial behavior and callous emotional dysfunction.

Brain anatomy

Global brain assessment

The brain of primary psychopathic individuals (as opposed to patients with psychopathic-like behavior secondary to focal brain damage) does not show any gross anatomical anomalies upon visual inspection. The whole brain volume is similar to the general population in most studies that have provided the measurement (Dolan *et al.*, 2002; Yang *et al.*, 2005a, 2005b; Narayan *et al.*, 2007; Tiihonen *et al.*, 2008; Contreras *et al.*, 2015). Significant brain volume reductions have only rarely been reported (Barkataki *et al.*, 2006). When volumes have been measured for specific lobes using conventional anatomical limits, significant volume reduction was solely observed in the temporal lobe and only a minimal effect was appreciated in the prefrontal lobe (Dolan *et al.*, 2002).

Within the samples of high socioeconomic risk, an association has been reported between the persistence of the cavum septum pellucidum – a fluid-filled space between the two leaflets of the septum – and higher scores of psychopathy (Raine *et al.*, 2010). However, the cavum is similarly prevalent in disruptive behavior disorders in the absence of psychopathy (Raine *et al.*, 2010; Toivonen *et al.*, 2013; White *et al.*, 2013), suggesting that it is mainly a non-specific neuroradiological finding (Saba *et al.*, 2013).

Changes in the content of gray matter

A large number of studies have focused on measuring the regional content of gray matter. These studies were based on trace delineation of gray/white matter boundaries, voxel-based morphometry and automated measurements of cortical thickness. To a large extent, there is general agreement regarding psychopaths' showing regional cortical reductions in relative gray matter content.

Earlier imaging studies predicted gray matter reductions in the prefrontal lobe of psychopaths (Raine *et al.*, 2000; Yang *et al.*, 2005a, 2005b). Subsequent research has both largely confirmed such a prediction and demonstrated that tissue alteration extends to other brain locations (Laakso *et al.*, 2001, 2002; Narayan *et al.*, 2007; de Oliveira-Souza *et al.*, 2008; Müller *et al.*, 2008; Tiihonen *et al.*, 2008; Yang *et al.*, 2009a, 2009b, 2010; Boccardi *et al.*, 2011, 2013; Raine *et al.*, 2011; Sato *et al.*, 2011; Ermer *et al.*, 2012; Gregory *et al.*, 2012; Ly *et al.*, 2012; Bertsch *et al.*, 2013; Kolla *et al.*, 2014; Kumari *et al.*, 2014; Contreras-Rodríguez *et al.*, 2015; Walters *et al.*, 2015; Jiang *et al.*, 2016), as summarized in Table 1. Although the number of reported brain areas indicates a tendency for changes to affect the cortex globally, gray matter volume reduction is particularly consistent across studies in (i) the rostral temporal lobe and the rostral and ventral frontal lobe including the ventral-medial and orbitofrontal cortex; (ii) the dorsal aspect of the brain medial wall involving a dorsal/medial frontal area extending to the anterior cingulate cortex and the posterior cingulate cortex/precuneus; (iii) the posterior parahippocampal gyri/medial visual cortex; and (iv) the sensorimotor

Table 1. Gray matter reduction in psychopathy

Dorsal/lateral frontal cortex (7, 8, 16, 17, 18, 19, 21, 23, 25, 26, 27, 28, 33)
Medial frontal cortex (6, 7, 8, 16, 18, 22, 23, 25, 26, 27, 28, 33)
Orbitofrontal cortex (6, 7, 16, 17, 19, 21, 22, 23, 27, 28, 32, 33)
Temporal pole/anterior temporal cortex (17, 18, 19, 21, 25, 26, 27, 30, 32)
Hippocampus (8, 15, 27, 32)
Amygdala (8*, 20, 21, 27*, 32)
Lateral temporal cortex (8, 17, 24, 26, 33)
Anterior cingulate cortex (8, 18, 22, 26, 31, 33)
Posterior cingulate cortex-precuneus (8, 19, 21, 22, 24, 27, 28, 33)
Visual cortex (7, 19, 21, 22, 24, 26, 28)
Parahippocampal/fusiform gyri (8, 19, 21, 22, 26, 27, 28, 32)
Somatosensory cortex (6, 7, 22, 25, 26, 28)
Parietal cortex (7, 28)
Insula (8, 17, 25, 26)
Cerebellum (28, 30)
Nucleus accumbens (29)

Significant gray matter volume reduction across reported studies distributed in gross brain parcellations. Literature references between parentheses. *marginally involved.

6: Narayan *et al.*, 2007; 7: Tiihonen *et al.*, 2008; 8: Contreras-Rodríguez *et al.*, 2015; 15: Laakso *et al.*, 2001; 16: Laakso *et al.*, 2002; 17: de Oliveira-Souza *et al.*, 2008; 18: Müller *et al.*, 2008; 19: Yang *et al.*, 2009a; 20: Yang *et al.*, 2009b; 21: Yang *et al.*, 2010; 22: Boccardi *et al.*, 2011; 23: Raine *et al.*, 2011; 24: Sato *et al.*, 2011; 25: Gregory *et al.*, 2012; 26: Ly *et al.*, 2012; 27: Ermer *et al.*, 2012; 28: Bertsch *et al.*, 2013; 29: Boccardi *et al.*, 2013; 30: Kolla *et al.*, 2014; 31: Kumari *et al.*, 2014; 32: Walters *et al.*, 2015; 33: Jiang *et al.*, 2016.

cortex. Figure 1 provides an overall depiction of this consistent pattern of gray matter volume reduction in psychopaths.

The set of cortical regions shown in Fig. 1 represents a combination of neocortical and paralimbic areas. Although the involvement of other (limbic) elements has frequently been emphasized in psychopathy, only a few studies have actually detected significant volume reduction in structures such as the amygdala, hippocampus, and insula, as indicated in Table 1. Moreover, some analyses specifically targeting the individual limbic structures using manual tracing failed to find the predicted volume reduction in the amygdala (Barkataki *et al.*, 2006; Boccardi *et al.*, 2011), hippocampus (Raine *et al.*, 2004; Barkataki *et al.*, 2006; Boccardi *et al.*, 2010), and anterior cingulate cortex (Glenn *et al.*, 2010a). However, the limbic/paralimbic system as a whole (integrated using latent-variable modeling) does appear to be a major contributor to psychopathy (Baskin-Sommers *et al.*, 2016).

A number of meta-analyses have been conducted in attempt to summarize common findings across studies of regional brain volumes. However, it is relevant to note that none have focused specifically on psychopathy. Existing meta-analyses have instead broadly pooled finding from studies of antisocial behavior (Yang and Raine, 2009; Aoki *et al.*, 2014), interpersonal violence (Lamsma *et al.*, 2017), oppositional defiant disorder (Noordermeer *et al.*, 2016), and conduct problems (Rogers and De Brito, 2016). Although these analyses have mapped regional volume reductions consistent with the emphasis of our review (Fig. 1), the frequency and extent of such alterations has notably been more discrete. It has been argued that the phenomenological and etiological heterogeneity of antisocial behavior, in particular, as well as methodological differences between studies, may explain the limited results of current meta-analytic studies (Lamsma *et al.*, 2017).

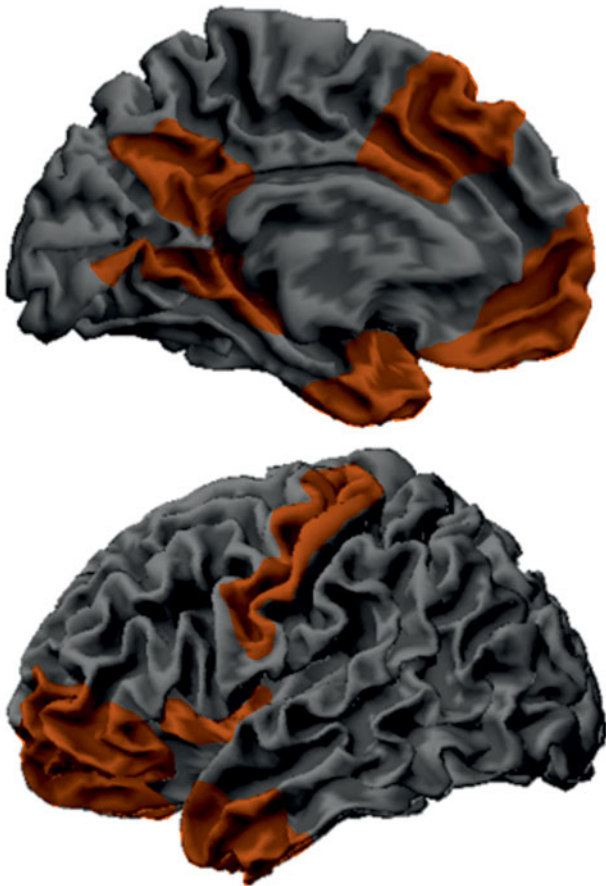


Fig. 1. Schematic representation of brain regions showing the most consistent gray matter volume reduction in primary psychopathy according to the literature.

In children and adolescents with psychopathic traits, research has demonstrated gray matter changes distributed in regions notably reminiscent of adult psychopathic patterns (De Brito *et al.*, 2009; Ermer *et al.*, 2013; Fairchild *et al.*, 2013; Cope *et al.*, 2014a, 2014b). However, such studies have produced mixed findings as to the direction of the alteration. Interestingly, young individuals (mean age of 12 years) show a gray matter volume increase (De Brito *et al.*, 2009) associated with psychopathic traits, whereas in older individuals (mean age of 17 years), psychopathic traits are instead associated with a gray matter volume decrease in both males (Ermer *et al.*, 2013) and females (Cope *et al.*, 2014a, 2014b). One study in female adolescents showed a mixed brain pattern of positive and negative correlations (Fairchild *et al.*, 2013). Taking both young and adult studies together, alterations in gray matter volume in psychopathy may be hypothesized to evolve dynamically throughout life from a relative gray matter increase to a relative decrease.

In support of a developmental dynamic basis of brain tissue alterations in psychopathy, one study reported a significant association of childhood physical abuse with gray matter volume reduction in the temporal pole of adult psychopaths (Kolla *et al.*, 2014). Child abuse was also associated with reduced fronto-temporal cortical thickness predicting antisocial behavior in adolescents (Busso *et al.*, 2017). In another study, the combination of relatively lower cortical volumes and higher volumes in subcortical regions was found to partially mediate the relation between adverse life events and antisocial behavior in a sample of 1741 adolescents (Mackey *et al.*, 2017). At the age of 25 years, a voxel-

based morphometry analysis demonstrated the association of early life poverty with gray matter volume reduction precisely in the ventral-medial frontal cortex (Holz *et al.*, 2015). Symptoms related to early onset cumulative adversity have similarly been associated with reduced gray matter volumes in persistent delinquent youths (Raine *et al.*, 2003).

Changes in the content of white matter

Despite consistency across studies, the extent to which reductions of gray matter volumes in adult psychopaths described above express true gray matter loss (i.e. atrophy) is not obvious. Indeed, results from white matter analyses suggest that white matter increases may contribute to relative reductions of gray matter measurements in the absence of relevant brain volume changes.

When results have been provided, white matter volume changes have generally paralleled the findings of gray matter changes in the opposite direction, with volume increases in global, prefrontal, and corpus callosum white matter correlating with psychopathy scores (Raine *et al.*, 2003; Yang *et al.*, 2005a, 2005b). Larger volumes have also been demonstrated for basal ganglia elements with a very high content of white matter (Barkataki *et al.*, 2006; Glenn *et al.*, 2010b; Pujara *et al.*, 2014).

A similar tendency has also been observed in disorders overlapping with psychopathy. In persistently violent offenders with antisocial personality disorder significantly larger white matter volumes were observed in broadly distributed brain regions grossly coinciding with areas of gray matter volume reduction (Tiihonen *et al.*, 2008). In young males with psychopathic traits, a mixed pattern of changes has been reported combining both increases and decreases in regional white matter volume (De Brito *et al.*, 2011).

It has been argued that the relative increase of white matter in psychopaths may be related to non-optimal brain remodeling (deficient axonal pruning), resulting in excessive anatomical connections (Raine *et al.*, 2003). However, alternatively, we suggest here that larger white matter volumes in psychopathy may also relate to significantly accelerated myelination. It is important to note that white matter segments in conventional (*T1*-weighted) anatomical magnetic resonance imaging (MRI) scans correspond to myelinated white matter (Paus *et al.*, 2001). Myelination is an active process throughout life (Yakovlev and LeCours, 1967; Pujol *et al.*, 1993; Narayan *et al.*, 2007), which is physiologically accelerated in early postnatal years and during adolescence (Paus *et al.*, 2001; Pujol *et al.*, 2006), and enhanced by repetitive use or skill learning (McKenzie *et al.*, 2014; Pujol *et al.*, 2016a). Pathological acceleration of myelination has been suggested, for example, in melancholic depression (Soriano-Mas *et al.*, 2011), childhood obesity (Ou *et al.*, 2015), heavy cannabis use (Matochik *et al.*, 2005), and pathological lying (Yang *et al.*, 2005a, 2005b).

To summarize, measurable changes in gray and white matter regional tissue content can be detected in the brain of psychopaths in the absence of changes of total brain volume. This overall pattern of findings argues against gray matter atrophy as a sole explanation for gray matter volume reductions in psychopaths. We propose that accelerated myelination may be one contributing factor, in that it affects image tissue segmentation by displacing the boundary between white and gray matter.

Changes in the structure of white matter pathways

Potential alterations in the structure of white matter pathways have been investigated using diffusion tensor imaging (DTI).

The common measurement across all studies is fractional anisotropy (FA), which quantifies the degree of structural maturation of white matter by estimating water diffusivity along tracts (Lebel *et al.*, 2012). DTI studies of psychopathic populations coincide in showing FA reductions mostly involving frontal lobe connections (Craig *et al.*, 2009; Motzkin *et al.*, 2011; Sundram *et al.*, 2012; Hoppenbrouwers *et al.*, 2013; Sethi *et al.*, 2015; Wolf *et al.*, 2015; Jiang *et al.*, 2017b).

Alterations in the ventral connections between the frontal lobe and the temporal lobe would appear to be a solid finding, which mostly implicate the uncinate fasciculus (Craig *et al.*, 2009; Motzkin *et al.*, 2011; Sundram *et al.*, 2012; Hoppenbrouwers *et al.*, 2013; Wolf *et al.*, 2015; Jiang *et al.*, 2017b). Significant FA reductions have also been identified in dorsal pathways connecting the frontal lobe with the parietal lobe (Sundram *et al.*, 2012; Sethi *et al.*, 2015; Jiang *et al.*, 2017b). Interestingly, the cingulum is altered both ventrally and dorsally, with FA reductions detected in the segment connecting the posterior cingulate cortex with the medial temporal lobe and the segment connecting the posterior cingulate cortex with the frontal lobe (Sethi *et al.*, 2015). Frontal lobe structural connectivity alterations in psychopaths therefore seem to implicate dorsal and ventral bundles that connect brain areas that broadly demonstrate gray matter volume reductions (summarized in Fig. 1). However, frontal lobe connectivity changes are not limited to the anterior–posterior direction, as reduced FA has also been demonstrated in the genu of corpus callosum (transverse connections) (Sundram *et al.*, 2012) and in frontal-basal ganglia connections (Sundram *et al.*, 2012; Hoppenbrouwers *et al.*, 2013).

Reductions in FA can be interpreted as expressing a maturation delay in late maturing bundles (Sethi *et al.*, 2015). Nevertheless, accelerated, as opposed to delayed, maturation may better account for the majority of pathway alterations in psychopaths. Indeed, the increase in FA from normal childhood to adulthood reaches a peak between 20 and 40 years of age, and subsequently decreases (Lebel *et al.*, 2012). Accordingly, from early adulthood, the normal physiological evolution of FA is one of the progressive reductions, presumably reflecting increased white matter structural complexity accompanying brain maturation (Douaud *et al.*, 2011; Jones *et al.*, 2013). In DTI studies of psychopathy, the mean age of adult samples has broadly coincided with the FA peak, or with the beginning of FA decreases (age range across studies, 30–40 years), with the sole exception of one study (Jiang *et al.*, 2017b). Thus, within this age range, reduced FA is better explained by accelerated maturation, or psychopaths reaching FA maturity earlier than what is normally observed. Interestingly, in the DTI study featuring the youngest population (mean age 23 years), a combination of FA decreases (predominant) and increases was reported (Jiang *et al.*, 2017b).

DTI analyses in younger populations with callous-unemotional traits have provided mixed results, with different studies reporting higher, lower or no differences in FA *v.* healthy controls for diverse white-matter tracts (see Waller *et al.* (2017) for a review). These findings offer further support for the proposal that abnormally accelerated white matter maturation contributes to the nature of anatomical changes in psychopathy and callousness. FA increase will be identified in youths, compared with typically developing controls, at ages prior to the FA age-related peak (the ascending part of the curve) for a given bundle, and FA reduction in older individuals closer to the age at which FA begins to decrease (Waller *et al.*, 2017). Here too, early life stress could play a significant role. In one study, adults with life-time exposure to parental abuse showed FA reduction in

the hippocampal extension of the cingulum bundle, the fornix, and the arcuate fasciculus (Choi *et al.*, 2009).

Brain function

Functional connectivity

Functional connectivity is considered a measurement of activity synchrony between brain regions sharing functional properties (Biswal *et al.*, 1995). In antisocial offenders, the assessment of functional connectivity changes using whole-brain measures has provided evidence of both reduced functional integration and segregation in the organization of large-scale brain networks (Jiang *et al.*, 2017a). In global terms, such findings may be interpreted as reflecting deficient brain functional maturation (Fair *et al.*, 2009; Pujol *et al.*, 2016b). The integration and segregation of large-scale brain networks is a life-time process that is especially active during adolescence (Sherman *et al.*, 2014). Thus, the hypothetical acceleration of white matter maturation does not seem to imply a more efficient coupling among late maturing networks in the case of psychopaths (i.e. maturation may be faster but deficient).

As in the case of other imaging alterations, global brain changes in functional connectivity have been observed in association with changes that are particularly prominent in specific brain systems. Once again, the frontal cortex is the structure that shows the most relevant connectivity alterations in psychopaths. Some evidence indicates reduced functional connectivity between ventral frontal areas and the anterior temporal lobe and amygdala at rest (Motzkin *et al.*, 2011) and during emotional stimulation (Decety *et al.*, 2013a; Yoder *et al.*, 2015; Volman *et al.*, 2016). Other studies have demonstrated reduced functional connectivity of the dorsal frontal cortex (and anterior cingulate cortex) with several limbic–paralimbic structures (Ly *et al.*, 2012; Pujol *et al.*, 2012; Contreras *et al.*, 2015; Philippi *et al.*, 2015) and, particularly, with the posterior cingulate cortex/precuneus complex (Pujol *et al.*, 2012; Contreras *et al.*, 2015; Philippi *et al.*, 2015).

In addition to long-distance connectivity reduction, psychopaths appear to display higher functional connectivity within the dorsal aspect of the frontal lobes at rest (Contreras *et al.*, 2015), and between dorsal frontal areas and the striatum during reward expectancy (Geurts *et al.*, 2016). Higher frontal cortex connectivity was associated with more severe lifestyle/antisocial traits (Hare factor 2) in the study carried out by Philippi *et al.* (2015). In general agreement with such functional connectivity findings, studies of structural connectivity (structural covariance) estimated from cortical thickness measurements, also implicates the superior frontal cortex as a relevant connectivity hub in psychopaths (Yang *et al.*, 2012). Reduced functional connectivity also seems to combine with increased connectivity in antisocial personality disorder (Tang *et al.*, 2016).

Brain activation

Brain response to emotional stimuli

A number of studies have examined how psychopaths respond to emotionally provocative stimuli, including emotional faces (Deeley *et al.*, 2006; Decety *et al.*, 2013b, 2014; Contreras *et al.*, 2014; Hyde *et al.*, 2014; Mier *et al.*, 2014; Pera-Guardiola *et al.*, 2016; Volman *et al.*, 2016), unpleasant pictures (Müller *et al.*, 2003; Decety *et al.*, 2013b; Harenski *et al.*, 2014; Sitaram *et al.*, 2014),

emotion-laden scenes (Decety *et al.*, 2013b, 2015; Meffert *et al.*, 2013), and emotional words (Contreras *et al.*, 2014). Collectively, these studies indicate that the neural processing of emotional stimuli is altered in psychopaths. However, depending on the nature of the experiment, studies have reported either attenuated (Deeley *et al.*, 2006; Harenski *et al.*, 2014; Hyde *et al.*, 2014; Mier *et al.*, 2014; Volman *et al.*, 2016) or enhanced (Intrator *et al.*, 1997; Contreras *et al.*, 2014) or indeed a combination of response changes (Decety *et al.*, 2013a, 2013b, 2014, 2015) in different elements of the 'emotion processing' network. Relevantly, enhanced brain response has been reported for visual sensory areas (Contreras *et al.*, 2014), association sensory cortex (Decety *et al.*, 2013b; Contreras *et al.*, 2014), insula (Decety *et al.*, 2013b, 2014), anterior cingulate cortex (Decety *et al.*, 2013b), basal ganglia (Decety *et al.*, 2013a, 2013b), and frontal (predominantly dorsal) areas (Contreras *et al.*, 2014; Decety *et al.*, 2013b). Thus, the psychopath's brain is not necessarily 'unemotional' in terms of its response to emotional stimulation, which may be enhanced at some processing stages. Nevertheless, a disruption of the emotional flow occurs, perhaps in the transition of processing from temporal lobe structures to the ventral prefrontal cortex. Indeed, the amygdala (Decety *et al.*, 2013a, 2014; Contreras *et al.*, 2014; Harenski *et al.*, 2014; Hyde *et al.*, 2014; Mier *et al.*, 2014) and the ventral prefrontal cortex (Decety *et al.*, 2013b, 2014) both show only a modest or attenuated response to emotional stimuli in psychopaths, and the normal functional coupling between both elements appear to be reduced during task performance (Decety *et al.*, 2013a; Contreras *et al.*, 2014; Volman *et al.*, 2016).

Brain response to aversively conditioned stimuli (e.g. with pain) has also been tested in psychopaths. Once again, the results have been divergent, with evidence for both attenuated (Veit *et al.*, 2002; Larson *et al.*, 2013; Decety *et al.*, 2014) and enhanced (Schneider *et al.*, 2000; Schultz *et al.*, 2016) brain activations, which further suggests that the experimental context is critical in determining the magnitude and direction of the response. Attention seems to be a relevant factor that may explain some apparent discrepancies. For example, compared with control subjects, psychopaths showed lower right amygdala and higher left frontal response to a short (200 ms) exposure to a pain-conditioned stimulus when attention was engaged in a neutral task (Larson *et al.*, 2013). By contrast, long exposure (8 s) to a pain-conditioned complex image generated a greater response, in this case in the *left* amygdala and in areas processing visual stimuli features (Schultz *et al.*, 2016).

There is also evidence relating psychopathy to altered responses to incentive stimulation. Specifically, psychopathy has been associated with lower basal ganglia activation related to monetary loss (Pujara *et al.*, 2014), lower medial frontal activation during reward anticipation (Veroude *et al.*, 2016), and lower anterior cingulate cortex activation in response to reward uncertainty (Prehn *et al.*, 2013), while increased activation has been observed in the posterior cingulate cortex and anterior insula during the task reversal phase (Gregory *et al.*, 2015). Also, higher psychopathy scores have been associated with reduced response to drug abuse-related pictures in the basal ganglia and connected brain structures (Cope *et al.*, 2014a, 2014b).

Brain activity during moral challenge

Neuroimaging research has demonstrated the involvement of a well-defined brain network in the mediation of moral judgment in the normal population. This network overlaps with the so-called default mode network connecting the medial frontal cortex, the posterior cingulate cortex, and the angular gyri

(Greene *et al.*, 2001), but also medial structures of the temporal lobe and upper brainstem (Harrison *et al.*, 2008; Pujol *et al.*, 2012). In functional MRI studies, psychopaths required to make a judgment in a moral dilemma situation (Fig. 2) have consistently shown deficient activation in the medial frontal and posterior cingulate cortex (Glenn *et al.*, 2009; Harenski *et al.*, 2010; Veit *et al.*, 2010; Pujol *et al.*, 2012; Yoder *et al.*, 2015) and, remarkably, in the hippocampus and parahippocampal gyrus extending to the periaqueductal gray (Pujol *et al.*, 2012) and amygdala (Glenn *et al.*, 2009; Pujol *et al.*, 2012; Marsh and Cardinale, 2014; Yoder *et al.*, 2015). Such experiments may therefore show the inappropriate use of a network that both mediates attention to self as an agent and has access to autobiographical storage (Moll *et al.*, 2007; Bado *et al.*, 2014; Leech and Sharp, 2014). Consistent with this view, criminal psychopaths precisely showed lower activity in the posterior (and anterior) cingulate cortex, parahippocampal gyrus, hippocampus, and amygdala during the performance of an affective memory task (Kiehl *et al.*, 2001).

A functional 'breakdown' in the brain network subserving moral judgment may also extend to neutral situations unrelated to the moral context. Functional MRI signal reduction or deactivation typically observed in the default mode network during conventional cognitive tasks is deficient in psychopaths (Pujol *et al.*, 2012; Juárez *et al.*, 2013; Freeman *et al.*, 2015). Moreover, the anterior and posterior elements of the default mode network appeared to be significantly uncoupled during the resting state in functional connectivity analyses (Pujol *et al.*, 2012). Therefore, the network abnormally responding during moral challenge would also seem to be primarily altered. This idea is consistent with the proposal that attentional deficits in psychopaths are not limited to situations of moral conflict, but extend more generally to other attentional domains (Newman *et al.*, 2010; Aharoni *et al.*, 2013; Newman and Baskin-Sommers, 2016; Rodman *et al.*, 2016).

The arousal generated by a moral challenge in psychopaths appears to depend on how the self is taken as a reference. While watching morally laden scenes, psychopaths showed higher frontal activation when identifying the emotional state of the victim and lower frontal activation when identifying the emotional state of the predator (Decety *et al.*, 2015). However, other data suggest that if the psychopath is forced to feel like the predator – as opposed to simply having to identify the predator's emotional state – such a response attenuation may be less evident (Sommer *et al.*, 2010; Decety *et al.*, 2013a, 2013b; Meffert *et al.*, 2013), further suggesting an attentional selection bias (Newman *et al.*, 2010; Newman and Baskin-Sommers, 2016).

In brief, while psychopaths are reactive to different forms of emotional stimulation, emotional processing may be incomplete with poor temporal lobe transmission of emotional flow to the ventral frontal system. Also, moral challenge experiments have revealed the inappropriate use of a dorsal network mediating attention to our inner emotional world.

In addition to functional imaging of evoked brain activation, other studies have assessed brain function based on a variety of metabolic parameters. Regional glucose metabolism and cerebral blood flow have generally been reported to be lower in psychopaths, particularly in frontal and temporal areas (Volkow *et al.*, 1995; Raine *et al.*, 1997; Soderstrom *et al.*, 2002). One study reported lower levels of monoamine oxidase-A, an enzyme that regulates neurotransmitters, in the orbitofrontal cortex and ventral striatum in offenders with high-psychopathic traits (Kolla *et al.*, 2015). Other authors have reported a positive correlation



On board is an injured man that will probably not survive. If you throw this man overboard he will certainly die, but the boat will stay afloat and the others may survive. If you do not do so, the boat will probably sink and all of them will die.

Would you throw the injured man overboard?

Fig. 2. Representation of a typical moral dilemma used in functional MRI experiments in psychopaths. Adapted, with permission, from Pujol *et al.* (2012).

between striatal serotonin 1B receptor binding and the level of psychopathy (da Cunha-Bang *et al.*, 2017).

General implications

In this review, we provide a synthesis of available neuroimaging research directly concerning to psychopathy. A variety of imaging methods has been used to date to provide distinct perspectives of brain structure and function. There are notable differences across the findings of existing studies, which is likely to reflect important differences in study methodology, but may also reflect the underlying biological heterogeneity of psychopathy. Nevertheless, most studies coincide in suggesting that the brain of psychopaths differs notably from the typical brain in terms of both anatomy and function. There is a tendency for changes to affect the brain globally, but variations from the normal pattern are particularly evident in a number of functionally related brain structures. One system includes the rostral aspect of both frontal and temporal lobes, which subcortically report to the ventral striatum and anterior hippocampus/amygdala, respectively. Although this system is involved in a vast variety of processes, in the context of psychopathy, we emphasize its role in conveying emotional input to motivated actions (Simpson and Balsam, 2016). The second

system combines the medial frontal (and anterior cingulate) cortex with the posterior cingulate cortex/precuneus, core elements of the default mode network, which are critical in focusing attention on self and accessing autobiographical storage (Bado *et al.*, 2014; Leech and Sharp, 2014). This dorsal system is connected to caudal temporal lobe structures also altered in psychopathy. Relevant changes have been identified in the parahippocampus/posterior hippocampus and visual areas involved in the processing of sensory stimulation in general, but also relevant for the storage of significant autobiographical events (Jeong *et al.*, 2015). In addition, alterations have also been reported involving the sensorimotor cortex, which is the primary representation of our bodies.

Functional data suggest that emotionally evocative stimuli are indeed capable of activating the brain and even generating excessive responses in some (mostly dorsal) emotion-relevant brain areas in psychopaths. However, the emotional processing flow may appear to be disrupted in the transition from the temporal lobe to ventral frontal areas, with the consequent failure to integrate emotion into cognition and subsequent decisions, as often proposed (Kiehl *et al.*, 2001; Raine and Yang, 2006; Blair, 2007; Moll *et al.*, 2008; Contreras *et al.*, 2014; Blair *et al.*, 2018). The alteration in emotional processing resulting from such ventral temporal-frontal blockage may be sufficient to account for

psychopathic behavior if taken to the extreme. Indeed, in fronto-temporal dementia and after focal damage of rostral fronto-temporal areas, the presence of psychopathic-like behavior is not exceptional (Anderson *et al.*, 1999; Brower and Price, 2001; Koenigs *et al.*, 2007; Moll *et al.*, 2007; Diehl-Schmid *et al.*, 2013; Birkhoff *et al.*, 2016; Darby *et al.*, 2018).

Nevertheless, imaging data indicate that emotional processing blockage may also occur as a result of the abnormal functioning of a dorsal brain system. Probably the most consistent finding in functional imaging research in the context of adult psychopathy is the alteration of the network involved in the mediation of moral judgment overlapping with the default mode network. The normal activation of this network serves to focus attention on the self as an agent and thus (as we propose) exposing the individual to be aroused (or 'touched') from emotional (positive or negative) memories stored in temporal lobe medial structures. Activation of the default mode network during moral conflict is certainly abnormal in psychopaths (Glenn *et al.*, 2009; Harenski *et al.*, 2010; Veit *et al.*, 2010; Pujol *et al.*, 2012; Yoder *et al.*, 2015), which concurs with a similarly poor activation of key memory structures such as the parahippocampal gyrus, hippocampus, and amygdala (Glenn *et al.*, 2009; Pujol *et al.*, 2012; Marsh and Cardinale, 2014; Yoder *et al.*, 2015).

All in all, a failure to integrate emotion into cognition would appear to result from at least two complementary breakdowns; bottom-up disruption of the emotional flow in the ventral fronto-temporal system and a top-down blockage of emotional self-exposure in the dorsal network mediating moral judgment.

Future directions

In the current review, we have focused on how current neuroimaging research may contribute to a better understanding of pathophysiological mechanisms leading to psychopathic behavior. Nevertheless, another question is whether neuroimaging can provide clues as to its etiology? We would emphasize three potential causal factors deserving future research, in addition to genetic predisposition, which always plays a significant role in complex behavioral disorders.

As discussed earlier, one of the factors that potentially contributes to the development of brain pathology in psychopaths is life-time stress, which may well accelerate brain maturation. Life-time stress could indeed contribute to regional gray matter volume reduction through excessive neural activity leading to subsequent atrophy (a 'burnout' effect) or by increasing myelinated white matter with an apparent reduction of the gray matter tissue segment, or both. Future analyses may specifically focus on determining the life-time evolution of cortical white matter content. Additionally, it may be valuable in this context to test the hypothesis of accelerated brain maturation from a functional perspective, by assessing both brain activity and functional network connectivity in children and adolescents with psychopathic traits.

Androgens have a relevant effect on brain shaping. Critical periods include the prenatal androgenization of the brain and androgen activation during adolescence (Arnold and Gorski, 1984; Sato *et al.*, 2008). The male and female brain differs, in part, due to androgen effects (Heany *et al.*, 2016) and antisocial behavior is substantially more frequent in males (Yildirim and Derksen, 2012). Thus, anomalies in developmental androgenic brain modeling may increase the predisposition to psychopathy (Yildirim and Derksen, 2012). Relevantly, the effects of prolonged high-dose administration of androgenic steroids on brain anatomy are largely

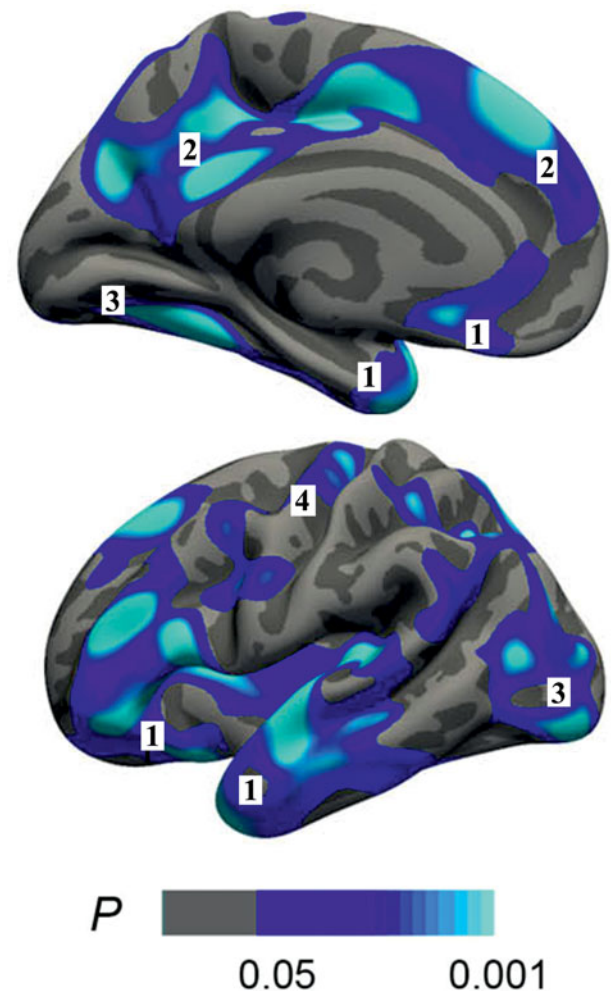


Fig. 3. Regions showing reduced cortical thickness in users exceeding 10 years of anabolic-androgenic steroid exposure compared with control subjects. Adapted, with permission, from Bjørnebekk *et al.* (2017). Note the notable regional coincidence with the areas showing the most consistent volume reduction in psychopaths illustrated in Fig. 1. The largest coincidences are present in the ventral temporal-frontal system (1) and the dorsal-medial system (2), but cortical reductions are also present in visual (3) and motor cortices (4).

reminiscent of gray matter alteration patterns in psychopaths showing reduced cortical thickness in rostral frontotemporal areas, the medial frontal cortex, the posterior cingulate cortex/pre-cuneus, and visual areas (Fig. 3) (Bjørnebekk *et al.*, 2017).

Finally, the results from some analyses suggest that the described brain alterations could show distinct and opposite patterns of association with both affective disturbances and antisocial behavior. Indeed, some brain alterations are reported to be associated with more affective disturbances (Hare factor 1) and less antisocial behavior (Hare factor 2), including reductions in gray matter volume (Contreras *et al.*, 2015), altered functional connectivity in large-scale cortical networks (Philippi *et al.*, 2015), and amygdala reactivity (Hyde *et al.*, 2014). A recent study further indicates that the severity of antisocial behavior is associated with larger prefrontal and striatal subregion volumes and higher functional connectivity between the several areas of the prefrontal cortex (Korponay *et al.*, 2017a, 2017b). Future research on this issue is therefore of great interest to ascertain whether the described alterations in brain structure and function in psychopaths necessarily predispose them to crime. Interestingly, there are behavioral

data indicating that antisocial behavior, as measured in Hare factor 2, is better explained by poorer cognitive functioning (Baskin-Sommers *et al.*, 2015).

Conclusions

This review has sought to provide a consolidated perspective on the contribution of brain imaging to understanding of psychopathy. The brain of psychopaths differs from the typical brain in terms of both anatomy and function. Anatomical alterations involve primarily a ventral system connecting the anterior temporal lobe to anterior and ventral frontal areas, and a dorsal system connecting the medial frontal lobe to the posterior cingulate cortex/precuneus complex and, in turn, to medial structures of the temporal lobe. Functional imaging data indicate that a significant disruption or 'breakdown' in the flow of emotional information processing may occur in both these two brain systems and suggest specific mechanisms via which emotion is anomalously integrated into cognition in psychopathic individuals during moral challenge. To this end, broader reviews are of interest comparing the results from different fields including, for instance, EEG, genetics, neurochemistry, and neuropsychology.

Acknowledgements. The authors thank Dr Laura Blanco-Hinojo for her valuable comments. Dr Oren Contreras-Rodríguez thanks the Instituto de Salud Carlos III for the Sara Borrell Contract (CD14/00246).

Funding. This research did not receive any specific grant from funding agencies in the public, commercial, or not-for-profit sectors.

Conflicts of interest. None.

References

- Aharoni E, Vincent GM, Harenski CL, Calhoun VD, Sinnott-Armstrong W, Gazzaniga MS and Kiehl KA (2013) Neuroprediction of future rearrest. *Proceedings of the National Academy of Sciences of the USA* **110**, 6223–6228.
- American Psychiatric Association (2013) *Diagnostic and Statistical Manual of Mental Disorders*, 5th Edn. Arlington, VA: American Psychiatric Association.
- Anderson SW, Bechara A, Damasio H, Tranel D and Damasio AR (1999) Impairment of social and moral behavior related to early damage in human prefrontal cortex. *Nature Neuroscience* **2**, 1032–1037.
- Aoki Y, Inokuchi R, Nakao T and Yamasue H (2014) Neural bases of antisocial behavior: a voxel-based meta-analysis. *Social Cognitive and Affective Neuroscience* **9**, 1223–1231.
- Arnold AP and Gorski RA (1984) Gonadal steroid induction of structural sex differences in the central nervous system. *Annual Review of Neuroscience* **7**, 413–442.
- Bado P, Engel A, de Oliveira-Souza R, Bramati IE, Paiva FF, Basilio R, Sato JR, Tovar-Moll F and Moll J (2014) Functional dissociation of ventral frontal and dorsomedial default mode network components during resting state and emotional autobiographical recall. *Human Brain Mapping* **35**, 3302–3313.
- Barkataki I, Kumari V, Das M, Taylor P and Sharma T (2006) Volumetric structural brain abnormalities in men with schizophrenia or antisocial personality disorder. *Behavioural Brain Research* **169**, 239–247.
- Baskin-Sommers AR, Brazil IA, Ryan J, Kohlenberg NJ, Neumann CS and Newman JP (2015) Mapping the association of global executive functioning onto diverse measures of psychopathic traits. *Personality Disorders* **6**, 336–346.
- Baskin-Sommers AR, Neumann CS, Cope LM and Kiehl KA (2016) Latent-variable modeling of brain gray-matter volume and psychopathy in incarcerated offenders. *Journal of Abnormal Psychology* **125**, 811–817.
- Bertsch K, Grothe M, Prehn K, Vohs K, Berger C, Hauenstein K, Keiper P, Domes G, Teipel S and Herpertz SC (2013) Brain volumes differ between diagnostic groups of violent criminal offenders. *European Archives of Psychiatry and Clinical Neuroscience* **263**, 593–606.
- Birkhoff JM, Garberi C and Re L (2016) The behavioral variant of frontotemporal dementia: an analysis of the literature and a case report. *International Journal of Law and Psychiatry* **47**, 157–163.
- Biswal B, Yetkin FZ, Haughton VM and Hyde JS (1995) Functional connectivity in the motor cortex of resting human brain using echo-planar MRI. *Magnetic Resonance in Medicine* **34**, 537–541.
- Bjørnebekk A, Walhovd KB, Jørstad ML, Due-Tønnessen P, Hullstein IR and Fjell AM (2017) Structural brain imaging of long-term anabolic-androgenic steroid users and nonusing weightlifters. *Biological Psychiatry* **82**, 294–302.
- Blair RJ (2007) The amygdala and ventromedial prefrontal cortex in morality and psychopathy. *Trends in Cognitive Science* **11**, 387–392.
- Blair RJ (2012) Cortical thinning and functional connectivity in psychopathy. *The American Journal of Psychiatry* **169**, 684–687.
- Blair RJ, Veroude K and Buitelaar JK (2018) Neuro-cognitive system dysfunction and symptom sets: a review of fMRI studies in youth with conduct problems. *Neuroscience & Biobehavioral Reviews* **91**, 69–90.
- Boccardi M, Ganzola R, Rossi R, Sabattoli F, Laakso MP, Repo-Tiihonen E, Vaurio O, Könönen M, Aronen HJ, Thompson PM, Frisoni GB and Tiihonen J (2010) Abnormal hippocampal shape in offenders with psychopathy. *Human Brain Mapping* **31**, 438–447.
- Boccardi M, Frisoni GB, Hare RD, Cavedo E, Najt P, Pievani M, Rasser PE, Laakso MP, Aronen HJ, Repo-Tiihonen E, Vaurio O, Thompson PM and Tiihonen J (2011) Cortex and amygdala morphology in psychopathy. *Psychiatry Research* **193**, 85–92.
- Boccardi M, Bocchetta M, Aronen HJ, Repo-Tiihonen E, Vaurio O, Thompson PM, Tiihonen J and Frisoni GB (2013) Atypical nucleus accumbens morphology in psychopathy: another limbic piece in the puzzle. *International Journal of Law and Psychiatry* **36**, 157–167.
- Brower MC and Price BH (2001) Neuropsychiatry of frontal lobe dysfunction in violent and criminal behaviour: a critical review. *Journal of Neurology, Neurosurgery, and Psychiatry* **71**, 720–726.
- Busso DS, McLaughlin KA, Brueck S, Peverill M, Gold AL and Sheridan MA (2017) Child abuse, neural structure, and adolescent psychopathology: a longitudinal study. *Journal of the American Academy of Child and Adolescent Psychiatry* **56**, 321–328.e1.
- Choi J, Jeong B, Rohan ML, Polcari AM and Teicher MH (2009) Preliminary evidence for white matter tract abnormalities in young adults exposed to parental verbal abuse. *Biological Psychiatry* **65**, 227–234.
- Contreras-Rodríguez O, Pujol J, Batalla I, Harrison BJ, Bosque J, Ibern-Regàs I, Hernández-Ribas R, Soriano-Mas C, Deus J, López-Solà M, Pifarré J, Menchón JM and Cardoner N (2014) Disrupted neural processing of emotional faces in psychopathy. *Social Cognitive and Affective Neuroscience* **9**, 505–512.
- Contreras-Rodríguez O, Pujol J, Batalla I, Harrison BJ, Soriano-Mas C, Deus J, López-Solà M, Macià D, Pera V, Hernández-Ribas R, Pifarré J, Menchón JM and Cardoner N (2015) Functional connectivity bias in the prefrontal cortex of psychopaths. *Biological Psychiatry* **78**, 647–655.
- Cope LM, Ermer E, Nyalakanti PK, Calhoun VD and Kiehl KA (2014a) Paralimbic gray matter reductions in incarcerated adolescent females with psychopathic traits. *Journal of Abnormal Child Psychology* **42**, 659–668.
- Cope LM, Vincent GM, Jobelius JL, Nyalakanti PK, Calhoun VD and Kiehl KA (2014b) Psychopathic traits modulate brain responses to drug cues in incarcerated offenders. *Frontiers in Human Neuroscience* **8**, 87.
- Craig MC, Catani M, Deeley Q, Latham R, Daly E, Kanaan R, Picchioni M, McGuire PK, Fahy T and Murphy DG (2009) Altered connections on the road to psychopathy. *Molecular Psychiatry* **14**, 946–953.
- da Cunha-Bang S, Hjordt LV, Perfalk E, Beliveau V, Bock C, Lehel S, Thomsen C, Sestoft D, Svarer C and Knudsen GM (2017) Serotonin 1B receptor binding is associated with trait anger and level of psychopathy in violent offenders. *Biological Psychiatry* **82**, 267–274.
- Darby RR, Horn A, Cushman F and Fox MD (2018) Lesion network localization of criminal behavior. *Proceedings of the National Academy of Sciences of the USA* **115**, 601–606.
- De Brito SA, Mechelli A, Wilke M, Laurens KR, Jones AP, Barker GJ, Hodgins S and Viding E (2009) Size matters: increased grey matter in

- boys with conduct problems and callous-unemotional traits. *Brain* 132, 843–852.
- De Brito SA, McCrory EJ, Mechelli A, Wilke M, Jones AP, Hodgins S and Viding E (2011) Small, but not perfectly formed: decreased white matter concentration in boys with psychopathic tendencies. *Molecular Psychiatry* 16, 476–477.
- Decety J, Chen C, Harenski C and Kiehl KA (2013a) An fMRI study of affective perspective taking in individuals with psychopathy: imagining another in pain does not evoke empathy. *Frontiers in Human Neuroscience* 7, 489.
- Decety J, Skelly LR and Kiehl KA (2013b) Brain response to empathy-eliciting scenarios involving pain in incarcerated individuals with psychopathy. *JAMA Psychiatry* 70, 638–645.
- Decety J, Skelly L, Yoder KJ and Kiehl KA (2014) Neural processing of dynamic emotional facial expressions in psychopaths. *Social Neuroscience* 9, 36–49.
- Decety J, Chen C, Harenski CL and Kiehl KA (2015) Socioemotional processing of morally-laden behavior and their consequences on others in forensic psychopaths. *Human Brain Mapping* 36, 2015–2026.
- Deeley Q, Daly E, Surguladze S, Tunstall N, Mezey G, Beer D, Ambikapathy A, Robertson D, Giampietro V, Brammer MJ, Clarke A, Dowsett J, Fahy T, Phillips ML and Murphy DG (2006) Facial emotion processing in criminal psychopathy. Preliminary functional magnetic resonance imaging study. *The British Journal of Psychiatry* 189, 533–539.
- de Oliveira-Souza R, Hare RD, Bramati IE, Garrido GJ, Azevedo Ignácio F, Tovar-Moll F and Moll J (2008) Psychopathy as a disorder of the moral brain: fronto-temporo-limbic grey matter reductions demonstrated by voxel-based morphometry. *Neuroimage* 40, 1202–1213.
- Diehl-Schmid J, Perneczky R, Koch J, Nedopil N and Kurz A (2013) Guilty by suspicion? Criminal behavior in frontotemporal lobar degeneration. *Cognitive and Behavioral Neurology* 26, 73–77.
- Dolan MC, Deakin JF, Roberts N and Anderson IM (2002) Quantitative frontal and temporal structural MRI studies in personality-disordered offenders and control subjects. *Psychiatry Research* 116, 133–149.
- Douaud G, Jabdi S, Behrens TE, Menke RA, Gass A, Monsch AU, Rao A, Whitcher B, Kindlmann G, Matthews PM and Smith S (2011) DTI measures in crossing-fibre areas: increased diffusion anisotropy reveals early white matter alteration in MCI and mild Alzheimer's disease. *Neuroimage* 55, 880–890.
- Ermer E, Cope LM, Nyalakanti PK, Calhoun VD and Kiehl KA (2012) Aberrant paralimbic gray matter in criminal psychopathy. *Journal of Abnormal Psychology* 121, 649–658.
- Ermer E, Cope LM, Nyalakanti PK, Calhoun VD and Kiehl KA (2013) Aberrant paralimbic gray matter in incarcerated male adolescents with psychopathic traits. *Journal of the American Academy of Child and Adolescent Psychiatry* 52, 94–103.e3.
- Fair DA, Cohen AL, Power JD, Dosenbach NU, Church JA, Miezin FM, Schlaggar BL and Petersen SE (2009) Functional brain networks develop from a 'local to distributed' organization. *PLoS Computational Biology* 5, e1000381.
- Fairchild G, Hagan CC, Walsh ND, Passamonti L, Calder AJ and Goodyer IM (2013) Brain structure abnormalities in adolescent girls with conduct disorder. *Journal of Child Psychology and Psychiatry* 54, 86–95.
- Freeman SM, Clewett DV, Bennett CM, Kiehl KA, Gazzaniga MS and Miller MB (2015) The posteromedial region of the default mode network shows attenuated task-induced deactivation in psychopathic prisoners. *Neuropsychology* 29, 493–500.
- Geurts DE, von Borries K, Volman I, Bulten BH, Cools R and Verkes RJ (2016) Neural connectivity during reward expectation dissociates psychopathic criminals from non-criminal individuals with high impulsive/antisocial psychopathic traits. *Social Cognitive and Affective Neuroscience* 11, 1326–1334.
- Glenn AL, Raine A and Schug RA (2009) The neural correlates of moral decision-making in psychopathy. *Molecular Psychiatry* 14, 5–6.
- Glenn AL, Yang Y, Raine A and Colletti P (2010a) No volumetric differences in the anterior cingulate of psychopathic individuals. *Psychiatry Research* 183, 140–143.
- Glenn AL, Raine A, Yarialian PS and Yang Y (2010b) Increased volume of the striatum in psychopathic individuals. *Biological Psychiatry* 67, 52–58.
- Greene JD, Sommerville RB, Nystrom LE, Darley JM and Cohen JD (2001) An fMRI investigation of emotional engagement in moral judgment. *Science* 293, 2105–2108.
- Gregory S, Ffytche D, Simmons A, Kumari V, Howard M, Hodgins S and Blackwood N (2012) The antisocial brain: psychopathy matters. *Archives of General Psychiatry* 69, 962–972.
- Gregory S, Blair RJ, Ffytche D, Simmons A, Kumari V, Hodgins S and Blackwood N (2015) Punishment and psychopathy: a case-control functional MRI investigation of reinforcement learning in violent antisocial personality disordered men. *The Lancet. Psychiatry* 2153–160.
- Hare RD (2003) *Hare Psychopathy Checklist- Revised (PCL-R)*, 2nd Edn. Toronto: Multi-Health Systems Inc.
- Harenski CL, Harenski KA, Shane MS and Kiehl KA (2010) Aberrant neural processing of moral violations in criminal psychopaths. *Journal of Abnormal Psychology* 119, 863–874.
- Harenski CL, Harenski KA and Kiehl KA (2014) Neural processing of moral violations among incarcerated adolescents with psychopathic traits. *Developmental Cognitive Neuroscience* 10, 181–189.
- Harrison BJ, Pujol J, López-Solà M, Hernández-Ribas R, Deus J, Ortiz H, Soriano-Mas C, Yücel M, Pantelis C and Cardoner N (2008) Consistency and functional specialization in the default mode brain network. *Proceedings of the National Academy of Sciences of the USA* 105, 9781–9786.
- Heany SJ, van Honk J, Stein DJ and Brooks SJ (2016) A quantitative and qualitative review of the effects of testosterone on the function and structure of the human social-emotional brain. *Metabolic Brain Disease* 31, 157–167.
- Holz NE, Boecker R, Hohm E, Zohsel K, Buchmann AF, Blomeyer D, Barker G, Bokde AL, Bromberg U, Büchel C, Cattrell A, Conrod PJ, Desrivières S, Flor H, Frouin V, Gallinat J, Gowland P, Heinz A, Ittermann B, Paillère Martinot ML, Artiges E, Nees F, Papadopoulos-Orfanos D, Poustka L, Smolka MN, Jurk S, Walter H, Whelan R, Schumann G, Althoff RR, Garavan H and IMAGEN Consortium (2015) The long-term impact of early life poverty on orbitofrontal cortex volume in adulthood: results from a prospective study over 25 years. *Neuropsychopharmacology* 40, 996–1004.
- Hoppenbrouwers SS, Nazeri A, de Jesus DR, Stirpe T, Felsky D, Schutter DJ, Daskalakis ZJ and Voineskos AN (2013) White matter deficits in psychopathic offenders and correlation with factor structure. *PLoS One* 8, e72375.
- Hyde LW, Byrd AL, Votruba-Drzal E, Hariri AR and Manuck SB (2014) Amygdala reactivity and negative emotionality: divergent correlates of antisocial personality and psychopathy traits in a community sample. *Journal of Abnormal Psychology* 123, 214–224.
- Intrator J, Hare R, Stritzke P, Brichtswein K, Dorfman D, Harpur T, Bernstein D, Handelsman L, Schaefer C, Keilp J, Rosen J and Machac J (1997) A brain imaging (single photon emission computerized tomography) study of semantic and affective processing in psychopaths. *Biological Psychiatry* 42, 96–103.
- Jeong W, Chung CK and Kim JS (2015) Episodic memory in aspects of large-scale brain networks. *Frontiers in Human Neuroscience* 9, 454.
- Jiang W, Li G, Liu H, Shi F, Wang T, Shen C, Lee SW, Hu D, Wang W and Shen D (2016) Reduced cortical thickness and increased surface area in antisocial personality disorder. *Neuroscience* 337, 143–152.
- Jiang W, Shi F, Liao J, Liu H, Wang T, Shen C, Hu D, Wang W and Shen D (2017a) Disrupted functional connectome in antisocial personality disorder. *Brain Imaging and Behavior* 11, 1071–1084.
- Jiang W, Shi F, Liu H, Li G, Ding Z, Shen H, Lee SW, Hu D, Wang W and Shen D (2017b) Reduced white matter integrity in antisocial personality disorder: a diffusion tensor imaging study. *Scientific Reports* 7, 43002.
- Jones DK, Knösche TR and Turner R (2013) White matter integrity, fiber count, and other fallacies: the do's and don'ts of diffusion MRI. *Neuroimage* 73: 239–254.
- Juárez M, Kiehl KA and Calhoun VD (2013) Intrinsic limbic and paralimbic networks are associated with criminal psychopathy. *Human Brain Mapping* 34, 1921–1930.
- Kiehl KA and Hoffman MB (2011) The criminal psychopath: history, neuroscience, treatment, and economics. *Jurimetrics* 51, 355–397.
- Kiehl KA, Smith AM, Hare RD, Mendrek A, Forster BB, Brink J and Liddle PF (2001) Limbic abnormalities in affective processing by criminal

- psychopaths as revealed by functional magnetic resonance imaging. *Biological Psychiatry* 50, 677–684.
- Koenigs M, Young L, Adolphs R, Tranel D, Cushman F, Hauser M and Damasio A** (2007) Damage to the prefrontal cortex increases utilitarian moral judgements. *Nature* 446, 908–911.
- Kolla NJ, Gregory S, Attard S, Blackwood N and Hodgins S** (2014) Disentangling possible effects of childhood physical abuse on gray matter changes in violent offenders with psychopathy. *Psychiatry Research* 221, 123–126.
- Kolla NJ, Matthews B, Wilson AA, Houle S, Bagby RM, Links P, Simpson AI, Hussain A and Meyer JH** (2015) Lower monoamine oxidase-A total distribution volume in impulsive and violent male offenders with antisocial personality disorder and high psychopathic traits: an [(11)C] harmine positron emission tomography study. *Neuropsychopharmacology* 40, 2596–2603.
- Korponay C, Pujara M, Deming P, Philippi C, Decety J, Kosson DS, Kiehl KA and Koenigs M** (2017a) Impulsive-antisocial psychopathic traits linked to increased volume and functional connectivity within prefrontal cortex. *Social Cognitive and Affective Neuroscience* 12, 1169–1178.
- Korponay C, Pujara M, Deming P, Philippi C, Decety J, Kosson DS, Kiehl KA and Koenigs M** (2017b) Impulsive-antisocial dimension of psychopathy linked to enlargement and abnormal functional connectivity of the striatum. *Biological Psychiatry: Cognitive Neuroscience and Neuroimaging* 2, 149–157.
- Kumari V, Uddin S, Premkumar P, Young S, Gudjonsson GH, Raghuvanshi S, Barkataki I, Sumich A, Taylor P and Das M** (2014) Lower anterior cingulate volume in seriously violent men with antisocial personality disorder or schizophrenia and a history of childhood abuse. *Australian and New Zealand Journal of Psychiatry* 48, 153–161.
- Laakso MP, Vaurio O, Koivisto E, Savolainen L, Eronen M, Aronen HJ, Hakola P, Repo E, Soininen H and Tiihonen J** (2001) Psychopathy and the posterior hippocampus. *Behavioural Brain Research* 118, 187–193.
- Laakso MP, Gunning-Dixon F, Vaurio O, Repo-Tiihonen E, Soininen H and Tiihonen J** (2002) Prefrontal volumes in habitually violent subjects with antisocial personality disorder and type 2 alcoholism. *Psychiatry Research* 114, 95–102.
- Lamsma J, Mackay C and Fazel S** (2017) Structural brain correlates of interpersonal violence: systematic review and voxel-based meta-analysis of neuroimaging studies. *Psychiatry Research, Neuroimaging* 267, 69–73.
- Larson CL, Baskin-Sommers AR, Stout DM, Balderston NL, Curtin JJ, Schultz DH, Kiehl KA and Newman JP** (2013) The interplay of attention and emotion: top-down attention modulates amygdala activation in psychopathy. *Cognitive, Affective, & Behavioral Neuroscience* 13, 757–770.
- Lebel C, Gee M, Camicioli R, Wieler M, Martin W and Beaulieu C** (2012) Diffusion tensor imaging of white matter tract evolution over the lifespan. *Neuroimage* 60, 340–352.
- Leech R and Sharp DJ** (2014) The role of the posterior cingulate cortex in cognition and disease. *Brain* 137, 12–32.
- Lilienfeld SO and Andrews BP** (1996) Development and preliminary validation of a self-report measure of psychopathic personality traits in noncriminal populations. *Journal of Personality Assessment* 66, 488–524.
- Ly M, Motzkin JC, Philippi CL, Kirk GR, Newman JP, Kiehl KA and Koenigs M** (2012) Cortical thinning in psychopathy. *The American Journal of Psychiatry* 169, 743–749.
- Mackey S, Chaarani B, Kan KJ, Spechler PA, Orr C, Banaschewski T, Barker G, Bokde AL, Bromberg U, Büchel C, Cattrell A, Conrod PJ, Desrivieres S, Flor H, Frouin V, Gallinat J, Gowland P, Heinz A, Ittermann B, Paillère Martinot ML, Artiges E, Nees F, Papadopoulos-Orfanos D, Poustka L, Smolka MN, Jurk S, Walter H, Whelan R, Schumann G, Althoff RR, Garavan H and IMAGEN Consortium** (2017) Brain regions related to impulsivity mediate the effects of early adversity on antisocial behavior. *Biological Psychiatry* 82, 275–282.
- Marsh AA and Cardinale EM** (2014) When psychopathy impairs moral judgments: neural responses during judgments about causing fear. *Social Cognitive and Affective Neuroscience* 9, 3–11.
- Matochik JA, Eldreth DA, Cadet JL and Bolla KI** (2005) Altered brain tissue composition in heavy marijuana users. *Drug and Alcohol Dependence* 77, 23–30.
- McKenzie IA, Ohayon D, Li H, de Faria JP, Emery B, Tohyama K and Richardson WD** (2014) Motor skill learning requires active central myelination. *Science* 346, 318–322.
- Meffert H, Gazzola V, den Boer JA, Bartels AA and Keysers C** (2013) Reduced spontaneous but relatively normal deliberate vicarious representations in psychopathy. *Brain* 136, 2550–2562.
- Mier D, Haddad L, Diers K, Dressing H, Meyer-Lindenberg A and Kirsch P** (2014) Reduced embodied simulation in psychopathy. *The World Journal of Biological Psychiatry* 15, 479–487.
- Moll J, de Oliveira-Souza R, Garrido GJ, Bramati IE, Caparelli-Daquer EM, Paiva ML, Zahn R and Grafman J** (2007) The self as a moral agent: linking the neural bases of social agency and moral sensitivity. *Social Neuroscience* 2, 336–352.
- Moll J, De Oliveira-Souza R and Zahn R** (2008) The neural basis of moral cognition: sentiments, concepts, and values. *Annals of the New York Academy of Sciences* 1124, 161–180.
- Motzkin JC, Newman JP, Kiehl KA and Koenigs M** (2011) Reduced prefrontal connectivity in psychopathy. *Journal of Neuroscience* 31, 17348–17357.
- Müller JL, Sommer M, Wagner V, Lange K, Taschler H, Röder CH, Schuierer G, Klein HE and Hajak G** (2003) Abnormalities in emotion processing within cortical and subcortical regions in criminal psychopaths: evidence from a functional magnetic resonance imaging study using pictures with emotional content. *Biological Psychiatry* 54, 152–162.
- Müller JL, Gänssbauer S, Sommer M, Döhnell K, Weber T, Schmidt-Wilcke T and Hajak G** (2008) Gray matter changes in right superior temporal gyrus in criminal psychopaths. Evidence from voxel-based morphometry. *Psychiatry Research* 163, 213–222.
- Narayan VM, Narr KL, Kumari V, Woods RP, Thompson PM, Toga AW and Sharma T** (2007) Regional cortical thinning in subjects with violent antisocial personality disorder or schizophrenia. *The American Journal of Psychiatry* 164, 1418–1427.
- Newman JP and Baskin-Sommers AR** (2016) Smith and Lilienfeld's meta-analysis of the response modulation hypothesis: important theoretical and quantitative clarifications. *Psychological Bulletin* 142, 1384–1393.
- Newman JP, Curtin JJ, Bertsch JD and Baskin-Sommers AR** (2010) Attention moderates the fearlessness of psychopathic offenders. *Biological Psychiatry* 67, 66–70.
- Noordermeer SD, Luman M and Oosterlaan J** (2016) A systematic review and meta-analysis of neuroimaging in Oppositional Defiant Disorder (ODD) and Conduct Disorder (CD) taking Attention-Deficit Hyperactivity Disorder (ADHD) into account. *Neuropsychology Review* 26, 44–72.
- Ou X, Andres A, Pivik RT, Cleves MA and Badger TM** (2015) Brain gray and white matter differences in healthy normal weight and obese children. *Journal of Magnetic Resonance Imaging* 42, 1205–1213.
- Patrick CJ** (2014) Physiological correlates of psychopathy, antisocial personality disorder, habitual aggression, and violence. *Current Topics in Behavioral Neurosciences* 21, 197–227.
- Patrick CJ, Fowles DC and Krueger RF** (2009) Triarchic conceptualization of psychopathy: developmental origins of disinhibition, boldness, and meanness. *Development and Psychopathology* 21, 913–938.
- Paus T, Collins DL, Evans AC, Leonard G, Pike B and Zijdenbos A** (2001) Maturation of white matter in the human brain: a review of magnetic resonance studies. *Brain Research Bulletin* 54, 255–266.
- Pera-Guardiola V, Contreras-Rodríguez O, Batalla I, Kosson D, Menchón JM, Pifarré J, Bosque J, Cardoner N and Soriano-Mas C** (2016) Brain structural correlates of emotion recognition in psychopaths. *PLoS One* 11, e0149807.
- Philippi CL, Pujara MS, Motzkin JC, Newman J, Kiehl KA and Koenigs M** (2015) Altered resting-state functional connectivity in cortical networks in psychopathy. *Journal of Neuroscience* 35, 6068–6078.
- Prehn K, Schlagenhauf F, Schulze L, Berger C, Vohs K, Fleischer M, Hauenstein K, Keiper P, Domes G and Herpertz SC** (2013) Neural correlates of risk taking in violent criminal offenders characterized by emotional hypo- and hyper-reactivity. *Social Neuroscience* 8, 136–147.
- Pujara M, Motzkin JC, Newman JP, Kiehl KA and Koenigs M** (2014) Neural correlates of reward and loss sensitivity in psychopathy. *Social Cognitive and Affective Neuroscience* 9, 794–801.

- Pujol J, Vendrell P, Junqué C, Martí-Vilalta JL and Capdevila A (1993) When does human brain development end? Evidence of corpus callosum growth up to adulthood. *Annals of Neurology* **34**, 71–75.
- Pujol J, Soriano-Mas C, Ortiz H, Sebastián-Gallés N, Losilla JM and Deus J (2006) Myelination of language-related areas in the developing brain. *Neurology* **66**, 339–343.
- Pujol J, Batalla I, Contreras-Rodríguez O, Harrison BJ, Pera V, Hernández-Ribas R, Real E, Bosa L, Soriano-Mas C, Deus J, López-Solà M, Pifarré J, Menchón JM and Cardoner N (2012) Breakdown in the brain network subserving moral judgment in criminal psychopathy. *Social Cognitive and Affective Neuroscience* **7**, 917–923.
- Pujol J, Fenoll R, Fornis J, Harrison BJ, Martínez-Vilavella G, Macià D, Alvarez-Pedrerol M, Blanco-Hinojo L, González-Ortiz S, Deus J and Sunyer J (2016a) Video gaming in school children: how much is enough? *Annals of Neurology* **80**, 424–433.
- Pujol J, Martínez-Vilavella G, Macià D, Fenoll R, Alvarez-Pedrerol M, Rivas I, Fornis J, Blanco-Hinojo L, Capellades J, Querol X, Deus J and Sunyer J (2016b) Traffic pollution exposure is associated with altered brain connectivity in school children. *Neuroimage* **129**, 175–184.
- Raine A and Yang Y (2006) Neural foundations to moral reasoning and antisocial behavior. *Social Cognitive and Affective Neuroscience* **1**, 203–213.
- Raine A, Buchsbaum M and LaCasse L (1997) Brain abnormalities in murderers indicated by positron emission tomography. *Biological Psychiatry* **42**, 495–508.
- Raine A, Lencz T, Bihrlé S, LaCasse L and Colletti P (2000) Reduced prefrontal gray matter volume and reduced autonomic activity in antisocial personality disorder. *Archives of General Psychiatry* **57**, 119–127.
- Raine A, Lencz T, Taylor K, Hellige JB, Bihrlé S, Lacasse L, Lee M, Ishikawa S and Colletti P (2003) Corpus callosum abnormalities in psychopathic antisocial individuals. *Archives of General Psychiatry* **60**, 1134–1142.
- Raine A, Ishikawa SS, Arce E, Lencz T, Knuth KH, Bihrlé S, LaCasse L and Colletti P (2004) Hippocampal structural asymmetry in unsuccessful psychopaths. *Biological Psychiatry* **55**, 185–191.
- Raine A, Lee L, Yang Y and Colletti P (2010) Neurodevelopmental marker for limbic maldevelopment in antisocial personality disorder and psychopathy. *The British Journal of Psychiatry* **197**, 186–192.
- Raine A, Yang Y, Narr KL and Toga AW (2011) Sex differences in orbitofrontal gray as a partial explanation for sex differences in antisocial personality. *Molecular Psychiatry* **16**, 227–236.
- Rodman AM, Kastman E, Dorfman HM, Baskin-Sommers A, Kiehl KA, Newman JP and Buckholz JW (2016) Selective mapping of psychopathy and externalizing to dissociable circuits for inhibitory self-control. *Clinical Psychological Science* **4**, 559–571.
- Rogers J and De Brito SA (2016) Cortical and subcortical gray matter volume in youths with conduct problems: a meta-analysis. *JAMA Psychiatry* **73**, 64–72.
- Saba L, Anzidei M, Raz E, Suri J, Piga M, Grassi R and Catalano C (2013) MR and CT of brain's cava. *Journal of Neuroimaging* **23**, 326–335.
- Sato SM, Schulz KM, Sisk CL and Wood RI (2008) Adolescents and androgens, receptors and rewards. *Hormones and Behavior* **53**, 647–658.
- Sato JR, de Oliveira-Souza R, Thomaz CE, Basilio R, Bramati IE, Amaro Jr. E, Tovar-Moll F, Hare RD and Moll J (2011) Identification of psychopathic individuals using pattern classification of MRI images. *Social Neuroscience* **6**, 627–639.
- Schneider F, Habel U, Kessler C, Posse S, Grodd W and Müller-Gärtner HW (2000) Functional imaging of conditioned aversive emotional responses in antisocial personality disorder. *Neuropsychobiology* **42**, 192–201.
- Schultz DH, Balderston NL, Baskin-Sommers AR, Larson CL and Helmstetter FJ (2016) Psychopaths show enhanced amygdala activation during fear conditioning. *Frontiers in Psychology* **7**, 348.
- Sethi A, Gregory S, Dell'Acqua F, Periche Thomas E, Simmons A, Murphy DG, Hodgins S, Blackwood NJ and Craig MC (2015) Emotional detachment in psychopathy: involvement of dorsal default-mode connections. *Cortex* **62**, 11–19.
- Sherman LE, Rudie JD, Pfeifer JH, Masten CL, McNealy K and Dapretto M (2014) Development of the default mode and central executive networks across early adolescence: a longitudinal study. *Developmental Cognitive Neuroscience* **10**, 148–159.
- Simpson EH and Balsam PD (2016) *Behavioral Neuroscience of Motivation*. Switzerland: Springer International Publishing.
- Sitaram R, Caria A, Veit R, Gaber T, Ruiz S and Birbaumer N (2014) Volitional control of the anterior insula in criminal psychopaths using real-time fMRI neurofeedback: a pilot study. *Frontiers in Behavioral Neuroscience* **8**, 344.
- Soderstrom H, Hultin L, Tullberg M, Wikkelso C, Ekholm S and Forsman A (2002) Reduced frontotemporal perfusion in psychopathic personality. *Psychiatry Research* **114**, 81–94.
- Sommer M, Sodian B, Döhnel K, Schwerdtner J, Meinhardt J and Hajak G (2010) In psychopathic patients emotion attribution modulates activity in outcome-related brain areas. *Psychiatry Research* **182**, 88–95.
- Soriano-Mas C, Hernández-Ribas R, Pujol J, Urretavizcaya M, Deus J, Harrison BJ, Ortiz H, López-Solà M, Menchón JM and Cardoner N (2011) Cross-sectional and longitudinal assessment of structural brain alterations in melancholic depression. *Biological Psychiatry* **69**, 318–325.
- Sundram F, Deeley Q, Sarkar S, Daly E, Latham R, Craig M, Raczek M, Fahy T, Picchioni M, UK AIMS Network, Barker GJ and Murphy DG (2012) White matter microstructural abnormalities in the frontal lobe of adults with antisocial personality disorder. *Cortex* **48**, 216–229.
- Tang Y, Long J, Wang W, Liao J, Xie H, Zhao G and Zhang H (2016) Aberrant functional brain connectome in people with antisocial personality disorder. *Scientific Reports* **6**, 26209.
- Tiihonen J, Rossi R, Laakso MP, Hodgins S, Testa C, Perez J, Repo-Tiihonen E, Vaurio O, Soininen H, Aronen HJ, Könönen M, Thompson PM and Frisoni GB (2008) Brain anatomy of persistent violent offenders: more rather than less. *Psychiatry Research* **163**, 201–212.
- Toivonen P, Könönen M, Niskanen E, Vaurio O, Repo-Tiihonen E, Seppänen A, Aronen HJ, Vanninen R, Tiihonen J and Laakso MP (2013) Cavum septum pellucidum and psychopathy. *The British Journal of Psychiatry* **203**, 152–153.
- Veit R, Flor H, Erb M, Hermann C, Lotze M, Grodd W and Birbaumer N (2002) Brain circuits involved in emotional learning in antisocial behavior and social phobia in humans. *Neuroscience Letters* **328**, 233–236.
- Veit R, Lotze M, Sewing S, Misenhardt H, Gaber T and Birbaumer N (2010) Aberrant social and cerebral responding in a competitive reaction time paradigm in criminal psychopaths. *Neuroimage* **49**, 3365–3372.
- Venables NC, Hall JR and Patrick CJ (2014) Differentiating psychopathy from antisocial personality disorder: a triarchic model perspective. *Psychological Medicine* **44**, 1005–1013.
- Veroude K, von Rhein D, Chauvin RJ, van Dongen EV, Mennes MJ, Franke B, Heslenfeld DJ, Oosterlaan J, Hartman CA, Hoekstra PJ, Glennon JC and Buitelaar JK (2016) The link between callous-unemotional traits and neural mechanisms of reward processing: an fMRI study. *Psychiatry Research* **255**, 75–80.
- Volkow ND, Tancredi LR, Grant C, Gillespie H, Valentine A, Mullani N, Wang GJ and Hollister L (1995) Brain glucose metabolism in violent psychiatric patients: a preliminary study. *Psychiatry Research* **61**, 243–253.
- Volman I, von Borries AK, Bulten BH, Verkes RJ, Toni I and Roelofs K (2016) Testosterone modulates altered prefrontal control of emotional actions in psychopathic offenders. *eNeuro* **3**, pii, ENEURO.0107-15.2016.
- Waller R, Dotterer HL, Murray L, Maxwell AM and Hyde LW (2017) White-matter tract abnormalities and antisocial behavior: a systematic review of diffusion tensor imaging studies across development. *Neuroimage Clinical* **14**, 201–215.
- Walters GD, Ermer E, Knight RA and Kiehl KA (2015) Paralimbic biomarkers in taxometric analyses of psychopathy: does changing the indicators change the conclusion? *Personality Disorders* **6**, 41–52.
- White SF, Brislin S, Sinclair S, Fowler KA, Pope K and Blair RJ (2013) The relationship between large cavum septum pellucidum and antisocial behavior, callous-unemotional traits and psychopathy in adolescents. *Journal of Child Psychology and Psychiatry* **54**, 575–581.
- Wolf RC, Pujara MS, Motzkin JC, Newman JP, Kiehl KA, Decety J, Kosson DS and Koenigs M (2015) Interpersonal traits of psychopathy linked to reduced integrity of the uncinate fasciculus. *Human Brain Mapping* **36**, 4202–4209.
- Yakovlev PI and LeCours AR (1967): The myelogenetic cycles of regional maturation of the brain. In Minkowski A (ed.), *Regional Development of the Brain in Early Life*. Oxford: Blackwell, pp. 3–70.
- Yang Y and Raine A (2009) Prefrontal structural and functional brain imaging findings in antisocial, violent, and psychopathic individuals: a meta-analysis. *Psychiatry Research* **174**, 81–88.

- Yang Y, Raine A, Lencz T, Bihrlé S, LaCasse L and Colletti P (2005a)** Volume reduction in prefrontal gray matter in unsuccessful criminal psychopaths. *Biological Psychiatry* **57**, 1103–1108.
- Yang Y, Raine A, Lencz T, Bihrlé S, Lacasse L and Colletti P (2005b)** Prefrontal white matter in pathological liars. *The British Journal of Psychiatry* **187**, 320–325.
- Yang Y, Raine A, Colletti P, Toga AW and Narr KL (2009a)** Abnormal temporal and prefrontal cortical gray matter thinning in psychopaths. *Molecular Psychiatry* **14**, 561–562.
- Yang Y, Raine A, Narr KL, Colletti P and Toga AW (2009b)** Localization of deformations within the amygdala in individuals with psychopathy. *Archives of General Psychiatry* **66**, 986–994.
- Yang Y, Raine A, Colletti P, Toga AW and Narr KL (2010)** Morphological alterations in the prefrontal cortex and the amygdala in unsuccessful psychopaths. *Journal of Abnormal Psychology* **119**, 546–554.
- Yang Y, Raine A, Joshi AA, Joshi S, Chang YT, Schug RA, Wheland D, Leahy R and Narr KL (2012)** Frontal information flow and connectivity in psychopathy. *The British Journal of Psychiatry* **201**, 408–409.
- Yildirim BO and Derksen JJ (2012)** A review on the relationship between testosterone and life-course persistent antisocial behavior. *Psychiatry Research* **200**, 984–1010.
- Yoder KJ, Harenski C, Kiehl KA and Decety J (2015)** Neural networks underlying implicit and explicit moral evaluations in psychopathy. *Translational Psychiatry* **5**, e625.