

Follicular dendritic cell sarcoma arising from the hypopharynx

CHRISTOS GEORGALAS, M.R.C.S., D.L.O., JEEVE KANAGALINGAM, M.R.C.S., D.L.O.,
ANDREW GALLIMORE, B.Sc., M.R.C.P., F.R.C.PATH., PAUL O'FLYNN, F.R.C.S. (ORL-HNS)

Abstract

Follicular dendritic cell (FDC) tumours have been described recently as malignant tumours arising from accessory cells of the lymph nodes. They are rare tumours with fewer than 70 cases occurring worldwide. They usually present in cervical or abdominal lymph nodes, with very few occurring extranodally. We present the first case of an FDC tumour to occur in the hypopharynx with simultaneous cervical node metastases. The pathology is discussed and the literature reviewed.

Key words: Sarcoma; Dendritic cells, Follicular; Hypopharynx

Introduction

Follicular dendritic cell (FDC) tumours are rare tumours, stemming from the dendritic accessory cells of B-cell follicles. They were first described in 1986 by Monda *et al.*¹ as occurring in lymph nodes, although since then they have been diagnosed in some other extra-nodal locations including the soft palate,² oral cavity and tonsils,³ gastrointestinal tract⁴ and liver.⁵ This is the first time, to our knowledge, that this rare tumour has been diagnosed as a primary tumour of the hypopharynx associated with metastatic lymph nodes presenting as a neck mass.

Case report

History

A 61-year-old male from Nigeria presented with a nine-month history of a neck mass and 'muffled' voice. An earlier biopsy performed abroad was inconclusive and he had been started on empirical antituberculous therapy. He had lost some weight although he was able to eat satisfactorily. On examination, a 9 cm × 8 cm mass was obvious encompassing levels 2, 3 and 4 cervical nodes. On flexible laryngoscopy, an extensive tumour was visualized arising from the hypopharynx. Direct laryngoscopy/pharyngoscopy performed a few days later under general anaesthesia confirmed the presence of a 4 cm × 5 cm exophytic tumour arising from the tongue base extending to the lateral pharyngeal wall and the pyriform fossa. The vocal folds and larynx were normal. The tumour was debulked transorally using a carbon dioxide (CO₂) laser. The neck mass was removed as part of a selective (levels 2–4) neck dissection. The final histological diagnosis for both specimens was follicular dendritic cell sarcoma.

Pathology

The tumour arising from the hypopharynx was a well-circumscribed lesion weighing approximately 41 grams. It

was composed of small spindle cells in a collagenous stroma. There was moderate to marked nuclear polymorphism, with abundant mitotic activity. There were numerous multinucleated cells, while a chronic inflammatory infiltrate of mainly lymphocytes was also present. The vascular pattern was haemangiopericytomatous. The appearances overall were most like those of a sarcoma. Immunostaining however was positive for CD21 and CD35, while CD30, CD15, CD45, CD3, CD20, CD34, S100 protein, HMB45, CAM5.2, EMA, desmin and SMA were not expressed by the tumour cells.

Discussion

Follicular dendritic cells are cells with extensive dendritic processes found in the B-cell areas (primary follicles and germinal centres) of lymphoid tissue. They are unrelated to the dendritic cells associated with T cells. Follicular dendritic cells have Fc and C3b receptors, but unlike other dendritic cells, they do not process or present antigen in a way that allows recognition by T cells. Instead, they hold antigen in the form of immune complexes on their surfaces for long periods and can present antigen to B cells during an immune response.⁶ In immunostaining, they are identified by the positivity for CD21, which recognizes the C3b receptor, and by positivity to CD35. Tumours arising from these cells were recently recognized and remain rare, with fewer than 60 patients reported worldwide in the English literature.

These tumours usually occur in young adults (age 22–66, with a mean age of 46), and have equal sex distribution. There is an association with Castleman's disease and Epstein-Barr virus (EBV) infection, with the virus genome present within the tumour cells. Clinically they usually present as painless, slow-growing cervical lymphadenopathy, with local symptoms when they present in other areas. These are, specifically, abdominal pain and distension in patients with abdominal masses or haemoptysis in those with mediastinal node involvement. Extranodal

From the Royal National Throat Nose and Ear Hospital, Gray's Inn Road, London, UK.

Accepted for publication: 8 January 2004.

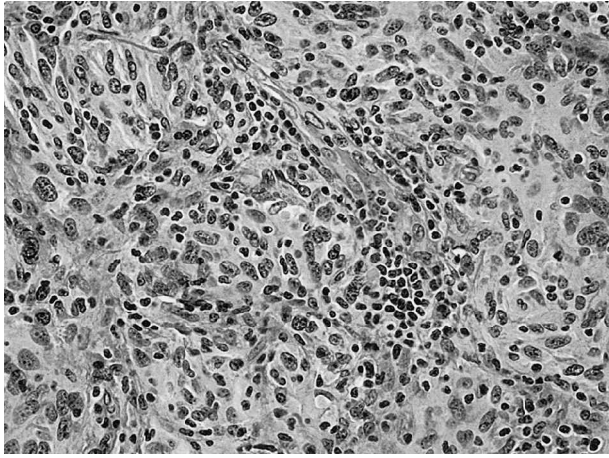


FIG. 1

Characteristic feature of perivascular cuffs of reactive lymphocytes and follicular dendritic tumour cells (H&E; ×200).

- Follicular dendritic cell tumours are rare and tend to present in the cervical or abdominal lymph nodes
- This paper presents a case arising from the hypopharynx
- This is the first reported case at this site

location however is rare, with fewer than 20 cases (six in the tonsil, five in the pharynx, two in the palate, five in the soft tissue, and one in the thyroid) described worldwide.⁷ As a result it can often be unrecognized or misdiagnosed as lymphoma, ectopic meningioma, malignant melanoma, malignant fibrous histiocytoma, large-cell lymphoma, synovial sarcoma (as was a differential diagnosis in our case) or even a tumour that is closely related, the interdigitating dendritic cell sarcoma. This non-lymphoid tumour of lymph nodes shows differentiation towards interdigitating dendritic cells, antigen-presenting cells that interact with the T cells (instead of the B cells in the case of the follicular dendritic cells) and stain negative for CD21 and CD35.

Microscopically, FDC sarcomas are composed of oval to spindle cells arranged in sheets or commonly in concentric whorls. In some cases there is a prominent vasculature and complete replacement of nodal architecture by tumour. The cell borders are ill-defined, resulting in a syncytial or multinucleated appearance. A characteristic feature of this tumour is the intimate association of tumour cells and small lymphocytes as well as the presence of perivascular cuffs of mature lymphocytes—a pattern similar to a chronic inflammatory infiltrate, as was the case in our patient (Figure 1). The diagnosis is usually made with the help of immunohistochemistry, although the features in light microscopy are usually highly suggestive.⁸ Recently it was suggested that the cytological features on aspirate from fine needle aspiration (FNA) could be almost pathognomonic for FDC.⁹

The FDC sarcomas are considered as low to intermediate grade neoplasms with a high incidence of local recurrence and occasional distant metastases to lung and liver.¹⁰ The numbers of patients are still quite small for meaningful conclusions, however, in 47 well-studied cases, 17 (36 per cent) developed local recurrences, 13 (28 per cent) metastatic disease and 10 (21 per cent) both. A study

of 17 patients¹¹ showed that factors associated with poor prognosis include tumour size more than 6 cm, nuclear pleomorphism, necrosis, high mitotic rate, intra-abdominal location and lack of adjuvant therapy. In the same study, of the 13 patients followed up for a median of three years, six had a local recurrence, six had metastasis and three died from the disease. Complete surgical excision appears to be the treatment of choice. Adjuvant therapy in the form of chemotherapy is probably indicated in tumours with adverse prognostic factors or incompletely excised. We discussed with our patient the current uncertainties and recommended chemotherapy, on the basis of adverse histological factors (large tumour, marked pleomorphism and high mitotic activity) with a diameter of 8 cm. However, he declined chemotherapy and currently remains on close follow up.

References

- 1 Monda L, Warnke R, Rosai J. A primary lymph node malignancy with features suggestive of dendritic reticulum cell differentiation. A report of 4 cases. *Am J Pathol* 1986;**122**:562–72
- 2 Araujo VC, Martins MT, Salmen FS, Araujo NS. Extranodal follicular dendritic cell sarcoma of the palate. *Oral Surg Oral Med Oral Pathol Oral Radiol Endod* 1999;**87**:209–14
- 3 Chan JK, Tsang WY, Ng CS, Tang SK, Yu HC, Lee AW. Follicular dendritic cell tumors of the oral cavity. *Am J Surg Pathol* 1994;**18**:148–57
- 4 Hollowood K, Stamp G, Zouvani I, Fletcher CD. Extranodal follicular dendritic cell sarcoma of the gastrointestinal tract. Morphologic, immunohistochemical and ultrastructural analysis of two cases. *Am J Clin Pathol* 1995;**103**:90–7
- 5 Shek TW, Ho FC, Ng IO, Chan AC, Ma L, Srivastava G. Follicular dendritic cell tumor of the liver. Evidence for an Epstein-Barr virus-related clonal proliferation of follicular dendritic cells. *Am J Surg Pathol* 1996;**20**:313–24
- 6 Herbert WJ, Wilkinson PC, Stott DI. *Dictionary of Immunology*. 4th edn. San Diego, CA: Academic Press, 1995
- 7 Biddle DA, Ro JY, Yoon GS, Yong YW, Ayala AG, Ordonez NG, *et al*. Extranodal follicular dendritic cell sarcoma of the head and neck region: three new cases, with a review of the literature. *Mod Pathol* 2002;**15**:50–8
- 8 Perez-Ordonez B, Rosai J. Follicular dendritic cell tumor: review of the entity. *Semin Diagn Pathol* 1998;**15**:144–54
- 9 Gaffney RL, Feddersen RM, Bocklage TJ, Joste NE. Fine needle aspiration cytology of follicular dendritic cell sarcoma. Report of a case with cytologic detection in an extranodal site. *Acta Cytol* 2000;**44**:809–14
- 10 Perez-Ordonez B, Erlandson RA, Rosai J. Follicular dendritic cell tumor: report of 13 additional cases of a distinctive entity. *Am J Surg Pathol* 1996;**20**:944–55
- 11 Chan JK, Fletcher CD, Nayler SJ, Cooper K. Follicular dendritic cell sarcoma. Clinicopathologic analysis of 17 cases suggesting a malignant potential higher than currently recognized. *Cancer* 1997;**79**:294–313

Address for correspondence:
Mr Jeeve Kanagalingam,
Specialist Registrar,
Royal National Throat Nose and Ear Hospital,
Gray's Inn Road,
London WC1X 8DA, UK.

Fax: +44 207 833 5518
E-mail: jeevekana@hotmail.com

C. Georgalas takes responsibility for the integrity of the content of the paper.

Competing interests: None declared