


Post-operative vestibular and equilibrium evaluation in patients with cholesteatoma-induced labyrinthine fistulas

Q Peng^{1,2}, K Liu^{1,2}, M Wang^{1,2}, C Zhou³, S Zhang^{1,2}, Y Liu^{1,2} and B Xie^{1,2} 

¹Department of Otolaryngology Head and Neck Surgery, Second Affiliated Hospital of Nanchang University, Nanchang, China, ²Jiangxi Biomedical Engineering Research Center for Auditory Research, Nanchang, China and ³Department of Otolaryngology, Shangrao Municipal Hospital, Shangrao, China

Main Article

Prof B Xie takes responsibility for the integrity of the content of the paper

Cite this article: Peng Q, Liu K, Wang M, Zhou C, Zhang S, Liu Y, Xie B. Post-operative vestibular and equilibrium evaluation in patients with cholesteatoma-induced labyrinthine fistulas. *J Laryngol Otol* 2024;**138**: 16–21. <https://doi.org/10.1017/S0022215123000671>

Accepted: 31 March 2023
First published online: 20 April 2023

Keywords:

Labyrinthine fistula; cholesteatoma; vertigo; equilibrium rehabilitation; hearing loss

Corresponding author:

Bingbin Xie;
Email: xiebb2013@163.com

Abstract

Objective. This study aimed to compare the pre- and post-operative vestibular and equilibrium functions of patients with cholesteatoma-induced labyrinthine fistulas who underwent different management methods.

Methods. Data from 49 patients with cholesteatoma-induced labyrinthine fistulas who underwent one of three surgical procedures were retrospectively analysed. The three management options were fistula repair, obliteration and canal occlusion.

Results. Patients underwent fistula repair ($n = 8$), canal occlusion ($n = 18$) or obliteration procedures ($n = 23$). Patients in the fistula repair and canal occlusion groups suffered from post-operative vertigo and imbalance, which persisted for longer than in those in the obliteration group. Despite receiving different management strategies, all patients achieved complete recovery of equilibrium functions through persistent efforts in rehabilitation exercises.

Conclusion. Complete removal of the cholesteatoma matrix overlying the fistula is reliable for preventing iatrogenic hearing deterioration due to unremitting labyrinthitis. Thus, among the three fistula treatments, obliteration is the optimal method for preserving post-operative vestibular functions.

Introduction

Labyrinthine fistula is a common complication of middle-ear cholesteatoma, with an incidence varying from 4 to 15 per cent.^{1–3} This is due to the gradually expanding destruction and progressive erosion of the bony structures of the labyrinth by epithelial lesions and the cholesteatoma matrix. The most susceptible site of fistula formation is the lateral semicircular canal, implicated in approximately 90 per cent of cases⁴ because of its anatomical proximity to the cholesteatoma. Because of the connection between the vestibular system and the cochlear, the symptoms directly attributable to a labyrinthine fistula are primary vestibular dysfunction⁵ and sensorineural hearing loss. Other symptoms include otorrhoea and otalgia, secondary to infection of the cholesteatoma and chronic otitis media.

The primary goal of labyrinthine fistula management is to attain a ‘safe’ ear. However, treating labyrinthine fistulas is controversial and challenging in light of the increased risk of iatrogenic sensorineural hearing loss and cholesteatoma recurrence. There are two general approaches⁶ for dealing with cholesteatoma overlying a labyrinthine fistula: (1) total removal of the cholesteatoma matrix with the repair of any ensuing labyrinthine defect; and (2) partial resection with residual matrix left through the canal wall down technique, and exteriorisation of the mastoid cavity.⁷

Most of the literature focuses on post-operative hearing preservation, which is the core source of debate regarding which strategy is the most appropriate for labyrinthine fistula management. Although the vestibular system is primarily affected by labyrinthine fistulas, resulting in many patients experiencing vertigo episodes, very few studies have focused on the functional status of the vestibular system in patients with a cholesteatoma-induced labyrinthine fistula.

The main purpose of this study was to systematically evaluate the pre- and post-operative vestibular function of patients with a cholesteatoma-induced labyrinthine fistula. The influence of the different management methods on vestibular function is also discussed.

Materials and methods

This study was a retrospective analysis of patients diagnosed with middle-ear cholesteatoma complicated by labyrinthine fistula development. After obtaining institutional review board approval from the Second Affiliated Hospital of Nanchang University (Nanchang, China), 49 patients with a labyrinthine fistula caused by middle-ear cholesteatoma underwent surgery at the Department of Otolaryngology Head and Neck Surgery at the Second Affiliated Hospital of Nanchang University between July 2016 and December 2020.

The following information was collected from the patients' records, via telephone interviews or questionnaires, up to March 2022: clinical symptoms, previous treatments, surgical procedures, pre- and post-operative hearing status, and vestibular and equilibrium functions.

The inclusion criteria consisted of: (1) age 18 years or older; (2) willingness and ability to provide written informed consent; and (3) a confirmed diagnosis of middle-ear cholesteatoma and complications of a labyrinthine fistula evaluated by a temporal bone high-resolution computed tomography scan pre-operatively, with intra-operative confirmation. The exclusion criteria were: (1) a diagnosis of petrous bone cholesteatoma; and (2) abnormal pre-operative semicircular canal function.

Hearing and vestibular and equilibrium function evaluation

Pure tone audiometry was performed to determine average air-conduction thresholds at 0.5, 1, 2 and 4 kHz, in order to evaluate patients' hearing. Post-operative evaluations were conducted at two time points: day 1 and 3 months post-operatively. Bone conduction thresholds on pure tone audiometry were evaluated to determine whether patients had iatrogenic sensorineural hearing loss caused by surgery. Hearing deterioration was defined as an increased bone conduction threshold on pure tone audiometry of 10 dB or more at two or more frequencies compared to pre-operative values.

Patients' vestibular function was evaluated using the video head impulse test pre- and post-operatively. The video head impulse test provides information about the vestibulo-ocular reflex gain and assists the clinician to quickly, safely and easily evaluate the three semicircular canals on both sides.

Equilibrium function was evaluated by the falling index scores obtained through the Tetrax Interactive Balance System (Sunlight Medical, Ramat Gan, Israel), which is a static posturography test consisting of four integrated but independent plates that measure postural sway in eight sensory conditions. The falling index represents the quantitative risk of falling, with a higher falling index score representing a greater possibility of falling.⁸

Surgical procedures

The standard canal wall down technique was performed through a post-auricular incision under general anaesthesia. The surgical procedures avoided dissection in the area proximal to the fistula until the cholesteatoma removal was completed elsewhere. The cholesteatoma matrix was meticulously removed from the fistula site without direct suctioning or suctioning near the fistula (Figure 1a). Endolymph leakage from the membranous fistula was noted in some patients, but direct aspiration was avoided. Complete removal of the cholesteatoma matrix from the fistula was a prerequisite before any manipulation of the fistula.

Three options were offered for fistula management: (1) fistula repair, which entailed placing a small patch of temporalis fascia or tragus perichondrium over the open fistula and covering it with Gelfoam; (2) canal occlusion, in which a small piece of soft tissue was filled into the semicircular canal through the fistula to block the membranous labyrinth tightly, and the fistula was sealed with bone wax to safeguard against perilymph leakage; and (3) obliteration, in which after placing the temporalis fascia or tragus perichondrium over the open fistula, an autograft bone paste was packed on the surface to fill in and narrow the mastoid cavity (Figure 1b).

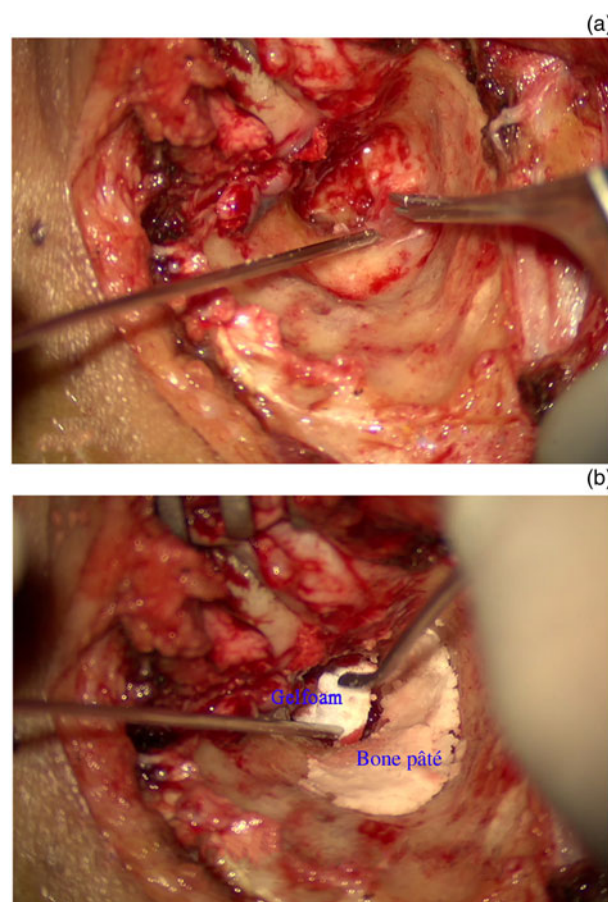


Figure 1. (a) Meticulous removal of the cholesteatoma matrix from the fistula site with a round knife, without suctioning directly or near the fistula. (b) Obliteration procedure with allograft bone paste. After placing the temporalis fascia or tragus perichondrium over the open fistula, an allograft bone paste was packed on the surface, filling in and narrowing the mastoid cavity.

Statistical analysis

Descriptive statistical analysis was utilised to record and compare pre- and post-operative hearing loss and vestibular function. In order to compare the equilibrium functions pre- and post-operatively, independent sample *t*-tests were used. Statistical significance was defined as a *p*-value of less than 0.05. All statistical tests were performed using SPSS Statistics for Windows, version 28.0 (IBM, Armonk, New York, USA).

Results and analysis

Patient characteristics

Forty-nine patients with a labyrinthine fistula caused by cholesteatoma were enrolled in the study (Table 1), consisting of 23 women and 26 men, with a median age of 46 (range, 22–79) years. All patients complained of hearing loss pre-operatively, including 18 (36.7 per cent) and 17 (34.7 per cent) with severe and profound hearing loss, respectively. Forty-seven patients (95.9 per cent) had experienced at least one vertigo episode; however, 41 patients (83.7 per cent) had normal vestibular function and only 15 patients (30.6 per cent) had a positive fistula test before surgery. Regarding fistula management, 8 patients underwent fistula repair, 18 underwent canal occlusion and 23 underwent obliteration procedures (Table 1).

Table 1. General characteristics of patients*

Characteristic	Value
Age (median (range); years)	46 (22–79)
Gender (n (%))	
– Male	26 (53.1)
– Female	23 (46.9)
Vertigo episode (n (%))	47 (95.9)
Degree of hearing loss (n (%))	49 (100.0)
– Severe hearing loss	18 (36.7)
– Profound hearing loss	17 (34.7)
Normal vestibular function (n (%))	41 (83.7)
Positive fistula test (n (%))	15 (30.6)
Strategy for fistula management (n (%))	
– Fistula repair	8 (16.3)
– Obliteration	23 (46.9)
– Canal occlusion	18 (36.7)

*Total n = 49

Table 2. Post-operative hearing evaluation*

Strategy for fistula management	Patients (n)	Hearing deterioration (cases, n (%)) [†]	
		Day 1	3 months
Fistula repair	7	0 (0)	5 (71.4)
Obliteration	16		1 (6.3)
Canal occlusion	9		2 (22.2)

*n = 32; 17 patients suffering from profound hearing loss pre-operatively were excluded. [†]All patients suffering with hearing deterioration experienced labyrinthitis post-operatively

Hearing evaluation

Excluding 17 patients with profound hearing loss pre-operatively, the hearing level was evaluated in the other 32 patients through pure tone audiometry (bone conduction thresholds) on the first day and at three months post-operatively. No patients suffered from hearing deterioration on the first day following surgery, but five patients in the fistula repair group, two in the occlusion group and one in the obliteration group experienced labyrinthitis during the post-operative period, with severe vertigo and profound hearing loss. These eight patients failed to undergo hearing restoration, and salvage treatment was arranged immediately, resulting in severe or profound hearing loss at three months post-operatively (Table 2). Patients who underwent fistula repair experienced significant deterioration in hearing (Figure 2).

Vestibular and equilibrium function evaluation

Of the 41 patients with normal vestibular function pre-operatively, 8 underwent fistula repair, 11 underwent canal occlusion and 22 had procedures that involved obliteration (Table 3). All patients in the fistula repair and canal occlusion groups suffered from vertigo and imbalance post-operatively. The vertigo symptoms persisted for a mean duration of 3.8 (range, 2–6) days and 2.2 (range, 1–7) days in the fistula repair and canal occlusion groups, respectively. Additionally, imbalance persisted for a mean duration of 26.5 (range, 14–32)

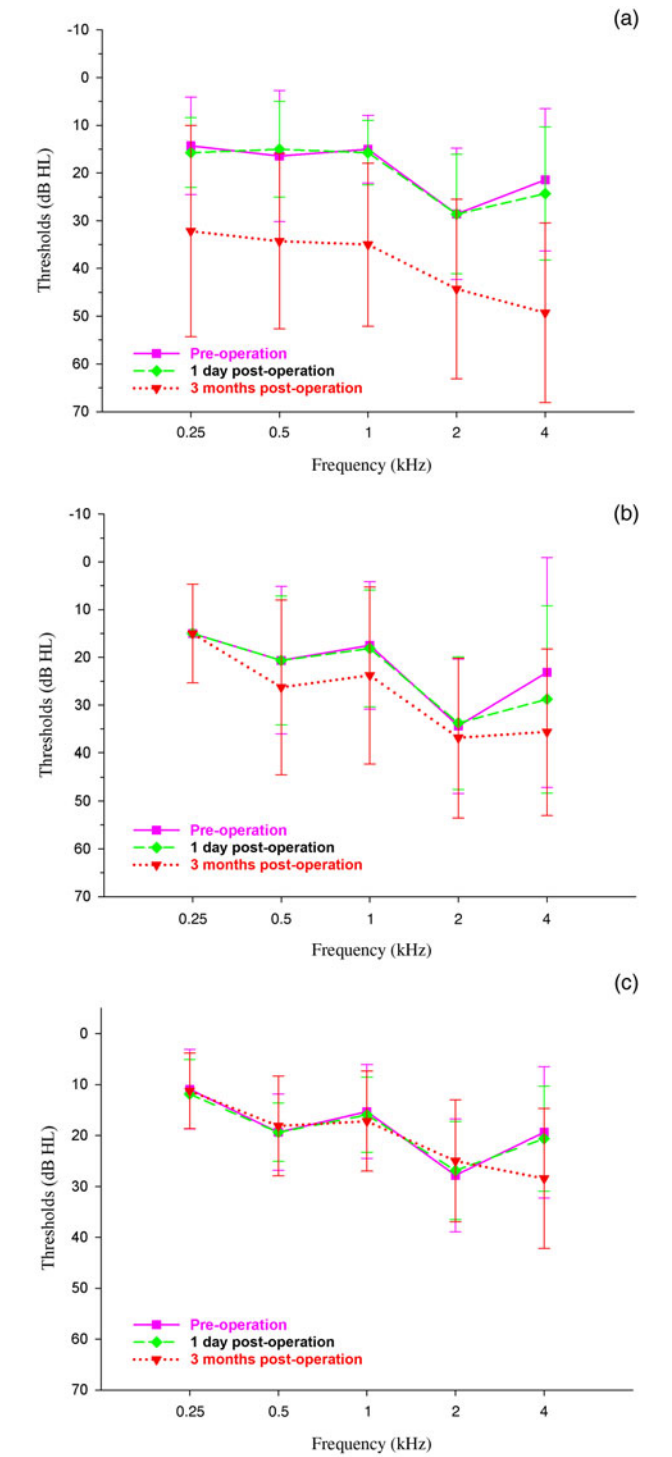


Figure 2. Pre- and post-operative hearing evaluation findings (average bone conduction hearing thresholds) for the patients in the three groups. (a) Fistula repair group: there was hearing deterioration in all frequencies at three months post-operatively. (b) Canal occlusion group: the average thresholds were slightly shifting, especially in the high frequency, at three months post-operatively. (c) Obliteration group: no patients had hearing deterioration at 1 day or 3 months post-operatively.

days and 18.6 (range, 13–33) days in the fistula repair and canal occlusion groups, respectively. In contrast, only one patient suffered from vertigo in the obliteration group, which lasted for 6 days; the patient presented with abnormal vestibular function 3 months after surgery, secondary to labyrinthitis. Six patients experienced imbalance for a mean duration of 10.3 (range, 3–22) days.

The results of the video head impulse test were analysed pre- and post-operatively (Table 4 and Figure 3). Only patients

Table 3. Post-operative vestibular function evaluation*

Strategy for fistula management	Patients (n)	Vertigo		Imbalance		Vestibular function deterioration†	
		Cases (n (%))	Duration (mean (range); days)	Cases (n (%))	Duration (mean (range); days)	Cases (n)	Ratio (%)
Fistula repair	8	8 (100)	3.8 (2–6)	8 (100)	26.5 (14–32)	5	62.5
Obliteration	22	1 (4.5)	6	6 (27.3)	10.3 (3–22)	1	4.5
Canal occlusion	11	11 (100)	2.2 (1–7)	11 (100)	18.6 (13–33)	11	100

*n = 41; 8 patients who suffered from abnormal vestibular function pre-operatively were excluded. †Video head impulse testing was conducted three months post-operatively

Table 4. Statistics of VOR gain values of lateral semicircular canal pre- and post-operation*

Strategy for fistula management	Patients (n)	VOR gain (mean (± SD))		p-value	Falling index score (mean (± SD))		
		Pre-operation	Post-operation		Pre-operation	Post-operation	p-value
Fistula repair	7	0.95 (0.035)	0.36 (0.422)	0.003†	31.57 (4.531)	34.43 (5.315)	0.336
Obliteration	21	0.97 (0.053)	0.96 (0.051)	0.583	34.50 (6.734)	36.59 (7.284)	0.34
Canal occlusion	11	0.96 (0.029)	0.14 (0.039)	<0.001†	36.82 (7.929)	40.64 (9.930)	0.353

*n = 39. †p < 0.05 is statistically significant; equal variances assumed (student's t-test). VOR = vestibulo-ocular reflex; SD = standard deviation

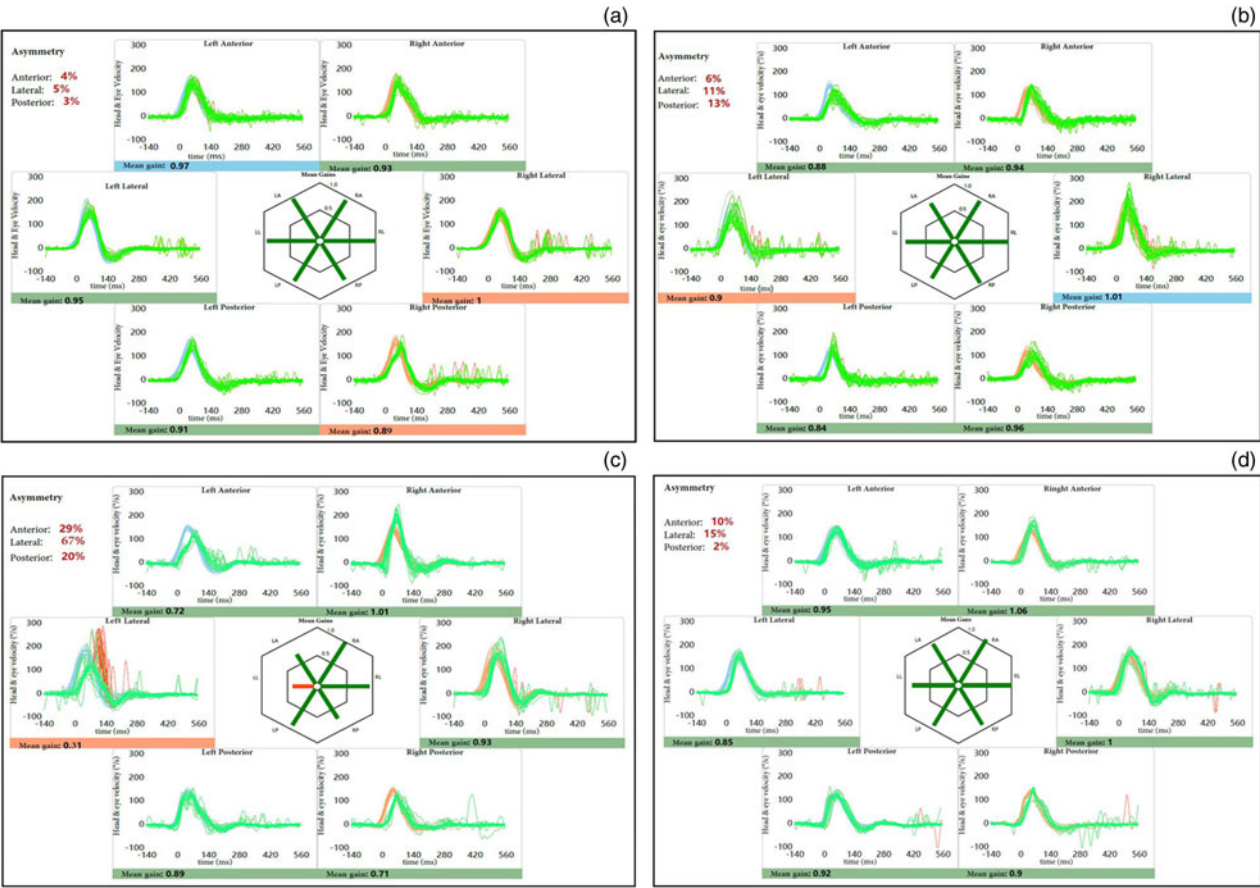


Figure 3. Pre- and post-operative video head impulse test results for patients in the different groups: (a) normal vestibular function pre-operatively, (b) fistula repair, (c) canal occlusion and (d) obliteration groups.

with exclusive lateral semicircular canal involvement and normal pre-operative vestibulo-ocular reflex values were included in this analysis.

The falling index scores obtained through the Tetrax Interactive Balance System were used to evaluate the equilibrium function of the patients pre-operatively and at three months post-operatively (Table 4). A falling index score of

36 or lower indicates normal equilibrium function. None of the patients experienced pre-operative disequilibrium caused by vestibular dysfunction. Although the average falling index scores were higher than 36 in the group with canal occlusion following surgery, none of the patients complained of imbalance, and there were no significant differences in falling index scores between the groups pre- and post-operatively.

All patients underwent different management strategies for the fistula, and achieved complete recovery of equilibrium functions through persistent efforts in rehabilitation exercises.

Discussion

A labyrinthine fistula is a common complication of cholesteatoma, reported to be present in 5–10 per cent of cases.² The lateral semicircular canal is the most vulnerable site, implicated in approximately 90 per cent of cases. The promontory is affected in approximately 8 per cent of cases, the superior semicircular canal in 6 per cent and the posterior semicircular canal in 2 per cent. Additionally, fistulas are found in multiple locations in about 10 per cent of cases.^{2,4,9} The perilymph flow is disturbed by the ‘third window’ caused by the fistula. The resultant excitatory or inhibitory asymmetry in both sides of the vestibular system causes vestibular dysfunction, such as vertigo or imbalance.

The optimal strategy for labyrinthine fistula management is still debatable, and is influenced by the location, size and type of fistula caused by cholesteatoma. However, the primary aim of all management strategies is to eradicate the cholesteatoma matrix and repair the fistula to obtain a safe ear, while preserving hearing and vestibular function. Many early studies suggested that partial resection with residual matrix left overlying the fistula through the canal wall down technique may prevent labyrinthine damage.^{10,11} However, criticisms of these strategies exist because of the risk of delayed sensorineural hearing loss caused by the potentially pernicious environment of an infected open mastoid cavity and the residual matrix.^{7,12} Alternatively, one-stage complete resection of the cholesteatoma matrix on the fistula has been recommended by some authors because of effective disease control and long-term hearing preservation,^{13,14} in which the hearing outcomes were independent of complete matrix removal from the top of the fistula post-operatively.⁷

Building on these recommendations, the results of our study, which has a level of evidence of 3, demonstrate that a one-stage complete resection of the matrix on the fistula was safe and that the surgical technique itself did not result in iatrogenic sensorineural deafness, which is a complication in patients with cholesteatoma and a labyrinthine fistula.^{14,15} Our results also highlight that different management methods for a labyrinthine fistula after total removal of the cholesteatoma matrix may result in different hearing outcomes at three months post-surgery. Patients in the group that underwent exclusive fistula repair were the most vulnerable to hearing deterioration (71.4 per cent), presumably due to the unremitting labyrinthitis that developed post-operatively, resulting from a thin monolayer fascia between the labyrinth and the sustaining open cavity. Our findings demonstrate that obliteration produced optimal results compared with fistula repair and canal occlusion.

Vertigo episodes are the main complaints of patients with a labyrinthine fistula. In this study, 83.7 per cent of patients presented normal vestibular function based on pre-operative video head impulse testing. In these cases, vestibular function preservation was a separate concern for surgeons. Patients who underwent fistula repair with fascia still had a ‘third window’ on the affected canal without bony coverage. This uncovered ‘third window’ left patients with persistent dizziness or vertigo due to suctioning, wind exposure or intense sound stimulation, sometimes resulting in an unresponsive labyrinth.

However, in the occlusion and obliteration groups, the labyrinth was completely separated from the persistent open cavity, preventing hearing deterioration and chronic vertigo due to unremitting labyrinthitis and the uncovered ‘third window’. However, the semicircular canal function was sacrificed in the occlusion group. Our results suggest that obliteration with autograft bone paste after completely removing the cholesteatoma over the labyrinth is a suitable management strategy for relieving vertigo or dizziness, which is consistent with current literature.¹⁶ Furthermore, in the obliteration group, most patients achieved perfectly preserved canal function, and experienced less fatigue, fewer periods of vertigo, faster recovery of equilibrium function and a lower rate of post-operative labyrinthitis or hearing exteriorisation.

Disequilibrium is a common concomitant symptom of vertigo in patients with a cholesteatoma-induced labyrinthine fistula prior to compensation of vestibular function, which may negatively affect an individual’s quality of life, such as performing activities of daily living, studying and working.¹⁷ Disequilibrium caused by vestibular failure in patients with a labyrinthine fistula is generally linked to bacterial toxins, host cytokines, inflammatory mediators and/or bacteria that may directly invade the inner ear through the fistula, causing labyrinthitis with the coexistence of otitis media.¹⁸ Alternatively, it may be due to the disturbance of fluids in the labyrinth causing the ‘third window’ in the semicircular canals. Owing to the use of antibiotics or the fistula being packed by the cholesteatoma, most patients achieve complete recovery or quickly compensate for vestibular function.¹⁹ In such cases, preserving undefective vestibular function is essential post-operatively.

- Labyrinthine fistulas are common complications of middle-ear cholesteatomas
- Hearing loss and vertigo are the main complaints of labyrinthine fistula patients, but most (83.7 per cent) had normal vestibular function
- Complete and meticulous removal of the cholesteatoma matrix overlying the fistula is safe and necessary
- Obliteration after complete removal of the cholesteatoma matrix is recommended to prevent hearing deterioration and preserve vestibular function
- Persistent efforts to perform equilibrium rehabilitation exercises are mandatory for functional recovery

In this study, 96 per cent of the patients had experienced vertigo, but 83.7 per cent had normal video head impulse test results and falling index scores of 36 or lower pre-operatively. These data demonstrate that most patients with a labyrinthine fistula generally presented normal pre-operative equilibrium function. While all the patients in our study achieved complete equilibrium recovery (compensation), the canal occlusion group sacrificed ipsilateral vestibular function, a very adverse post-operative complication. However, patients in the obliteration group achieved an optimal prognosis in preserving both hearing and vestibular function.

Conclusion

Complete and meticulous removal of the cholesteatoma matrix overlying the fistula is a safe and effective procedure for preserving hearing post-operatively. In order to restore or preserve the vestibular function post-operatively, it is critical to only remove the fistula after total resection of the matrix. Fistula repair using the temporalis fascia or tragus perichondrium may result in a ‘third window’, leaving patients at risk of persistent vertigo, dizziness or secondary hearing deterioration. Canal occlusion

eliminates the ‘third window’, but canal function is sacrificed in these patients. Of these three procedures, obliteration is recommended to eliminate the ‘third window’ entirely, thus preventing post-operative hearing deterioration from unremitting labyrinthitis and preserving vestibular function. Additionally, persistent efforts to perform equilibrium rehabilitation exercises are mandatory for functional recovery.

Acknowledgements. We would like to thank Editage (www.editage.cn) for the English language editing. This work was supported by grants from the National Natural Science Foundation of China (grant number: 82160216), the Natural Science Foundation of Jiangxi Province (grant number: 20202BABL206065), and the Key Research and Development Program of Jiangxi Province (grant number: 20181BBG78013).

References

- 1 Motegi M, Yamamoto Y, Akutsu T, Yamauchi H, Kurihara S, Takahashi M *et al.* Imaging analysis for cholesteatoma extension to the perilymphatic space in labyrinth fistulae. *Laryngoscope* 2020;**131**:E1301–7
- 2 Copeland BJ, Buchman CA. Management of labyrinthine fistulae in chronic ear surgery. *Am J Otolaryngol* 2003;**24**:51–60
- 3 Prasad SC, Shin SH, Russo A, Di Trapani G, Sanna M. Current trends in the management of the complications of chronic otitis media with cholesteatoma. *Curr Opin Otolaryngol Head Neck Surg* 2013;**21**:446–54
- 4 Meyer A, Bouchetemple P, Costentin B, Dehesdin D, Lerosey Y, Marie JP. Lateral semicircular canal fistula in cholesteatoma: diagnosis and management. *Eur Arch Otorhinolaryngol* 2016;**273**:2055–63
- 5 Jeong H, Lee DH, Shin JE, Kim CH. Positional nystagmus in middle ear cholesteatoma with labyrinthine fistula. *Med Hypotheses* 2020;**144**:110223
- 6 Basu S, Hamilton J. Treatment using diffuse laser energy of cochlear and vestibular fistulas caused by cholesteatoma. *J Laryngol Otol* 2019;**133**:102–5
- 7 Lim J, Gangal A, Gluth MB. Surgery for cholesteatomatous labyrinthine fistula. *Ann Otol Rhinol Laryngol* 2017;**126**:205–15
- 8 Song YB, Chun MH, Kim W, Lee SJ, Yi JH, Park DH. The effect of virtual reality and tetra-ataxiometric posturography programs on stroke patients with impaired standing balance. *Ann Rehabil Med* 2014;**38**:160–6
- 9 Albu S, Amadori M, Babighian G. Predictors of hearing preservation in the management of labyrinthine fistulas positioned on the semicircular canals. *Ann Otol Rhinol Laryngol* 2013;**122**:529–34
- 10 Freeman P. Fistula of the lateral semicircular canal. *Clin Otolaryngol Allied Sci* 1978;**3**:315–21
- 11 Ritter FN. Chronic suppurative otitis media and the pathologic labyrinthine fistula. *Laryngoscope* 1970;**80**:1025–35
- 12 Vrabec JT. Imaging of labyrinthine fistula after repair with bone pate. *Laryngoscope* 2018;**128**:1643–8
- 13 Rah YC, Han WG, Joo JW, Nam KJ, Rhee J, Song JJ *et al.* One-stage complete resection of cholesteatoma with labyrinthine fistula: hearing changes and clinical outcomes. *Ann Otol Rhinol Laryngol* 2018;**127**:241–8
- 14 Westerhout SF, Straatman LV, Dankbaar JW, Thomeer H. Labyrinthine fistulas: surgical outcomes and an additional diagnostic strategy. *Am J Otolaryngol* 2022;**43**:103441
- 15 Pace A, Milani A, Messineo D, Rossetti V, Cocuzza S, Maniaci A *et al.* Labyrinthine fistula in cholesteatoma patients: outcomes of partial labyrinthectomy with ‘underwater technique’ to preserve hearing. *Front Neurol* 2022;**13**:804915
- 16 Djalilian H, Borrelli M, Desales A. Cholesteatoma causing a horizontal semicircular canal fistula. *Ear Nose Throat J* 2021;**100**:888–91S
- 17 Hall CD, Herdman SJ, Whitney SL, Anson ER, Carender WJ, Hoppes CW *et al.* Vestibular rehabilitation for peripheral vestibular hypofunction: an updated clinical practice guideline from the Academy of Neurologic Physical Therapy of the American Physical Therapy Association. *J Neurol Phys Ther* 2022;**46**:118–77
- 18 Jang CH, Park SY, Wang PC. A case of tympanogenic labyrinthitis complicated by acute otitis media. *Yonsei Med J* 2005;**46**:161–5
- 19 McDonnell MN, Hillier SL. Vestibular rehabilitation for unilateral peripheral vestibular dysfunction. *Cochrane Database Syst Rev* 2015;**1**:CD005397