

Pathology in Focus

A parapharyngeal myxoid liposarcoma

JOHANNES J. FAGAN, F.C.S.(SA), EUGENE N. MYERS, M.D., LEON BARNES, M.D.

Abstract

We present a case of a parapharyngeal space myxoid liposarcoma. This case highlights the importance of wide surgical resection margins, and the difficult histological diagnosis.

Key words: Head and neck neoplasms; Liposarcoma

Case report

In December 1981, a 74-year-old man presented with a one-month history of a painless mass in the right parapharyngeal space which caused medial displacement of the tonsil and soft palate (Figure 1). Past medical history was noncontributory. Computerized tomography (CT) scan with contrast revealed a mostly lucent, irregularly enhancing mass both deep and inferior to the angle of the mandible. It was separate from the parotid gland, and the skull base was not involved. The tumour was excised through a transverse incision in a cervical skin crease. The submandibular triangle was dissected, and the submandibular gland retracted anteriorly. The digastric muscle was divided to improve access to the parapharyngeal space, and the tumour removed by blunt and sharp dissection. The tumour measured $7 \times 5 \times 4$ cms, was lobulated, had a cystic quality, and was surrounded by a smooth, transparent intact capsule. Pathologically it had been completely excised, and a histological diagnosis of a neurofibroma was made (Figure 2).

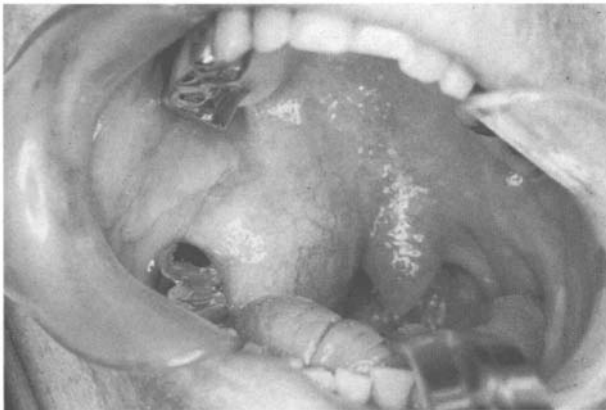

FIG. 1

Liposarcoma in the parapharyngeal space causing medial displacement of the right tonsil.

In March 1987 (five years following the previous surgery) the patient presented with a 3×2 cm mobile mass in the subcutaneous tissues, just inferior to the scar from the initial operation. The mass was excised through the previous incision, and a histological diagnosis of recurrent neurofibroma was made (Figure 3). Two soft cylindrical projections from the main tumour, measuring 7 mm and 4 mm and with a diameter of 1 mm were noted.

In May 1988 (six and a half years following the initial surgery) the tumour again recurred just inferior to the original incision in the neck. As local recurrence was considered to be unusual for a neurofibroma, the prior histology was reviewed.

The initial tumour was again diagnosed as a neurofibroma (Figure 2), but the first recurrence was reclassified as a malignant schwannoma (Figure 3). The second recurrence, measuring $6 \times 3.5 \times 2$ cm, was resected. It was circumscribed and histologically composed of numer-

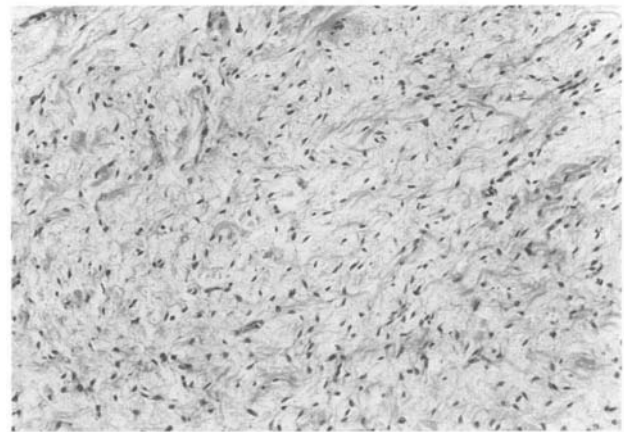


FIG. 2

Tumour first resected in 1981, composed of benign-appearing, short, spindled cells in a myxoid background and diagnosed as a neurofibroma (H & E; $\times 150$).

From the Departments of Otolaryngology* and Pathology†, University of Pittsburgh School of Medicine, Pittsburgh, Pennsylvania, USA.

Accepted for publication: 8 December 1998.

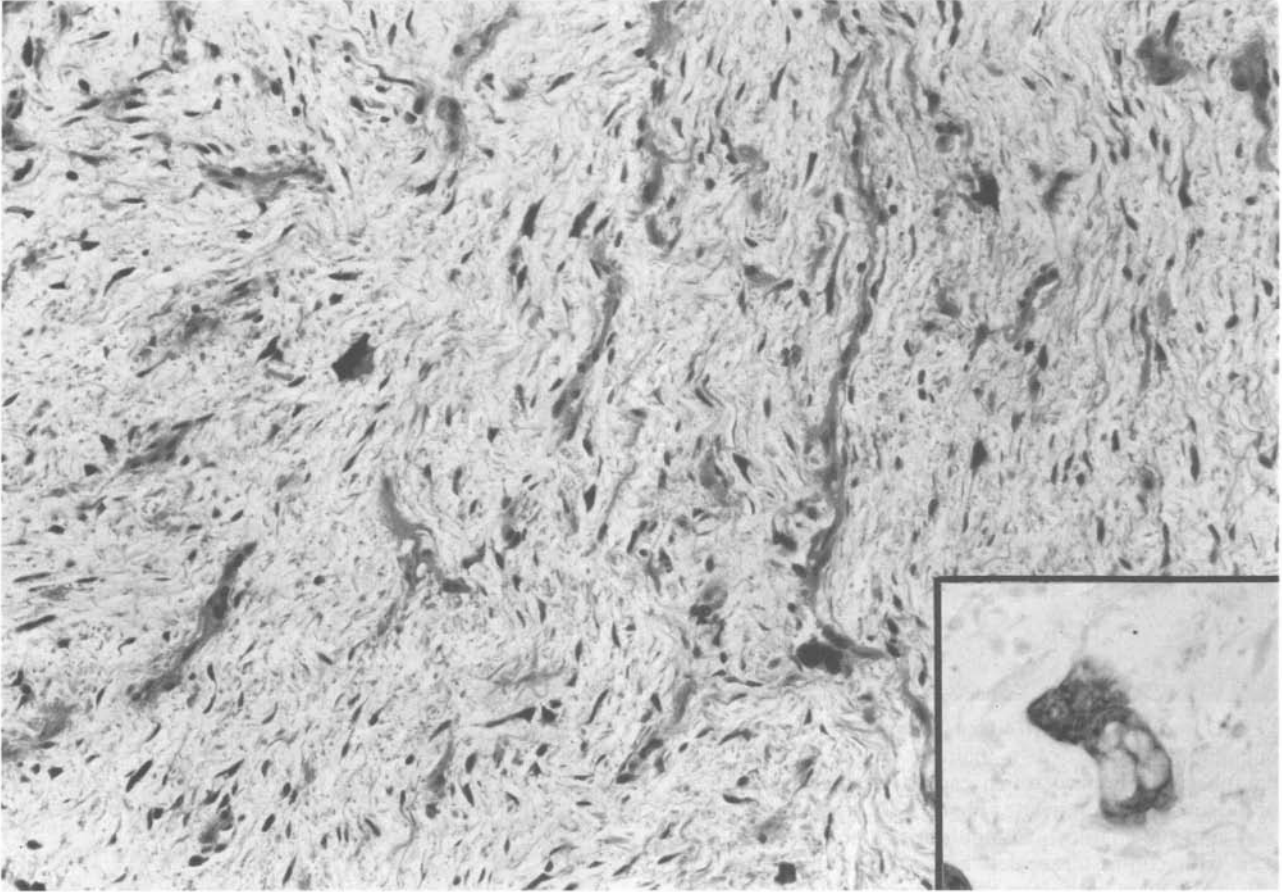


FIG. 3

First recurrence of the tumour in 1987. The tumour was initially diagnosed as a recurrent neurofibroma, and on subsequent review as a malignant schwannoma. However, final review showed a few scattered lipoblasts (insert) establishing the correct diagnosis of liposarcoma (H & E; $\times 150$; insert $\times 400$).

ous signet ring lipoblasts in an abundant myxoid matrix, with a delicate plexiform capillary vasculature (Figure 4). Pleomorphism was present, but mitotic figures were rarely seen. The tumour invaded surrounding skeletal muscle, and extended to the margin of the resection. A diagnosis of myxoid spindle cell liposarcoma was made. Because of the presence of numerous lipoblasts, a second review of the previous histology was done, and revealed subtle foci of lipoblasts in both previous specimens. A revised diagnosis of liposarcoma for all three specimens was made (Figures 2 and 3). The right lateral neck was irradiated (electron beam, 5600R). A month after completion of the radiotherapy, a 2×2 cm intraoral mass at the posterior-most aspect of the alveolar ridge was detected, and treated with brachytherapy (Ir-192 implants).

In February 1989 (seven years after the initial surgery) the tumour recurred at the anterior border of the sternocleidomastoid muscle. A $2.5 \times 2 \times 1$ cm tumour was excised. Histologically it was a myxoid liposarcoma, and invasion of skeletal muscle again was noted (Figure 5). Post-operative radiotherapy (cobalt, 5600R) was administered to the anterior and posterior neck, and a 400R electron beam boost given to the surgical site.

In June 1990, (eight and a half years after initial surgery), the tumour recurred in the mid-jugular region and was resected by means of a type 1 modified neck dissection. It measured $3.2 \times 2.5 \times 2.2$ cm, appeared circumscribed, and was again diagnosed a myxoid liposar-

coma with areas of possible dedifferentiation (Figure 6). Margins of resection were clear, and there was no evidence of lymphatic metastasis.

At last follow-up in September 1995 (five years and three months after the neck dissection) the patient remains clear of disease.

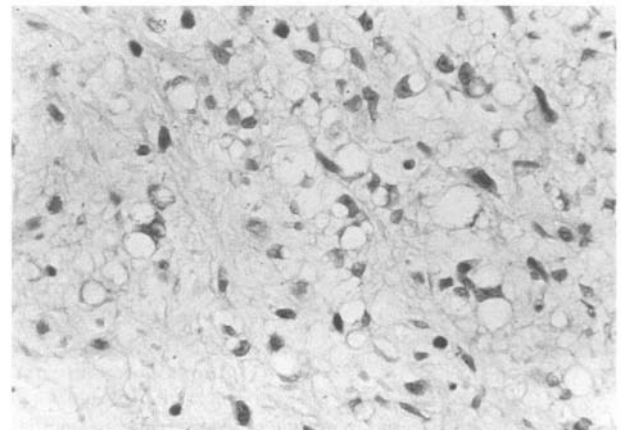


FIG. 4

Microscopic appearance of second recurrence in 1988. Note the numerous signet ring lipoblasts and myxoid matrix (H & E; $\times 400$).

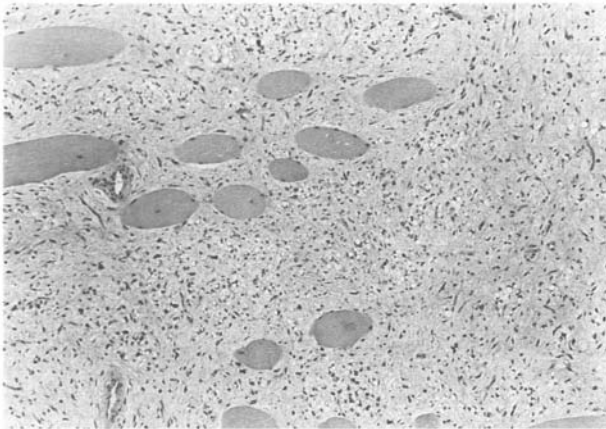


FIG. 5

Microscopic appearance of third recurrence in 1989. Note the spindle cells and signet ring lipoblasts infiltrating skeletal muscle (H & E; $\times 100$).

Discussion

Liposarcomas are among the most common of adult soft-tissue sarcomas (Pack and Pierson, 1954; Suit *et al.*, 1975; Patel *et al.*, 1994), yet they rarely occur in the head and neck (McCulloch *et al.*, 1992). In a review of liposarcoma of the head and neck in the English literature between 1911 and 1990, McCulloch *et al.* (1992) identified only 76 reported cases, of which two tumours were located in the parapharyngeal space.

The majority of liposarcomas occur between the fourth and sixth decades of life, and there is a male preponderance (Pack and Pierson, 1954; Brasfield and Das Gupta, 1970; Spittle *et al.*, 1970; McCulloch *et al.*, 1992). Liposarcomas do not develop from pre-existing lipomas (Batsakis *et al.*, 1980; Patel *et al.*, 1994), but appear to originate from primitive mesenchymal cells (Ashley, 1978; Patel *et al.*, 1994). They are classified into four histological types: myxoid, round cell, well-differentiated and pleomorphic (Batsakis *et al.*, 1980). Myxoid liposarcomas constitute 40–50 per cent of liposarcomas, are found in adults, and have a peak incidence in the fifth decade (Patel *et al.*, 1994).

Liposarcomas generally behave in accordance with the histological type (Saunders *et al.*, 1979; McCulloch *et al.*, 1992; Patel *et al.*, 1994). Enzinger and Winslow (1962) reported five year survivals of 85 per cent for well-differentiated, 77 per cent for myxoid, 21 per cent for pleomorphic and 18 per cent for round cell liposarcomas. Similar patterns of survival have been noted in other studies (McCulloch *et al.*, 1992). Local recurrence rates of 53 per cent for well-differentiated, 53 per cent for myxoid, 73 per cent for pleomorphic and 85 per cent round cell liposarcomas were reported by Enzinger and Winslow (1962). In McCulloch's review (1992), none of the myxoid tumours in the head and neck recurred locally. This was probably a reflection of the adequate surgical margins attained in this group of patients. The probable reasons why our patient with the myxoid liposarcoma had four local recurrences are that the tumour location precluded adequate surgical soft tissue margins, and that the incorrect

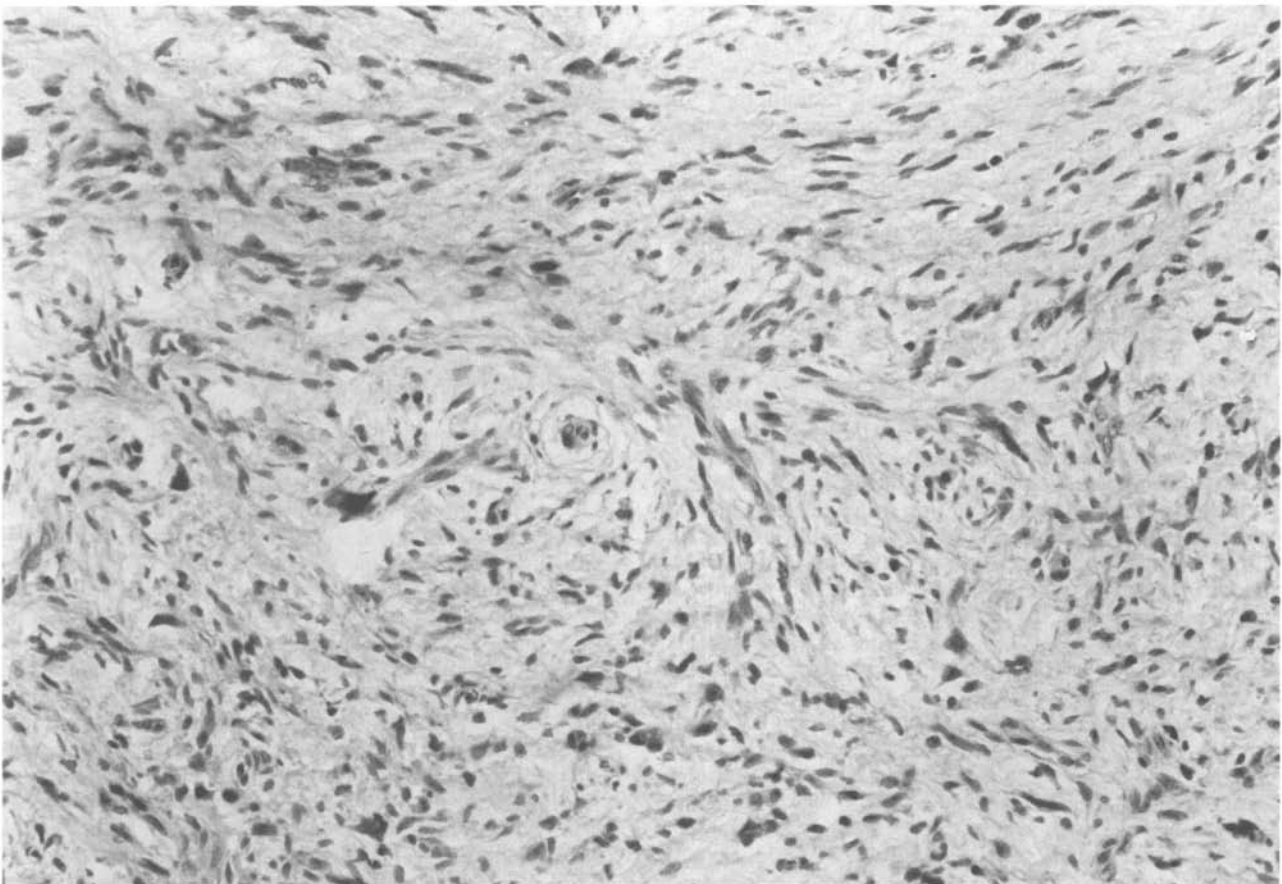


FIG. 6

Microscopic appearance of fourth recurrence. Although the tumour was still obviously a liposarcoma, it contained small areas shown in this photograph reminiscent of a malignant fibrous histiocytoma suggesting "dedifferentiation" (H & E; $\times 200$).

initial pathological diagnoses of a benign tumour prompted the surgeon to perform local excisions with narrow margins.

Regional nodal metastases are rare with liposarcoma (Spittle *et al.*, 1970; McCulloch *et al.*, 1992). McCulloch *et al.* (1992) identified only one case of lymphatic metastasis in a review of liposarcomas of the head and neck. Distant metastases occur mainly in high grade tumours, and metastatic sites include lung, brain, liver, spine and kidney (McCulloch *et al.*, 1992).

Liposarcomas are best treated by wide local excision (Brasfield and Das Gupta, 1970; Saunders *et al.*, 1979; Otte and Kleinsasser, 1981; McCulloch *et al.*, 1992; Zheng and Wang, 1994). McCulloch *et al.* (1992) reported an 80 per cent local or distant recurrence rate when excision was incomplete, as opposed to 17 per cent when excision was complete. Even though liposarcomas may appear encapsulated, the borders are always infiltrating (Otte and Kleinsasser, 1981), and the main tumour may be surrounded by satellite nodules (Ashley, 1978; Menown *et al.*, 1992). In our patient, muscle infiltration was noted on two occasions, and the first tumour recurrence had two cylindrical projections from the main tumour mass. Liposarcoma of the parapharyngeal space present a problem in surgical management as the anatomy of the parapharyngeal space precludes a wide local excision. A similar problem may be encountered elsewhere in the head and neck when tumours are in close proximity to important vascular or neural structures.

Liposarcomas are radiosensitive tumours (Stout, 1944; Pack and Pierson, 1954; Brasfield and Das Gupta, 1970; Spittle *et al.*, 1970; Suit *et al.*, 1975; Saunders *et al.*, 1979; Otte and Kleinsasser, 1981; McCulloch *et al.*, 1992; Menown *et al.*, 1992). This applies in particular to the myxoid (Pack and Pierson, 1954; Brasfield and Das Gupta, 1970; Menown *et al.*, 1992) and differentiated (Otte and Kleinsasser, 1981) subtypes. Adjuvant radiotherapy in conjunction with local excision should be considered when anatomical considerations preclude wide excision, and when radical surgery would result in severe cosmetic and/or functional deficits.

There is not much data regarding the use of chemotherapy, but doxorubicin and dacarbazine-based chemotherapy has been shown to be effective in the treatment of advanced myxoid liposarcoma (McCulloch *et al.*, 1992; Patel *et al.*, 1994).

Conclusions

Wide local excision is the mainstay of treatment of liposarcoma arising in the head and neck. If the initial surgical margins are inadequate, then the surgeon should perform, where possible, a second surgical resection to

attain wide margins. When the anatomical location of the tumour precludes adequate surgical margins, adjuvant radiotherapy should be considered.

References

- Ashley, D. J. B. (1978) Liposarcoma. In *Evan's Histological Appearances of Tumours*, 4th Edition. Churchill Livingstone, Edinburgh, London, New York, p. 70.
- Batsakis, J. G., Regezi, J. A., Rice, D. H. (1980) The pathology of head and neck tumours: Fibroadipose tissue and skeletal muscle, Part 8. *Head and Neck Surgery* **3**: 145–168.
- Brasfield, R. D., Das Gupta, T. K. (1970) Liposarcoma. *Ca: A Cancer Journal for Clinicians* **20**: 3–8.
- Enzinger, F. M., Winslow, D. J. (1962) Liposarcoma: a study of 103 cases. *Virchows Archives* **335**: 367–388.
- McCulloch, T. M., Makielski, K. H., McNutt, M. A. (1992) Head and neck liposarcoma. A histopathologic reevaluation of reported cases. *Archives of Otolaryngology – Head and Neck Surgery* **118**: 1045–1049.
- Menown, I. B. A., Liew, S. H., Napier, S. S., Primrose, W. J. (1992) Retro-pharyngeal liposarcoma. *Journal of Laryngology and Otolaryngology* **106**: 469–471.
- Pack, G. T., Pierson, J. C. (1954) Liposarcoma. A study of 105 cases. *Surgery* **36**: 687–711.
- Patel, S. R., Burgess, M. A., Plager, C., Papadopolous, N. E., Linke, K. A., Benjamin, R. S. (1994) Myxoid liposarcoma: Experience with chemotherapy. *Cancer* **74**: 1265–1269.
- Otte, Th., Kleinsasser, O. (1981) Liposarcoma of the head and neck. *Archives of Otorhinolaryngology* **232**: 285–291.
- Saunders, J. R., Jaques, D. A., Casterline, P. F., Percarpio, B., Goodloe, S. (1979) Liposarcomas of the head and neck. A review of the literature and addition of four cases. *Cancer* **43**: 162–168.
- Spittle, M. F., Newton, K. A., MacKenzie, D. H. (1970) Liposarcoma. A review of 60 cases. *British Journal of Cancer* **24**: 696–704.
- Stout, A. P. (1944) Liposarcoma – The malignant tumour of lipoblasts. *Annals of Surgery* **119**: 86–107.
- Suit, H. D., Russell, W. O., Martin, R. G. (1975) Sarcoma of soft tissue: Clinical and histopathologic parameters and response to treatment. *Cancer* **35**: 1478–1483.
- Zheng, J-W., Wang, Y. (1994) Liposarcoma in the oral and maxillofacial region: An analysis of 10 consecutive patients. *Journal of Oral and Maxillofacial Surgery* **52**: 595–598.

Address for correspondence:

E. N. Myers, M.D.,
Department of Otolaryngology,
University of Pittsburgh School of Medicine,
The Eye and Ear Institute Building,
Suite 500,
200 Lothrop Street,
Pittsburgh, PA, 15213,
USA.

Fax: (412)-647-2080