

Indium¹¹¹ pentetreotide single photon emission computed tomography (In¹¹¹ pentetreotide SPECT): a new technique to evaluate somatostatin receptors in chordomas

STEFANO DI GIROLAMO, MD, FABRIZIO OTTAVIANI, MD, ROBERTO FLORIS, MD*, ERNESTO BRUNO, MD, BIANCA NAPOLITANO, MD, ORAZIO SCHILLACI, MD†

Abstract

Chordomas are rare neoplasms originating along the neuraxis. Although they do not usually show cytological atypia, metastases have been reported in 30 per cent of cases. Survival rates in cases of skull base locations are low, and local recurrence is common after local excision. Radiation therapy is used in post-operative treatment and proton radiation therapy as the primary treatment. In the present paper we present the case of a 50-year-old Caucasian man affected by chordoma of the clivus, with liver and chest metastases, relapsed after several surgical local excisions, to discuss improvements in therapeutic and imaging techniques. Indium¹¹¹ (In¹¹¹) pentetreotide single photon emission computed tomography (SPECT) was employed to assess the presence of somatostatin receptors and to treat the tumour with radiolabelled Y⁹⁰-DOTA-lanreotide. Imaging, performed 2 months afterwards, showed stable disease in the lungs but a local progression in the metastases, in comparison with pre-treatment uptake. These data suggest the usefulness of radiolabelled somatostatin analogues in the diagnosis and therapy of chordomas.

Key words: Chordoma; Indium; Somatostatin; Computed Tomography

Introduction

Chordomas are rare neoplasms arising from embryonic notochordal remnants and comprise less than 1 per cent of intracranial neoplasms. They represent only 3 per cent of all primary bone tumours and typically have their origin along the neuraxis, especially at the developmentally more active cranial and caudal end, and notably in the sphenoccipital, sacrococcygeal, and vertebral locations. Twenty-five per cent to 40 per cent of chordomas occur in the sphenoccipital and skull base region and predominate in the 30 to 50-year-old age range, with a slight predominance in men. Usually chordomas do not show cytological atypia, but in 30 per cent of cases metastases to the lung, skin, lymph node, liver and bone have been reported. Dedifferentiated chordoma is very rare^{1,2} and is characterized by the presence of a sarcomatous component.³ Also prognosis is poor in differentiated chordoma patients, due to the presence of distance metastases, as is shown by the 5-year survival rate which reaches only 58 per cent.³

Clinical presentation depends on the origin and extension of each particular lesion. Delay in diagnosis is common, due to the occult nature of the disease and poorly localizing signs and symptoms. Late symptoms depend on the direction of the tumour extension.

Computed tomography (CT) reveals an expansible, destructive, lytic lesion and associated soft tissue mass, but

these features can also be seen with chondrosarcomas and other similar lesions. Foci of calcification may also be seen. Magnetic resonance imaging (MRI) yields more accurate information concerning the limits of the lesions and the vascular relationships, especially in the T2-weighted images. T1 images are particularly useful in defining any tumour-CSF (cerebro-spinal fluid) interface.⁴

The reported average survival time for chordomas of the skull base is 4.1 years. There appears to be a better prognosis for chordomas of the nasopharynx and paranasal sinuses. Notably, chondroid chordomas have a reported average survival time of 15.8 years.

The choice treatment for these lesions is total surgical excision. Recurrence is the rule, and metastases are extremely uncommon. Usually death occurs with local disease. Radiation therapy can be used in post-operative management because of the tumour's usually relentless course to local recurrence and death when conventional treatment is applied. Fractionated proton radiation therapy is currently advocated for the treatment of chordomas.⁵ Because of its higher biological effectiveness, patients can be treated with a higher total equivalent radiation dose.

A large variety of clinical studies have clearly demonstrated that *in vivo* scintigraphy with In¹¹¹ pentetreotide is effective in the diagnosis and staging of somatostatin receptor-positive tumours,^{6–8} but Schmidt *et al.*⁹ have reported a single case of chordoma, that

From the Department of Otorhinolaryngology, the *Department of Radiology and the †Nuclear Medicine Division, University Tor Vergata, Rome, Italy.

Accepted for publication: 15 February 2005.

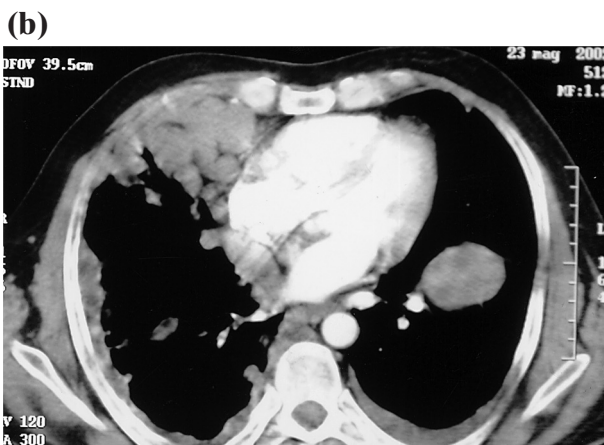
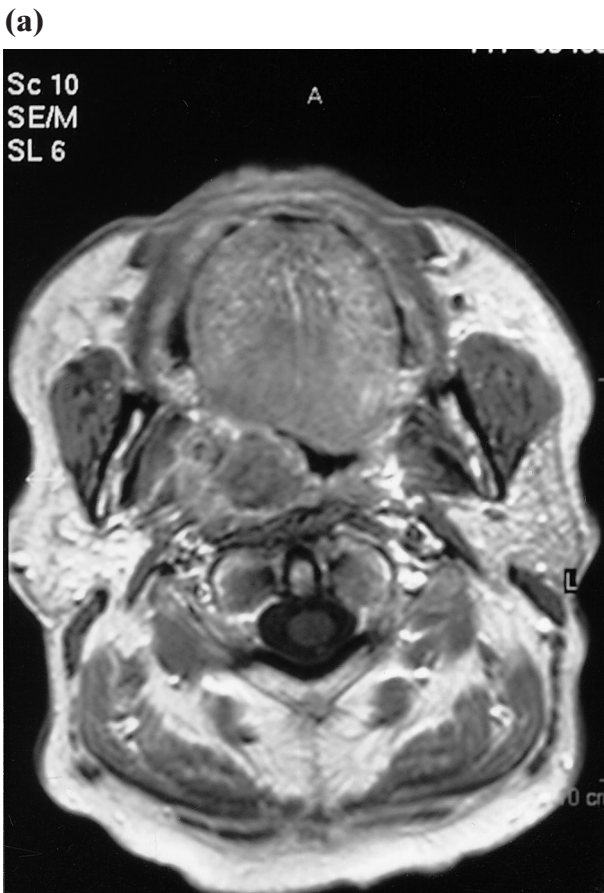
FIG. 1

Pre-treatment head and neck MRI (a) and chest CT (b).

demonstrated a faint uptake of the radiopharmaceutical, similar to the uptake of the skull, in a group of 124 patients with 141 brain lesions.

We describe the case of a 50-year-old Caucasian man affected by differentiated chordoma of the clivus, diagnosed 14 years before, and presenting with local relapse and distance metastases after multimodal treatment, in order to discuss new therapeutical approaches made possible by improvements in imaging techniques.

Case report

A 50-year-old Caucasian man presented in 1988 complaining of nasal obstruction. A nasopharyngeal

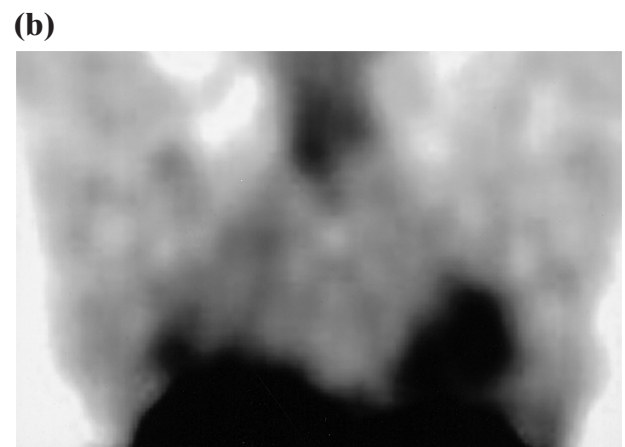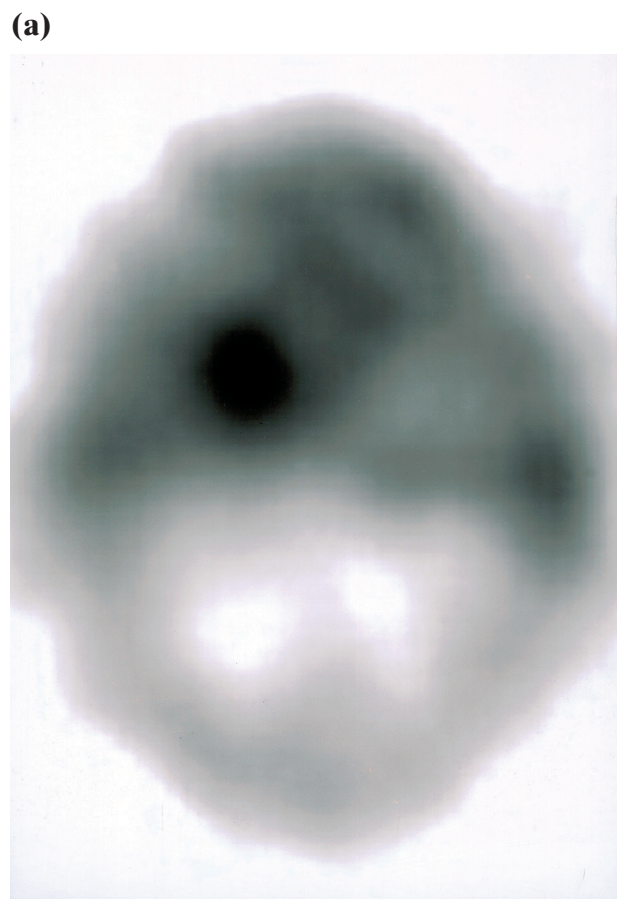

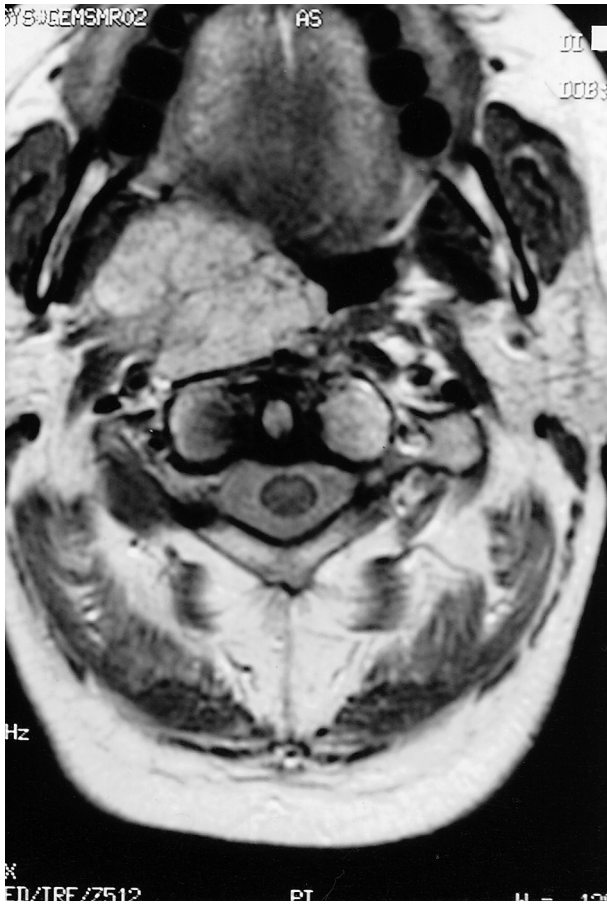
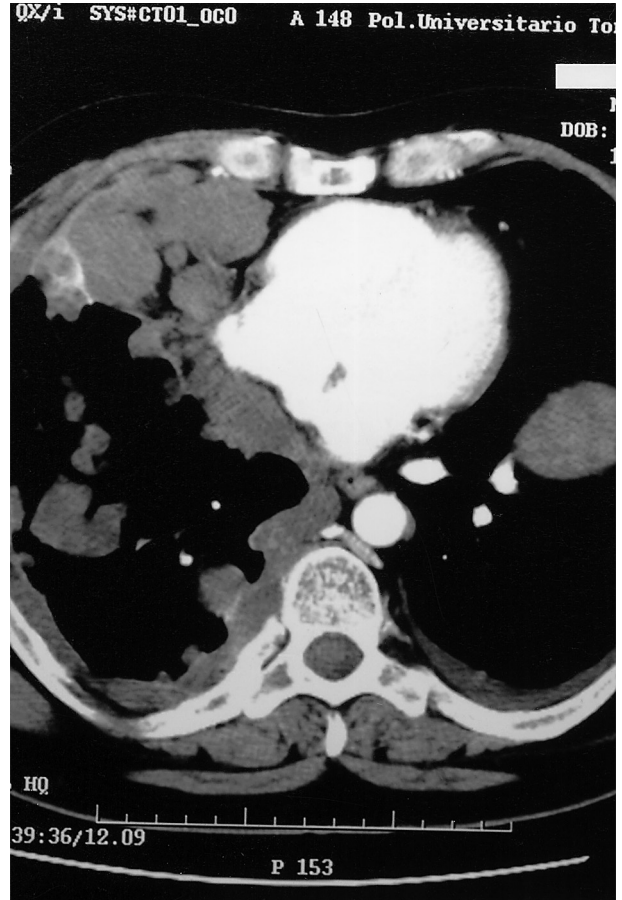
FIG. 2

The scintigraphic images clearly detect both the local recurrence (a) and the lung metastases (b); the visual analysis of the images demonstrates an intense uptake in the metastases and only a faint to moderate uptake in the local recurrence.

chordoma was diagnosed. After local excision, the chordoma relapsed 3 years later. Local excision was again performed, completed with radiation therapy (58 Gy) and interstitial brachytherapy. In 1997 nasal obstruction recurred and a lung nodule was also detected. A thoracoscopic biopsy revealed chordoma metastasis. In 1998 multiple lung metastases were diagnosed and the patient underwent unsuccessful chemotherapy treatment. In June 2000 the chordoma was removed by means of the Le Fort I approach, while metastases also involved the



(a)



(b)

FIG. 3

Post-treatment head and neck MRI (a) and chest CT (b) performed 2 months after the radionuclide therapy demonstrate a stable disease in the lungs but a progression of the nasopharyngeal lesion, when compared with the images acquired before treatment.

pleura and pericardium. The following year, the chordoma relapsed while liver metastases were detected. Due to the progressive deterioration of the clinical picture (dyspnoea, ipomoea, hypogeusia, hearing loss, loss of libido, urinary incontinency), the mass was once again removed by a combined ENT-neurosurgical approach (tracheotomy, and a transoral approach). Nasal symptoms temporarily improved, but a recent follow-up revealed a new local relapse and progression of the lung and liver metastases (Figure 1).

Somatostatin receptor scintigraphy was acquired after an intravenous injection of ~250 MBq of In^{111} pentetreotide (Mallinckrodt Medical, Petten, The Netherlands), a radiolabelled somatostatin analogue. Images were obtained with a double-head rotating gamma camera (Millenium VG, GE Milwaukee, USA) equipped with medium energy collimators. A whole-body scan in anterior and posterior views at 4 hours and multiple planar images from the head to the mid-thigh region in anterior and posterior projections at 24 hours following injection were obtained; moreover, tomographic images (SPECT) were acquired over the head/neck region and chest. The scintigraphic images clearly detected both the local recurrence and the lung metastases; the visual analysis of the images demonstrated an intense uptake in the metastases and only a faint to moderate uptake in the local recurrence (Figure 2).

Considering the surgical failure, and the possibility of treating somatostatin receptor-positive tumours,¹⁰ the

patient underwent a radionuclide receptor-target radiotherapy with Y^{90} -DOTA-*lanreotide*. A first dose of mCi 18.3 in March 2003 and a second of mCi 34 in June 2003 were given as short-term intravenous infusion.

Head and neck MRI and chest CT performed two months after the radionuclide therapy demonstrated a stable disease in the lungs, but showed a progression of the nasopharyngeal lesion (Figure 3) when compared with the images acquired before treatment (Figure 1), thus correlating with the pre-treatment scintigraphic images (Figure 2).

This different biological behaviour between the primary lesion and metastases suggests that the efficiency of radiolabelled somatostatin analogues is strictly related to the expression of somatostatin receptors.

As far as we know, this is the first case of chordoma showing a high uptake of In^{111} pentetreotide. Due to its capacity to demonstrate *in vivo* somatostatin receptors, scintigraphy is a useful tool for selecting the patients likely to benefit from therapy with somatostatin analogues, as in the case we are describing. Moreover, recently radiolabelled somatostatin analogues were also developed, and the initial results have indicated a clinical potential for radionuclide receptor-target radiotherapy.¹⁰

These results confirm the tendency towards better results in patients whose tumours have a higher accumulation of In^{111} pentetreotide demonstrable *in vivo* by scintigraphy,¹¹ and suggest the potential usefulness of radiolabelled somatostatin analogues for the diagnosis and therapy of chordomas.

Why primary lesion and metastases behave differently is still unknown. It can be hypothesized that the several surgical and radiation treatments may have induced a dedifferentiation of the primary tumour.

- **This case report documents the investigation and treatment of a clivus chordoma with pulmonary metastases**
- **The use of somatostatin receptor scintigraphy facilitated treatment with radionucleotide receptor-target radiotherapy**
- **The possible applications of this technique in the management of somatostatin receptor positive tumours is discussed**

References

- 1 Saito A, Hasegawa T, Shimoda T, Toda G, Hirohashi S, Tajima G, *et al.* Dedifferentiated chordoma: a case report. *Jpn J Clin Oncol* 1998;**28**:766–71
- 2 Sefiani S, Amarti A, Maher M, Benkiran L, Saidi A. Dedifferentiated chordoma of the skull base: a case report. *Neurochirurgie* 2002;**48**:436–9
- 3 Unni KK. Chordoma. In: Unni KK, ed. *Dahlin's Bone Tumors. General Aspects and Data on 11,087 cases*, 5th edn. New York: Lippincott-Raven, 1996:291–305
- 4 Pile RF, Melville GE, New PF, Austin Seymour F, Munzenrider J, Pile-Spellmann J, *et al.* The role of MRI and CT evaluating clival chordomas and chondrosarcomas. *Am J Roentgenol* 1988;**151**:567–75
- 5 Austin-Seymour M, Munzenrider J, Boitein M, Verhey L, Urie M, Gentry R, *et al.* Fractionated proton radiation therapy of chordoma and low-grade chondrosarcoma of the base of the skull. *J Neurosurg* 1989;**70**:13–17
- 6 Krenning EP, Kwekkeboom DJ, Bakker WH, Breeman WA, Kooji PP, Ori HY, *et al.* Somatostatin receptor scintigraphy with [¹¹¹In-DTPA-D-Phe¹]- and [¹²³I-Tyr³]-octreotide: the Rotterdam experience with more than 1000 patients. *Eur J Nucl Med* 1993;**20**:716–31
- 7 Kwekkeboom DJ, Krenning EP, de Jong M. Peptide receptor imaging and therapy. *J Nucl Med* 2000;**41**:1704–13
- 8 Schillaci O, Spanu A, Scopinaro F, Falchi F, Danieli R, Marongiu P, *et al.* Somatostatin receptor scintigraphy in liver metastasis detection from gastroenteropancreatic neuroendocrine tumors. *J Nucl Med* 2003;**44**:359–68
- 9 Schmidt M, Scheidhauer K, Luyken C, Voth E, Hildebrandt G, Klug N, *et al.* Somatostatin receptor imaging in intracranial tumours. *Eur J Nucl Med* 1998;**25**:675–86
- 10 Virgolini I, Britton K, Buscombe J, Moncayo R, Paganelli G, Riva P. In- and Y-DOTA-lanreotide: results and implications of the MAURITIUS trial. *Semin Nucl Med* 2002;**32**:148–55
- 11 Krenning EP, Valkema R, Kooij PP, Breeman WA, Bakker WH, de Herder WW, *et al.* The role of radioactive somatostatin and its analogues in the control of tumor growth. *Recent Results Cancer Res* 2000;**153**:1–13

Address for correspondence:
Professor Stefano Di Girolamo,
Department of Otorhinolaryngology,
Policlinico di Tor Vergata,
I-00133 Rome, Italy.

Fax: +390620902921
E-mail: sdigirolamo@virgilio.it

Dr S Di Girolamo takes responsibility for the integrity of the content of the paper.
Competing interests: None declared
