

Neuroimaging

FC42

Parkinsonism and basal ganglia volumes in first-episode psychosis

M.J. Cuesta^{1,2,*}, A.M. Sánchez-Torres^{1,2}, T. Cabada^{2,3}, P. Lecumberri^{2,4}, R. Lorente-Omeñaca^{1,2}, J.M. López-Ilundain^{1,2}, M. Ribeiro^{1,2}, L. Moreno-Izco^{1,2}, M. Gómez^{2,4}

¹ Complejo Hospitalario de Navarra, Department of Psychiatry, Pamplona, Spain

² IdiSNA, Navarra Institute for Health Research, Pamplona, Spain

³ Complejo Hospitalario de Navarra, Department of Radiology, Pamplona, Spain

⁴ Universidad Pública de Navarra, Department of Mathematics, Pamplona, Spain

* Corresponding author.

Introduction Parkinsonian motor signs are the most frequent of the genuine motor abnormalities present in drug-naïve patients with schizophrenia, and are also present in patients with a first-episode of psychosis (FEP).

Objective To study whether there are differences in basal ganglia volumes depending on the presence of Parkinsonism in FEP.

Methods Forty-six patients with a FEP were included in the study. Twenty-three controls were included to normalise patients' brain volume data. Parkinsonism was assessed with the UKU scale. Brain volumes were obtained with MRI (1.5 Tesla Siemens Avanto). Reconstruction and volumetric segmentation was made with the Freesurfer© software (<http://surfer.nmr.mgh.harvard.edu/>). Patients were divided into two groups, considering the presence/absence of Parkinsonism (UKU total score cutoff point=4). Patients have been treated with antipsychotics a mean of less than 2 months. There were not significant differences in the total exposure to antipsychotics between both groups. ANCOVAs were performed including gender as covariate.

Results Patients with Parkinsonism showed a trend towards significance to exhibit reduced volumes in the left caudate and right putamen (Fig. 1).

Conclusions FEP patients who exhibit Parkinsonian signs tend to show reduced left caudate and right putamen volumes in the early phases of psychotic illness, after correcting by gender.

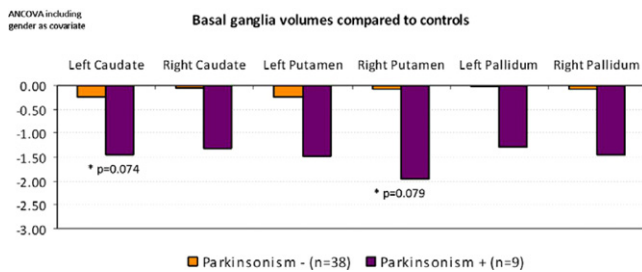


Fig. 1

Disclosure of interest The authors have not supplied their declaration of competing interest.

<http://dx.doi.org/10.1016/j.eurpsy.2016.01.046>

FC43

The role of neurometabolites in emotional processing

D. Denzel^{1,*}, L.R. Demenescu², L. Colic², F. von Düring³, H. Nießen³, M. Walter²

¹ Magdeburg, Germany

² Clinical Affective Neuroimaging Laboratory CANLAB, Leibniz Institute for Neurobiology, Magdeburg, Germany

³ Clinical Affective Neuroimaging Laboratory CANLAB, Otto-von-Guericke University Magdeburg, Magdeburg, Germany

* Corresponding author.

Objective To investigate how brain metabolites, especially glutamate and glutamine to glutamate ratio of pgACC modulate the neural response within these areas and how this affects their function during emotion facial expression matching task.

Methods Seventy healthy volunteers underwent magnetic resonance spectroscopy (MRS) and task functional magnetic resonance imaging (fMRI) in 7 Tesla scanner. PgACC MRS data were obtained using STEAM sequence and analyzed using LCModel.

Angry, fearful, and happy facial expressions were presented in an affect-matching block where one of the two facial expressions presented matched the target facial expression. The control condition was form matching. Data were preprocessed and analyzed in SPM 8.

Results Glutamate to Creatine ratio measured in pgACC positively correlated with BOLD response in the right DLPFC during negative emotional perception (FWE=0.05). Glutamate to glutamine ratio indicating on-off mechanisms in pgACC positively correlated with BOLD responses in FFA extending to cerebellum cluster (FWE<0.05).

Conclusion This study indicates that pgACC, baseline metabolism predicts neural response to emotional processing. We conclude that individuals with higher glutamate ratios, an excitatory neurotransmitter, in pgACC during rest might have a better coping mechanism to potential danger indicated by perception of angry or afraid faces. The higher glutamate to glutamine ratio in pgACC indicates a higher turnover of excitatory metabolite glutamate. This mechanism is associated with higher emotional response in fusiform area and cerebellum suggesting higher visual attention towards negative emotions.

Disclosure of interest The authors have not supplied their declaration of competing interest.

<http://dx.doi.org/10.1016/j.eurpsy.2016.01.047>

FC44

Association analysis of imbalanced interhemispheric functional coordination and early therapeutic efficacy in major depressive disorder: Evidence from resting state fMRI

Z. Hou^{1,*}, X. Song², W. Jiang¹, Y. Yue¹, Y. Yin¹, Y. Zhang¹, Y. Liu³, Y. Yuan¹

¹ Affiliated Zhongda Hospital of Southeast University, Medical School of Southeast University, Department of Psychosomatics and Psychiatry, Nanjing, China

² College of Engineering, Peking University, Department of Biomedical Engineering, Beijing, China

³ Key Laboratory of Cognition and Personality, Faculty of Psychology, Southwest University, Chongqing, China

* Corresponding author.

Introduction Emerging evidences indicate that the alteration of interhemispheric functional coordination may be involved in the pathogenesis of major depressive disorder (MDD). In present study, we aim to explore the potential marker by using the voxel-mirrored homotopic connectivity (VMHC) approach, which may be contributing to predict the clinical prognosis in MDD.

Methods Eighty-two MDD patients and 50 normal control (NC) subjects participated in this study. We divided the MDD group into unremitted and remitted group according to the reduction rate of Hamilton Rating Scale for Depression (HAM-D) within 2 weeks.

Results The study detected significantly decreased VMHC in bilateral precuneus (pCu), inferior temporal gyrus (ITG) and