






Double-orifice tricuspid valve: case series and literature review

Brendan T. Haughian¹ , Nee S. Khoo^{1,2}  and Lily Q. Lin^{1,2} 

¹Department of Pediatric Cardiology, Stollery Children's Hospital, Edmonton, AB, Canada and ²Department of Pediatrics, University of Alberta, Edmonton, AB, Canada

Original Article

Cite this article: Haughian BT, Khoo NS, and Lin LQ (2024) Double-orifice tricuspid valve: case series and literature review. *Cardiology in the Young* **34**: 1906–1911. doi: [10.1017/S1047951124025058](https://doi.org/10.1017/S1047951124025058)

Received: 8 September 2023
Revised: 27 March 2024
Accepted: 3 April 2024
First published online: 9 May 2024

Keywords:

Double-orifice tricuspid valve; tricuspid valve duplication; double-orifice atrioventricular valve; atrioventricular valve duplication; accessory tricuspid valve orifice

Corresponding author:

L. Q. Lin; Email: lily.lin@ualberta.ca

Abstract

The double-orifice tricuspid valve (DOTV) is a rare lesion. We present a series of three patients encountered at the Stollery Children's Hospital with a diagnosis of DOTV on 2D and/or 3D echocardiography. The patient's medical records are reviewed for presentation history, investigative findings, and clinical course. We discuss the cases in the context of a complete review of all literature documenting cases of DOTV. In the majority of cases, the lesion is relatively benign, with little change in valve function over the short to medium term, and outcomes are determined largely by significant concomitant heart defects.

A double-orifice atrioventricular valve occurs when there is an accessory communication within the boundaries of the valve annulus that is also supported by a tensor apparatus. While double-orifice atrioventricular valve has been well documented in the mitral position, double-orifice tricuspid valve (DOTV) by comparison is rare, with less than 50 reported cases¹, and little to no information regarding the clinical course or long-term outcomes for these patients.

The study of this anomaly is further complicated by its inconsistent definition. Some authors have analysed the grouping of double-orifice valve in the tricuspid as well as those in the right atrioventricular valve position,¹ while others have chosen to deliberately exclude those associated with atrioventricular septal defects.² There also exist cases that straddle the border between a septal malalignment defect and a defect of valve development. We have reviewed the entire spectrum of presentations and suggested an approach that will hopefully provide some clarity.

Given the extreme rarity of the lesion, we present this case series of three additional cases, to further add to our understanding of its natural history.

Materials and methods

A literature search for DOTV was performed using the Medline database (Ovid) and EMBASE 1974 to November 23, 2022 (Ovid). No language or date limits were applied to the search. Records were exported from the Ovid interface, and duplicates were removed using EndNote 20 software. All reported cases of the DOTV, accessory tricuspid valve orifice, duplication of the tricuspid valve, and double-orifice right atrioventricular valve were reviewed. The reference sections of all sources were then reviewed for additional cases including those published in English, German, Italian, and Spanish. Any cases that did not meet the definition of a tricuspid or a right atrioventricular valve with a second orifice, supported by its own tensor apparatus, were excluded. Cases of double-outlet right atrium were excluded.

Results

Case studies

Case 1

A seven-day-old female was referred for investigation of a cardiac murmur. She was the product of an uncomplicated pregnancy delivered vaginally at term. Her electrocardiogram was normal, while her echocardiogram showed a small, secundum atrial septal defect and a small pressure-restrictive, mid-muscular ventricular septal defect. The tricuspid valve had mildly restricted leaflet motion secondary to chordal tethering. On examination of the RA-RV inflow, an additional posterior jet of the right ventricle to the right atrium flow was noted (Fig. 1). Differential diagnoses included tricuspid regurgitation from the DOTV or a right ventricle to the right atrium tunnel. She was brought back at two months of age for a sedated 3D assessment of the tricuspid valve.

At the sedated scan, the small atrial septal defect remained, with a resolution of her muscular ventricular septal defect. 3D examination confirmed the presence of both a central main orifice and a smaller accessory orifice, supported by separate subvalvar tensor apparatus

© The Author(s), 2024. Published by Cambridge University Press. This is an Open Access article, distributed under the terms of the Creative Commons Attribution-NonCommercial-NoDerivatives licence (<http://creativecommons.org/licenses/by-nc-nd/4.0/>), which permits non-commercial re-use, distribution, and reproduction in any medium, provided that no alterations are made and the original article is properly cited. The written permission of Cambridge University Press must be obtained prior to any commercial use and/or adaptation of the article.



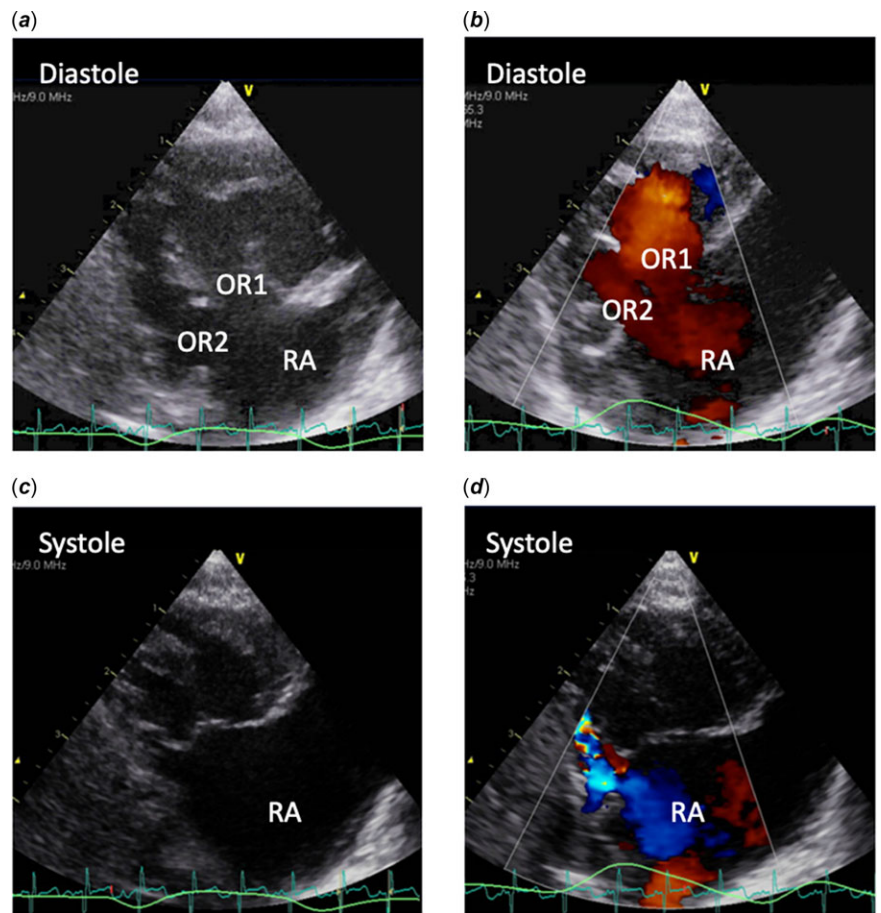


Figure 1. 2D and colour Doppler images of the right ventricular inflow in the parasternal long axis. Panel A and B shows the separate orifice in 2D and the double inflow pattern during diastole. Main orifice (OR1), accessory orifice (OR2). Panel C and D shows the separate orifice in 2D in systole as well as the regurgitation jet from the smaller orifice. RA = right atrium.

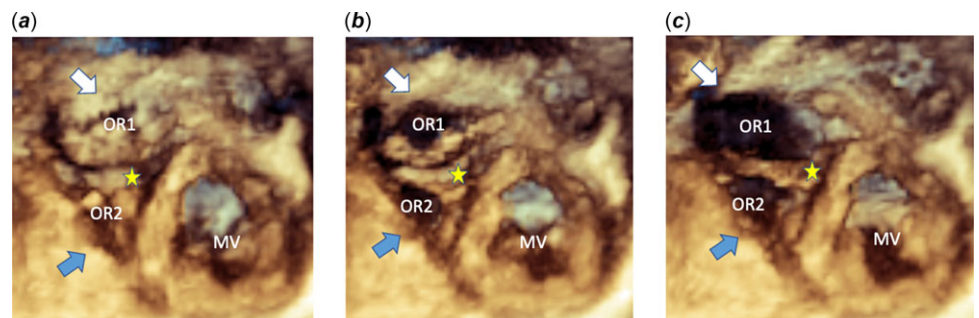


Figure 2. 3D rendering of tricuspid valve *enface* viewed from the apex in systole (Panel A), early diastole (Panel B), and late diastole (Panel C). The main orifice (OR1) indicated by the white arrow and accessory orifice (OR2) indicated by the blue arrow. Note the bridge of tissue between the two, indicated by the star. MV = mitral valve.

(Fig. 2 and S1 Video). Both the main and accessory orifices were unobstructed with moderate regurgitation from the small posterior orifice.

At the latest follow-up of two years, the patient had stable moderate tricuspid regurgitation from the accessory orifice, and trivial regurgitation of the main orifice. The small atrial septal defect had a left to right shunt with mild dilation of both the right atrium and ventricle. The patient was asymptomatic with a normal growth trajectory.

Case 2

This infant was reviewed at two days of age in the neonatal ICU for antenatal ultrasound showing a dysplastic pulmonic valve, without obstruction, and dilated right atrium. The aortic valve was reportedly hypoplastic. The infant was born at 37 weeks by spontaneous vaginal delivery and was admitted for continuous

positive airway pressure (CPAP) support secondary to mild respiratory distress. On exam, he had a 3/6 systolic ejection murmur heard at the left lower sternal border and a 2/6 systolic murmur heard over the upper left sternal border. Postnatal 2D echocardiogram showed a moderate secundum atrial septal defect, Ebsteinoid tricuspid valve with a double-orifice and moderate regurgitation, mild pulmonic valve stenosis, and mild aortic valve hypoplasia. The patient’s respiratory distress resolved promptly following admission. He was discharged on day 5 to be followed up by paediatric cardiology. Suspicion of the concomitant double-orifice *mitral* valve at initial echocardiogram was confirmed at four months follow-up echocardiogram. At the most recent follow-up of four years, he remained asymptomatic, with only mild pulmonic valve stenosis and stable atrio-ventricular valve function, with no dilation or dysfunction of the right heart chambers.

Table 1. Summary of reported cases of DOTV

Case	Author	Year reported	Method of detection
1	Pisenti	1887	Autopsy
2	Gurtler	1958	Autopsy
3	Neufeld	1960	Autopsy
4	Sherman	1963	Post-mortem heart specimen
5	Edwards	1965	Unknown
6	Sanchez-Cascos	1967	Autopsy
7		1967	Autopsy
8	Elfenbein	1968	Autopsy
9	Taira	1979	Surgical
10	Becker	1980	Post-mortem heart specimen
11	Lynch	1980	Surgical
12	Huhta	1982	Post-mortem heart specimen
13	Miyamura	1984	Autopsy
14	Bano-Rodrigo	1988	Post-mortem heart specimen
15		1988	Post-mortem heart specimen
16		1988	Post-mortem heart specimen
17		1988	Post-mortem heart specimen
18	Cabrera	1988	Autopsy
19		1988	Autopsy
20	Pignoni	1988	Autopsy
21	Cabrera	1990	2D TTE
22	Honnekeri	1993	Surgical
23	Yoo	1993	Autopsy
24	Prendergast	1996	Surgical
25	Goldberg	1996	2D TEE
26	Radermecker	2001	Surgical
27	Anil	2003	Surgical
28	Oppido	2005	Surgical
29	Mainwaring	2009	Surgical
30	Itatani	2010	Surgical
31	Zhang	2011	Surgical
32		2011	Surgical
33		2011	Surgical
34	Gajjar	2012	Surgical
35	Wang	2012	Surgical
36		2012	Surgical
37	Feier	2012	Surgical
38	Mur	2012	2D TTE

(Continued)

Table 1. (Continued)

Case	Author	Year reported	Method of detection
39	Kansara	2014	Surgical
40	Case 3 (current study)	2014	3D TEE
41	Saxena	2016	Surgical
42	Nitta	2016	3D epicardial echo
43	Obase	2016	2D TTE, 3D confirmed
44	Case 2 (current study)	2016	TTE
45	Egbe	2018	TTE, TEE
46	Mohanty	2019	2D TTE, 3D confirmed
47	Case 1 (current study)	2019	2D TTE, 3D confirmed
48	Henning	2022	2D TTE

Case 3

The patient was a two-year-old with a cardiac murmur. She was asymptomatic and had a resting saturation of 92% in room air with early clubbing. She had a 2/6 harsh, systolic ejection murmur and a widened S2. The electrocardiogram was suspicious for Wolff-Parkinson-White. The echocardiogram found severe Ebstein's malformation with mild tricuspid regurgitation, unobstructed outflows, mild prolapse of the mitral valve, and a bidirectional patent oval foramen. It was not until after five follow-up echocardiograms and one cardiac MRI that the tricuspid valve was found to have double-orifice, two years after initial assessment. The main orifice was competent, while the accessory orifice had mild regurgitation. The tricuspid valve was not stenotic. At five years old, the patient underwent a bidirectional cavopulmonary anastomosis and suture closure of the atrial septal defect, as she was deemed not suitable for the cone procedure. The patient is now six years post-procedure and remains asymptomatic, with unchanged tricuspid valve findings.

Including our own cases, we have found a total of 48 published cases of DOTV from the first case cited in 1887 until June 2022 (Table 1). The patients ranged in age from newborn to 80 years, and there was an even distribution between males and females. With only one notable exception, all cases were associated with one or more coexisting heart defects. The most common associated defects were atrial septal defect, ventricular septal defect, double-orifice mitral valve, and Ebstein's anomaly. The majority of DOTVs were detected either during surgery or post-mortem/heart specimen examination; however, reports from the last two decades indicate that diagnosis is increasingly made from echocardiography. Of the cases that reported the valve's functional status, tricuspid regurgitation was seen in 62.1% of cases, stenosis was seen in 6.9%, and 3.4% reported both stenosis and regurgitation. In approximately 27.6% of the cases, valve function was reported as normal (Table 2). There was no apparent correlation between the age at diagnosis and severity of valve regurgitation. Only two of the published cases reported genetic analyses, with "normal chromosomes" for one³ and a variant of unknown significance in gene PEX6 for the other.⁴

Table 2. Detailed findings from 48 cases of DOTV

	Number	Percent	<i>n</i>
Total number of cases			48
Gender			48
Male	20	41.7	
Female	20	41.7	
Unknown	8	16.7	
Type of defect			36
Hole	9	25.0	
Central/bridge	22	61.1	
Commissural	5	13.9	
Unknown	12		
Location of accessory orifice			35
Anterior	5	14.3	
Posterior	8	22.9	
Septal	3	8.6	
Anteroseptal commissure	10	28.6	
Posteroseptal commissure	2	5.7	
Central	7	20.0	
Unknown	13		
Functional status of TV			29
Tricuspid regurgitation	18	62.1	
Tricuspid stenosis	2	6.9	
TS and TR	1	3.4	
Normal	8	27.6	
Unknown	19		
Associated anomalies			46
None (isolated)	1	2.2	
Ebstein's	8	17.4	
PFO	5	10.9	
ASD	11	23.9	
VSD	9	19.6	
Tetralogy of Fallot	6	13.0	
Complete or partial AVSD	7	15.2	
Pulmonary atresia	2	4.3	
Pulmonic valve stenosis	7	15.2	
DOMV	9	19.6	
TGA	3	6.5	
LSVC	2	4.3	
Raghib complex	2	4.3	
Pulmonic valve fenestration	1	2.2	
Coarctation of the aorta	1	2.2	
BAV	1	2.2	
Unknown	2		
Method of detection			48

(Continued)

Table 2. (Continued)

	Number	Percent	<i>n</i>
Echo	11	22.9	
Surgical	18	37.5	
Autopsy/heart specimen	18	37.5	
Unknown	1		
Surgical intervention required?			22
Yes	9	40.9	
No	13	59.1	

ASD = atrial septal defect; AVSD = atrioventricular septal defect; BAV = bicuspid aortic valve; DOMV = double-orifice mitral valve; LSVC = left sided superior vena cava; PFO = patent foramen ovale; TGA = transposition of the great arteries; TV = tricuspid valve; VSD = ventricular septal defect.

Discussion

There have been two attempts at describing and classifying the double-orifice atrioventricular valve since it was first described by Greenfield in 1876.⁵ The first was Hartmann in 1937,⁶ who proposed three categories for double-orifice mitral valve: the Brucke (bridge) or B type is characterised by two ostia of similar size, separated by a bridge of tissue, each being supported by one papillary muscle and cord apparatus. The Locke (hole) or L type is characterised by the joining of two leaflets along the zone of apposition near the base, creating a second ostium. The native tensor apparatus is intact and supports both ostia. The Sonderstellung (special status) or S type is essentially the same as the B type; however, each ostium has two separate tensor apparatuses instead of one.

With a larger group of reported cases to draw from in 1967, Sanchez-Cascos⁷ was able to revise this classification to eliminate redundancy and include another type that had not been covered by Hartmann. The commissural type is similar to Hartmann's L type, being an accessory orifice at the base of the zone of apposition, with the normal tensor apparatus. This includes both those with the usual number of papillary muscles and those with accessory papillary muscles in addition to the normal ones. The central type describes a band or bridge of tissue crossing the atrioventricular valve centrally, with two orifices of either equal or unequal size and shape. This corresponds to Hartmann's B and S types. Lastly, the hole type is a hole within a valve leaflet that is supported by a tensor apparatus, whereas a hole in the leaflet without this would be a simple fenestration.

The diagnosis and classification of a double-orifice atrioventricular valve becomes less clear when there is override or straddling due to septal malalignment. As the migration of the right atrioventricular valve inlet over the developing right ventricle and the formation of the right atrioventricular valve are temporally distinct during cardiac development,^{8,9,10} it is likely that a distinct process results in each malformation. We therefore suggest that a DOTV be considered a distinct entity that arises only from a defect in valvar formation, and an overriding or straddling tricuspid valve as a double-outlet right atrium.

There is another small subgroup of defects in which the right atrium and right atrioventricular canal are both divided by a fibromuscular septation, creating two inlets.^{11,12,13} Closely related to the so-called cor triatriatum dexter, this defect as described by Karalius et al.¹³ included a distinctive feature whereby the septation

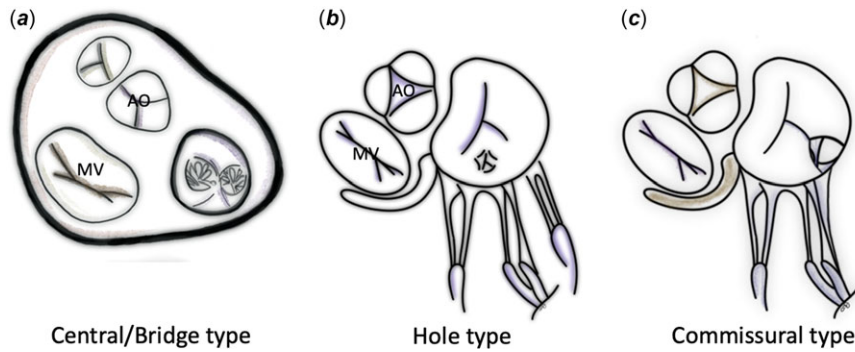


Figure 3. Schematic diagrams demonstrating the three types of DOTV. Panel A shows the central/bridge type, Panel B shows the hole type, and Panel C shows the commissural type. AO = aortic valve; MV = mitral valve.

was attached to the tricuspid valve. It is our contention that even in the case whereby a persistent septum spurium divides the tricuspid inflow, this constitutes a double-outlet right atrium and not a DOTV.

Of the cases that meet the criteria for DOTV, the most commonly reported type of defect was the central/bridge type at 61.1%, followed by the hole type at 25.0%, and lastly the commissural type at 13.9% (Fig. 3).

Surgical intervention for the DOTV was performed in approximately 40.9% of patients using combinations of suture closure of the accessory orifice and annuloplasty. In one patient, the short chordae were fenestrated, the papillary muscles split, and the bridging tissue left intact.¹⁴ Regardless of the type of repair, it is now generally agreed that the bridging tissue should be left intact to avoid significant regurgitation.¹ Most interventions on DOTVs were incidental to the repair of other associated lesions, with only two cases in which DOTV functional status contributed to the decision for intervention. Based on these findings, we can surmise that a DOTV will rarely determine surgical course in and of itself. That said, in one notable case reported by Oppido *et al.*, the patient's repair for tetralogy of Fallot was impacted by limited access to the ventricular septal defect and right ventricular outflow tract through the tricuspid valve.¹⁵

Since the advent of 2D echo imaging in the early 1970s, only 27.5% of the published cases have been detected by echocardiogram. The most significant barriers to improved detection have been twofold: first, the general lack of awareness about the defect among both sonographers and cardiologists, likely secondary to the paucity of reported cases. Second, the views in which the defect can be best appreciated are often not standard echo views.²

When assessing the tricuspid valve, careful attention should be paid to the annulus dimension, as the increase in dimension can be the first clue to an abnormal valve.^{16,17} The next clue may be a bridge-like appearance of the leaflets in the apical four-chamber view, as described by Obase *et al.*¹⁸ As most of these defects will present with regurgitation of the valve, a regurgitant jet that is not centrally located, as was seen in Case 1, or a double inflow jet on colour Doppler should alert the imager to the presence of a DOTV (Fig. 1). Furthermore, the subcostal and parasternal views especially will aid in defining the tensor apparatus of each orifice (Supplementary Video S1).

Once suspicion has been raised with standard two-dimensional imaging, it should be followed by three-dimensional echocardiogram. A full-volume dataset allows the inspection of the valve from multiple non-standard planes as well as from a rendered enface view of the TV to improve diagnostic certainty.

In conclusion, the most common complication of a DOTV is tricuspid regurgitation. Our own experience with the cases

presented here suggests that these lesions tend to be stable, with little to no progression seen over several years based on clinical and echocardiographic findings. In isolation, the clinical course can be relatively benign, and the DOTV is most commonly an incidental finding associated with other more significant lesions. It is useful to report the function, size, and location of the orifices, as this may impact surgical planning and management for their associated cardiac lesions.

Supplementary material. The supplementary material for this article can be found at <https://doi.org/10.1017/S1047951124025058>.

Acknowledgements. The authors would like to acknowledge the contributions of Dr Martha Moran, who provided the artwork for Figure 3.

Financial support. None.

Competing interests. None.

Ethical standard. The authors assert that all patient information gathered for the purposes of this work was done so according to the ethical standards of Alberta Health Services and the University of Alberta and has been approved by both the Research Ethics Office (University of Alberta) and the Northern Alberta Clinical Trials and Research Centre (Alberta Health Services).

References

- Zhang J, Ma WG, Pan SW. Surgical management of double-orifice tricuspid valve. *J Card Surg* 2011; 26: 425–428.
- Tutarel O, Westhoff-Bleck M. The double-orifice tricuspid valve: a review. *J Heart Valve Dis* 2007; 16: 508–510.
- Mainwaring RD, Reddy VM, Wright SB. Double-orifice tricuspid valve in association with complete atrioventricular septal defect. *Pediatr Cardiol* 2009; 30: 564–565.
- Henning RE, Kieu VH, Goot BH. Double-orifice tricuspid valve in an infant with multiple noncardiac anomalies. *CASE* 2022; 6: 165–166.
- Greenfield WS. Double mitral valve. *Trans Pathol Soc London* 1876; 27: 128–129.
- Hartmann B. Zur Lehre der Verdoppelung des linken Atrioventricularostiums. *Arch Kreislaufforsch* 1937; 1: 286–304.
- Sanchez-Cascos A, Rabago P, Sokolowski M. Duplication of the tricuspid valve. *Br Heart J* 1967; 29: 943–946.
- Gittenberger-De Groot A, Bartelings MM, Deruiter MC, *et al.* Basics of cardiac development for the understanding of congenital heart malformations. *Pediatr Res* 2005; 57: 169–176.
- Kim JS, Viragh S, Moorman AFM, *et al.* Development of the myocardium of the atrioventricular Canal and the vestibular spine in the human heart. *Circ Res* 2001; 88: 395–402.
- Lamers WH, Viragh S, Wessels A, *et al.* Cardiac valves: formation of the tricuspid valve in the human heart. *Circulation* 1995; 91: 111–121.
- Antit S, Zakhama L, Boussabeh E, *et al.* Isolated double orifice tricuspid valve. *Tunis Med* 2019; 97: 1311–1312.

12. Dabirian M, Nabati M, Jalalian R, et al. Double-orifice tricuspid valve: a case report and literature review. *Echocardiography* 2016; 33: 479–483.
13. Karalius R, Sipavicius R, Aidietis A, et al. A double-orifice tricuspid valve associated with a divided right atrium. *Ann Thorac Surg* 2012; 93: 63–65.
14. Saxena R, Talwar S, Gharde P, Kumar MV, Choudhary SK. Repair of concomittant double orifice mitral and tricuspid valves. *World J Pediatr and Congenit Heart Surg* 2016; 7: 120–122.
15. Oppido G, Napoleone CP, Ragni L, et al. Double orifice tricuspid valve in an infant with tetralogy of fallot. *Ann Thorac Surg* 2006; 81: 1121–1123.
16. Gajjar T, Desai N. Double-orifice tricuspid valve: a rare entity. *Eur J Cardiothorac Surg* 2012; 41: 1187–1189.
17. Mohanty S, Pavithran S, Agarwal R, et al. Utility of three-dimensional echocardiography and magnetic resonance imaging in the diagnosis of double-orifice tricuspid valve. *Ann Pediatr Cardiol* 2019; 12: 339–341.
18. Obase K, Addetia K, Takahashi K, et al. Double-orifice tricuspid valve visualized by three-dimensional transthoracic echocardiography. *J Cardiovasc Ultrasound* 2016; 24: 253–255.