

## EPV0833

**Risperidone Induced DRESS Syndrome: A case report**S. E. Ilgin<sup>1,2\*</sup>, Ö. Yanartaş<sup>1</sup> and E. Akça<sup>2</sup><sup>1</sup>Psychiatry, Marmara University Research & Training Hospital and<sup>2</sup>Psychiatry, Marmara University Research & Training Hospital, Istanbul, Türkiye

\*Corresponding author.

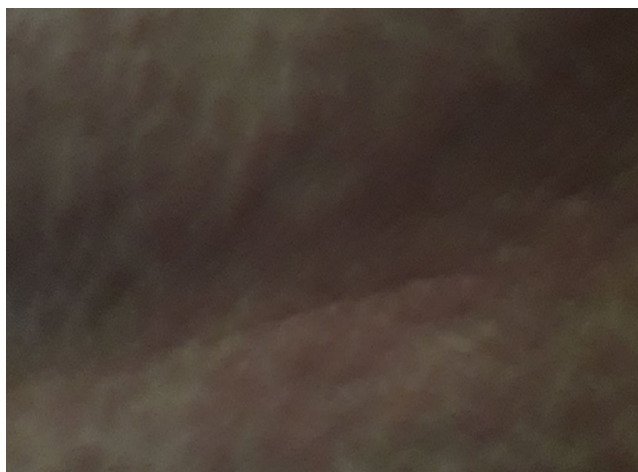
doi: 10.1192/j.eurpsy.2024.1455

**Introduction:** DRESS (Drug Reaction with Eosinophilia and Systemic Symptoms) syndrome, also called DIHS (Drug-Induced Hypersensitivity Syndrome) is a rare drug-induced systemic hypersensitivity reaction that can be potentially life-threatening (Choudhary et al. J Clin Aesthet Dermatol 2013; 6 -7). Risperidone is an antipsychotic drug with significant antagonist activity at the 5-HT<sub>2</sub> and the D<sub>2</sub> receptors. It has been reported that risperidone may be effective in controlling agitation, delusion, hallucination, and withdrawal behavior in geriatric patients (Yunusa & El Helou. Front Pharmacol 2020;11:596).

**Objectives:** The aim of this study is to demonstrate the case of developed DRESS syndrome following the use of risperidone.

**Methods:** The 81-year-old female patient was admitted to the Dermatology Clinic due to skin rash, high fever and leukocytosis following the use of risperidone. The patient was consulted to Psychiatry.

**Results:** In her history it was determined that risperidone 0.5 mg/d was started to the patient with depression due to agitative symptom. On the 4th day of treatment, targetoid lesions, starting from the back and spreading first to the trunk and then to the extremities, were observed. Further laboratory examinations revealed that the fever was measured at 39.5 C°, liver enzymes were elevated (ALT= 119 IU/l, AST= 124 IU/l), and significant leukocytosis (WBC=12.000) was present along with the lesions. The patient was planned to be hospitalized to Dermatology Clinic on the 5th day and risperidone was stopped. The patient's agitation increased and following the risperidone discontinuation thereupon the lesions tended to fade and desquamation began. After the treatment of the DRESS syndrome, aripiprazole was given to the patient for agitative symptom. The level of agitation symptoms decreased, and the patient tolerated aripiprazole well without any observed side effects.

**Image:**

**Conclusions:** When initiating medication for the elderly population to address agitation, considering such rare side effects can prevent the patient from being hospitalized due to DRESS syndrome. To the best of our knowledge, this is the first case report associated with DRESS syndrome and risperidone treatment thus, it is necessary to be very careful when starting psychotropic medication for elderly patients.

**Disclosure of Interest:** None Declared

## EPV0834

**Clinical Insights into Antipsychotics and Rifampicin Interaction: A Case Report**

P. Abreu\*, C. Ferreira dos Santos, M. Pereira, M. Vieira Lisboa, M. Cameira and M. Rebelo Soares

Centro Hospitalar Psiquiátrico de Lisboa, Lisbon, Portugal

\*Corresponding author.

doi: 10.1192/j.eurpsy.2024.1456

**Introduction:** Antipsychotics are the primary class of drugs used to manage schizophrenia. These medications help control and reduce the severity of these symptoms, allowing individuals with schizophrenia to better function. On the other hand, rifampicin, used as treatment for tuberculosis, is a powerful inducer of several drug-metabolizing enzymes which have the potential to decrease the plasma levels of antipsychotics. Therefore, the presence of multiple pharmacokinetic interactions can alter how antipsychotics are metabolized, leading to a notable clinical impact when these medications are administered concurrently.

**Objectives:** The objective is to share valuable clinical experiences and insights to aid healthcare providers in making informed decisions when faced with the challenge of co-administering antipsychotics with rifampicin, ultimately ensuring the safety and efficacy of treatment for their patients.

**Methods:** It will be discussed a case of a 41-year-old woman with the diagnosis of schizophrenia under treatment with paliperidone palmitate and clozapine who had a sudden relapse after starting treatment for latent tuberculosis with rifampicin as a framework for a literature review based off Pubmed.

**Results:** The antituberculosis drug rifampicin induces drug-metabolizing enzymes in the liver, having the greatest effects on the expression of cytochrome P450 (CYP3A4) and therefore can lead to a decrease in the plasma levels of antipsychotic medications that also rely on these pathways for clearance. In this particular case, although specific data on clozapine and paliperidone concentrations were not reported, fluctuations in symptomatology following rifampicin introduction were probably explained by an inducing effect of this drug on their metabolism. So, when initiating rifampicin treatment and when discontinuing it, clinicians should carefully assess the dosages of any concomitant medications that may potentially interact with rifampicin. To ensure effective therapy during rifampicin treatment, it is crucial to monitor both the patient's clinical response and their blood drug concentrations, making dosage adjustments as necessary.

**Conclusions:** This case report offers valuable guidance to clinicians on safely and effectively managing drug interactions between antipsychotic medications and rifampicin, ensuring the well-being of