

Molecular characterization of *Cysticercus tenuicollis* isolates from sheep in the Nile Delta, Egypt and a review on *Taenia hydatigena* infections worldwide

Research Article

*Current address: Institute for Experimental Infection Research, TWINCORE, Centre for Experimental and Clinical Infection Research, a joint venture between the Hanover Medical School and the Helmholtz Centre for Infection Research, Hanover, Germany

Cite this article: Abbas I, El-Alfy E-S, Janecek-Erfurth E, Strube C (2021). Molecular characterization of *Cysticercus tenuicollis* isolates from sheep in the Nile Delta, Egypt and a review on *Taenia hydatigena* infections worldwide. *Parasitology* **148**, 913–933. <https://doi.org/10.1017/S0031182021000536>



Received: 18 November 2020
Revised: 23 February 2021
Accepted: 21 March 2021
First published online: 29 March 2021

Keywords:

12S rRNA; *Cysticercus tenuicollis*; Egypt; global distribution; sheep; *Taenia hydatigena*

Author for correspondence:

Ibrahim Abbas,
E-mail: ielsayed@mans.edu.eg

Ibrahim Abbas¹ , El-Sayed El-Alfy¹, Elisabeth Janecek-Erfurth^{2,*} and Christina Strube² 

¹Parasitology Department, Faculty of Veterinary Medicine, Mansoura University, Mansoura 35516, Egypt and ²Institute for Parasitology, Center for Infection Medicine, University of Veterinary Medicine Hannover, Buenteweg 17, 30559 Hanover, Germany

Abstract

The predator–prey-transmitted cestode *Taenia hydatigena* infects a wide range of definitive and intermediate hosts all over the world. Domestic and sylvatic cycles of transmission are considered as well. The parasite has considerable economic importance, particularly in sheep. Here, the molecular characters of *T. hydatigena* cysticerci in sheep from the Nile Delta, Egypt were investigated for the first time. For this purpose, 200 sheep carcasses and their offal were inspected at the municipal abattoir, Dakahlia governorate, Egypt. Cysticerci of *T. hydatigena* were collected and molecularly characterized employing the mitochondrial 12S rRNA gene. Cysticerci were found in 42 (21%) sheep, mostly attached to the omenti, mesenteries and livers. After molecular confirmation, nine isolates were sequenced displaying six different haplotypes. Analysis of the *T. hydatigena* 12S rRNA nucleotide sequences deposited in GenBank revealed 55 haplotypes out of 69 isolates, displaying high haplotype (0.797) and low nucleotide (0.00739) diversities. For the Tajima D neutrality index, a negative value (−2.702) was determined, indicating the population expansion of the parasite. Additionally, global data summarized in this study should be useful to set up effective control strategies against this ubiquitous parasite.

Introduction

The globally distributed taeniid cestode *Taenia hydatigena* Pallas, 1766 (class: Cestoda; subclass: Eucestoda; order: Cyclophyllidea; Family: Taeniidae) infects a wide range of definitive and intermediate hosts (Solusby, 1982). The parasite is usually transmitted in a dog–sheep cycle and can cause high economic losses to the sheep industry (Nourani *et al.*, 2010; Scala *et al.*, 2015).

Taenia hydatigena infections were documented in sheep worldwide. In Egypt, *T. hydatigena* cysticerci were molecularly identified in sheep from the Southern governorates (Omar *et al.*, 2016), but not from the Nile Delta, the largest agricultural region in Egypt. Thus, our objective was to determine for the first time the molecular characteristics of *T. hydatigena* cysticerci from sheep in Dakahlia governorate, the Nile Delta, Egypt. Additionally, we aimed to give a comprehensive overview on different epidemiological, clinical and molecular aspects of *T. hydatigena* infections in hosts other than pigs and cattle as for these species *T. hydatigena* infections have been reviewed previously (Nguyen *et al.*, 2016).

Materials and methods

Experimental study

Animals and study area

Carcasses and visceral organs of 200 local breed sheep aged 1–2 years old and of both sexes, but mostly males, were examined during a routine veterinary inspection in the main municipal slaughterhouse of Dakahlia governorate, Egypt in the period from January to August 2015. Dakahlia is a large (3500 km²) agricultural governorate located in the Nile Delta (North to Cairo) at approximately 31°50'N and 31°00'E with an annual average temperature of 22–28° C. This governorate has about 6 million inhabitants, many of them working in the agriculture and livestock production. Besides Dakahlia, four other governorates (Gharbia, Sharkia, Menoufiya and Kafr Elsheikh) are located in the Nile Delta, and all share their geographical boundaries with each other. In the Nile Delta, frequent movement of sheep for feeding on crop residues in the agricultural areas is common among different governorates. No official estimates for the sheep population in Dakahlia are available; however, approximately 5.5 million sheep are reared in Egypt (FAO, 2015).

Taenia hydatigena cysticerci in the slaughtered sheep were identified morphologically according to Loos-Frank (2000) and viable cysticerci with no signs of caseation or calcification

were collected. From these, the invaginated protoscolices were harvested, washed several times with PBS and stored in 70% ethanol at -20°C . Samples were then transferred to the Institute for Parasitology, University of Veterinary Medicine Hannover, for further analysis.

Molecular analysis

DNA was extracted from the individual protoscolices using the NucleoSpin[®] Tissue kit (Macherey-Nagel, Düren, Germany) according to the manufacturer's instructions. The primer pair 12SRF (5'-AGGGGATAGGACACAGTGCCAGC-3') and 12SRR (5'-CGGTGTGTACATGAGCTAAAC-3') was used to amplify a part of the 12S rRNA gene (Rostami *et al.*, 2015). PCR reactions were carried out in a total volume of 50 μL containing 1 μL (25 μM) of each primer, 1 μL (10 mM) dNTP mix, 5 μL PCR buffer (10 \times), 0.5 μL 5 Prime Perfect Taq DNA polymerase (5 Prime GmbH), 4 μL template DNA and 37.5 μL nuclease-free water. Thermocycling comprised the following conditions: 5 min at 94°C as an initial hot start, followed by 35 cycles of 30 s at 94°C , 45 s at 57°C , 35 s at 72°C and final extension for 10 min at 72°C . A negative control (no template DNA) was included in each experiment.

PCR products were visualized on 1% agarose gels stained with Gel Red[™] nucleic acid stain (BIOTREND Chemikalien GmbH, Cologne, Germany). Bands of about 500 bp were cut off the gel and centrifuged at 5000 *g* for 2 min to squeeze out the amplification products for subsequent commercial Sanger-sequencing (Seqlab, Göttingen, Germany). Obtained sequences were confirmed as *T. hydatigena* using the Basic Local Alignment Search Tool (BLAST, <http://blast.ncbi.nlm.nih.gov/Blast.cgi>). Alignment of the obtained sequences with sequences deposited in GenBank (Table 1, including available sequences from pigs) was conducted employing the software Bioedit (<https://bioedit.software.informer.com/>). Different diversity indices (haplotype and nucleotide), Tajima D neutral index (Tajima, 1989) and the Neighbor-Joining phylogenetic analysis were established using the software MEGA version 6 (Tamura *et al.*, 2013).

Searching strategy

A systematic search was conducted using various databases including PubMed, Science Direct and Google Scholar. The following keywords were used: *T. hydatigena*, *Cysticercus tenuicollis*, canids, sheep, goat, ruminants and wild animals. Publications on cattle and pigs were excluded except one study in cattle and three recent studies in pigs not cited by Nguyen *et al.* (2016). Published papers in local journals from Egypt were also included. Criteria of inclusions were the full text of papers; articles available only as conference or proceeding abstracts were excluded. In total, 251 articles met the criteria to be selected for this review. Of these, 138 reported *T. hydatigena* infections in intermediate hosts, 101 in definitive hosts and 4 in both kinds of hosts. Information on animals, sampling year, country/region, sample size, number of positive samples and organ distribution was gathered from these studies. No statistical methods were used in this review.

Results

Detection of *T. hydatigena cysticerci* in Egyptian sheep and molecular analysis

Taenia hydatigena cysticerci were detected in 42 (21%) of the 200 examined sheep. Most of the cysts were found attached to the omentum and mesenteries; however, five animals carried cysts on the visceral liver surface. *Cysticerci* from nine animals, mostly

old-aged, were caseated or calcified. Each cyst of the 33 animals carrying viable cyst was subjected to molecular analysis.

PCR analyses of the collected viable *T. hydatigena* cysts resulted in single gel bands at the expected size (489 bp). Sequencing of the PCR products yielded high-quality sequences of nine isolates, which were verified as *T. hydatigena* using BLAST, and deposited in GenBank under accession numbers KU671388–KU671396.

Cluster analysis and diversity indices

Sequence alignment of the nine Egyptian *T. hydatigena* isolates revealed 14 polymorphic sites. Overall, six haplotypes were determined. Of these, one comprised three isolates, another one comprised two isolates, and the four remaining haplotypes were detected in single isolates. In addition to the nine isolates obtained in this study, available *T. hydatigena* 12S rRNA nucleotide sequences deposited in GenBank ($n = 63$) were subjected to cluster analysis. Initial phylogenetic analysis displayed a bizarre clustering of two Iranian isolates from sheep (KX084713 and KX094337) and one from goats (KX094338) in a separate branch apart from *T. hydatigena* and *Taenia saginata*. BLAST search with these isolates showed the highest identities with *Echinococcus granulosus* (KX084713) and *Echinococcus ortleppi* (KX094337 and KX094338), respectively. Consequently, these isolates were supposed to be misidentified as *T. hydatigena*, and were excluded from subsequent analyses.

In total, 88 polymorphic sites and 55 haplotypes were detected among the remaining 69 isolates, indicating high haplotype diversity (0.797). Low nucleotide diversity (0.00339) and a negative value (-2.702) for the Tajima *D* neutrality index were also noted. Phylogenetically, our isolates clustered with those of *T. hydatigena* from different definitive and intermediate hosts in different geographical regions; however, the isolate KU671395 displayed marked genetic variation (Fig. 1).

Discussion

Taenia hydatigena can cause serious implications to the livestock economy. In the following sections, we gathered the most important findings of the published papers on *T. hydatigena* infections worldwide, and our results were discussed within the respective sections.

Taenia hydatigena morphology

Morphological characters of the different taeniids overlap considerably (Edwards and Herbert, 1981). *Taenia hydatigena* was first described by Verster (1979), then redescribed by Edwards and Herbert (1981). Loos-Frank (2000) and Hoberg *et al.* (2000) tabulated the results of the earlier studies. Adult *T. hydatigena* from dogs measures up to 1 m in length. The scolex measures 601–682 μm in diameter and bears four suckers (228–273 μm) and a rostellum (373–382 μm) with two rows of 22–44 alternatively arranged large (175–228 μm) and small (118–157 μm) hooks. The mature proglottids have two ovarian lobes of unequal size; the poral lobe is smaller than the aporal one. The vagina has a characteristic dilatation proximal to the genital pore but devoid of the vaginal sphincter. Testis are 400–1000 in number, arranged in one layer and are not confluent posterior to the vitellarium. The cirrus pouch extends to the excretory vessels. The gravid proglottid is wider (4–8 mm) than long and the uterine branches ($n = 6$ –10) have terminal bifurcations. The larval stage (*C. tenuicollis*) from the intermediate hosts can be easily identified. The *cysticerci* measure up to 7–10 mm in size and consist of a yellowish-white bladder completely filling a transparent capsule

Table 1. Partial 12S rRNA nucleotide sequences of *Taenia hydatigena* isolates included in the cluster analysis

Country	Host	GenBank accession number	Reference
Australia	Dog	KJ591569, KJ591571	Jenkins <i>et al.</i> (2014b)
	Red fox	KJ591570	
Egypt	Sheep	KU671388–KU671396	Present study
Italy	Wild boar	FJ608745, FJ608746	Cancrini and Iori (2004)
Iran	Sheep	JQ717210–JQ717248	Rostami <i>et al.</i> (2015)
		KX084713, KX081070, KX094336, KX094337, KX094340, KU745527, KU745526	Unpublished
	Goat	KX084714, KX094338, KX094339, KU750812	Unpublished
Japan	Unknown	AB027135	Unpublished
	Unknown	AB031352	Unpublished
	Dog	AB704400	Kimura <i>et al.</i> (2013)
Mongolia	Dog	AB793739, AB785549, AB787550	Unpublished
	Fox	AB793738	
	Goat	AB793740	

of walnut to apple size with a scolex suspended with a long neck (Loos-Frank, 2000).

Taenia hydatigena infections in definitive hosts

Dogs are the main definitive hosts for *T. hydatigena*; however, sylvatic cycles for transmission are also considered, in which the parasite utilizes wild canids such as foxes, wolves and jackals (Jenkins *et al.*, 2014b). Furthermore, occasionally cats may serve as definitive hosts (Karamon *et al.*, 2019).

Definitive hosts become infected after ingesting the larval stage (*C. tenuicollis*) in tissues of intermediate hosts. Protoscolices evert in the intestine, attach to the intestinal wall and start to grow. The number of the resultant worms is proportional to the number of the cysticerci fed; however, individual weight, length and number of proglottids of adult worms decrease with increasing infection dose (Parmeter *et al.*, 1981). After growth, the ripened proglottids and/or eggs are shed in the feces. *Taenia hydatigena* eggs are environmentally resistant; they can survive for 250–400 days on pastures (Duthy and van Someren, 1948; Cabrera *et al.*, 1995), and in different relative humidity conditions; however, eggs are very sensitive to dry conditions (Thevenet *et al.*, 2017). Eggs lose their viability after heat treatment at 60°C for 5 min (Buttar *et al.*, 2013a).

Worldwide reports on the prevalence of *T. hydatigena* in dogs are listed in Table 2. However, reports are not always comparable because of the highly varying number of dogs sampled, and utilization of different diagnostic tools. Diagnosis of cestode infections in alive dogs requires detection of the proglottids in feces (often after purgative treatment) or in the perianal region by the adhesive tape method. Shape and morphometric characteristics of the proglottid and the gravid uterus offer a sensitive tool of species identification, while detection of eggs in feces by coproscopy does not allow species identification because of identical morphological characteristics of taeniid eggs (Edwards and Herbert, 1981). Indirect detection of *T. hydatigena* coproantigen

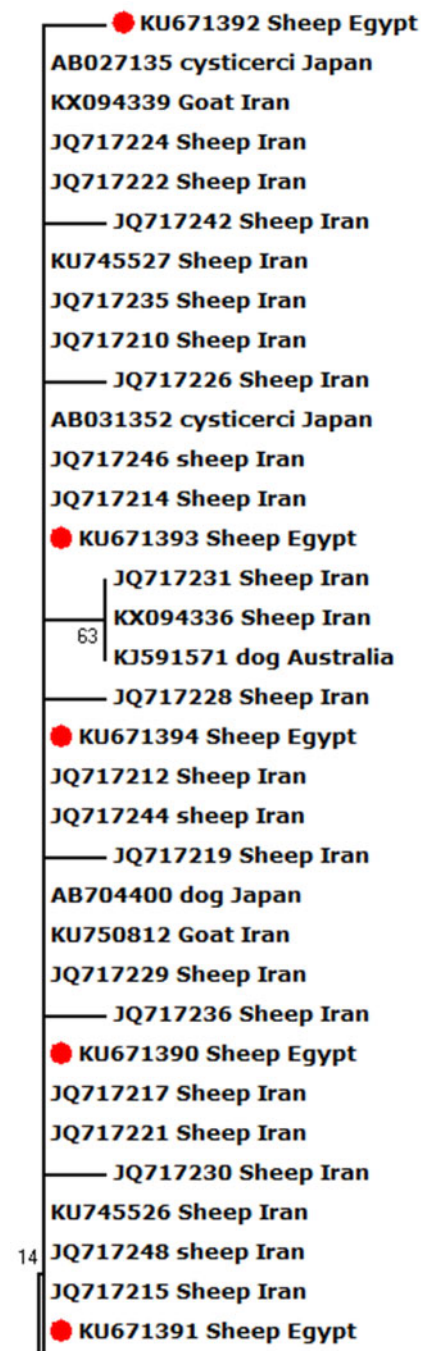


Fig. 1. Neighbour-Joining phylogenetic tree of *T. hydatigena* isolates from different hosts and geographical regions worldwide. *Taenia saginata* was used as an outgroup. The tree was constructed by sequence sections (394 bp) of the mitochondrial 12S rRNA. Scale bar indicates the proportion of sites changing along each branch.

in feces or antibody detection in serum using different types of antigens was tested, but hindered by cross-reactions with other taeniids (Jenkins and Rickard, 1985; Deplazes *et al.*, 1990). In addition, coprophagia of feces of infected definitive hosts may lead to absorption of the antigens through the gut, resulting in false-positive serological reactions (Jenkins *et al.*, 1991), as well as false-positive coproscopic results. Molecular methods using e.g. PCR and employing different genetic markers provide a precise species diagnosis (Cabrera *et al.*, 2002).

Among the worldwide reports, the prevalence is very high in dogs from African countries and the Middle East, where sheep and goats are also highly infected with the larval stage (*C. tenuicollis*). Various reasons contribute to this high prevalence in both definitive and intermediate hosts: (1) most dogs are stray and

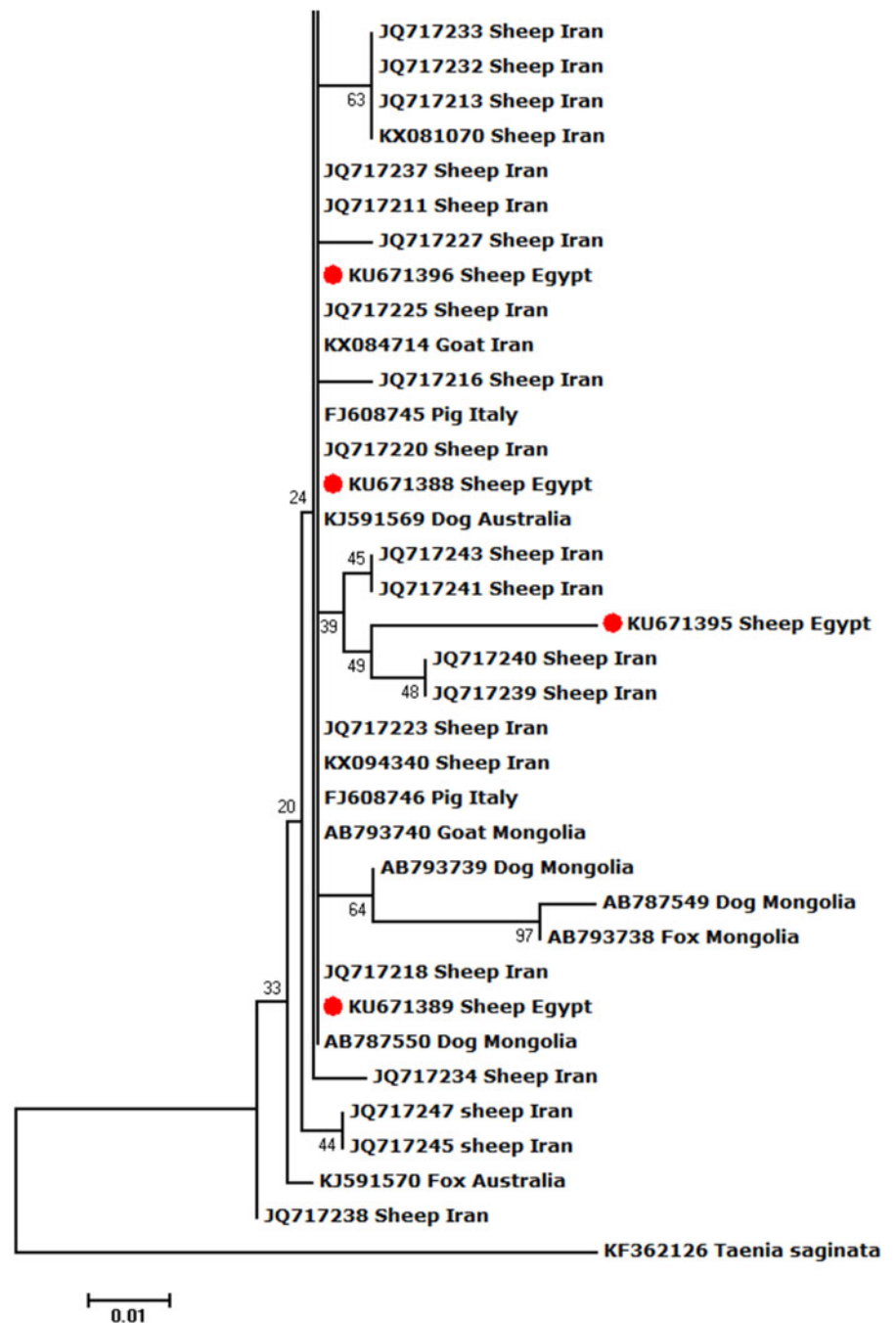


Fig. 1. Continued.

widely spread *T. hydatigena* eggs in the environment, (2) shepherd dogs within sheep flocks are widely used, (3) most dogs do not receive anthelmintic treatment, (4) a nomadic pastoralism system for sheep rearing is used in these countries with sheep feeding on residues of agricultural crops and moving between lands, which increases the infection possibility with *T. hydatigena* eggs, (5) uncontrolled home slaughter of sheep and goats with raw offal usually fed to dogs, and (6) incorrect disposal of infected carcasses in slaughterhouses (Varcasia *et al.*, 2011).

Although stray dogs are usually exposed to parasitic infections more than farmed/owned ones, the effect of dog lifestyle on the prevalence of *T. hydatigena* is not entirely clear due to scarce reports comparing the prevalence in stray and owned or farmed dogs from the same geographical area. Moreover, *T. hydatigena* infections are more common in adult than in young dogs (Lahmar *et al.*, 2017), while no significant difference between males and females was reported (Ajlouni *et al.*, 1984). The

prevalence is increased after certain ceremonial events such as Eid Al-Adha in Muslim countries, in which many sheep are slaughtered mostly outside slaughterhouses (Alishani *et al.*, 2017).

Besides domestic cycles including dogs and, more rarely, cats (Table 3), sylvatic *T. hydatigena* transmission cycles have been investigated in different, mostly European, countries. Data on the prevalence of *T. hydatigena* infections in foxes, jackals as well as wolves are given in Tables 4–6, respectively. *Taenia hydatigena* was also found in the intestines of 3.3% (3/91) free-ranging black bears (*Ursus americanus*) in Alberta, Canada (Dies, 1979). Additionally, *T. hydatigena* was detected in wild felids. Of Eurasian Lynx (*Lynx lynx*), 3% (1/37) were reported to be infected in Estonia (Valdmann *et al.*, 2004), and in the feces of two adult lions from the University of Ibadan Zoological Garden, Nigeria, proglottids were noted. Both lions were donated by the Zoo Leipzig in former East Germany and fed daily on raw goat meat (Ogunrbade and Ogunrinade, 1984).

Table 2. Worldwide reports on *Taenia hydatigena* prevalence in dogs

Country/region	Sampling year	Dog origin	No. tested	No. of positives (%)	Identification method	Reference
Albania Tirana	2004–2009	Suburban areas	111	18 (16.2)	Morphology of adult worms	Xhaxhiu <i>et al.</i> (2011)
Algeria Constantine, Batna	1981–2005	Rural areas	127	NC (>40.0)	Morphology of adult worms	Bentounsi <i>et al.</i> (2009)
Australia Western	NS	NS	304	46 (15.1)	Morphology of adult worms	Chaneet and White (1976)
Mainland, Tasmania	NS	Rural areas	1425	4 (0.3)	PCR	Jenkins <i>et al.</i> (2014a)
New South Wales	NS	Wild dogs	48	4 (8.3)	Morphology of adult worms and PCR	Jenkins <i>et al.</i> (2014b)
Bhutan Thimphu	NS	Slaughterhouses	138	1 (0.7)	PCR	Thapa <i>et al.</i> (2017)
China Heilongjiang	1996–2004	Farmed	178	35 (19.7)	Morphology of adult worms	Wang <i>et al.</i> (2006)
Dutch Antillian Islands	1974	NS	91	NS	Morphology of adult worms	Rep (1975)
Ghana Ashanti	NS	Stray and owned	154	NS ^a	Coproscopy	Amissah-Reynolds <i>et al.</i> (2016)
Germany	2012	Shepherd dogs from 36 farms	165	5 (3.1)	PCR	Rehbein <i>et al.</i> (2016)
India Uttar Pradesh	NS	Stray and owned	1023	419 (40.9)	Morphology of adult worms	Pathak and Gaur (1982)
Different regions	2008	Stray and refuge	411	124 (30.3)	PCR	Traub <i>et al.</i> (2014)
Iran Caspian region	NS	Stray	23	12 (52.2)	Morphology of adult worms	Sadighian (1969)
Azarbaijan, Kordestan, Kermanshah	NS	Stray	83	44 (53.0)	Morphology of adult worms	Dalimi <i>et al.</i> (2006)
Semnan	2006	Rural areas	50	40 (80.0)	Morphology of adult worms	Eslami <i>et al.</i> (2010)
Caspian area	2007	Stray	50	3 (6.0)	Morphology of adult worms	Gholami <i>et al.</i> (2011)
Khorasan Razavi	2008–2009	Stray	100	61 (61.0)	Morphology of adult worms	Adinezadeh <i>et al.</i> (2013)
Chahar Mahal, Bakhtiari	2009	Stray	14	4 (28.6)	Morphology of adult worms	Nabavi <i>et al.</i> (2014)
Khorasan Razavi	2011–2012	Stray	100	43 (43.0)	Morphology of adult worms	Emamapour <i>et al.</i> (2015)
Rasht, Anzali Port, Roudbar, Deylaman	2015	Road-killed	27	5 (18.5)	Morphology of adult worms	Eslahi <i>et al.</i> (2017)
Khuzestan	2013–2014	Rural areas	167	18 (10.8)	PCR	Beiromvand <i>et al.</i> (2018)
Iraq Sulaimani	2005–2006	Stray	50	39 (78.0) ^a	Coproscopy	Bajalan (2010)
Italy Rome	NS	Stray and owned	100	1 (1.0)	Morphology of adult worms	Tassi and Widenhorn (1977)
Sardinia	2014	NS	300	33 (11.0)	Coproantigen ELISA	Scala <i>et al.</i> (2015)
Veneto	2013–2015	Dogs from 99 cattle and sheep farms	208	7 (3.4)	PCR	Cassini <i>et al.</i> (2019)
Jordan different regions	1979–1980	Stray	173	79 (46.0)	Morphology of adult worms	Ajlouni <i>et al.</i> (1984)
Different regions	1992–1995	Stray and semi-stray	340	25 (7.4)	Morphology of adult worms	El-Shehabi <i>et al.</i> (1999)
Kenya Turkana	NS	NS	143	128 (89.5)	Morphology of adult worms	Jenkins <i>et al.</i> (1991)
Kosovo	2012–2013	Owned	504	5 (1.0) ^b 17 (3.4)	PCR	Alishani <i>et al.</i> (2017)
Mexico Mexico city	1997–1998		120	3 (2.5)		

(Continued)

Table 2. (Continued.)

Country/region	Sampling year	Dog origin	No. tested	No. of positives (%)	Identification method	Reference
		Canine rabies control centres			Morphology of adult worms	Eguia-Aguilar <i>et al.</i> (2005)
Morocco Rabat	NS	Stray	57	7 (12.3)	Morphology of adult worms	Pandey <i>et al.</i> (1987)
Nigeria Zaria	NS	Stray	180	122 (67.8)	Morphology of adult worms	Dada <i>et al.</i> (1979)
Zaria	1978–1982	NS	4211	396 (9.4) ^a	Coprospecty	Folaranmi <i>et al.</i> (1984)
Calabar	NS	NS	254	2 (0.8)	Morphology of adult worms	Ugochukwu and Ejimadu (1985)
Poland Podkarpackie	2017–2018	Rural and urban areas	268	14 (5.2)	PCR	Karamon <i>et al.</i> (2019)
South Africa different regions	1960–1977	NS	260	20 (7.7)	Morphology of adult worms	Verster (1979)
Spain Alava	NS	Stray	1040	12 (1.1)	Morphology of adult worms	Benito <i>et al.</i> (2003)
Córdoba	NS	Animal control centre	1800	138 (7.66)	Morphology of adult worms	Martínez-Moreno <i>et al.</i> (2007)
Switzerland	NS	Stray	371	11 (2.9)	Morphology of adult worms	Deplazes <i>et al.</i> (1995)
Thailand lower Northern region	2014	NS	197	14 (7.1) ^a	Coprospecty	Pumidonming <i>et al.</i> (2016)
Tunisia Jendouba, Béjà	NS	Semi-stray	375	35 (9.5)	Morphology of adult worms	Lahmar <i>et al.</i> (2008)
Ariana	2014	Stray	271	60 (22.1)	Morphology of adult worms	Lahmar <i>et al.</i> (2017)
UK Snowdonia	1976–1978	Farmed	485	55 (11.3)	Morphology of adult worms	Edwards <i>et al.</i> (1979b)
Uruguay Florida	NS	Farmed	303	42 (13.9)	Morphology of adult worms	Cabrera <i>et al.</i> (1996)
USA Arizona, New Mexico	NS	Rural camps	429	195 (45.5)	Morphology of adult worms	Schantz <i>et al.</i> (1977)
Wales Clwyd	NS	Foxhounds	162	NS	Morphology of adult worms	Stallbaumer (1987)
Powys	1983–1988	Farmed	882	85 (9.6)	Morphology of adult worms	Jones and Walters (1992a)
Middle region	NS	Foxhounds	875	57 (6.5)	Morphology of adult worms	Jones and Wlaters (1992b)
Zambia Lusaka	1980–1982	Stray, owned	85	15 (17.6)	Morphology of adult worms	Islam and Chizyuka (1983)
Lusaka, Katete, Petauke, Luangwa	2005–2006	Stray	560	73 (13.5) ^{a,c}	Coprospecty	Nonaka <i>et al.</i> (2011)

NS, not stated; NC, not clear.

^aUnidentified *Taenia* spp.

^bDogs were inspected before and after feeding on sheep offal during a religious ceremony (Eid Al-Adha).

^c*Taenia hydatigena* in 35 out of 38 PCR teaniid-positive samples.

Taenia hydatigena infections in the intermediate hosts

During its life cycle, *T. hydatigena* utilizes various intermediate hosts. Besides goats, sheep are the principal intermediate host for this parasite; and often sheep and goats co-graze on the same pastures. Reports on the prevalence of *T. hydatigena* cysticerci in sheep and goats worldwide supplemented with the results from the present study in Egyptian sheep are listed in Tables 7 (sheep) and 8 (goats). Noteworthy, the prevalence in sheep remained similar (19–21%) throughout three reports from Dakahlia governorate, covering the last 10 years. Overall, small ruminants from African countries and the Middle East showed to be infected at quite high percentages (up to 79%) for reasons

given in the above section. Other domestic ruminants such as cattle, buffaloes and camels are also infected (Table 9). Wild boars are considered good hosts (Sgroi *et al.*, 2019, 2020), and wild ruminants including different deer species could play a role in *T. hydatigena* transmission (Table 9). *Taenia hydatigena* cysticerci were also observed attached to the omentum of *Cynomolgus* and Rhesus macaque monkeys (Hobbs *et al.*, 2003; Tsubota *et al.*, 2009).

Epidemiology with focus on sheep

The large number of possible definitive and intermediate hosts for *T. hydatigena* is one key factor for the wide distribution of this

Table 3. Worldwide reports on *Taenia hydatigena* prevalence in cats

Country/region	Sampling year	Cat origin	No. tested	No. of positives (%)	Identification method	Reference
Iran Khorasan, Razavi	2009–2010	Stray	52	1 (1.9)	Morphology of adult worms	Borji <i>et al.</i> (2011)
Ilam	2012–2013	Stray	50	3 (6.0)	Morphology of adult worms	Bahrami and Shamsi (2015)
Poland Podkarpackie	2017–2018	Rural and urban areas	67	1 (1.5)	PCR	Karamon <i>et al.</i> (2019)
UAE Dubai	2004–2008	Feral	240	1 (0.4)	Morphology of adult worms	Schuster <i>et al.</i> (2009)

Table 4. Worldwide reports on *Taenia hydatigena* prevalence in foxes

Country/region	Sampling year	Fox species	No. tested	No. of positives (%)	Identification method	Reference
Australia different regions	NS	Red fox	147	1 (0.7)	Morphology of adult worms	Dybing <i>et al.</i> (2013)
Western Australia	NS	Red fox	255	1 (0.4)	Morphology of adult worms	Jenkins <i>et al.</i> (2014b)
Denmark different regions	1997–2002	Red fox	1040	4 (0.4)	Morphology of adult worms	Saeed <i>et al.</i> (2006)
Germany Southwest	1975–1980	Red fox	3573	1 (0.03)	Morphology of adult worms	Loos-Frank and Zeyhle (1982)
Hesse, Westphalia	1989–1990	Red fox	397	3 (0.8)	Morphology of adult worms	Ballek <i>et al.</i> (1992)
Iran Azarbaijan, Kordestan, Kermanshah	NS	Red fox	22	2 (9.1)	Morphology of adult worms	Dalimi <i>et al.</i> (2006)
Different regions	2003–2004	Red fox	37	2 (5.4)	Morphology of adult worms	Meshgi <i>et al.</i> (2009)
Ilam	2010–2013	Red fox	62	5 (8.0)	Morphology of adult worms	Razmjoo <i>et al.</i> (2014)
Italy Emilia-Romagna	2013–2014	Red fox	57	None (0.0)	Morphology of adult worms	Fiocchi <i>et al.</i> (2016)
Mongolia different regions	2012–2013	Red fox Corsac fox	167 62	23 (13.8) 3 (4.8)	PCR-sequencing of cox1 and 12S rRNA genes	Ulziijargal <i>et al.</i> (2019)
Peru central Peruvian Andes	1995	Grey fox	20	7 (35.0)	Morphology of adult worms	Moro <i>et al.</i> (1998)
Romania different regions	2007–2010	Red fox	561	46 (8.2)	Morphology of adult worms	Barabási <i>et al.</i> (2010)
Saudi Arabia Thumamah	NS	Arabian fox	66	6 (9.0)	Morphology of adult worms	Alagaili <i>et al.</i> (2011)
UK	1977–1978	NS	111	1 (0.9)	Morphology of adult worms	Edwards <i>et al.</i> (1979a)
Different regions	1985–1990	Red fox	843	21 (2.5)	Morphology of adult worms	Richards <i>et al.</i> (1995)
Wales New South region	NS	Red fox	930	None (0.0)	Morphology of adult worms	Ryan (1976)
Mid region	1973–1977	Red fox	280	18 (6.4)	Morphology of adult worms	Hackett and Walters (1980)

NS, not stated.

parasite. Intermediate hosts acquire infection accidentally *via* ingestion of food or water contaminated with *T. hydatigena* proglottids and/or eggs from infected definitive hosts. The presence of infected dogs on the pastures increases the rate and intensity of infection. Gemmell and Macnamara (1976) compared these parameters in different groups of lambs before (group A) and after (group B) the removal of infected dogs from the pasture. At slaughter 6 months later, significantly higher *T. hydatigena* infection rates (65%) and cysts count (4–104) were found in group A compared to group B (6.5% infection rate and 0–3 cysts count).

In addition, mechanical transmission of *T. hydatigena* eggs has been documented in dung beetles (Vargas-Calla *et al.*, 2018), blow flies (Lawson and Gemmell, 1985), potatoes (Buttar *et al.*, 2013b), and vegetable and fruits (Federer *et al.*, 2016). Upon ingestion, eggs hatch in the small intestine. Oncospheres are liberated, penetrate the wall of the gut, and usually reach the liver through the portal blood stream. Sometimes, oncospheres reach other organs such as lungs and kidneys (Scala and Marrosu, 1997). In sheep, oncospheres reach the liver 7 days after ingestion and the immature cysticerci migrate to the liver surface 18 days later (Sweetman and Plummer, 1957). Cysticerci may remain in the liver or drop in

Table 5. Worldwide reports on *Taenia hydatigena* prevalence in golden jackals

Country/region	Sampling year	No. tested	No. of positives (%)	Identification method	Reference
Bulgaria Strandzha Mountains	NS	13	7 (55.0)	Morphology of adult worms	Trifonov et al. (1970)
Hungary different regions	2010–2012	20	3 (15.0)	Morphology of adult worms	Takács et al. (2014)
Iran Azarbaijan, Kordestan, Kermanshah	NS	10	1 (10.0)	Morphology of adult worms	Dalimi et al. (2006)
Different regions	2003–2004	79	6 (7.6)	Morphology of adult worms	Meshgi et al. (2009)
Chahar Mahal, Bakhtiari	2009	18	1 (5.6)	Morphology of adult worms	Nabavi et al. (2014)
Ilam	2010–2013	56	4 (7.1)	Morphology of adult worms	Razmjoo et al. (2014)
Rasht, Anzali Port, Roudbar, Deylaman	2015	11	2 (18.1)	Morphology of adult worms	Eslahi et al. (2017)

NS, not stated.

Table 6. Worldwide reports on *Taenia hydatigena* prevalence in grey wolves

Country/region	Sampling year	No. tested	No. of positives (%)	Identification method	Reference
Estonia	2000–2004	26	3 (12.0)	Morphology of adult worms	Moks et al. (2006)
Germany Lower Saxony	2013–2015	54	16 (29.6) ^a	PCR	Bindke et al. (2019)
Italy different regions	1987–1995	89	42 (47.0)	Morphology of adult worms	Guberti et al. (1993)
Liguria	2011–2014	179	35 (19.6)	PCR	Gori et al. (2015)
Emilia-Romagna	2013–2014	3	2 (66.6)	Morphology of adult worms	Fiocchi et al. (2016)
Foreste Casentinesi National Park	2001–2008	54	22 (40.7)	PCR	Poglayen et al. (2017)
Iran Chahar Mahal, Bakhtiari	2009	4	1 (25.0)	Morphology of adult worms	Nabavi et al. (2014)
Latvia western part	2003–2008	34	14 (41.2)	Morphology of adult worms	Bagrade et al. (2009)
Mongolia different regions	2012–2013	136	27 (19.9)	PCR-sequencing of cox1 and 12S rRNA genes	Ulzijiargal et al. (2019)
Portugal Northern region	2008–2009	68	8 (11.8)	PCR	Guerra et al. (2013)
Serbia	2009–2014	102	10 (9.8)	Morphology of adult worms	Ćirović et al. (2015)
Spain North western	1993–1999	47	21 (44.7)	Morphology of adult worms	Segovia et al. (2001)
Northwest	1993–2001	50	32 (64.0)	Morphology of adult worms	Segovia et al. (2003)
Sweden Västra Götaland län, Värmland, Dalarna	2010	20	5 (25.0)	PCR	Al-Sabi et al. (2018)

^a13.3% (2/15) in wild wolves and 35.9% (14/39) in captive wolves.

the abdominal cavity and attach to the omentum or mesentery. Additionally, cysticerci may develop in the lungs or the serosal surface of the peritoneal cavity. Within 8 weeks, the cysticerci become mature and remain infective to dogs for several months. Cysticerci that died during liver migration may remain surrounded by granulomatous lesions, and calcium salts are deposited around them (Gemmell and Lawson, 1985).

Cysticerci are more common in lambs than in old-aged sheep as well as in fattening lambs than slower growing ones. Due to

immunity (see below), cysticerci are rather uncommon in ewes, in which they may be of considerable volume, sometimes dead and organized, whereas in fattening lambs the cysticerci are usually small (Edwards and Herbert, 1980).

Predilection sites of the cysticerci

Cysticerci of *T. hydatigena* are frequently found attached to the omentum, mesentery, liver and peritoneum (cf. Tables 7 and 8).

Table 7. Worldwide reports on the prevalence of *Taenia hydatigena* cysticerci in sheep (tissues were ordered according to affection rates)

Country/region	No. tested	No. of positives (%)	Affected tissues	Reference
Algeria El Tarf	256	62 (24.2)	Abdominal cavity, liver	Ouchene-Khelifi and Ouchene (2017)
Tiaret	1973	155 (7.8)	Liver, omentum	Mokhtaria <i>et al.</i> (2018)
Argentina Santa Cruz	100 lambs	NS	Liver	Santana <i>et al.</i> (2018)
Australia Victoria	39 216	5338 (13.6)	NS	Broadent (1972)
Benin	366	203 (58.2)	NS	Attindehou and Salifou (2012)
Brazil Paraiba	195	34 (17.4)	Omentum, mesentery, abomasum, rumen, liver, bladder, small intestine	Morais <i>et al.</i> (2017)
Rio Grande do Sul	24	20 (83.3)	Liver, mesentery	Almeida <i>et al.</i> (2018)
Burkina Faso	60	26 (43.3)	NS	Belem <i>et al.</i> (2005)
China Tibet	118	74 (62.7)	NS	Xia <i>et al.</i> (2014)
Colombia Bolivar	23	9 (39.1)	Rumen serosa, abomasal serosa, liver, bladder serosa, diaphragm	Martinez <i>et al.</i> (2016)
Egypt Aswan	669	89 (13.3)	Omentum, mesentery, liver, urinary bladder, lung, diaphragm	Dyab <i>et al.</i> (2017)
Assiut	250	12 (4.8)	Livers only were examined	Taher and Sayed (2011)
Cairo	6257	1456 (23.2)	Omentum, liver, mesentery	EL-Massry (1985)
Cairo	265	45 (16.9)	NS	Abedl-Maogood <i>et al.</i> (2005)
Cairo	426	84 (19.7)	Omentum, liver, diaphragm	Fahmi (2014)
Cairo, Giza, Kaubiya	1000	7 (0.7)	Livers only were examined	Borai <i>et al.</i> (2013)
Dakahlia	151	29 (19.2)	Omentum, mesentery, liver	Abu-Elwafa <i>et al.</i> (2009)
Dakahlia	347	73 (21.0)	Omentum, mesentery, liver	El-Alfy <i>et al.</i> (2017)
Dakahlia	200	42 (21.0)	Omentum, mesentery, liver	Present study
Gharbia	189	32 (16.9)	NS	Sultan <i>et al.</i> (2010)
Minoufiya	1148	207 (18)	Liver, omentum, mesentery, kidney	AbouLaila <i>et al.</i> (2020)
Qena, Sohag, Aswan	500	80 (16.0)	Omentum, mesentery, liver, urinary bladder, diaphragm	Omar <i>et al.</i> (2016)
Zagazig	369	110 (29.8)	NS	El-Azazy and Fayek (1990)
Ethiopia Addis Ababa	560	208 (37.1)	NS	Bekele <i>et al.</i> (1988)
Addis Ababa	630	252 (40.0)	Omentum, liver, mesentery, lung	Samuel and Zewde (2010)
Addis Ababa	600	223 (37.2)	Omentum, liver, mesentery, lung, diaphragm, uterus	Bejiga <i>et al.</i> (2016)
Debre Zeit	92	30 (32.8)	NS	Abede and Esayas (2001)
Debre Zeit	576	327 (56.8)	Omentum, liver, mesentery, peritoneum, lung	Wondimu <i>et al.</i> (2011)
Debre Zeit	262	118 (45.0)	Omentum, liver, mesentery, peritoneum	Abdulatif <i>et al.</i> (2015)
Dessie	510	233 (45.7)	Omentum, mesentery, peritoneum, liver, lung	Gessese <i>et al.</i> (2015)
Dire-Dawa	425	96 (22.8)	Liver, omentum, peritoneum, lung, pelvic cavity	Mekuria <i>et al.</i> (2013)
Haramaya, Harar, Dire Dawa, Jijiga	655	518 (79.0)	Omentum, mesentery, peritoneum, liver	Sissay <i>et al.</i> (2008)
Oromia	232	42 (18.1)	Liver, peritoneum, mesentery, omentum	Admasu <i>et al.</i> (2019)
Germany	4710	785 (16.7)	Omentum	Hasslinger and Weber-Werrighen (1988)
Upper Bavaria	136	19 (14.0)	NS	Rehbein <i>et al.</i> (1996)
Swabian Alb	59	9 (15.3)	NS	Rehbein <i>et al.</i> (1998)
Greece central, Thessaly	2200	647 (29.4)	Abdominal cavity and liver ^a	Christodouloupoulos <i>et al.</i> (2008)
India Andhra Pradesh	20 888	495 (2.3)	NS	Rao <i>et al.</i> (2003)
Northern part	760	17 (2.2)	Abdominal cavity, liver	Singh <i>et al.</i> (2015)
Uttar Pradesh	87	30 (34.4)	NS	Gaur <i>et al.</i> (1980)

(Continued)

Table 7. (Continued.)

Country/region	No. tested	No. of positives (%)	Affected tissues	Reference
Uttar Pradesh	810	300 (37.0)	Mesentery, liver, lungs	Pathak and Gaur (1982)
Iraq Al-Qadissiya	40	19 (47.5)	Liver, lung, spleen	Al-Kardhi (2018)
Basrah	180	73 (40.5)	Liver	Essa and Al-Azizz (2011)
Duhok	4716	31(0.7)	Mesentery, diaphragm, urinary bladder, ovary, uterus, liver, heart, kidney	Ghaffar (2011)
Karbala	240	78 (32.5)	NS	Haddawee <i>et al.</i> (2018)
Kurdistan	13 395	352 (2.6)	NS	Hama <i>et al.</i> (2018)
Ninevah	2000	40 (2.0)	Omentum, mesentery, liver	Al-Bakri (2012)
Iran Fars	7992	2266 (28.3)	Mesentery, liver, kidneys	Oryan <i>et al.</i> (1994)
Fars	1050	184 (17.5)	Mesentery, liver, lung, kidney	Oryan <i>et al.</i> (2012)
Kerman	1336	172 (12.8)	Omentum, liver, mesentery, lung, heart, gall bladder	Radfar <i>et al.</i> (2005)
Mazandaran	1200	49 (4.1)	Liver, omentum	Khanjari <i>et al.</i> (2015)
Tabriz	1400	56 (4.0)	Liver, omentum, mesentery, lung, diaphragm	Mirzaei and Rezaei (2015)
Italy	7781	1135 (14.6)	NS	Scala <i>et al.</i> (2015)
Jordan	2444	226 (9.2)	Peritoneum, liver	Dajani and Khalaf (1981)
Nigeria Eastern	116 ^a	35 (30.2)	NS	Fakae (1990)
Kano	1800	385 (21.4)	NS	Dada and Belino (1978)
Sokoto	261	34 (13.0)	Omentum, liver, mesentery, lungs	Saulawa <i>et al.</i> (2011)
Zaria	28	3 (10.7)	NS	Folaranmi <i>et al.</i> (1984)
Palestine	1489	32 (2.2)	Liver	Adwan <i>et al.</i> (2018)
Saudi Arabia	3045	64 (1.1)	Mesentery, peritoneal cavity	El-Metenawy (1999)
Sudan	3478	1256 (32.4)	NS	El Badawi <i>et al.</i> (1978)
Tanzania Mbeya	27	14 (51.9)	NS	Braae <i>et al.</i> (2015)
Ngorongoro	90	38 (42.2)	Omentum	Miran <i>et al.</i> (2017)
Tunisia Northeast	3692	106 (2.8)	Mesentery, Liver	Khaled <i>et al.</i> (2019)
Turkey Bursa	594	143 (24.1)	Omentum, liver, mesentery, peritoneum	Senlik (2008)
Malatya	1763	214 (12.1)	NS	Kara <i>et al.</i> (2009)
Marmara	50	1 (2.0)	NS	Öncel (2000)
Van	525	149 (28.3)	NS	Oğuz and Değer (2013)
UK	1268 lambs	319 (25.1)	Liver, omentum	Edwards <i>et al.</i> (1979b)
Uruguay	2035	102 (5.0)	NS	Cabrera <i>et al.</i> (2003)

NS, not stated.

^a116 sheep and goats were examined; authors did not specify the number of animals examined in both species.

Lungs, kidneys and brain are less common attachment sites. Sometimes, the cysticerci attach to ovaries, uterine tubes, cervix and the outer surface of the uterus (Smith *et al.*, 1999), and were recently noticed inside the chorio-allantoic membranes of goat fetus, indicating materno-fetal transmission of *T. hydatigena* oncospheres (Payan-Carreira *et al.*, 2008; Al Salihi *et al.*, 2016).

Clinical signs and pathology in intermediate hosts and resulting economic loss

Taenia hydatigena infections in intermediate hosts are usually asymptomatic; however, hepatitis cysticercosis caused by migrating cysticerci is common sequelae of infection (Blazek *et al.*, 1985; Nourani *et al.*, 2010), and may be fatal in heavy infections producing massive destruction to the liver parenchyma (Scala *et al.*, 2016). Acute fatal cysticercosis in sheep and goats has been reported from

the UK (Livesey *et al.*, 1981), Italy (Manfredi *et al.*, 2006), Turkey (Yildirim *et al.*, 2006), Greece (Koutsoumpas *et al.*, 2013) and Israel (Perl *et al.*, 2015). Lung involvement is also commonly observed during acute cysticercosis (Darzi *et al.*, 2002). Additionally, severe hepatic alterations due to the involvement of the liver with multiple small (3–6 mm) cysticerci of *T. hydatigena* were documented in a camel calf from a farm in Dubai, UAE. This calf died shortly after translocation with his mother from Pakistan, and the majority of the cysticerci were in a stage of caseous degeneration; their identity was molecularly confirmed (Schuster *et al.*, 2015).

The infection dose correlates with the severity of the disease. Edwards and Herbert (1980) fed six lambs with *T. hydatigena* eggs at different doses; four lambs showed clinical signs, and two of them died. Both dead lambs were infected with 25 000 eggs and exhibited fever, lethargy, anorexia and jaundice. Livers were grossly enlarged with numerous haemorrhagic tracts. The

Table 8. Worldwide reports on the prevalence of *Taenia hydatigena* cysticerci in goats (tissues were ordered according to affection rates)

Country/region	No. tested	No. of positives (%)	Affected tissues	Reference
Algeria El Tarf	164	72 (43.9)	Abdominal cavity, liver	Ouchene-Khelifi and Ouchene (2017)
Tiaret	1175	263 (22.3)	Omentum, liver	Mokhtaria <i>et al.</i> (2018)
Australia Queensland	374 580	8923 (2.4)	NS	Jenkins <i>et al.</i> (2018)
Bangladesh	3036	1656 (54.5)	Mesentery, peritoneum, liver, kidney	Islam <i>et al.</i> (1995)
Benin	390	207 (53.1)	NS	Attindehou and Salifou (2012)
Brazil Paraíba	195	76 (39.0)	Omentum, mesentery, abomasum, rumen, liver, carcass, small intestine, large intestine	Morais <i>et al.</i> (2017)
China Hunan	479	54 (11.3)	Mesentery, omentum, liver, pelvic cavity	Ma <i>et al.</i> (2014)
Tibet	147	69 (46.9)	NS	Xia <i>et al.</i> (2014)
Egypt Aswan	45	1 (2.2)	NS	Elshahawy <i>et al.</i> (2014)
Aswan	484	117 (24.2)	Omentum, mesentery, liver	Dyab <i>et al.</i> (2017)
Qena, Sohag, Aswan	350	67 (19.0)	Omentum, mesentery, liver	Omar <i>et al.</i> (2016)
Zagazig	240	80 (33.3)	NS	El-Azazy and Fayek (1990)
Ethiopia Addis Ababa	768	358 (46.6)	Omentum, liver, mesentery, lung	Samuel and Zewde (2010)
Addis Ababa	300	132 (44.0)	Omentum, liver, mesentery, lung, diaphragm, rectum	Bejiga <i>et al.</i> (2016)
Debre Zeit	91	31 (34.0)	NS	Abede and Esayas (2001)
Debre Zeit	576	368 (63.9)	Omentum, mesentery, liver, peritoneum, lung	Wondimu <i>et al.</i> (2011)
Debre Zeit	280	151 (53.9)	Omentum, liver, mesentery, peritoneum	Abdulatif <i>et al.</i> (2015)
Dessie	420	304 (72.3)	Omentum, mesentery, peritoneum, lung, liver	Gessese <i>et al.</i> (2015)
Dire-Dawa	420	112 (26.4)	Liver, omentum, peritoneum, pelvic cavity, lung	Mekuria <i>et al.</i> (2013)
Haramaya, Harar, Dire Dawa, Jijiga	632	336 (53.0)	Omentum, mesentery, peritoneum, liver	Sissay <i>et al.</i> (2008)
Oromia	268	60 (22.4)	Carcass, mesentery, peritoneum, liver, omentum	Admasu <i>et al.</i> (2019)
Greece central, Thessaly	2200	29.41%	Abdominal cavity and liver ^a	Christodoulopoulos <i>et al.</i> (2008)
India Andhra Pradesh	798	13 (1.6)	NS	Rao <i>et al.</i> (2003)
Bareilly	382	88 (23.0)	Omentum, mesentery, liver, diaphragm	Ganaie <i>et al.</i> (2018)
Chhattisgarh	652	137 (21.0)	Omentum, mesentery, liver, diaphragm	Nath <i>et al.</i> (2010)
Northern part	2439	118 (4.8)	Abdominal cavity, liver	Singh <i>et al.</i> (2015)
Uttar Pradesh	757	202 (26.6)	NS	Gaur <i>et al.</i> (1980)
Uttar Pradesh	1015	277 (27.3)	Mesentery, liver, spleen, gall bladder	Pathak and Gaur (1982)
Iraq Basrah	90	24 (26.2)	Liver	Essa and Al-Azizz (2011)
Karbala	240	85 (35.4)	NS	Haddawee <i>et al.</i> (2018)
Kurdistan	693	18 (2.6)	NS	Hama <i>et al.</i> (2018)
Ninevah	400	40 (10.0)	Omentum, mesentery, liver	Al-Bakri (2012)
Iran Fars	950	523 (55.0)	Mesentery, liver, lung, kidney	Oryan <i>et al.</i> (2012)
Kerman	1674	302 (18.0)	Omentum, liver, mesentery, uterus, peritoneum, urinary bladder, rumen, lung, heart	Radfar <i>et al.</i> (2005)
Mazandaran	1200	52 (4.33)	Liver, omentum, diaphragm	Khanjari <i>et al.</i> (2015)
Tabriz	1000	49 (4.9)	Liver, omentum, mesentery, diaphragm, lung	Mirzaei and Rezaei (2015)
Jordan	1474	91 (6.2)	Peritoneum, liver	Dajani and Khalaf (1981)
Nigeria Ibadan	120	40 (33.3)	NS	Nwosu <i>et al.</i> (1996)
Kano	1260	431 (34.2)	NS	Dada and Belino (1978)
Zaria	21	1 (4.7)	NS	Folaranmi <i>et al.</i> (1984)
Saudi Arabia	312	15 (4.8)	NS	El-Metenawy (1999)

(Continued)

Table 8. (Continued.)

Country/region	No. tested	No. of positives (%)	Affected tissues	Reference
South Africa	60	21 (0.4)	NS	Boomker <i>et al.</i> (1994)
Sudan	960	278 (29.0)	NS	El Badawi <i>et al.</i> (1978)
Khartoum	18	7 (38.9)	NS	Hamid <i>et al.</i> (1991)
Tanzania Mbeya	392	179 (45.7)	Omentum, mesentery, liver, peritoneum, lungs	Braae <i>et al.</i> (2015)
Ngorongoro	90	55 (61.1)	Omentum	Miran <i>et al.</i> (2017)
Tunisia Northeast	78	7 (8.9)	Mesentery	Khaled <i>et al.</i> (2019)

NS, not stated.

^a116 sheep and goats were examined; authors did not specify the number of animals examined in both species.**Table 9.** Worldwide reports on the prevalence of *Taenia hydatigena* cysticerci in miscellaneous intermediate hosts

Country/region	Animal species	No. tested	No. of positives (%)	Affected tissue	Reference
Austria Ostrong, Tullner, Donauauen	Sika deer	108	1 (0.9)	NS	Rehbein and Visser (2007)
Bangladesh	Water buffalo	180	20 (11.1)	NS	Islam <i>et al.</i> (1992)
Belarussia	Elk	18	8 (44.4)	NS	Shimalov and Shimalov (2003)
	Red deer	16	1 (6.2)		
	Roe deer	16	2 (12.5)		
Canada Alberta	Moose	191	116 (61.0)	Liver	Pybus (1990)
	Mule deer	247	35 (14.0)		
Cameroon Yaoundé	Pigs ^a	416	28 (6.7)	Omental and mesenteric fat	Assana <i>et al.</i> (2019a)
Cameroon Yaoundé	Pigs ^a	305	16 (5.24)	Omental and mesenteric fat	Assana <i>et al.</i> (2019b)
Egypt South	Camel	103	1 (0.9)	Liver	Omar <i>et al.</i> (2016)
England Southern	Fallow deer	309	38 (12.3)	Mesentery, omentum, liver	Chapman and Chapman (1987)
Italy Southern	Wild boar	1	1 (100)	Liver, spleen, omentum	Sgroi <i>et al.</i> (2019)
Southern	Wild boar	3363	229 (6.8)	Liver, omentum, lung, diaphragm, spleen, colon	Sgroi <i>et al.</i> (2020)
South Africa	Grey duiker	13	5 (38.4)	NS	Boomker <i>et al.</i> (1987)
	Blue duiker	3	1 (33.3)	NS	Boomker <i>et al.</i> (1991)
Thailand Tak	Pigs ^a	16	13	NS	Chaisiri <i>et al.</i> (2019)
Tunisia Sidi Thabet	Antelope	1	1 (100)	15 cysts in liver, 18 in abdominal cavity	Boufana <i>et al.</i> (2017)
Turkey Black sea	Roe deer	15	1 (6.6)	Mesentery	Bolukbas <i>et al.</i> (2012)
Tavan	Cattle ^a	220	18 (8.8)	NS	Değer and Biçek (2005)
UAE Abu Dhabi	Oryx	213	12 (5.6)	Lung, liver, omentum and mesentery	Chege <i>et al.</i> (2016)
	Camel	1	1 (100)	Liver	Schuster <i>et al.</i> (2019)
USA Oregon	Bighorn sheep	6	2 (33.3)	Livers only were examined	Kistner <i>et al.</i> (1977)
Texas	White-tailed deer	86	6 (7.0)	NS	Waid <i>et al.</i> (1985)
Florida	White-tailed deer	124	1 (0.8)	NS	Forrester and Rausch (1990)

^aThose studies have been included as it has not been mentioned in the review of Nguyen *et al.* (2016).

liver from one lamb harboured 5318 juvenile cysticerci (8 mm), which were also recovered from washings of the abdominal cavity and lungs. The two recovered lambs showed clinical signs 3–4 days after infection, which continued for 18–20 days; one of

them was infected with the same dose, whereas the other lambs, as well as lambs with no clinical signs, were given trickle doses each of 5000 eggs in alternate days. Elevated levels of liver enzymes (GOT and GPT) were observed in all infected lambs.

In chronic infections with low parasite burdens, most liver lesions become resolved. Livers may pass for human consumption or may be partially or completely condemned (Trees *et al.*, 1985). Based on liver condemnations of lambs, resulting economic losses were exemplarily estimated to be \$65 000 and \$370 600 annually in Ethiopia and Italy, respectively (Wondimu *et al.*, 2011; Scala *et al.*, 2015).

Diagnosis

Diagnosis of *T. hydatigena* infections in definitive hosts including the limitations of e.g. coproscopy are described in the respective section above. In intermediate hosts, macroscopic examination for *T. hydatigena* cysticerci during meat inspection is the diagnostic gold standard. However, routine meat inspection can be of low sensitivity because immature small cysts often remain unnoticed. Antibody detection assays offer diagnosis in sera from live animals. However, as described above, these assays are limited regarding species identification, because antigens of different *Taenia* species are very similar and, therefore, cross-reactions between *Taenia* spp. are common in immunodiagnosis (Craig and Rickard, 1980). Craig and Rickard (1981) used the ELISA technique to diagnose *T. hydatigena* and *T. ovis* in experimentally infected lambs. They found oncospherical antigens prepared from eggs to be non-species-specific, and the antibodies raised against these antigens were detectable 1 week post-infection, reached their peak after 3–4 weeks and lasted for 8–12 weeks, while antibodies resulting from strobilate antigen extracts lasted for a longer time (18 weeks). El-Massry (1999) tested sera from 500 sheep for *T. hydatigena* and found 151 (30.2%) individuals to be ELISA-positive. During postmortem inspection, 100 sheep were diagnosed to harbour *T. hydatigena* cysticerci. Of these, 91 tested seropositive, while in the remaining 60 seropositive sheep, no *T. hydatigena* cysticerci were found. Recently, hepatic ultrasonography was proven to be effective for the diagnosis of acute cysticercosis in lambs (Corda *et al.*, 2020).

Immunity

In dogs as definitive hosts, no immunity develops after *T. hydatigena* infection and re-infection is common (Heath *et al.*, 1980). For example, Cabrera *et al.* (1996) noted *T. hydatigena* re-infection in dogs 2 months after anthelmintic treatment. This lack of immunity in dogs and presumably other definitive hosts sustains the persistence and distribution of the parasite.

In contrast, sheep develop immunity against *T. hydatigena* already after primary infection. This immunity manifests by (1) absence or reduction in the number of cysticerci, (2) loss of cysticerci viability or (3) both (Gemmell *et al.*, 1990). Gemmell (1964) reported solid immunity in sheep after oral challenge infection with *T. hydatigena* eggs ($n = 2500$) following parenteral injection of viable *T. hydatigena* eggs or active embryos. In addition, the use of culture antigens of hatched *T. hydatigena* oncospheres provided a good level of protection against reinfection (Onawunmi and Coles, 1980). A study investigating the possible involvement of neutrophils in the immunity against *T. hydatigena* infection showed that there might be an interplay between these cells and antibodies: *in vitro* experiments with neutrophils collected from the mammary glands of both *T. hydatigena* infected and uninfected sheep, attached to and killed oncospheres in the presence of serum from infected sheep (Beardsell and Howell, 1984).

Acquired immunity to *T. hydatigena* is transferred from the dam to her offspring. After grazing on contaminated pastures for 10 days, Gemmell *et al.* (1990) noted a lower proportion of viable *T. hydatigena* cysticerci in lambs from ewes previously

exposed to *T. hydatigena* than those from previously unexposed ewes. Additionally, short-acting protection of 1–3 weeks was detected in lambs receiving colostrum from infected ewes (Jacobs *et al.*, 1994).

Treatment and control

Taenia hydatigena infections in dogs or other definitive hosts can easily be treated with the isoquinoline derivatives praziquantel and epsiprantel. Additionally, several benzimidazoles, niclosamide and nitroscanate are effective against taeniosis (Saari *et al.*, 2010). No reports on anthelmintic resistance of *T. hydatigena* are available. Praziquantel in high doses (15 mg kg^{-1}) was also used successfully in lambs suffering from acute *T. hydatigena* cysticercosis (Scala *et al.*, 2016); however, no product is licensed in this indication. Unlike *Taenia solium* and *Taenia saginata*, no vaccination trials to control *T. hydatigena* infections in both definitive and intermediate hosts are reported.

Improved regional epidemiological data on *T. hydatigena* occurrence is essential for its control, especially in endemic areas. Careful routine meat inspection procedures in slaughterhouses including tissues other than the cysticerci predilection sites, and proper condemnation of the infected tissues or organs are mandatory. Various strategies were evaluated to control this ubiquitous parasite. Of them, regular simultaneous treatment of both definitive and intermediate hosts proved its efficacy (Harris *et al.*, 1980).

Molecular characterization of *T. hydatigena* isolates

Molecular analysis of *T. hydatigena* isolates, adult worms and cysticerci, aids in understanding the circulation patterns of this parasite among different definitive and intermediate hosts, and in the implementation of effective control strategies. Based on the mitochondrial 12S rRNA gene, the present study is the first to describe the molecular characteristics of *T. hydatigena* isolates from sheep in Dakahlia governorate, Egypt. Using this marker, one of our isolates showed to be genetically different from the others. By use of another marker (cox1), Omar *et al.* (2016) investigated the molecular characteristics of isolates from sheep, goats and camels in Southern Egypt. Earlier molecular analyses using mitochondrial genes reported nad1 displaying greater inter-taxon sequence variations than cox1 (Gasser *et al.*, 1999), and 12S rRNA displaying greater *T. hydatigena* intra-taxon variation than cox1 (Rostami *et al.*, 2015). Furthermore, variable sections of the nuclear 18S rRNA gene are highly discriminative among members of the genus *Taenia* including *T. hydatigena* (Yan *et al.*, 2013).

Many different *T. hydatigena* haplotypes have been recorded in different geographical regions. Based on our analysis including 69 worldwide *T. hydatigena* isolates, high haplotype diversity was noted, which could be attributed to (1) different definitive and intermediate hosts, (2) hosts population and dispersal in countries, (3) farming practices, and (4) infection rate (Boufana *et al.*, 2015; Rostami *et al.*, 2015). However, the existence of a common lineage of *T. hydatigena* circulating worldwide was suggested (Boufana *et al.*, 2015; Sgroi *et al.*, 2020), possibly resulting from the worldwide circulation of the parasite through human and animal transportation (Rostami *et al.*, 2015). Based on the biochemical, morphological and molecular differences in *T. hydatigena* cysticerci from intermediate hosts, the possibility of strain variations is stated (Abidi *et al.*, 1989; Radfar *et al.*, 2005; Boufana *et al.*, 2015; Singh *et al.*, 2015). Significant results on the genetic variation and population structure of *T. hydatigena* are summarized in Table 10.

Table 10. Worldwide reports on molecular characterization of *Taenia hydatigena* isolates

Country/region	Animal species	No. of isolates	Marker gene	Remarks	Reference
Australia Western, New South Wales	Wolf	1	rrnS	Sequences were similar to isolates from China with single nucleotide substitution	Jenkins <i>et al.</i> (2014b)
	Dog	2			
Australia Victoria UK Liverpool UK Wales	Sheep	1	ITS2-rDNA	PCR-RFLP profiling of different taeniid cestode species. Using 4 endonucleases, the technique could be used for differentiating between <i>T. hydatigena</i> , <i>Taenia ovis</i> and <i>Taenia pisiformis</i>	Gasser and Chilton (1995)
	Dog	2			
	Dog	1			
	Dog	1			
China	Dog	8	cox1, nad4, ITS1	Higher variation in ITS1 than in nad4 and cox1	Dai <i>et al.</i> (2012)
	Sheep	1	18S rRNA	<i>T. hydatigena</i> is genetically more closely related to <i>Taenia pisiformis</i> than to other <i>Taenia</i> species	Yan <i>et al.</i> (2013)
Tibet	Pig	NS	cox2	Very close resemblance to other isolates from China	Luo <i>et al.</i> (2017)
Mongolia	Goat	2	cox1, nad4, cyt b	2 haplotypes at each locus	Zhang <i>et al.</i> (2018)
Egypt Upper Egypt	Sheep, goat, camel	NS	cox1	Camel isolate is genetically different from those of sheep and goats	Omar <i>et al.</i> (2016)
Menoufiya	Sheep	NS	cox1, nad1	Isolates are highly similar to those from Upper Egypt and Iran	AbouLaila <i>et al.</i> (2020)
Nile Delta	Sheep	9	12S rRNA	6 haplotypes, 1 of them displayed high genetic variation	Present study
Finland, Sweden	Wolf	23	cox1	8 haplotypes, 1 of them is common (13 isolates from wolves). None of the haplotypes from reindeer and sheep was found in wolves	Lavikainen <i>et al.</i> (2011)
	Reindeer	1			
	Sheep	1			
Iran	Dog	3	cox1	2 haplotypes, low genetic diversity	Mirbadie <i>et al.</i> (2019)
Tehran, Alborz, Kerman	Sheep	100	cox1, 12S rRNA	40 cox1 and 39 12S rRNA haplotypes. 12S rRNA gene is more variable than cox1	Rostami <i>et al.</i> (2015)
Kerman	Sheep	20	ITS1 microsatellite	Direct rapid identification of 4 <i>Taenia</i> species using conventional PCR	Shamsaddini <i>et al.</i> (2017)
Khuzestan	Dog ^a	18	SS rRNA	–	Beiromvand <i>et al.</i> (2018)
Iraq Al-Qadissiya	Sheep	13	cox1	–	Al-Kardhi (2018)
Baghdad	Dog	20	18S rRNA	Isolates are very similar to those from China	Faraj and Al-Amery (2018)
Kurdistan	Sheep, goat	NS	cox1	Isolates are closely related to those from Palestine, Iran and Turkey	Hama <i>et al.</i> (2018)
Italy Sardinia	Sheep, goat, wild boar	27 cysticerci, 8 worms ^b	cox1, nad1	High haplotype and low nucleotide diversity. Common lineage of <i>T. hydatigena</i> across the world. Existence of <i>T. hydatigena</i> variants (isolates from sheep differ from those from goats and pigs)	Boufana <i>et al.</i> (2015)
Nigeria Maiduguri	Sheep	8	cox1, nad1, nad5	<i>T. hydatigena</i> isolates of sheep origin were genetically distinct from those of goats	Ohirolei <i>et al.</i> (2019)
	Goats	24			
Palestine Nablus	Sheep	20	cox1	9 haplotypes, 1 of them is common in 55% of isolates	Adwan <i>et al.</i> (2018)
Peru	Trauca	2	cox1	Identical isolates from both animal species	Gomez-Puerta <i>et al.</i> (2015)
	Red brocket deer	1			
Poland	Wild boar	2	cox1	Isolates are related to those from wolves in Germany, Finland and Sweden	Filip <i>et al.</i> (2019)
	Moose	2			
Poland, Ukraine, UK Wales	Pig	8	nad1	Samples from Ukraine and Wales showed major differences. Samples from neighbouring locations in Poland were similar to each other	Kedra <i>et al.</i> (2001)
Sudan Khartoum	Sheep	11	cox1, nad1		Muku <i>et al.</i> (2020)

(Continued)

Table 10. (Continued.)

Country/region	Animal species	No. of isolates	Marker gene	Remarks	Reference
				3 and 2 haplotypes were identified for the nad1 and cox1 genes respectively	
Tanzania Mbeya	Sheep, goat	12	cox1	4 haplotypes with 1–3 SNPs	Braae <i>et al.</i> (2015)
Turkey	Red deer	2	cox1	Isolates are related to those from reindeer in Finland	Cengiz <i>et al.</i> (2019)
Ankara	Goat	1	cox1	Cysticerci from a liver of a 1-month-old goat	Utuk and Piskin (2012)
Upper Firat	Sheep, goat	20/animal species	nad1	16 haplotypes in sheep and 15 in goats	Kilinc <i>et al.</i> (2019)
UAE Dubai	Camel calf	36	cox1, nad1	Isolates were clustered closely with isolate from pigs in China	Schuster <i>et al.</i> (2015)
UK Wales	Dog	1	cox1, nad1	Interspecific nucleotide variation in NADH was greater than in cox1	Gasser <i>et al.</i> (1999)

cox, mitochondrial cytochrome c oxidase subunit gene; nad, mitochondrial NADH dehydrogenase subunit gene; ITS, internal transcribed spacer; SS rRNA (rrnS), small-subunit ribosomal RNA gene; cytb, cytochrome b; ND, not done; NS, not stated.

^aEggs from dog feces.

^b*Taenia hydatigena* tapeworm isolates from necropsied dogs in Sicily ($n=1$), Tunisia ($n=5$) and Wales ($n=2$) were included for comparison.

Conclusion

Taenia hydatigena is a ubiquitous parasite circulating worldwide and utilizing various intermediate and definitive hosts in domestic and sylvatic cycles of transmission. In this review, we gathered the available information from the earlier publications about *T. hydatigena* in both kinds of hosts. In addition, we updated the prevalence of *T. hydatigena* cysticerci from sheep in Egypt, where sheep are mainly reared in small flocks including one or two dogs for protection. No reports on this parasite in dogs from Egypt are available, thus a study on the dispersal of *T. hydatigena* in dogs, particularly shepherd ones, from Egypt is needed. For the first time, molecular characteristics of isolates from sheep in the Nile Delta were determined. Analysis of newly generated and published Genbank-retrieved 12S rRNA partial nucleotide sequences of *T. hydatigena* elucidated genetic variants among the Egyptian isolates and a future large-scale study with a large number of samples from various intermediate and definitive hosts is desirable to confirm the present findings.

Acknowledgements. We thank Mansoura University, Egypt, for supporting Ibrahim Abbas with a 1-month externship at the Institute for Parasitology, Center for Infection Medicine, University of Veterinary Medicine Hannover, Germany.

Financial support. This research received no specific grant from any funding agency, commercial or not-for-profit sectors.

Conflict of interest. None.

Ethical standards. All national and international ethical guidelines were followed during the handling of the sampled animals. This study was approved by the ethics committee at the Faculty of Veterinary Medicine, Mansoura University, Egypt.

References

- Abdulatif A, Tsegay AK and Mammo B (2015) Prevalence, cyst distribution in visceral organs and economic loss of *Cysticercus tenuicollis* in small ruminants slaughtered at Bishoftu, Elfora Export Abattoir. *American-Eurasian Journal of Scientific Research* **10**, 210–220.
- Abede W and Esayas G (2001) Survey of ovine and caprine gastro-intestinal helminthosis in eastern part of Ethiopia during the dry season of the year. *Revue de Medecine Veterinaire* **152**, 379–384.
- Abedl-Maogood SZ, Hassan AA, Ramadan E and Mousa W (2005) *Studies on Metacestodes of Sheep with Reference to Serodiagnosis of Coenurus Cerebralis* (PhD thesis), Cairo University, Giza, Egypt.
- Abidi SMA, Nizami WA, Khan P, Ahmad M and Irshadullah M (1989) Biochemical characterization of *Taenia hydatigena* cysticerci from goats and pigs. *Journal of Helminthology* **63**, 333–337.
- AbouLaila M, Mohamed AS, Roshdey T and El-Khatam A (2020) Infection rate and biochemical characterization of *Cysticercus tenuicollis* from sheep in Minoufiya governorate, Egypt. *Veterinary Parasitology: Regional Studies and Reports* **20**, 100396. <https://doi.org/10.1016/j.vprsr.2020.100396>
- Abu-Elwafa SA, Al-Araby MA and Abbas IE (2009) Metacestodes among sheep slaughtered at Mansoura abattoir, Dakahlia province, Egypt. *Mansoura Veterinary Medical Journal* **11**, 21–33.
- Adinezadeh A, Eshrat Beigom KIA, Mohebal M, Shojaee S, Rokni MB, Zarei Z and Mowlavi G (2013) Endoparasites of stray dogs in Mashhad, Khorasan Razavi province, Northeast Iran with special reference to zoonotic parasites. *Iranian Journal of Parasitology* **8**, 459–466.
- Admasu Y, Tadesse T and Reta Z (2019) Study on prevalence of small ruminant *Cysticercus tenuicollis* and its monetary loss at Bishoftu Elfora Export Abattoir, Oromia, Ethiopia. *Journal of Dairy and Veterinary Sciences* **9**, 555759.
- Adwan K, Jayousi A, Abuseir S, Abbasi I, Adwan G and Jarrar N (2018) Genetic diversity of *Taenia hydatigena* in the northern part of the West Bank, Palestine as determined by mitochondrial DNA sequences. *Acta Parasitologica* **63**, 299–303.
- Ajlouni AQ, Saliba EK and Disi AM (1984) Intestinal cestodes of stray dogs in Jordan. *Zeitschrift für Parasitenkunde* **70**, 203–210.
- Al-Bakri HS (2012) Prevalence of Tenuicollosis among livestock slaughtered at Ninevah Governorate-Iraq. *Journal of Advanced Biomedical and Pathobiology Research* **2**, 30–39.
- Al-Kardhi IKA (2018) Molecular detection of *Taenia hydatigena* cysts from the visceral organs of sheep slaughtered at AL-Qadissyia governorate abattoir. *Mirror of Research in Veterinary Sciences and Animals* **6**, 21–27.
- Al-Sabi MNS, Rääf L, Osterman-Lind E, Uhlhorn H and Kapel CMO (2018) Gastrointestinal helminths of gray wolves (*Canis lupus lupus*) from Sweden. *Parasitology Research* **117**, 1891–1898.
- Alagaili AN, Mohammed OB and Omer SA (2011) Gastrointestinal parasites and their prevalence in the Arabian red fox (*Vulpes vulpes arabica*) from the Kingdom of Saudi Arabia. *Veterinary Parasitology* **180**, 336–339.
- Alishani M, Sherifi K, Rexhepi A, Hamidi A, Armua-Fernandez MT, Grimm F, Heggin D and Deplazes P (2017) The impact of socio-cultural factors on transmission of *Taenia* spp. and *Echinococcus granulosus* in Kosovo. *Parasitology* **144**, 1736–1742.
- Almeida FA, Bassetto CC, Amarante MRV, Albuquerque ACA, Starling RZC and Amarante AFTD (2018) Helminth infections and hybridization

- between *Haemonchus contortus* and *Haemonchus placei* in sheep from Santana do Livramento, Brazil. *Revista Brasileira de Parasitologia Veterinária* 27, 280–288.
- Al Salihi K, Rahee SS and Ali AH (2016) *Cysticercus tenuicollis* vesicle in goat pregnant uterus and fetal body: report of a case. *Basrah Journal of Veterinary Research* 15, 45–51.
- Amissah-Reynolds PK, Monney I, Adowah LM and Agyemang SO (2016) Prevalence of helminths in dogs and owners' awareness of zoonotic diseases in Mampong, Ashanti, Ghana. *Journal of Parasitology Research* 2016, 1715924. <http://dx.doi.org/10.1155/2016/1715924>.
- Assana E, Awah-Ndukum J, Djonmaïla JD and Zoli AP (2019a) Prevalence of porcine *Taenia solium* and *Taenia hydatigena* cysticercosis in Cameroon. *Preventive Veterinary Medicine* 169, 104690. <https://doi.org/10.1016/j.prevetmed.2019.104690>.
- Assana E, Awah-Ndukum J, Djonmaïla JD, Djiathe HD, Awé C, Manchang TK and Zoli AP (2019b) A comparison of *Taenia solium* and *Taenia hydatigena* infection in pigs using serological diagnosis and post-mortem inspection methods in Benoué division, North Cameroon. *Veterinary Parasitology: Regional Studies and Reports* 17, 100306.
- Attindehou S and Salifou S (2012) Epidemiology of cestodes infections in sheep and goats in Benin. *Veterinary Research* 5, 59–62.
- Bagrade G, Kirjušina M, Vismans K and Ozoliņš J (2009) Helminth parasites of the wolf *Canis lupus* from Latvia. *Journal of Helminthology* 83, 63–68.
- Bahrami AM and Shamsi M (2015) Zoonotic parasitic infections of cats in human community: a histopathological study. *Journal of Basic Research in Medical Sciences* 2, 49–56.
- Bajalan MMM (2010) Prevalence of intestinal helminths in stray dogs of Kalar city/Sulaimani province. *Iraqi Journal of Veterinary Medicine* 34, 151–157.
- Ballek D, Takla M, Ising-Volmer S and Stoye M (1992) The helminth fauna of red foxes (*Vulpes vulpes* Linnaeus 1758) in North Hesse and East Westphalia. 1. Cestodes. *Deutsche Tierärztliche Wochenschrift* 99, 362–365.
- Barabási SS, Fok E, Gubányi A, Mészáros F and Cozma V (2010) Helminth fauna of the small intestine in the European red fox, *Vulpes vulpes* with notes on the morphological identification of *Echinococcus multilocularis*. *Scientific Parasitology* 11, 141–151.
- Beardell PL and Howell MJ (1984) Killing of *Taenia hydatigena* oncospheres by sheep neutrophils. *Zeitschrift für Parasitenkunde* 70, 337–344.
- Beiomvand M, Rafiei A, Razmjou E and Maraghi A (2018) Multiple zoonotic helminth infections in domestic dogs in a rural area of Khuzestan Province in Iran. *BMC Veterinary Research* 14, 224.
- Bejiga T, Haile A, Solomon T and Pal DSM (2016) Prevalence of *Cysticercus tenuicollis* in small ruminants slaughtered at Addis Ababa abattoir, Ethiopia. *World's Veterinary Journal* 6, 137–142.
- Bekele T, Mukasa-Mugerwa E and Kasali OB (1988) The prevalence of cysticercosis and hydatidosis in Ethiopian sheep. *Veterinary Parasitology* 28, 267–270.
- Belem AMG, Kaboré A and Bessin R (2005) Gastrointestinal helminthes of sheep in the central, eastern and northern parts of Burkina Faso. *Bulletin of Animal Health and Production in Africa* 53, 13–23.
- Benito A, Carmena D, Postigo I, Estibalez JJ, Martinez J and Guisantes JA (2003) Intestinal helminths in dogs in Alava, North of Spain. *Research and Reviews in Parasitology* 63, 121–126.
- Bentounsi B, Meradi S, Ayachi A and Cabaret J (2009) Cestodes of untreated large stray dog populations in Algeria: a reservoir for herbivore and human parasitic diseases. *Open Veterinary Science Journal* 3, 64–67.
- Bindke JD, Springer A, Janeczek-Erfurth E, Böer M and Strube C (2019) Helminth infections of wild European gray wolves (*Canis lupus Linnaeus*, 1758) in Lower Saxony, Germany, and comparison to captive wolves. *Parasitology Research* 118, 701–706.
- Blazek K, Schramlova J and Hulinska D (1985) Pathology of the migration phase of *Taenia hydatigena* (Pallas, 1766) larvae. *Folia Parasitologica* 32, 127–137.
- Bolukbas CS, Gurler AT, Beyhan YE, Acici M and Umur S (2012) Helminths of roe deer (*Capreolus capreolus*) in the Middle Black Sea Region of Turkey. *Parasitology International* 61, 729–730.
- Boomker J, Keep ME and Horak IG (1987) Parasites of South African wildlife. I. Helminths of bushbuck, *Tragelaphus scriptus*, and grey duiker, *Sylvicapra grimmia*, from the Weza State Forest, Natal. *Onderstepoort Journal of Veterinary Research* 54, 131–134.
- Boomker JDF, Booyse DG and Keep ME (1991) Parasites of South African wildlife. VI. Helminths of blue duikers, *Cephalophus monticola*, in Natal. *Onderstepoort Journal of Veterinary Research* 58, 11–13.
- Boomker J, Horak IG and Ramsay KA (1994) Helminth and arthropod parasites of indigenous goats in the northern Transvaal. *The Onderstepoort Journal of Veterinary Research* 61, 13–20.
- Borai M, Nagi A, Gab-Allah M, el-Mashad A and Moustafa S (2013) Comparative pathological studies on parasitic affections of liver in farm animals. *Benha Veterinary Medical Journal* 25, 284–295.
- Borji H, Razmi G, Ahmadi A, Karami H, Yaghfoori S and Abedi V (2011) A survey on endoparasites and ectoparasites of stray cats from Mashhad (Iran) and association with risk factors. *Journal of Parasitic Diseases* 35, 202–206.
- Boufana B, Scala A, Lahmar S, Pointing S, Craig PS, Dessi G, Zidda A, Pipia AP and Varcasia A (2015) A preliminary investigation into the genetic variation and population structure of *Taenia hydatigena* from Sardinia, Italy. *Veterinary Parasitology* 214, 67–74.
- Boufana B, Saïd Y, Dhibi M, Craig PS and Lahmar S (2017) *Echinococcus granulosus* sensu stricto (s.s.) from the critically endangered antelope *Addax nasomaculatus* in Tunisia. *Acta Tropica* 165, 17–20.
- Braae UC, Kabululu M, Nørmark ME, Nejsum P, Ngowi HA and Johansen MV (2015) *Taenia hydatigena* cysticercosis in slaughtered pigs, goats, and sheep in Tanzania. *Tropical Animal Health and Production* 47, 1523–1530.
- Broadert DW (1972) Ovine cysticercosis and canine taeniasis in Victoria. *Australian Veterinary Journal* 48, 452–455.
- Buttar BS, Nelson ML, Busboom JR, Hancock DD, Walsh DB and Jasmer DP (2013a) Effect of heat treatment on viability of *Taenia hydatigena* eggs. *Experimental Parasitology* 133, 421–426.
- Buttar BS, Nelson ML, Busboom JR, Hancock DD, Walsh DB and Jasmer DP (2013b) Effect of ensilation of potato on viability of *Taenia hydatigena* eggs. *Experimental Parasitology* 133, 483–486.
- Cabrera P, Haran G, Benavidez U, Valledor S, Perra G, Liyod S, Gemmell MA, Baraibar M, Morana A, Maissonave J and Carballo M (1995) Transmission dynamics of *Echinococcus granulosus*, *Taenia hydatigena* and *Taenia ovis* in sheep. *International Journal for Parasitology* 25, 807–813.
- Cabrera PA, Parietti S, Haran G, Benavidez U, Lloyd S, Perera P, Valledor S, Gemmell MA and Botto T (1996) Rates of reinfection with *Echinococcus granulosus*, *Taenia hydatigena*, *Taenia ovis* and other cestodes in a rural dog population in Uruguay. *International Journal for Parasitology* 26, 79–83.
- Cabrera M, Canova S, Rosenzvit M and Guarnera E (2002) Identification of *Echinococcus granulosus* eggs. *Diagnostic Microbiology and Infectious Disease* 44, 29–34.
- Cabrera PA, Irabedra P, Orlando D, Rista L, Harán G, Viñals G, Blanco MT, Alvarez M, Elola S, Morosoli D, Moraña A, Bondad M, Sambrán Y, Heinzen T, Chans L, Piñeyro L, Pérez D and Pereyra I (2003) National prevalence of larval echinococcosis in sheep in slaughtering plants *Ovis aries* as an indicator in control programmes in Uruguay. *Acta Tropica* 85, 281–285.
- Cancrini G and Iori A (2004) Traditional and innovative diagnostic tools: when and why they should be applied. *Parassitologia* 46, 173–176.
- Cassini R, Simonato G, Mulatti P, Ravagnan S, Danesi P, Pascotto E, Breda T, Bricchese M, Pietrobelli M and Capelli G (2019) A new approach to outbreak management for bovine cystic echinococcosis cases in hypo-endemic areas. *Veterinary Parasitology Regional Studies and Reports* 16, 100269.
- Cengiz G, Tenekeci GY and Bilgen N (2019) Molecular and morphological characterization of *Cysticercus tenuicollis* in red deer (*Cervus elaphus*) from Turkey. *Acta Parasitologica* 64, 652–657.
- Chaisiri K, Kusolsuk T, Homsuwan N, Sanguankiat S, Dekumyoy P, Peunpipoom G, Khiriphattharaphon S, Sako Y, Yanagida T, Okamoto M and Ito A (2019) Co-occurrence of swine cysticercosis due to *Taenia solium* and *Taenia hydatigena* in ethnic minority villages at the Thai–Myanmar border. *Journal of Helminthology* 93, 681–689.
- Chanee G and White JB (1976) Ovine cysticercosis in the Albany region of Western Australia. 1. Survey of tapeworms of rural dogs. *Australian Veterinary Journal* 52, 69–72.
- Chapman NG and Chapman DI (1987) Cysticercosis in fallow deer in England. *Acta Theriologica* 32, 105–113.
- Chege S, Toosy A, Sakr A, Shawki A, O'Sullivan S, de Vargas AP, Cavero T and Islam A (2016) Incidental findings of *Cysticercus tenuicollis* metacestodes in five oryx species. *Asian Pacific Journal of Tropical Biomedicine* 6, 90–92.
- Christodoulouopoulos G, Theodoropoulos G and Petrakos G (2008) Epidemiological survey of cestode-larva disease in Greek sheep flocks. *Veterinary Parasitology* 153, 368–373.
- Čirović D, Pavlović I and Penezić A (2015) Intestinal helminth parasites of the grey wolf (*Canis lupus L.*) in Serbia. *Acta Veterinaria Hungarica* 63, 189–198.

- Corda A, Dessi G, Varcasia A, Carta S, Tamponi C, Sedda G, Scala M, Marchi B, Salis F, Scala A and Pinna Pargaglia ML** (2020) Acute visceral cysticercosis caused by *Taenia hydatigena* in lambs: ultrasonographic findings. *Parasites and Vectors* **13**, 568, <http://doi.org/10.1186/s13071-020-04439-x>.
- Craig PS and Rickard MD** (1980) Evaluation of crude antigen prepared from *Taenia saginata* for the serological diagnosis of *T. saginata* cysticercosis in cattle using the enzyme-linked immunosorbent assay (ELISA). *Zeitschrift für Parasitenkunde* **61**, 287–297.
- Craig PS and Rickard MD** (1981) Anti-oncospherical antibodies in the serum of lambs experimentally infected with either *Taenia ovis* or *Taenia hydatigena*. *Zeitschrift für Parasitenkunde* **64**, 169–177.
- Dada BJ and Belino ED** (1978) Prevalence of hydatidosis and cysticercosis in slaughtered livestock in Nigeria. *Veterinary Records* **103**, 311–312.
- Dada BJ, Adegboye DS and Mohammed AN** (1979) A survey of gastro-intestinal helminth parasites of stray dogs in Zaria, Nigeria. *Veterinary Records* **104**, 145–146.
- Dai RS, Liu GH, Song HQ, Lin RQ, Yuan ZG, Li MW, Huang SY, Liu W and Zhu XQ** (2012) Sequence variability in two mitochondrial DNA regions and internal transcribed spacer among three cestodes infecting animals and humans from China. *Journal of Helminthology* **86**, 245–251.
- Dajani YF and Khalaf FH** (1981) Hydatidosis and tenuicollosis in sheep and goats of Jordan: a comparative study. *Annals of Tropical Medicine and Parasitology* **75**, 175–179.
- Dalimi A, Sattari A and Motamedi GH** (2006) A study on intestinal helminthes of dogs, foxes and jackals in the western part of Iran. *Veterinary Parasitology* **142**, 129–133.
- Darzi MM, Pandit BA, Shahardar RA and Mir MS** (2002) Pathology of *Taenia hydatigena* cysticercosis in a naturally infected Corriedale lamb. *Veterinary Parasitology* **16**, 173–174.
- Değer S and Biçek K** (2005) Tatvan belediye mezbahasında kesilen koyun, keçi ve sığırlarda larval cestodiosis. *Yüzüncü Yıl Üniversitesi Veteriner Fakültesi Dergisi* **16**, 45–47.
- Deplazes P, Gottstein B, Stingelin Y and Eckert J** (1990) Detection of *Taenia hydatigena* copro-antigens by ELISA in dogs. *Veterinary Parasitology* **36**, 91–103.
- Deplazes P, Guscetti F, Wunderlin E, Bucklar H, Skaggs J and Wolff K** (1995) Endoparasite infection in stray and abandoned dogs in southern Switzerland. *Schweizer Archiv für Tierheilkunde* **137**, 172–179.
- Dies KH** (1979) Helminths recovered from black bears in the Peace River region of northwestern Alberta. *Journal of Wildlife Diseases* **15**, 49–50.
- Duthy BL and van Someren VD** (1948) The survival of *Taenia saginata* eggs on open pasture. *East African Agricultural Journal* **13**, 147–148.
- Dyab AK, Marghany ME and Osman RA** (2017) Cysticercosis in small ruminants slaughtered in the Aswan slaughterhouse, Egypt. *Assiut Veterinary Medical Journal* **63**, 73–80.
- Dybing NA, Fleming PA and Adams PJ** (2013) Environmental conditions predict helminth prevalence in red foxes in Western Australia. *International Journal for Parasitology: Parasites and Wildlife* **2**, 165–172.
- Edwards GT and Herbert IV** (1980) The course of *Taenia hydatigena* infections in growing pigs and lambs: clinical signs and post-mortem examination. *British Veterinary Journal* **136**, 256–264.
- Edwards GT and Herbert IV** (1981) Some quantitative characters used in the identification of *Taenia hydatigena*, *T. ovis*, *T. pisiformis* and *T. multiceps* adult worms, and *T. multiceps* metacestodes. *Journal of Helminthology* **55**, 1–8.
- Edwards GT, Hackett F and Herbert IV** (1979a) *Taenia hydatigena* and *Taenia multiceps* infections in Snowdonia, UK II. The role of hunting dogs and foxes as definitive hosts, and of sheep as intermediate hosts. *British Veterinary Journal* **135**, 433–439.
- Edwards GT, Hackett F and Herbert IV** (1979b) *Taenia hydatigena* and *Taenia multiceps* infections in Snowdonia, UK I. Farm dogs as definitive hosts. *British Veterinary Journal* **135**, 426–432.
- Eguia-Aguilar P, Cruz-Reyes A and Martínez-Maya JJ** (2005) Ecological analysis and description of the intestinal helminths present in dogs in Mexico City. *Veterinary Parasitology* **127**, 139–146.
- El-Alfy EN, Al-Kappany YM and Abu-Elwafa SA** (2017) Parasitological and pathological studies on tissue parasites among slaughtered animals in Dakahlia province, Egypt. *Journal of Egyptian Veterinary Medical Society of Parasitology* **13**, 78–98.
- El-Azazy OM and Fayek SA** (1990) Seasonal pattern of *Fasciola gigantica* and *Cysticercus tenuicollis* infections in sheep and goats in Egypt. *Bulletin of Animal Health and Production in Africa* **38**, 369–373.
- El-Massry AAN** (1985) *Morphobiological Studies on the Larval Stages of Some Cestodes* (MS thesis). Cairo University, Cairo, Egypt.
- El-Massry AA** (1999) An enzyme linked immunosorbent assay for serodiagnosis of *Taenia hydatigena* metacestode infection in sheep. *Journal of Egyptian Society of Parasitology* **29**, 409–415.
- El-Metenawy TM** (1999) An abattoir survey of metacestodes among the slaughtered ruminants at Al-Qassim Area, Saudi Arabia. *Veterinary Medical Journal Giza* **47**, 199–204.
- El-Shehabi FS, Abdel-Hafez SK and Kamhawi SA** (1999) Prevalence of intestinal helminths of dogs and foxes from Jordan. *Parasitology Research* **85**, 928–934.
- El Badawi EK, El Gezuli AY, Eisa AM and Slepnev NK** (1978) Incidence of *Cysticercus tenuicollis* in animals slaughtered for human consumption in the Sudan. *Sudan Journal of Veterinary Science and Animal Husbandry* **19**, 78–91.
- Elshahawy I, Metwally A and Ibrahim D** (2014) An abattoir-based study on helminthes of slaughtered goats (*Capra hircus L.*, 1758) in upper Egypt, Egypt. *Helminthologia* **51**, 67–72.
- Emamapour SR, Borji H and Nagibi A** (2015) An epidemiological survey on intestinal helminths of stray dogs in Mashhad, North-east of Iran. *Journal of Parasitic Diseases* **39**, 266–271.
- Eslahi AV, Kia EB, Mobei I, Sharifdini M, Badri M and Mowlavi G** (2017) Road killed carnivores illustrate the status of zoonotic helminthes in Caspian Sea littoral of Iran. *Iranian Journal of Parasitology* **12**, 230–235.
- Eslami A, Ranjbar-Bahadori SH, Meshgi B, Dehghan M and Bokaie S** (2010) Helminth infections of stray dogs from Garmsar, Semnan province, Central Iran. *Iranian Journal of Parasitology* **5**, 37–41.
- Essa IM and Al-Azizz SA** (2011) Studies on *Cysticercus tenuicollis* collected from slaughtered sheep and goats in Basrah abattoir, Iraq. *Egyptian Journal of Experimental Biology (Zoology)* **7**, 343–347.
- Fahmi SA** (2014) *Studies on Larval Cestodes Infecting Sheep and Cattle* (MS thesis). Cairo University, Cairo, Egypt.
- Fakae BB** (1990) The epidemiology of helminthosis in small ruminants under the traditional husbandry system in eastern Nigeria. *Veterinary Research Communications* **14**, 381–391.
- Faraj AA and Al-Amery AM** (2018) Molecular identification of *Taenia hydatigena* isolated from domestic dogs in Baghdad city. *International Journal of Biosciences* **13**, 71–77.
- Federer K, Armua-Fernandez MT, Gori F, Hoby S, Wenker C and Deplazes P** (2016) Detection of taeniid (*Taenia* spp., *Echinococcus* spp.) eggs contaminating vegetables and fruits sold in European markets and the risk for metacestode infections in captive primates. *International Journal for Parasitology: Parasites and Wildlife* **5**, 249–253.
- Filip KJ, Pyziel AM, Jeżewski W, Myczka AW, Demiaszkiewicz AW and Laskowski Z** (2019) First molecular identification of *Taenia hydatigena* in wild ungulates in Poland. *EcoHealth* **16**, 161–170.
- Fiocchi A, Gustinelli A, Gelmini L, Rugna G, Renzi M, Fontana MC and Poglajen G** (2016) Helminth parasites of the red fox *Vulpes vulpes* (L., 1758) and the wolf *Canis lupus italicus* Altobello, 1921 in Emilia-Romagna, Italy. *Italian Journal of Zoology* **83**, 503–513.
- Folaranmi DO, Usman S, Gimba D and Okwori J** (1984) Taeniid infection of dogs in Zaria Nigeria. *International Journal of Zoonoses* **11**, 145–148.
- Food and Agriculture Organization** (2015) *Africa sustainable livestock 2050 report, Country brief Egypt* www.fao.org/3/a-i7312e/pdf.
- Forrester DJ and Rausch RL** (1990) Cysticerci (Cestoda: Taeniidae) from white-tailed deer, *Odocoileus virginianus*, in southern Florida. *Journal of Parasitology* **76**, 583–585.
- Ganaie ZA, Samanta S, Batoo AS, Nisha M, Rialch A and Rather W** (2018) Infection rate and biochemical profile of *Cysticercus tenuicollis* in goats in and around Bareilly Region, India. *International Journal of Current Microbiology and Applied Sciences* **7**, 89–94.
- Gasser RB and Chilton NB** (1995) Characterisation of taeniid cestode species by PCR-RFLP of ITS2 ribosomal DNA. *Acta Tropica* **59**, 31–40.
- Gasser RB, Zhu X and McManus DP** (1999) NADH dehydrogenase subunit I and cytochrome c oxidase subunit I sequences compared for members of the genus *Taenia* (Cestoda). *International Journal for Parasitology* **29**, 1965–1970.
- Gaur SNS, Sethi MS, Tewari HC and Prakash O** (1980) Note on the incidence of *Cysticercus tenuicollis* in sheep and goats in certain parts of Uttar Pradesh. *Indian Journal of Animal Research* **14**, 73–75.
- Gemmell MA** (1964) Immunological responses of the mammalian host against tapeworm infections: I. Species specificity of hexacanth embryos in protecting sheep against *Taenia hydatigena*. *Immunology* **7**, 489–499.

- Gemmell MA and Lawson JR (1985) The survival in sheep and infectivity to dogs of *Taenia hydatigena* and *T. ovis* in sheep. *Veterinary Parasitology* **17**, 215–218.
- Gemmell MA and Macnamara FN (1976) Factors regulating tapeworm populations: estimations of the infection pressure and index of clustering from *Taenia hydatigena* before and after the removal of infected dogs. *Research in Veterinary Science* **21**, 215–219.
- Gemmell MA, Lawson JR, Roberts MG and Griffin JFT (1990) Population dynamics in echinococcosis and cysticercosis: regulation of *Taenia hydatigena* and *T. ovis* in lambs through passively transferred immunity. *Parasitology* **101**, 145–151.
- Gessese AT, Mulate B, Nazir S and Asmare A (2015) Major metacestodes in small ruminants slaughtered at Dessie municipal abattoir, Eastern Ethiopia: prevalence, cyst viability, organ distribution and economic implications. *Comparative Clinical Pathology* **24**, 659–668.
- Ghaffar NM (2011) Tenuicollosis in slaughtered sheep at Duhok abattoir-Kurdistan region of Iraq. *Basrah Journal of Veterinary Research* **10**, 1–24.
- Gholami I, Daryani A, Sharif M, Amouei A and Mobedi I (2011) Seroepidemiological survey of helminthic parasites of stray dogs in Sari City, northern Iran. *Pakistan Journal of Biological Sciences* **14**, 133–137.
- Gomez-Puerta LA, Pacheco J, Gonzales-Viera O, Lopez-Urbina MT, Gonzalez AE and Cysticercosis Working Group in Peru (2015) The taruca (*Hippocamelus antisensis*) and the red brocket deer (*Mazama americana*) as intermediate hosts of *Taenia hydatigena* in Peru, morphological and molecular evidence. *Veterinary Parasitology* **212**, 465–468.
- Gori F, Armua-Fernandez MT, Milanese P, Serafini M, Magi M, Deplazes P and Macchioni F (2015) The occurrence of taeniids of wolves in Liguria (northern Italy). *International Journal for Parasitology: Parasites and Wildlife* **4**, 252–255.
- Guberti V, Stancampiano L and Francisci F (1993) Intestinal helminth parasite community in wolves (*Canis lupus*) in Italy. *Parassitologia* **35**, 59–65.
- Guerra D, Armua-Fernandez MT, Silva M, Bravo I, Santos N, Deplazes P and de Carvalho LMM (2013) Taeniid species of the Iberian wolf (*Canis lupus signatus*) in Portugal with special focus on *Echinococcus* spp. *International Journal for Parasitology: Parasites and Wildlife* **2**, 50–53.
- Hackett F and Walters TMH (1980) Helminths of the red fox in mid-Wales. *Veterinary Parasitology* **7**, 181–184.
- Haddawee RH, Sulbi IM and Abass ZF (2018) Prevalence of *Cysticercus tenuicollis* in slaughtered sheep and goats by season, sex, age, at Karbala abattoir, Iraq. *Scientific Journal of Medical Research* **2**, 52–56.
- Hama AA, Zorab RH, Ali FM, Salih AM and Hassan AA (2018) Prevalence and molecular characterization of *Cysticercus tenuicollis* isolated from some intermediate host in Kurdistan-Iraq. *Kurdistan Journal of Applied Research* **3**, 177–182.
- Hamid ME, Mohamed GE, Samra MA and Hamad AA (1991) First report of infectious necrotic hepatitis (black disease) among Nubian goats in Sudan. *Revue d'élevage et de médecine vétérinaire des pays tropicaux* **44**, 273–275.
- Harris RE, Revfeim KJA and Heath DD (1980) Simulating strategies for control of *Echinococcus granulosus*, *Taenia hydatigena* and *T. ovis*. *Epidemiology and Infection* **84**, 389–404.
- Hasslinger MA and Weber-Werrighen R (1988) Fecal surveys in pastured sheep and the occurrence of *Cysticercus tenuicollis* in slaughtered sheep. *Angewandte Parasitologie* **29**, 227–234.
- Heath DD, Parmeter SN and Osborn PJ (1980) An attempt to immunise dogs against *Taenia hydatigena*. *Research in Veterinary Science* **29**, 388–389.
- Hobbs TR, Colgin L, Maginnis GM and Lewis AD (2003) Abdominal cysticercosis in a rhesus macaque (*Macaca mulatta*). *Comparative Medicine* **53**, 545–547.
- Hoberg EP, Jones A, Rausch RL, Eom KS and Gardner SL (2000) A phylogenetic hypothesis for species of the genus *Taenia* (Eucestoda: Taeniidae). *Journal of Parasitology* **86**, 89–98.
- Islam AS and Chizyuka HGB (1983) Prevalence of helminth parasites of dogs in Lusaka, Zambia. *Tropical Animal Health and Production* **15**, 234–236.
- Islam FMS, Rahman MH and Chowdhury SMZH (1992) Prevalence of parasites of water buffaloes in Bangladesh. *Asian-Australian Journal of Animal Sciences* **5**, 601–604.
- Islam MK, Mondal MMH and Das PM (1995) Metacestodes infection in black Bengal goats in Bangladesh. *Asian-Australasian Journal of Animal Sciences* **8**, 13–16.
- Jacobs HJ, Moriarty KM, Charleston WAG and Heath DD (1994) Resistance against *Taenia hydatigena* in sheep after passive transfer of serum or colostrum. *Parasite Immunology* **16**, 351–359.
- Jenkins DJ and Rickard MD (1985) Specific antibody responses to *Taenia hydatigena*, *Taenia pisiformis* and *Echinococcus granulosus* infection in dogs. *Australian Veterinary Journal* **62**, 72–78.
- Jenkins DJ, Gasser RB, Romig T and Zeyhle E (1991) Antibody responses against natural *Taenia hydatigena* infection in dogs in Kenya. *International Journal for Parasitology* **21**, 251–253.
- Jenkins DJ, Lievaart JJ, Boufana B, Lett WS, Bradshaw H and Armua-Fernandez MT (2014a) *Echinococcus granulosus* and other intestinal helminths: current status of prevalence and management in rural dogs of eastern Australia. *Australian Veterinary Journal* **92**, 292–298.
- Jenkins DJ, Urwin NA, Williams TM, Mitchell KL, Lievaart JJ and Armua-Fernandez MT (2014b) Red foxes (*Vulpes vulpes*) and wild dogs (dingoes (*Canis lupus dingo*) and dingo/domestic dog hybrids), as sylvatic hosts for Australian *Taenia hydatigena* and *Taenia ovis*. *International Journal for Parasitology: Parasites and Wildlife* **3**, 75–80.
- Jenkins DJ, Cowled B and Brookes V (2018) Taeniid metacestodes in rangeland goats in Australia. *Veterinary Parasitology* **255**, 1–9.
- Jones A and Walters TMH (1992a) A survey of taeniid cestodes in farm dogs in mid-Wales. *Annals of Tropical Medicine and Parasitology* **86**, 137–142.
- Jones A and Walters TMH (1992b) The cestodes of foxhounds and foxes in Powys, mid-Wales. *Annals of Tropical Medicine and Parasitology* **86**, 143–150.
- Kara M, Gicik Y, Sari B, Bulut H and Arslan MO (2009) A slaughterhouse study on prevalence of some helminths of cattle and sheep in Malatya Province, Turkey. *Journal of Animal and Veterinary Advances* **8**, 2200–2205.
- Karamon J, Sroka J, Dąbrowska J, Bilska-Zajac E, Zdybel J, Kochanowski M, Różycki M and Cencek T (2019) First report of *Echinococcus multilocularis* in cats in Poland: a monitoring study in cats and dogs from a rural area and animal shelter in a highly endemic region. *Parasites and Vectors* **12**, 313.
- Kedra AH, Tkach VV, Swiderski Z and Pawłowski Z (2001) Intraspecific variability among NADH dehydrogenase subunit 1 sequences of *Taenia hydatigena*. *Parasitology International* **50**, 145–148.
- Khaled K, Teber G, Bouaicha F, Amairia S, Rekić M and Gharbi M (2019) Infestation of small ruminants by the metacestode stage of *Taenia hydatigena* in slaughterhouse, North East Tunisia. *Veterinary Medicine and Science* **6**, 204–208.
- Khanjari A, Cheraghi N, Bokaie S, Fallah S, Basti AA, Fallah M and Mohammadkhan F (2015) Prevalence of *Cysticercus tenuicollis* in slaughtered sheep and goats by season, sex, age, and infected organ at Amol abattoir, Mazandaran province, Iran. *Comparative Clinical Pathology* **24**, 149–152.
- Kilinc SG, Kesik HK and Simsek S (2019) Molecular characterization and haplotypes of sheep and goat isolates of *Cysticercus tenuicollis* in Turkey. *Parasitology* **146**, 1–8.
- Kimura A, Morishima Y, Nagahama S, Horikoshi T, Edagawa A, Kawabuchi-Kurata T, Sugiyama H and Yamasaki HA (2013) Coprological survey of intestinal helminthes in stray dogs captured in Osaka prefecture, Japan. *Journal of Veterinary Medical Science* **75**, 1409–1411.
- Kistner TP, Matlock SM, Wyse D and Masons GE (1977) Helminth parasites of bighorn sheep in Oregon. *Journal of Wildlife Diseases* **13**, 125–130.
- Koutsoumpas A, Psychas V, Papadopoulos E, Panousis N, Karatzias H and Giadinis ND (2013) Acute visceral cysticercosis in feed-lot lambs. *Revue de Médecine Vétérinaire* **164**, 425–428.
- Lahmar S, Sarciron ME, Rouiss M, Hammouda A, Youssfi M and Mensi M (2008) *Echinococcus granulosus* and other intestinal helminths in semi-stray dogs in Tunisia: infection and re-infection rates. *La Tunisie Médicale* **86**, 279–286.
- Lahmar S, Arfa I, Othmen SB, Jguirim W, Saïd Y, Dhibi A and Boufana B (2017) Intestinal helminths of stray dogs from Tunisia with special reference to zoonotic infections. *Parasitology Open* **3**, e18. <https://doi.org/10.1017/pao.2017.21>.
- Lavikainen A, Laaksonen S, Beckmen K, Oksanen A, Isomursu M and Meri S (2011) Molecular identification of *Taenia* spp. in wolves (*Canis lupus*), brown bears (*Ursus arctos*) and cervids from North Europe and Alaska. *Parasitology International* **60**, 289–295.
- Lawson JR and Gemmell MA (1985) The potential role of blowflies in the transmission of taeniid tapeworm eggs. *Parasitology* **91**, 129–143.
- Livesey CT, Herbert IV, Willis JM and Evans WT (1981) Acute cysticercosis in housed sheep. *Veterinary Records* **109**, 217.
- Loos-Frank B (2000) An up-date of Verster's (1969) 'Taxonomic revision of the genus *Taenia* Linnaeus' (Cestoda) in table format. *Systematic Parasitology* **45**, 155–183.

- Loos-Frank B and Zeyhle E (1982) The intestinal helminths of the red fox and some other carnivores in southwest Germany. *Zeitschrift für Parasitenkunde* **67**, 99–113.
- Luo H, Zhang H, Li K, Rehman MU, Mehmood K, Lan Y, Huang S and Li J (2017) Epidemiological survey and phylogenetic characterization of *Cysticercus tenuicollis* isolated from Tibetan pigs in Tibet, China. *BioMed Research International* **2017**, 7857253. doi: 10.1155/2017/7857253.
- Ma J, He SW, Li H, Guo QC, Pan WW, Wang XJ, Zhang J, Liu LZ, Liu W and Liu Y (2014) First survey of helminths in adult goats in Hunan Province, China. *Tropical Biomedicine* **31**, 261–269.
- Manfredi MT, Ghirardelli R and Zanzani S (2006) *Cysticercus tenuicollis* infection in a goat farm. *Parassitologia* **48**, 433–436.
- Martínez-Moreno FJ, Hernández S, López-Cobos E, Becerra C, Acosta I and Martínez-Moreno A (2007) Estimation of canine intestinal parasites in Cordoba (Spain) and their risk to public health. *Veterinary Parasitology* **143**, 7–13.
- Martínez C, Andrés J, Hernández-Ortiz BA and Martelo Torres A (2016) Report of cysticercosis in sheep of Ballesta, Bolivar, Colombia. *CES Medicina Veterinaria y Zootecnia* **11**, 35–47.
- Mekuria E, Shimelis S, Bekele J and Sheferaw D (2013) Sheep and goats *Cysticercus tenuicollis* prevalence and associated risk factors. *African Journal of Agricultural Research* **8**, 3121–3125.
- Meshgi B, Eslami A, Bahonar AR, Kharrazian-Moghadam M and Gerami-Sadeghian A (2009) Prevalence of parasitic infections in the red fox (*Vulpes vulpes*) and golden jackal (*Canis aureus*) in Iran. *Iranian Journal of Veterinary Research* **10**, 387–391.
- Miran MB, Kasuku AA and Swai ES (2017) Prevalence of echinococcosis and *Taenia hydatigena* cysticercosis in slaughtered small ruminants at the livestock-wildlife interface areas of Ngorongoro, Tanzania. *Veterinary World* **10**, 411–417.
- Mirbadie SR, Nasab AN, Mohaghegh MA, Norouzi P, Mirzaei M and Spotin A (2019) Molecular phylodiagnosis of *Echinococcus granulosus* sensu lato and *Taenia hydatigena* determined by mitochondrial Cox1 and SSU-rDNA markers in Iranian dogs: indicating the first record of pig strain (G7) in definitive host in the Middle East. *Comparative Immunology, Microbiology and Infectious Diseases* **65**, 88–95.
- Mirzaei M and Rezaei H (2015) Role of goats and sheep in the epidemiology of *Cysticercus tenuicollis* in Tabriz, Northwest Iran. *Comparative Clinical Pathology* **24**, 441–444.
- Mokhtaria K, Fadela S, Ammar SSM, Belcacec BT, Ammar AA, Ameer AS and Abdelkader B (2018) *Cysticercus tenuicollis* in small ruminants of Algeria: abattoir survey, biochemical and morphological characterizations. *Bulgarian Journal of Agricultural Science* **24**, 698–703.
- Moks E, Jõgisalu I, Saarma U, Talvik H, Jarvis T and Valdmann H (2006) Helminthologic survey of the wolf (*Canis lupus*) in Estonia, with an emphasis on *Echinococcus granulosus*. *Journal of Wildlife Diseases* **42**, 359–365.
- Morais DFD, Vilela VLR, Feitosa TF, Santos VMD, Gouveia VR, Athayde ACR and Azevêdo SSD (2017) Prevalence and risk factors for *Cysticercus tenuicollis* in goats and sheep in Paraíba, northeastern Brazil. *Revista Brasileira de Parasitologia Veterinária* **26**, 235–238.
- Moro PL, Ballarta J, Gilman RH, Leguia G, Rojas M and Montes G (1998) Intestinal parasites of the grey fox (*Pseudalopex culpaeus*) in the central Peruvian Andes. *Journal of Helminthology* **72**, 87–89.
- Muku RJ, Yan HB, Ohiolei JA, Saaid AA, Ahmed S, Jia WZ and Fu BQ (2020) Molecular identification of *Taenia hydatigena* from sheep in Khartoum, Sudan. *The Korean Journal of Parasitology* **58**, 93–97.
- Nabavi R, Naeini KM, Zebardast N and Hashemi H (2014) Epidemiological study of gastrointestinal helminths of canids in Chaharmahal and Bakhtiari province of Iran. *Iranian Journal of Parasitology* **9**, 276–281.
- Nath S, Pal S, Mandal S and Parveen K (2010) Prevalence of caprine *Taenia hydatigena* cysticercosis (*Cysticercus tenuicollis*) in Durg, Chhattisgarh. *Indian Journal of Field Veterinarians* **5**, 64–66.
- Nguyen MT, Gabriël S, Abatih EN and Dorny P (2016) A systematic review on the global occurrence of *Taenia hydatigena* in pigs and cattle. *Veterinary Parasitology* **226**, 97–103.
- Nonaka N, Nakamura S, Inoue T, Oku Y, Katakura K, Matsumoto J, Mathis A, Chembesofu M and Phiri IGK (2011) Coprological survey of alimentary tract parasites in dogs from Zambia and evaluation of a coproantigen assay for canine echinococcosis. *Annals of Tropical Medicine and Parasitology* **105**, 521–531.
- Nourani H, Pirali Kheirabadi KH, Rajabi H and Banitalebi A (2010) An unusual migration of *Taenia hydatigena* larvae in a lamb. *Tropical Biomedicine* **27**, 651–656.
- Nwosu CO, Ogunrinade AF and Fagbemi BO (1996) Prevalence and seasonal changes in the gastro-intestinal helminths of Nigerian goats. *Journal of Helminthology* **70**, 329–333.
- Ogunbade SG and Ogunrinade AF (1984) Tapeworm infection (*Taenia hydatigena*) in lion (*Panthera leo*) in captivity. A case report. *Revue d'élevage et de médecine vétérinaire des pays tropicaux* **37**, 30–31.
- Oğuz B and Değer S (2013) Cystic echinococcosis and cysticerci of *Taenia hydatigena* in cattle and sheep slaughtered in a Van Local Slaughterhouse. *Türkiye Parazitoloji Dergisi* **37**, 186–189.
- Ohiolei JA, Luka J, Zhu GQ, Yan HB, Li L, Magaji AA, Alvi MA, Wu YT, Li JQ, Fu BQ and Jia WZ (2019) First molecular description, phylogeny and genetic variation of *Taenia hydatigena* from Nigerian sheep and goats based on three mitochondrial genes. *Parasites & Vectors* **12**, 520.
- Omar MA, Elmajdoub LO, Al-Aboody MS, Elsify AM, Elkhtam AO and Hussien AA (2016) Molecular characterization of *Cysticercus tenuicollis* of slaughtered livestock in Upper Egypt governorates. *Asian Pacific Journal of Tropical Biomedicine* **6**, 706–708.
- Onawunmi OA and Coles GC (1980) Attempts to immunise sheep with culture antigens of *Taenia hydatigena*. *Research in Veterinary Science* **29**, 122–123.
- Öncel T (2000) The prevalence of helminth species in sheep in the southern region of Marmara. *Türkiye Parazitoloji Dergisi* **24**, 414–419.
- Oryan A, Moghaddar N and Gaur SNS (1994) Metacestodes of sheep with special reference to their epidemiological status, pathogenesis and economic implications in Fars Province, Iran. *Veterinary Parasitology* **51**, 231–240.
- Oryan A, Goorgipour S, Moazeni M and Shirian S (2012) Abattoir prevalence, organ distribution, public health and economic importance of major metacestodes in sheep, goats and cattle in Fars, southern Iran. *Tropical Biomedicine* **29**, 349–359.
- Ouchene-Khelifi NA and Ouchene N (2017) Infestation and biochemical content of *Cysticercus tenuicollis* cysts (*Taenia hydatigena* cysts) in sheep and goats. *Journal of Entomology and Zoology Studies* **5**, 822–825.
- Pandey VS, Dakkak A and Elmamoune M (1987) Parasites of stray dogs in the Rabat region, Morocco. *Annals of Tropical Medicine and Parasitology* **81**, 53–55.
- Parmeter SN, Heath DD and Twaalfhoven H (1981) Effect of population density on growth and development of *Taenia hydatigena* in dogs. *Research in Veterinary Science* **30**, 257–259.
- Pathak KML and Gaur SNS (1982) The incidence of adult and larval stage *Taenia hydatigena* in Uttar Pradesh (India). *Veterinary Parasitology* **10**, 91–95.
- Payan-Carreira R, Silva F, Rodrigues M and Dos Anjos Pires M (2008) *Cysticercus tenuicollis* vesicle in fetal structures: report of a case. *Reproduction in Domestic Animals* **43**, 764–766.
- Perl S, Edery N, Bouznach A, Abdalla H and Markovics A (2015) Acute severe visceral cysticercosis in lambs and kids in Israel. *Israel Journal of Veterinary Medicine* **70**, 49–53.
- Poglayen G, Gori F, Morandi B, Galuppi R, Fabbri E, Caniglia R, Milanese P, Galaverni M, Randi E, Marchesi B and Deplazes P (2017) Italian wolves (*Canis lupus italicus* Altobello, 1921) and molecular detection of taeniids in the Foreste Casentinesi National Park, Northern Italian Apennines. *International Journal for Parasitology: Parasites and Wildlife* **6**, 1–7.
- Pumidonning W, Salman D, Gronsang D, AdelBaset AE, Sangkaeo K, Kawazu SI and Igarashi M (2016) Prevalence of gastrointestinal helminth parasites of zoonotic significance in dogs and cats in lower Northern Thailand. *Journal of Veterinary Medical Science* **78**, 1779–1784.
- Pybus MJ (1990) Survey of hepatic and pulmonary helminths of wild cervids in Alberta, Canada. *Journal of Wildlife Diseases* **26**, 453–459.
- Radfar MH, Jajalli M and Jalalzadeh M (2005) Prevalence and morphological characterization of cysticerci from sheep and goats in Iran. *Veterinarski arhiv* **75**, 469–470.
- Rao TB, Prasad VP and Hafeez MD (2003) Prevalence of *Cysticercus tenuicollis* infection in slaughtered sheep and goats at Kakinada, Andhra Pradesh. *Journal of Parasitic Diseases* **27**, 126–127.
- Razmjoo M, Bahrami AM and Shamsollahi M (2014) Seroepidemiological survey of important parasitic infections of wild carnivores. *International Journal of Advanced Biological Biomedical Research* **2**, 783–792.
- Rehbein S and Visser M (2007) Die Endoparasiten des Sikawildes (*Cervus nippon*) in Österreich. *Wiener Klinische Wochenschrift* **119**, 96–101.
- Rehbein S, Kollmannsberger M, Visser M and Winter R (1996) Helminth burden of slaughter sheep in Upper Bavaria. 1: Species spectrum, infestation extent and infestation intensity. *Berliner und Münchener Tierärztliche Wochenschrift* **109**, 161–167.

- Rehbein S, Visser M and Winter R (1998) Endoparasitic infections in sheep from the Swabian Alb. *Deutsche Tierärztliche Wochenschrift* **105**, 419–424.
- Rehbein S, Kaulfuss KH, Visser M, Sommer MF, Grimm F and Silaghi C (2016) Parasites of sheep herding dogs in central Germany. *Berliner und Münchener Tierärztliche Wochenschrift* **129**, 56–64.
- Rep BH (1975) Intestinal helminths in dogs and cats on the Antillian Islands Aruba, Curaçao and Bonaire. *Tropical and Geographical Medicine* **27**, 317–323.
- Richards DT, Harris S and Lewis JW (1995) Epidemiological studies on intestinal helminth parasites of rural and urban red foxes (*Vulpes vulpes*) in the United Kingdom. *Veterinary Parasitology* **59**, 39–51.
- Rostami S, Salavati R, Beech RN, Babaei Z, Sharbatkhori M, Baneshi MR, Hajjalilo E, Shad H and Harandi MF (2015) Molecular and morphological characterization of the tapeworm *Taenia hydatigena* (Pallas, 1766) in sheep from Iran. *Journal of Helminthology* **89**, 150–158.
- Ryan GE (1976) Helminth parasites of the fox (*Vulpes vulpes*) in New South Wales. *Australian Veterinary Journal* **52**, 126–131.
- Saari S, Näreaho A and Nikander S (2010) *Canine Parasites and Parasitic Diseases*, 1st Edn Massachusetts, United States: Academic Press.
- Sadighian A (1969) Helminth parasites of stray dogs and jackals in Shahsavari area, Caspian region, Iran. *Journal of Parasitology* **55**, 372–374.
- Saeed I, Maddox-Hyttel C, Monrad J and Kapel CM (2006) Helminths of red foxes (*Vulpes vulpes*) in Denmark. *Veterinary Parasitology* **139**, 168–179.
- Samuel W and Zewde GG (2010) Prevalence, risk factors, and distribution of *Cysticercus tenuicollis* in visceral organs of slaughtered sheep and goats in central Ethiopia. *Tropical Animal Health and Production* **42**, 1049–1051.
- Santana J, Martínez A, Soulés A, Milicevic M, Marcellino R, Larroza M and Robles C (2018) Cisticercosis visceral por *Cysticercus tenuicollis* en ovinos de faena en la Provincia de Santa Cruz, Argentina. *Revista Veterinaria Argentina* **XXXV**, 1–11.
- Saulawa MA, Magaji AA, Faleke OO, Mohammed AA, Kudi AC, Musawa AL, Sada A, Ugboma AN, Akawu B, Sidi S and Lawal N (2011) Prevalence of *Cysticercus tenuicollis* cysts in sheep slaughtered at Sokoto abattoir, Sokoto state, Nigeria. *Sokoto Journal of Veterinary Sciences* **9**, 24–27.
- Scala A and Marrosu R (1997) Cysticercosis in lambs. Studies on cysticercosis caused by *Cysticercus tenuicollis* in Sardinia. *Obiettivi e Documenti Veterinari* **18**, 67–73.
- Scala A, Pipia AP, Dore F, Sanna G, Tamponi C, Marrosu R, Bandino E, Carmona C, Boufana B and Varcasia A (2015) Epidemiological updates and economic losses due to *Taenia hydatigena* in sheep from Sardinia, Italy. *Parasitology Research* **114**, 3137–3143.
- Scala A, Urrai G, Varcasia A, Nicolussi P, Mulas M, Goddi L, Pipia AP, Sanna G, Genchi M and Bandino, E (2016) Acute visceral cysticercosis by *Taenia hydatigena* in lambs and treatment with praziquantel. *Journal of Helminthology* **90**, 113–116.
- Schantz PM, Alstine CV, Blacksheep A and Sinclair S (1977) Prevalence of *Echinococcus granulosus* and other cestodes in dogs on the Navajo reservation in Arizona and New Mexico. *American Journal of Veterinary Research* **38**, 669–670.
- Schuster RK, Thomas K, Sivakumar S and O'Donovan D (2009) The parasite fauna of stray domestic cats (*Felis catus*) in Dubai, United Arab Emirates. *Parasitology Research* **105**, 125–134.
- Schuster RK, Kinne J, Boufana B and Varcasia A (2015) A case of hepatic cysticercosis in a dromedary calf. *Journal of Camel Practice and Research* **22**, 1–5.
- Schuster RK, Dessi G and Varcasia A (2019) Another case of hepatic cysticercosis caused by *Cysticercus tenuicollis* in a dromedary. *Journal of Camel Practice and Research* **26**, 1–4.
- Segovia JM, Torres J, Miquel J, Llaneza L and Feliu C (2001) Helminths in the wolf, *Canis lupus*, from north-western Spain. *Journal of Helminthology* **75**, 183–192.
- Segovia JM, Guerrero R, Torres J, Miquel J and Feliu C (2003) Ecological analyses of the intestinal helminth communities of the wolf, *Canis lupus*, in Spain. *Folia Parasitologica* **50**, 231–236.
- Senlik B (2008) Influence of host breed, sex and age on the prevalence and intensity of *Cysticercus tenuicollis* in sheep. *Journal of Animal and Veterinary Advances* **7**, 548–551.
- Sgroi G, Varcasia A, Dessi G, D'Alessio N, Pacifico L, Buono F, Neola B, Fusco G, Santoro M, Toscano V, Fioretti A and Veneziano V (2019) Massive *Taenia hydatigena* cysticercosis in a wild boar (*Sus scrofa*) from Italy. *Acta Parasitologica* **64**, 938–941.
- Sgroi G, Varcasia A, D'Alessio N, Varuzza P, Buono F, Amoroso MG, Boufana B, Otranto D, Fioretti A and Veneziano V (2020) *Taenia hydatigena* cysticercosis in wild boar (*Sus scrofa*) from southern Italy: an epidemiological and molecular survey. *Parasitology* **147**, 1636–1642.
- Shamsaddini S, Mohammadi MA, Mirbadie SR, Nasibi S, Rostami S, Dehghani M and Harandi MF (2017) Evaluation of microsatellites markers to discriminate four main taeniid tapeworms of dogs. *Iranian Journal of Parasitology* **12**, 292–297.
- Shimalov VV and Shimalov VT (2003) Helminth fauna of cervids in Belorussian Polesie. *Parasitology Research* **89**, 75–76.
- Singh BB, Sharma R, Gill JPS and Sharma JK (2015) Prevalence and morphological characterisation of *Cysticercus tenuicollis* (*Taenia hydatigena* cysts) in sheep and goat from north India. *Journal of Parasitic Diseases* **39**, 80–84.
- Sissay MM, Uggla A and Waller PJ (2008) Prevalence and seasonal incidence of adult cestodes in Eastern Ethiopia. *Tropical Animal Health and Production* **40**, 587–594.
- Smith C, Parkinson TJ and Long SE (1999) Abattoir survey of acquired reproductive abnormalities in ewes. *Veterinary Records* **144**, 491–496.
- Solusby E (1982) *Helminths, Arthropods and Protozoa of Domesticated Animals*, 7th Edn. London: Bailliere Tindall.
- Stallbaumer M (1987) The prevalence and epidemiology of cestodes in dogs in Clwyd, Wales: II. Hunting dogs. *Annals of Tropical Medicine and Parasitology* **81**, 43–47.
- Sultan K, Desoukey AY, Elsiefy MA and Elbahy NM (2010) An abattoir study on the prevalence of some gastrointestinal helminths of sheep in Gharbia Governorate, Egypt. *Global Veterinaria* **5**, 84–87.
- Sweatman GK and Plummer PJG (1957) The biology and pathology of the tapeworm *Taenia hydatigena* in domestic and wild hosts. *Canadian Journal of Zoology* **35**, 93–109.
- Taher GA and Sayed GM (2011) Some studies on parasitic liver affections of sheep in Assiut governorate. *Assiut Veterinary Medical Journal* **57**, 343–359.
- Tajima F (1989) Statistical method for testing the neutral mutation hypothesis by DNA polymorphism. *Genetics* **123**, 585–595.
- Takács A, Szabó L, Juhász L, Takács A, Lanszki J, Takács P and Heltai M (2014) Data on the parasitological status of golden jackal (*Canis aureus* L., 1758) in Hungary. *Acta Veterinaria Hungarica* **62**, 33–41.
- Tamura K, Stecher G, Peterson D, Filipksi A and Kumar S (2013) MEGA6: molecular evolutionary genetics analysis version 6.0. *Molecular Biology and Evolution* **30**, 2725–2729.
- Tassi P and Widenhorn O (1977) Research on intestinal parasitic diseases in dogs of the city of Rome. *Parassitologia* **19**, 43–57.
- Thapa NK, Armua-Fernandez MT, Kinzang D, Gurung RB, Wangdi P and Deplazes P (2017) Detection of *Echinococcus granulosus* and *Echinococcus ortleppi* in Bhutan. *Parasitology International* **66**, 139–141.
- Thevenet PS, Alvarez HM and Basualdo JA (2017) Survival, physical and physiological changes of *Taenia hydatigena* eggs under different conditions of water stress. *Experimental Parasitology* **177**, 47–56.
- Traub RJ, Pednekar RP, Cuttler L, Porter RB, Rani PAAM and Gatne ML (2014) The prevalence and distribution of gastrointestinal parasites of stray and refuge dogs in four locations in India. *Veterinary Parasitology* **205**, 233–238.
- Trees AJ, Owen RR, Craig PS and Purvis GM (1985) *Taenia hydatigena*: a cause of persistent liver condemnations in lambs. *Veterinary Records* **116**, 512–516.
- Trifonov T, Meskov S and Stoimenov K (1970) Helminth fauna of the jackal (*Canis aureus*) in the Strandzha Mountains. *Veterinarno Meditsinski Nauki* **7**, 51–54.
- Tsubota K, Nakatsuji S, Matsumoto M, Fujihira S, Yoshizawa K, Okazaki Y, Murakami Y, Anagawa A, Oku Y and Oishi Y (2009) Abdominal cysticercosis in a cynomolgus monkey. *Veterinary Parasitology* **161**, 339–341.
- Ugochukwu EI and Ejimadu KN (1985) Studies on the prevalence of gastrointestinal helminths of dogs in Calabar, Nigeria. *International Journal of Zoonoses* **12**, 214–218.
- Ulziijargal G, Yeruult C, Khulan J, Gantsetseg C, Wandra T, Yamasaki H and Narankhajid M (2019) Molecular identification of *Taenia hydatigena* and *Mesocestoides* species based on copro-DNA analysis of wild carnivores in Mongolia. *International Journal for Parasitology: Parasites and Wildlife* **11**, 72–82.
- Utuk AE and Piskin FC (2012) Molecular detection and characterization of goat isolate of *Taenia hydatigena* in Turkey. *Scientific World Journal* **2012**, 962732. <http://dx.doi.org/10.1100/2012/962732>.
- Valdmann H, Moks E and Talvik H (2004) Helminth fauna of Eurasian lynx (*Lynx lynx*) in Estonia. *Journal of Wildlife Diseases* **40**, 356–360.

- Varcasia A, Tanda B, Giobbe M, Solinas C, Pipia AP, Malgor R, Carmona C, Garippa G and Scala A** (2011) Cystic echinococcosis in Sardinia: Farmers' knowledge and dog infection in sheep farms. *Veterinary Parasitology* **181**, 335–340.
- Vargas-Calla A, Gomez-Puerta LA, Pajuelo MJ, Garcia HH, Gonzalez AE and Cysticercosis Working Group in Peru** (2018) Molecular detection of taeniid eggs in beetles collected in an area endemic for *Taenia solium*. *American Journal of Tropical Medicine and Hygiene* **99**, 1198–1200.
- Verster AJ** (1979) Gastro-intestinal helminths of domestic dogs in the Republic of South Africa. *Onderstepoort Journal of Veterinary Research* **46**, 79–82.
- Waid DD, Pence DB and Warren RJ** (1985) Effects of season and physical condition on the gastrointestinal helminth community of white-tailed deer from the Texas Edwards Plateau. *Journal of Wildlife Diseases* **21**, 264–273.
- Wang CR, Qiu JH, Zhao JP, Xu LM, Yu WC and Zhu XQ** (2006) Prevalence of helminthes in adult dogs in Heilongjiang Province, the People's Republic of China. *Parasitology Research* **99**, 627–630.
- Wondimu A, Abera D and Hailu Y** (2011) A study on the prevalence, distribution and economic importance of *Cysticercus tenuicollis* in visceral organs of small ruminants slaughtered at an abattoir in Ethiopia. *Journal of Veterinary Medicine and Animal Health* **3**, 67–74.
- Xhaxhiu D, Kusi I, Rapti D, Kondi E, Postoli R, Rinaldi L, Dimitrova ZM, Visser M, Knaus M and Rehbein S** (2011) Principal intestinal parasites of dogs in Tirana, Albania. *Parasitology Research* **108**, 341–353.
- Xia C, Liu J, Yuan Z, Feng J and Song T** (2014) Investigation of infectious prevalence of major metacestodes in livestock in Tibet. *Chinese Veterinary Science/Zhongguo Shouyi Kexue* **44**, 1205–1209.
- Yan H, Lou Z, Li L, Ni X, Guo A, Li H, Zheng Y, Dyachenko V and Jia W** (2013) The nuclear 18S ribosomal RNA gene as a source of phylogenetic information in the genus *Taenia*. *Parasitology Research* **112**, 1343–1347.
- Yildirim A, İça A, Beyaz L and Atasaver A** (2006) Acute hepatitis cysticercosa and pneumonitis cysticercosa in a lamb: case report. *Turkiye Parazitoloji Dergisi* **30**, 108–111.
- Zhang Y, Zhao W, Yang D, Tian Y, Zhang W and Liu A** (2018) Genetic characterization of three mitochondrial gene sequences of goat/sheep-derived *Coenurus cerebralis* and *Cysticercus tenuicollis* isolates in Inner Mongolia, China. *Parasite* **25**, 1.