

The detection of clinically occult nasopharyngeal carcinoma in patients following radiotherapy – an analysis of 69 patients

JOHN M. NICHOLLS, F.R.C.P.A.* , DANIEL CHUA, F.R.C.R.†, PUI MAN CHIU, A.I.M.L.S.* ,
DORA L. W. KWONG, F.R.C.R.†

Abstract

A prospective analysis of 69 patients who had been treated for nasopharyngeal carcinoma (NPC) by external radiotherapy was carried out. Biopsies from the posterior nasopharynx were performed and analyzed by *in situ* hybridization using an antisense Epstein-Barr Early RNA (EBER) radio-labelled riboprobe. None of the patients had evidence of disease in the nasopharynx. One patient was found to have nasopharyngeal carcinoma detected only by *in situ* hybridization. In the subsequent 18-month follow-up of these clinically- and biopsy-negative patients, only one patient developed relapse in the nasopharynx. *In situ* hybridization is a valuable tool for the detection of NPC and should be routinely available in histopathology laboratories where NPC is regularly diagnosed.

Key words: Nasopharyngeal neoplasms; Carcinoma; Radiotherapy

Introduction

Nasopharyngeal carcinoma is a common tumour in the Hong Kong region with an incidence of 19 cases per 100,000 people. The tumour originates in the epithelium of the nasopharynx and ultrastructural studies have shown that it is squamous in origin. Radiotherapy is the mainstay of treatment but histological evidence of relapse in the nasopharynx after a disease-free period is seen in 11 per cent of patients (Nicholls *et al.*, 1993). The peak interval of relapse is 15 months after the completion of radiotherapy but ranges from seven months to 26 years. We undertook a prospective study of flexible endoscopic examination and biopsy of the posterior wall of the nasopharynx for all patients one year after the completion of radiotherapy. In addition to routine histopathology, the biopsy was used for *in situ* hybridization using ³⁵S riboprobes for EBERs 1 and 2. This paper is a report of the findings.

Materials and methods

All patients with NPC treated in Queen Mary Hospital are followed up by the Department of Radiation Oncology, Queen Mary Hospital, Hong Kong. For this study only patients with initial complete remission documented by serial biopsy at six and eight weeks after radiotherapy were entered into the study. As part of the follow-up procedures all patients regularly have endoscopic examination of the nasopharynx but in the past biopsy was only performed for clinically suspicious lesions. In the present study, after excluding patients with distant metastases, regional nodal relapse and those with confirmed or suspicious (endoscopic or other clinical evidence) relapse

in the nasopharynx, flexible endoscopic examination was performed and a tissue biopsy from the left and right posterior wall of the nasopharynx was taken and placed in 10 per cent neutral buffered formalin. The specimen was routinely processed and embedded in paraffin. Histological assessment of the biopsy was performed and a report issued to the clinician. The cases were then studied for the presence of EBERs 1 and 2 as previously described (Yuen *et al.*, 1994). A DNA fragment containing EBER 1 and 2 (nucleotides 6661 to 7119 of EBV) was prepared by PCR and cloned into the Bluescript vector, from which ³⁵S labelled antisense RNA probes were generated by *in vitro*-transcription. The sections for *in situ* hybridization were deparaffinized in two washes, respectively, of xylene and graded ethanol and rehydrated in water. Proteolysis was performed by 0.2 N HCl followed by washing and rinsing in phosphate buffered saline containing 20 mg of proteinase K. The slides were rinsed and placed in 0.25 per cent acetic anhydride with 0.1 M trimethanolamine for 10 minutes, washed, dehydrated in graded ethanol baths (80 per cent, 90 per cent and 100 per cent) and air dried. A hybridization buffer which included 10 mg/ml salmon sperm DNA, 5g/l rat RNA, 10 mg/ml tRNA, 50 per cent formamide and dextran sulphate was prepared to which a probe solution of EBER 1 and 2 was added. Hybridization was carried out at 50°C overnight in the presence of 6 × SSC. The sections were rinsed, treated with 20 g/ml ribonuclease A and coated with photographic emulsion. After exposure for 24 and 72 hours the slides were developed, fixed and stained with Mayer's haematoxylin and eosin.

From the Departments of Pathology* and Radiation Oncology†, The University of Hong Kong, Queen Mary Hospital Compound, Pok Fu Lam, Hong Kong.

Supported by grant 335/046/0066.

Accepted for publication: 27 January 1996.

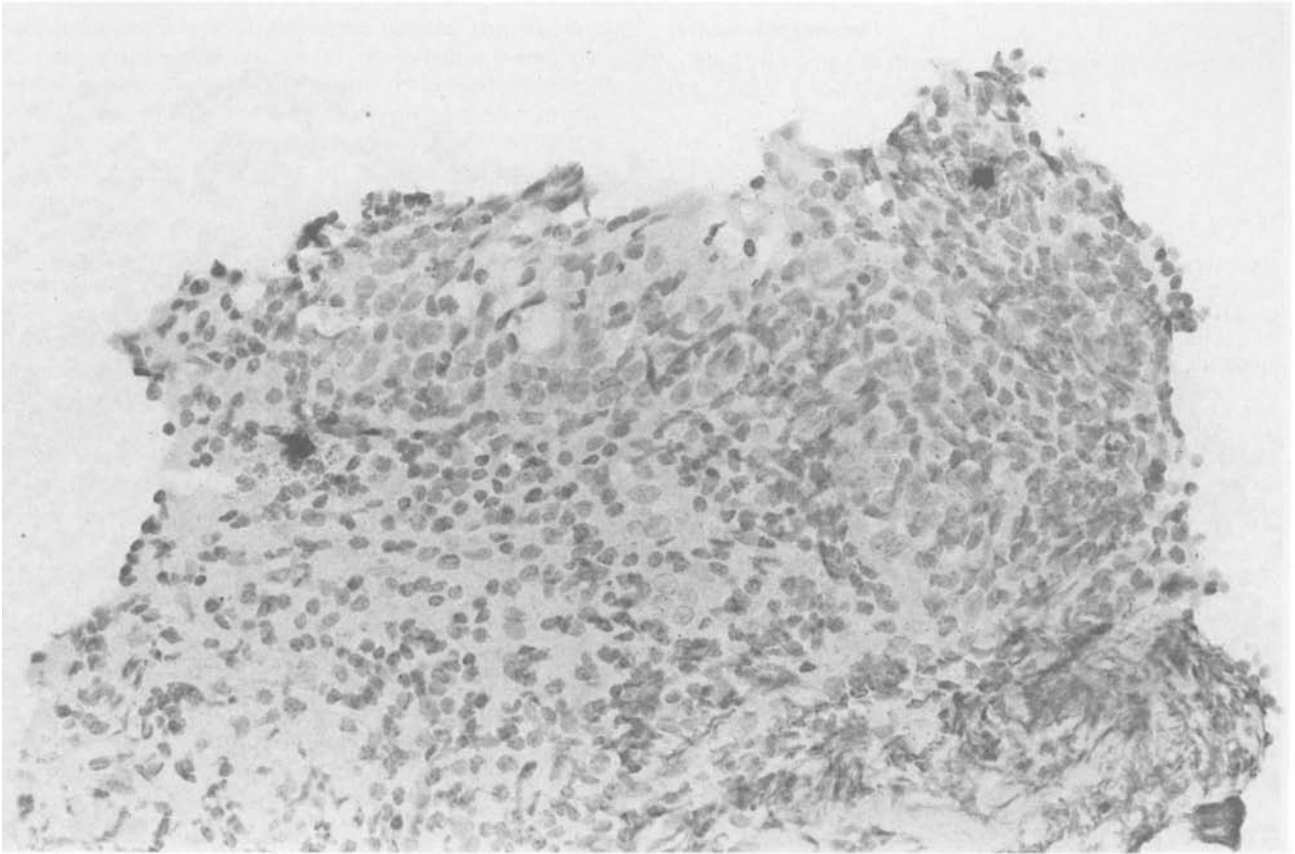


FIG. 1

In situ hybridization showing two positive lymphocytes in the nasopharyngeal stroma of a patient one year after the completion of radiotherapy (H & E; $\times 280$).

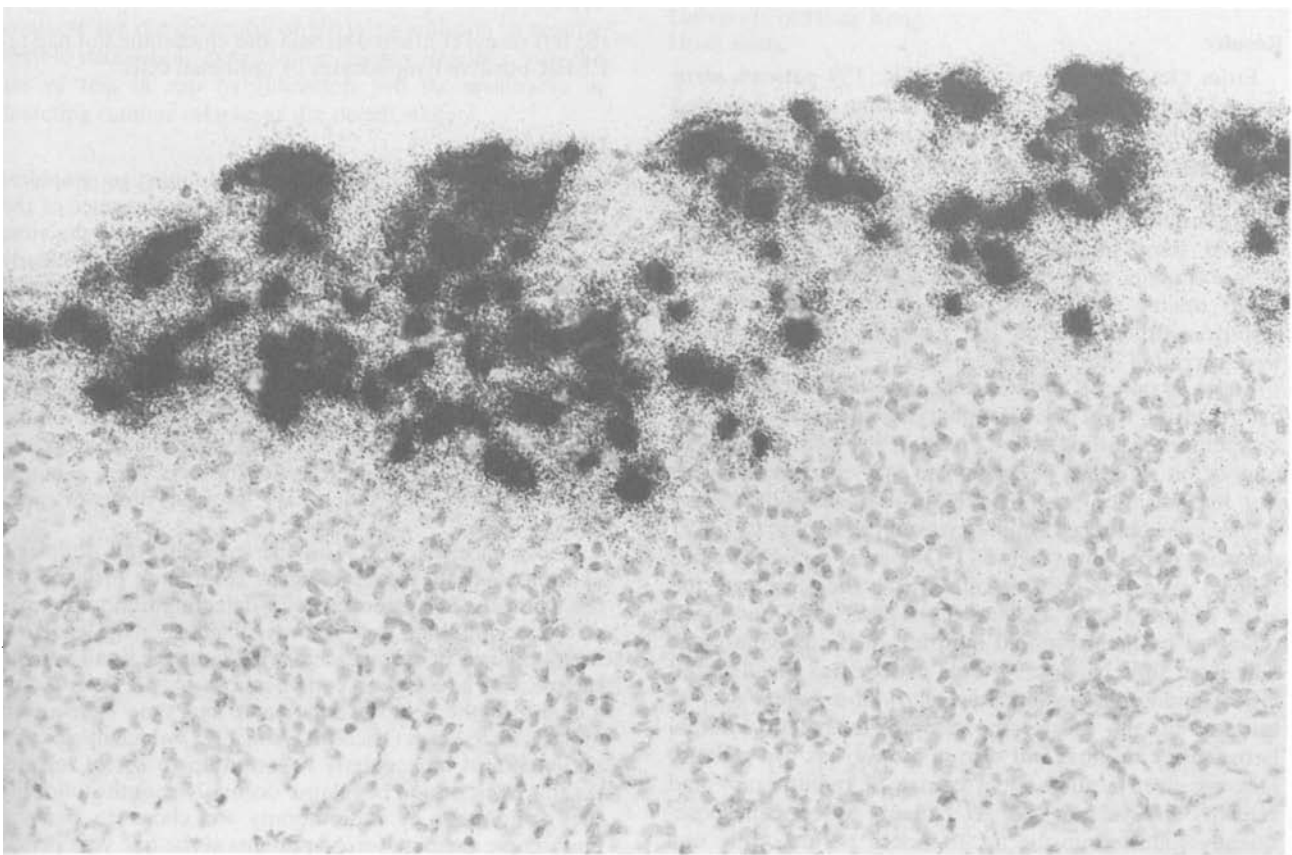


Fig. 2

In situ hybridization showing a nest of positive EBER tumour cells at the edge of a nasopharyngeal biopsy one year after the completion of radiotherapy (H & E; $\times 280$).

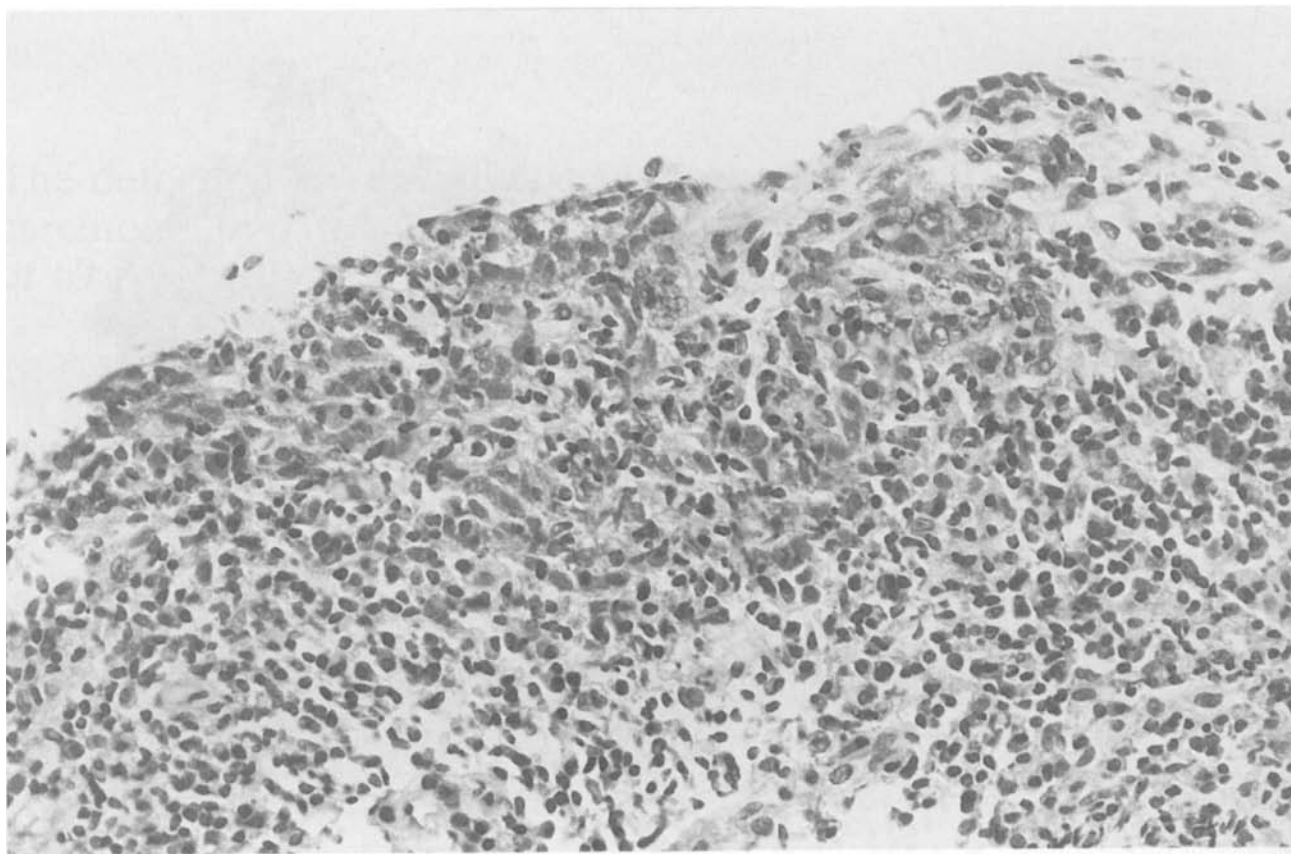


FIG. 3

The original haematoxylin and eosin slide of the case shown in Figure 2. The tumour cells are obscured by an intense lymphoid infiltrate (H & E; $\times 280$).

Results

From October 1992 to April 1994, 159 patients were treated for nasopharyngeal carcinoma and achieved complete remission. Of these patients, in the first year of follow-up, nine patients developed local relapse (5.7 per cent). Two of these relapsing patients were asymptomatic at the time of diagnosis but subsequent examination showed gross tumour. Of the remaining 150 patients, after excluding patients with distant metastasis, regional nodal relapse and those with confirmed or evidence suspicious of relapse in the nasopharynx, 69 patients were recruited into the present study.

These 69 patients, with normal endoscopic examination, had biopsies from the nasopharynx one year after the completion of radiotherapy. None of the patients showed tumour on standard haematoxylin and eosin staining. *In situ* hybridization with EBER probes showed positive signals over scattered lymphocytes in the stroma in 19 (27 per cent) of patients (Figure 1). One patient (1.4 per cent) showed a nest of positive cells within the stroma at the edge of the biopsy (Figure 2). These cells had been obscured by the lymphoid infiltrate in the haematoxylin and eosin slide (Figure 3). This patient was recalled and repeat endoscopic examination showed a visible nest of tumour in the posterior nasopharynx. The interval between the original and second biopsy was two months. He was given a subsequent course of radiotherapy and remains disease free. All 69 patients have been subsequently followed-up for an 18-month period. Only one patient who had a negative biopsy at the one year assessment developed relapse in the left recess of the nasopharynx six months later. The biopsy at one year from

the left recess contained stroma and epithelium but had no EBER-positive lymphocytes or epithelial cells.

Discussion

NPC is an epithelial tumour which in most geographical localities is intimately associated with the presence of the Epstein-Barr virus. Though the exact function of the virus with respect to tumour development is still not clearly elucidated the presence of the virus serves as a useful marker of tumour presence. Current methods for the detection of EBV include Southern blot analysis, DNA amplification, immunohistochemistry with anti-latent membrane protein antibodies and *in situ* hybridization. For the cellular localization of the viral genome *in situ* hybridization is more sensitive than immunohistochemistry and using EBER oligonucleotides always gives a higher signal intensity than other EBV probes (Brousset *et al.*, 1992).

Recurrence of NPC in the nasopharynx following external radiotherapy remains a continuing problem for the clinician. The importance of detecting tumour relapse at the occult stage is that early diagnosis may lead to a better chance of salvage, and treatment for small volume relapse will have fewer complications. A previous report has shown the relapse may occur any time from seven months to 26 years (Nicholls *et al.*, 1993) which means that patients must be regularly followed up to detect relapse. As this peak period of relapse occurs 15 months following the completion of radiotherapy we chose to perform endoscopic examination on patients at the one year period to see if early *in situ* lesions or occult tumour could be detected. In this study we were only able to detect one case of clinically occult tumour. At the time of biopsy in this

patient the endoscopic findings were those of scarring with no gross evidence of relapse. In the original biopsy the carcinoma was obscured by a prominent inflammatory cell infiltrate but was readily seen using radiolabelled *in situ* hybridization. Whilst one group (Sam *et al.*, 1993) has reported a positive detection rate of EBER positive cells of 11 per cent from biopsy material, our frequency of 27 per cent is higher. When autopsy material from normal individuals is used from the same hospital as in this study the detection rate rises to 87 per cent (Tao *et al.*, 1995). This variation is dependent on the size of material available for study as autopsy material will provide a greater amount of tissue for examination than that from endoscopic examination. It is too early to speculate if the continued presence of EBER-positive cells has a greater risk for developing relapse.

The results of this study have three important messages for the clinicians involved in the management of patients with NPC. The first is that even though flexible endoscopic examination may be superior to indirect mirror examination of the nasopharynx, a normal examination cannot exclude residual tumour. The second is that patients should have frequent examinations of the nasopharynx following radiotherapy as re-growth of tumours may evolve over a short period of time. Finally, *in situ* hybridization is an excellent technique for the detection of small nests of tumour which may not be easily visible under ordinary haematoxylin and eosin staining. We chose to use radiolabelled *in situ* hybridization but a non-isotopic, digoxigenin labelled kit is commercially available and this shows comparable results to isotopic methods. We believe that any pathology laboratory involved in the routine diagnosis of NPC should have this technique available for the detection of EBV. In addition to regular flexible endoscopic examination, biopsy together with the use of this *in situ* hybridization will be invaluable in detecting tumour relapse at the occult stage.

Acknowledgement

Dr L P Chung is thanked for original development of the EBER 1 and 2 probe.

References

- Brousset, P., Butet, V., Chittal, S., Selves, J., Delsol, G. (1992) Comparison of *in situ* hybridization using different non-isotopic probes for detection of Epstein-Barr virus in nasopharyngeal carcinoma and immunohistochemical correlation with anti-latent membrane protein antibody. *Laboratory Investigation* **67**: 457–464.
- Nicholls, J. M., Sham, J. S. T., Ng, M. H. (1993) *In situ* carcinoma adjacent to recurrent nasopharyngeal carcinoma. Evidence of a new growth? *Pathology, Research and Practice* **189**: 1067–1070.
- Sam, C. K., Brooks, L. A., Niedobitek, G., Young, L. S., Prasad, U., Rickinson, A. B. (1993) Analysis of Epstein-Barr virus infection in nasopharyngeal biopsies from a group at high risk of nasopharyngeal carcinoma. *International Journal of Cancer* **53**: 957–962.
- Tao, Q., Srivastava, G., Chan, A. C. L., Chung, L. P., Loke, S. L., Ho, F. C. S. (1995) Evidence for lytic infection by Epstein-Barr virus in mucosal lymphocytes instead of nasopharyngeal epithelial cells in normal individuals. *Journal of Medical Virology* **45**: 71–77.
- Yuen, S. T., Chung, L. P., Leung, S. Y., Luk, I. S. C., Chan, S. Y., Ho, J (1994) *In situ* detection of Epstein-Barr virus in gastric and colorectal adenocarcinomas. *American Journal of Surgical Pathology* **18**: 1158–1163.

Address for correspondence:
Dr J. Nicholls,
Department of Pathology,
University of Hong Kong,
Hong Kong.

Fax: (852) 28725197