

The role of midfacial degloving in modern rhinological practice

DAVID J. HOWARD, F.R.C.S., F.R.C.S. (ED.), VALERIE J. LUND, M.S., F.R.C.S. (LONDON)

Abstract

The midfacial degloving approach has been available for twenty five years and is slowly increasing in popularity in the management of extensive benign lesions of the sinonasal region, for selected malignancy in this area and to afford access to the nasopharynx and infra-temporal fossa. The advantages, applications and low complication rate are presented in a cohort of 86 patients, ranging from three to 79 years of age with a mean follow-up of 5.5 years. Seventy-seven per cent of the group had benign pathology of which juvenile angiofibroma was the commonest (40 cases). The 20 cases of malignant disease were a heterogeneous group histopathologically including adenoid cystic carcinoma (four cases), malignant schwannoma (two cases), rhabdomyosarcoma (two cases) and squamous cell carcinoma (two cases). Five underwent bilateral radical maxillectomies combined with orbital clearance in one patient. Complications include oro-antral fistula (three cases) and epiphora (three cases) all of which were successfully treated.

Key words: Paranasal sinuses; Nose; Neoplasms; Surgery, operative

Introduction

In 1992 the application of the midfacial degloving approach in 36 cases of sinonasal pathology was published (Howard and Lund, 1992), representing at that time one of the largest series in the literature. Continued experience with the application of the technique in the last six years suggested it was an appropriate moment to review the utility of this technique in modern rhinological practice. Unilateral exposure of the midfacial skeleton via an intra-oral incision with sub-periosteal elevation was originally described by Converse in 1950. The technique was subsequently extended to combine a bilateral sublabial incision with elevation of the external nasal tissues via inter-cartilaginous and transfixation incisions to mobilize the soft tissues of the entire middle-third of the face (Casson *et al.*, 1974). This approach, however, was obviously derivative from those approaches described by Denker in 1906 and Portmann and Retrovey in 1927. Initially described by Casson and colleagues for cases of fibrous dysplasia, it subsequently provided a useful approach to midfacial fractures, craniofacial dysostosis and a range of maxillary sinus neoplasia.

The operation gained some popularity in the United States resulting in a number of publications in the 1980s (Allen and Siegel, 1981; Anand and Conley, 1983; Maniglia, 1986; Price, 1986). More recently Maniglia and Phillips (1995) published a further review of the procedure in 30 cases treated between 1986 and 1994. Publications in the European literature have remained sporadic with relatively small series, largely confined to the

management of inverted papilloma (Sachs *et al.*, 1984; Buchwald *et al.*, 1995; Esteban *et al.*, 1997; Peter and Grossenbacher, 1997; Plinkert *et al.*, 1997).

Materials and methods

The midfacial degloving approach has been undertaken in 86 patients since 1986, utilizing a technique which has remained essentially unchanged since it was described in 1992 (Howard and Lund, 1992). Potential post-operative complications remain haemorrhage, temporary or permanent parasthesia of the overlying skin, oro-antral fistula and vestibular stenosis.

Results

The cohort of 86 patients consisted of 72 males and

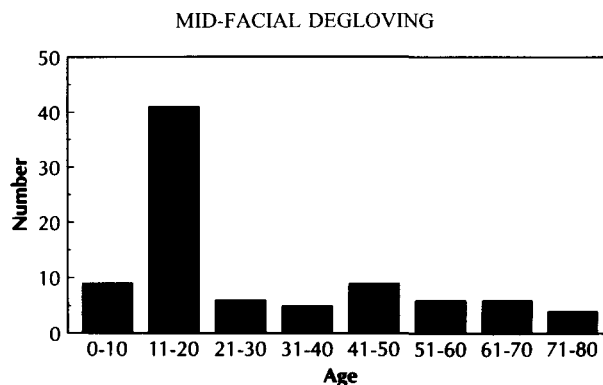


FIG. 1

Histogram showing distribution by age of patients undergoing mid-facial degloving.

From the Institute of Laryngology and Otology, University College London, London, UK.
Accepted for publication: 28 June 1999.

TABLE I
MALIGNANT AND BENIGN PATHOLOGIES TREATED BY A MIDFACIAL
DEGLOVING APPROACH

<i>Malignant</i>	
Adenoid cystic	4
Malignant schwannoma	2
Rhabdomyosarcoma	2
Squamous cell carcinoma	2
NPC	2
Plasmacytoma	1
Malignant melanoma	1
Neuroblastoma	1
Chondrosarcoma	1
Transitional cell carcinoma	1
Adenocarcinoma	1
Lymphoma	1
BCC	1
<i>Benign</i>	
Angiofibroma	40
Inverted papilloma	8
Fibro-osseous disease	4
Dermoid cyst	3
Fungal infection	2
HHT	2
Neurolemmoma	1
Ameloblastoma	1
Haemangiolymproma	1
Haemangioma	1
Odontogenic cyst	1
Facial #	1
Cherubism	1

14 females, the sexual bias reflecting the pathologies treated. Their ages ranged from three to 79 years with a mean of 28 years. Fifty-eight per cent were under 20 at the time of surgery, emphasizing the cosmetic considerations in such a young population (Figure 1). The cohort included a wide range of both malignant and benign conditions, the latter constituting 77 per cent of the group, with juvenile angiofibroma representing by far the commonest pathology (40 cases) (Table I). Follow-up ranged from six months to 12 years (with a mean of 5.5 years).

Previous surgical procedures had been employed in 11 cases which included lateral rhinotomy (seven), Caldwell-Luc (two) and septodermoplasty (two). Four individuals have required revision surgery for residual recurrent disease (two for angiofibroma, one for a calcifying odontogenic cyst, one for an ossifying fibroma).

Complications included three cases of oro-antral fistula. All of these occurred in the first 36 cases originally reported and two were in patients who had undergone previous Caldwell-Luc procedures. They were all closed primarily. Mild temporary epiphora may occur after the procedure but has only persisted in three individuals all of whom were successfully treated with an endoscopic dacrocystorhinostomy. The two cases of hereditary haemorrhagic telangiectasia developed subtotal septal perforations as a result of the bilateral septal mucosal mobilization. These two cases occurred in the early part of the series and no attempt was made to close them. There have been no cases of vestibular stenosis.

In the 20 cases of malignant diseases five underwent bilateral radical maxillectomies, combined with orbital clearance in one patient. No cases of craniofacial resection are included in this cohort.

Discussion

Despite a number of moderately large series of this technique in both the American and European literature it would seem that the midfacial degloving approach has not achieved the degree of popularity that might be anticipated given its excellent exposure of the nasal cavity, middle third of the face and central skull base combined with its outstanding cosmetic result. The technique can clearly be modified and extended and accomplishes all that may be achieved via a conventional Weber-Ferguson approach and more, without the disfiguring scar. Its main limitations are access to the frontal sinus and anterior skull base and the duration of the procedure. However, the approach may be readily combined with a bicoronal incision for craniofacial resection, particularly in the young (Nishikawa *et al.*, 1993; Lund *et al.*, 1998). The increased length of the procedure relates primarily to the closure which must be done with care to avoid the complications of fistula and especially vestibular stenosis. However, except in some of our elderly patients, the procedure has largely replaced the lateral rhinotomy.

In this series juvenile angiofibroma predominate although in the literature inverted papilloma has proved the most popular indication (Buchwald *et al.*, 1995; Esteban *et al.*, 1997; Peter and Grossenbacher, 1997; Plinkert *et al.*, 1997). The previously high recurrence rates reported for this condition (up to 75 per cent) undoubtedly reflect residual rather than recurrent disease (Cummings and Goodman, 1970; Snyder and Perzin, 1972; Calcaterra *et al.*, 1980; Weissler *et al.*, 1986). In selected cases an endonasal endoscopic approach may be applied with good long-term results (Wigand and Hosemann, 1991) although in a recent personal series of 22 patients an entirely endoscopic approach was only possible in six and in the remaining 16, a midfacial degloving or lateral rhinotomy approach was employed (14 of whom had undergone previous external surgery). Most other series of inverted papilloma also contain a similar mix of endoscopic and external approaches as determined by the extent of the disease (Dolgin *et al.*, 1992; Buchwald *et al.*, 1995; Peter and Grossenbacher, 1997; Plinkert *et al.*, 1997).

Juvenile angiofibroma has been the main indication in our series, as described by other authors (Allen and Siegal, 1981; Radkowski *et al.*, 1996). The application of this approach to a range of benign fibro-osseous conditions, facial fractures, osteotomies and bone grafting is readily apparent. However, its use in severe hereditary haemorrhagic telangiectasia for radical septodermoplasty is not advocated and has been superseded by closure of the nasal cavity (Lund and Howard, 1997).

The use of the technique for sinonasal malignancy should only be attempted in those selected cases that can be successfully encompassed by the exposure. However, as previously noted, the procedure may be extended to a craniofacial resection and enables bilateral maxillectomy and/or orbital clearance as appropriate (Lund *et al.*, 1998). The procedure may be combined with pre- or post-operative radio-

therapy and/or chemotherapy and allows immediate prosthetic rehabilitation with, or without, the use of osseo-integrated implants. The approach may be revised on a number of occasions without cosmetic compromise and has been used as an approach to the nasopharynx for nasopharyngeal cancer. However, this has only been in exceptional limited lesions that have failed radiotherapy. To achieve optimal control of the internal carotid artery, a maxillary swing approach would be generally preferred (Wei *et al.*, 1991).

Although a midfacial degloving approach was utilized in one patient with malignant melanoma, a lateral rhinotomy or even an endoscopic approach in limited cases may be preferred in patients who are generally elderly and in whom the disease may extend anteriorly to the mucocutaneous junction of the vestibule (Lund *et al.*, in press).

Whilst avoiding facial incisions, radical midfacial surgery in children as young as three might justifiably raise concerns regarding subsequent facial development. However, within the parameters of this approach, if the hard palate, cartilaginous septum and upper lateral cartilages are not disturbed there is no evidence on standardized sequential photography that distortion of midfacial growth occurs. In a study of 31 adolescents or children ranging in age from two to 16 years (mean 11.3 years), nine of whom had undergone midfacial degloving, serial standardized photography failed to show any significant cosmetic distortion (Lund *et al.*, 1995).

The midfacial degloving approach is an important component of our armamentarium in the management of a diverse range of sinonasal pathology. As with all surgical procedures it is not applicable in every case as may be judged when it is placed in the context of all sinonasal neoplasia treated since 1986. During this 12 year period, 86 cases were treated primarily by a midfacial degloving approach out of a total of 421 patients undergoing radical surgery for nose and sinus tumours. It does, however, provide a number of significant advantages over conventional techniques in particular the anachronistic Weber Fergusson/Diffenbach approaches which we now rarely utilize.

References

- Allen, G. W., Siegel, G. I. (1981) The sublabial approach for extensive nasal and sinus resection. *Laryngoscope* **91**: 1635–1640.
- Anand, V. K., Conley, J. J. (1983) Sublabial surgical approach to the nasal cavity and paranasal sinuses. *Laryngoscope* **93**: 1483–1484.
- Buchwald, C., Franzmann, M. B., Tos, M. (1995) Sinonasal papillomas: a report of 82 cases in Copenhagen County, including a longitudinal epidemiological and clinical study. *Laryngoscope* **105**(1): 72–79.
- Calcaterra, T. C., Thompson, J. W., Paglia, D. E. (1980) Inverting papillomas of the nose and paranasal sinuses. *Laryngoscope* **90**: 53–60.
- Casson, P. R., Bonnano, P. C., Converse, J. M. (1974) The midfacial degloving procedure. *Plastic and Reconstructive Surgery* **53**: 102–103.
- Converse, J. M. (1950) Restoration of facial contour by bone grafts introduced through oral cavity. *Plastic and Reconstructive Surgery* **6**: 295–300.
- Cummings, C. W., Goodman, M. L. (1970) Inverted papillomas of the nose and paranasal sinuses. *Archives of Otolaryngology* **92**: 445–449.
- Denker, A. (1906) Ein neuer weg für die operation der malignen nasen tumoren. *Munscher Medizinische Wochenschrift* **20**: 20–26.
- Dolgin, S. R., Zaveri, V. D., Casiano, R. R., Maniglia, A. J. (1992) Difference options for treatment of inverting papilloma of the nose and paranasal sinuses: a report of 41 cases. *Laryngoscope* **102**(3): 231–236.
- Esteban, F., Jurado, A., Cantillo, E., Mochon, A., Caado, J. M. (1997) Facial degloving as a versatile approach to paranasal sinus tumours. *Acta-Otorrinolaringologica Espanola* **48**(6): 457–460.
- Howard, D. J., Lund, V. J. (1992) The midfacial degloving approach to sinonasal disease. *Journal of Laryngology and Otology* **106**(12): 1059–1062.
- Lund, V. J., Howard, D. J. (1997) Closure of the nasal cavities in the treatment of refractory hereditary haemorrhagic telangiectasia. *Journal of Laryngology and Otology* **111**: 30–33.
- Lund, V. J., Howard, D. J., Harding, L., Wei, W. (1999) Management options and survival in malignant melanoma of the sinonasal mucosa. *Laryngoscope* (in press).
- Lund, V. J., Howard, D. J., Wei, W. I., Cheesman, A. D. (1998) Craniofacial resection for tumors of the nasal cavity and paranasal sinuses – a 17 year experience. *Head and Neck Surgery* **20**: 97–105.
- Lund, V. J., Neijens, H., Clement, P., Lusk, R., Stammberger, H. (1995) The treatment of chronic sinusitis: A controversial issue. *International Journal of Pediatric Otorhinolaryngology* **32**(Suppl): S21–35.
- Maniglia, A. J. (1986) Indications and techniques of midfacial degloving. *Archives of Otolaryngology – Head and Neck Surgery* **112**: 750–752.
- Maniglia, A., Phillips, D. A. (1995) Midfacial degloving for the management of nasal, sinus, and skull-base neoplasms. *Otolaryngologic Clinics of North America* **28**(6): 1127–1143.
- Nishikawa, K., Nishioka, S., Aoji, K., Koike, S., Nameki, H. (1993) Skull base surgery using the degloving technique – an approach without facial scarring. *Nippon-Jibiinkokagakkai-Kaiho* **96**(9): 1447–1456.
- Peter, B., Grossenbacher, R. (1997) Inverted papilloma of the nose and paranasal sinuses. *Laryngorhinootologie* **76**(1): 14–18.
- Plinkert, P. K., Ruck, P., Baumann, I., Scheffler, B. (1997) Inverted papilloma of the nose and paranasal sinuses – diagnosis, surgical procedure and studies of cytokeratin profile. *Laryngorhinootologie* **76**(4): 216–224.
- Portmann, G., Retrovey, H. (1927) *Le cancer due nez*. Gaston Doin et Cie, Paris.
- Price, J. C. (1986) The midfacial degloving approach to the central skull-base. *Ear Nose Throat Journal* **65**: 174–180.
- Radkowski, D., McGill, T., Healy, G. B., Ohlms, L., Jones, D. T. (1996) Angiofibroma. Changes in staging and treatment (see comments). *Archives of Otolaryngology – Head and Neck Surgery* **122**(2): 122–129.
- Sachs, M. E., Conley, J., Rabuzzi, D., Blaugrund, S., Price, J. (1984) Degloving approach for total excision of inverted papilloma. *Laryngoscope* **94**: 1595–1598.
- Synder, R. N., Perzin, K. H. (1972) Papillomatosis of nasal cavity and paranasal sinuses (inverted papilloma, squamous papilloma). *Cancer* **30**: 668–690.
- Wei, W. I., Lam, K. H., Shams, J. S. (1991) New approach to the nasopharynx: the maxillary swing approach. *Head and Neck* **13**: 206–207.
- Weissler, M. C., Montgomery, W. W., Turner, P. A., Montgomery, S. K., Joseph, M. P. (1986) Inverted papilloma. *Annals of Otology, Rhinology and Laryngology* **95**: 215–221.
- Wigand, M. E., Hosemann, W. G. (1991) Results of endoscopic surgery of the paranasal sinuses and anterior skull base. *Journal of Otolaryngology* **20**: 385–390.

Address for correspondence:
Professor Valerie J. Lund,
Institute of Laryngology and Otology,
University College London,
330–332 Gray's Inn Road,
London WC1X 8DA.

Fax: +44 0171 833 9480